

Achlya infection in an Oscar (*Astronotus ocellatus*) with typical symptoms of saprolegniosis

Rahim Peyghan^{1*}, Roya Rahnama², Zahra Tulaby Dezfuly³, Maryam Shokoozmand³

¹ Department of Clinical Sciences, Faculty of Veterinary Medicine, Shahid Chamran University of Ahvaz, Ahvaz, Iran; ² Graduated student of Aquatic Animal Health, Faculty of Veterinary Medicine, Shahid Chamran University of Ahvaz, Ahvaz, Iran; ³ PhD Candidate of Aquatic Animal Health, Faculty of Veterinary Medicine, Shahid Chamran University of Ahvaz, Ahvaz, Iran.

Article Info	Abstract
<p>Article history:</p> <p>Received: 21 April 2018 Accepted: 29 September 2018 Available online: 15 March 2019</p> <p>Key words:</p> <p><i>Achlya</i> Fungus Ornamental fish Oscar</p>	<p>Saprolegniosis is one of the most frequent diseases in the ornamental fish industry that may cause by <i>Achlya</i> spp. There is no report of fungal infection caused by <i>Achlya</i> spp. in Oscar (<i>Astronotus ocellatus</i>) in Iran. An Oscar fish was referred to the Veterinary Hospital, Shahid Chamran University of Ahvaz, Ahvaz, Iran with saprolegniosis symptoms including loss of appetite and yellow to gray cottony mass on the skin of flank and caudal peduncle. The infected area of the fish body was investigated by wet smear. After observing broad aseptate hyphae (approximate width 10-15 μm), the infected skin was inoculated on Sabouraud dextrose agar and incubated at 30 °C for seven days. The large fungi colony was appeared on the agar and the isolated fungi were detected as <i>Achlya</i> spp. after examination by wet and stained dry smears according to the morphology of hypha, spores, and zoosporangium. It is the first report of cutaneous saprolegniosis in Oscar caused by <i>Achlya</i> spp. in Iran.</p>

© 2019 Urmia University. All rights reserved.

آلودگی به آکلیا در یک ماهی اُسکار (*Astronotus ocellatus*) با علائم مشخص ساپروولگنیوز

چکیده

ساپروولگنیوز یکی از شایع ترین بیماری‌ها در صنعت ماهیان زینتی می باشد که ممکن است توسط گونه های آکلیا ایجاد شود. گزارشی مبنی بر آلودگی قارچی ناشی از گونه آکلیا در ماهی اُسکار (*Astronotus ocellatus*) در ایران وجود ندارد. یک قطعه ماهی اُسکار به بیمارستان دامپزشکی دانشگاه شهید چمران اهواز، اهواز، ایران با علائم ساپروولگنیوز شامل بی اشتها و توده پنبه ای زرد تا خاکستری بر روی پوست تنه و ساقه دمی ارجاع داده شد. ناحیه آلوده بدن ماهی به واسطه تهیه گسترش مرطوب مورد بررسی قرار گرفت. پس از مشاهده ریشه های عریض غیرمنشعب (با عرض تقریبی ۱۰-۱۵ میکرومتر)، پوست آلوده در ساپروود دکستروز آگار کشت داده شد و در دمای ۳۰ درجه سانتیگراد به مدت هفت روز نگهداری گردید. کلونی بزرگی از قارچ ها بر روی آگار ظاهر گردید و قارچ های جدا شده متعاقب ارزیابی توسط گسترش های مرطوب و رنگ آمیزی شده خشک بر اساس ریخت شناسی ریشه، اسپورها و زئوسپرانژیوم، گونه آکلیا تشخیص داده شد. این گزارش نخستین مورد ساپروولگنیوز جلدی ناشی از گونه آکلیا در ماهی اُسکار در ایران می باشد.

واژه های کلیدی: آکلیا، اُسکار، قارچ، ماهی زینتی

*Correspondence:

Rahim Peyghan. DVM, PhD
Department of Clinical Sciences, Faculty of Veterinary Medicine, Shahid Chamran University of Ahvaz, Ahvaz, Iran.
E-mail: peyghan_r@scu.ac.ir



This work is licensed under a Creative Commons Attribution-NonCommercial 4.0 International License which allows users to read, copy, distribute and make derivative works for non-commercial purposes from the material, as long as the author of the original work is cited properly.

Introduction

Saprolegniosis (water molds disease) is one of the most common diseases of freshwater fish caused by members of class Oomycetes fungi. This fungal infection is one of the most frequent problems in the ornamental fish industry.¹ Most fungi create superficial infection and attack the external tissues, however, a number of them cause systemic kind of infection.² Many investigations have reported fungal contamination in ornamental fish in the world.^{3,4} In Iran, the outbreak of these diseases has been observed in rainbow trout cultured in the country. For instance, Shahbazian *et al.* and Fadaeifard *et al.* have isolated number of fungi species from infected eggs of rainbow trout.^{5,6}

Saprolegniosis is a fungal disease caused by members of the order Saprolegniales (i.e., *Achlya*, *Dictyuchus*, *Saprolegnia* and *Aphanomyces*). *Achlya* is one of the most virulent genera in comparison with *Saprolegnia* in freshwater fishes and it causes severe damages in aquaculture. In the infected fish, the disease appears as cotton wool-like lesions causing the skin destruction.^{4,7}

Oscar (*Astronotus ocellatus*) is the most commercial and popular ornamental fish. It is a species of fish from the Cichlid family known under a variety of common names including tiger Oscar and velvet Cichlid.⁸ The ornamental fishes are exported and transported alive, so it can be the main cause of various pathogens introduction to importing countries.⁹ In this study, for the first time, isolation of *Achlya* fungi along with the emphasis on morphological characteristics of *Achlya* from Oscar has been described.

Case Description

In December 2016, an Oscar fish was referred to the Veterinary Hospital, Shahid Chamran University of Ahvaz, Ahvaz, Iran. Infected fish showed symptoms like an initial loss of appetite, the darkness of skin, fin rot, eroded scales and bloody wounds on the body and in the caudal region. Then, the symptoms progressed to widespread yellow to gray cottony mass on the skin of flank and caudal peduncle (Fig. 1). The wet mounts were prepared from the skin and fins and the fungal hyphae were seen and inspected (Figs. 2 and 3). For culturing of fungal specimens, Sabouraud dextrose agar (Merck, Darmstadt, Germany) (SDA; Fig. 4) was prepared and streptomycin sulphate (Nasr-pharmaceutical co., Tehran, Iran) was added in order to avoid bacterial contamination. The agar plates were incubated at 30 °C and fungal growth was observed after 7 days.⁴ For microscopic detection, slides were prepared by taking a sample from the colony and stained with 0.05% Trypan blue in lactophenol (Merck). After preparing the slides, they were observed under a microscope and photographed.⁷ The fungal identification was carried out using identification keys.⁴

The genus *Achlya* consists of a number of species that their zoospores do not swim away from the zoosporangium and they encyst as a hollow ball at its mouth (Fig. 5).¹

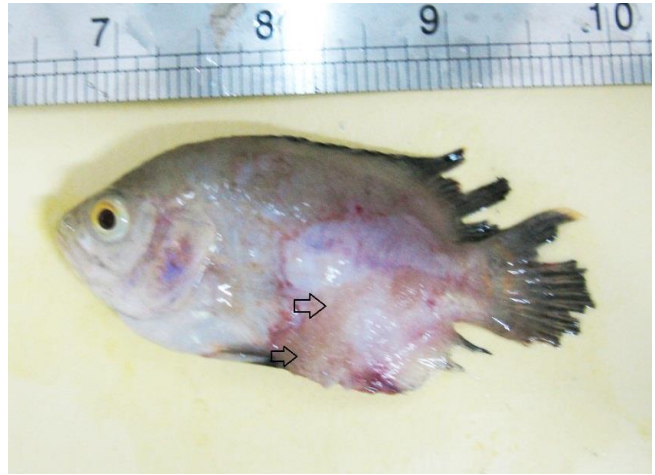

Fig. 1. An Oscar fish with yellow to gray cottony mass on the skin of flank (arrows) and caudal peduncle.

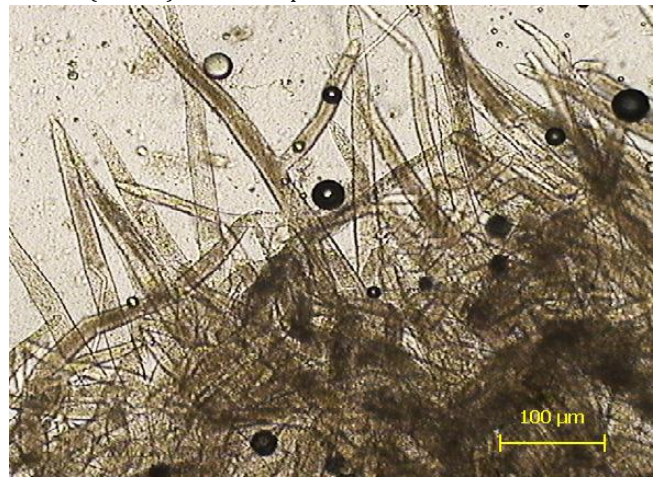

Fig. 2. *Achlya* hypha in a fresh wet smear of fish skin.

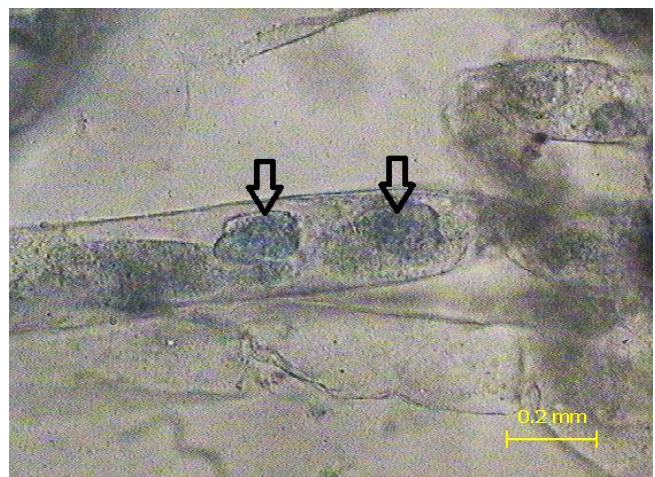


Fig. 3. *Achlya* hypha in a fresh wet smear of fish skin with the infecting secondary zoospores inside the hyphae (arrows).

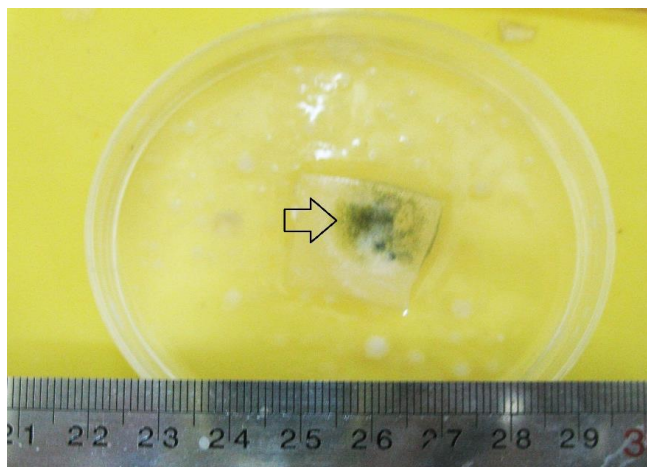


Fig. 4. *Achlya* spp. fungal colony grown on Sabouraud dextrose agar inoculated from the fish (arrow).

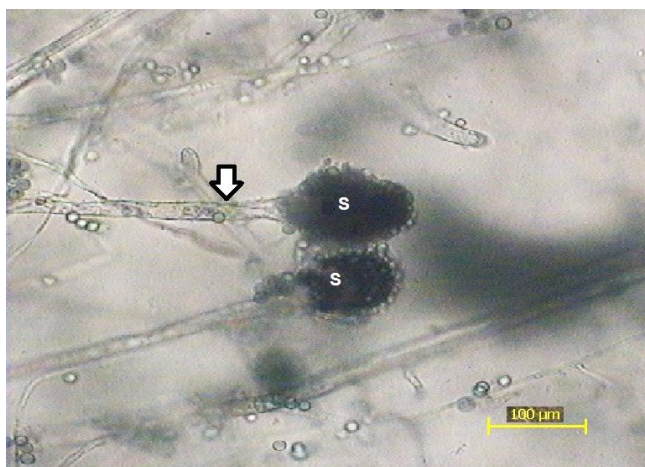


Fig. 5. Hypha (arrow) and sporangium (S) of *Achlya* spp. from the isolated fungal colony grown on Sabouraud dextrose agar inoculated from diseased fish.

Infected fish showed clinical signs of fungal infection such as ruptured dorsal fins, the skin darkness, skin erosion and yellow to brown cottony mass on the skin of flank and caudal peduncle. The scales were eroded and muscles were exposed from the lesion in some regions. This is a sign of chronic infection. This kind of lesion indicates a secondary fungal infection. The wet smear was prepared from the skin and fins and no parasites were observed, but hyphae of Saprolegnia-like fungus were recognized. By culturing fungal specimens on SDA, and after three days, gray-green fungal colonies appeared on agar plates (Fig. 3). By examining the hypha of fresh smear from the colonies, the *Achlya* spp. was identified based on colonies and microscopic observations.¹

Discussion

The classical white to gray or yellow to brown, fluffy fungus growing on sick fish is the problem of many

aquarium fish owners. This disease is usually due to the last stage of events where a saprophytic organism has become an opportunistic pathogen. Saprolegnials including *Achlya* spp. are normally called water molds, since they are common components of the aquatic biota and spend most of their time harmlessly breaking down the dead and decaying organic materials such as plant matter or the old dead bacteria in the water.⁹ What triggers these harmless molds to change from a saprophyte into a pathogen is complex. Changes in water quality and high amounts of dissolved organic compounds help the fungi to reach unnaturally high population densities where they can colonize the host after any damage to the epithelium to cause the initial infection. Suppression of fish immunity can be also considered as a major factor in permitting the water molds to change from saprophytes to opportunistic pathogens.¹⁰ The isolated fungi detected as *Achlya* spp. after examination by wet and stained dry smears according to the morphology of hypha, spores, and zoosporangium. Results of the present study showed that the isolated fungus was found to be pathogenic to fish. Infections caused by *Achlya* have been described previously. Kitancharoen *et al.* have reported a new record of *Achlya klebsiana* from snakehead (*Channa striatus*), with a fungal infection in Myanmar.¹²

Infected fish showed clinical signs of fungal infection such as ruptured dorsal fins, the skin darkness, skin erosion and yellow to brown cottony mass on the skin of flank and caudal peduncle. This report is supported by findings of Iqbal *et al.* and is comparable to the finding of Saraswathi *et al.*, who reported that the most frequent important sign of *Achlya* sp. infection can be observed in all fishes was decoloration of the body followed by descaling and exposure of epidermis. Additionally, there were patches, lesions, and ulcerations which mostly occurred in the head and tail regions.^{9,13}

The growth of *Achlya* spp. in smear and culturing medium indicate that this fungus was responsible for the pathological signs in the affected fish. Since *Achlya* regarded as the most pathogenic water mold, maintenance of water quality and feeding in pet shops needs more attention to prevent skin fungal infections. Poor water quality is one of the most important factors favouring the growth of this fungus.¹⁰

Shahbazian *et al.* and Fadaeifard *et al.* have isolated number of fungi species from infected eggs of rainbow trout in Iran.^{5,6} However, there is no report on the isolation of this fungus in the Oscar fish in Iran. There is a lack of information about the identification and characterization of fungal diseases of ornamental fishes in Iran. Such information is also important for the same diseases in cultured fishes and fisheries management.

The risks of fungal infection in ornamental fishes increase due to poor aquarium management. Also, the basic health management practices could be simply

unnoticed due to lack of expert personals. In order to decrease the chance of spreading fungal infection in the native fish species, control on the import of diseased fish into the country is urgently required. This is the first reported case of fungal infection caused by *Achlya* spp. in Oscar (*Astronotus ocellatus*) in Iran.

Acknowledgments

This research was part of an investigation on the infectious diseases of aquarium fishes in Ahvaz, Iran. Financial support of Research Deputy of Shahid Chamran University of Ahvaz, Ahvaz, Iran is appreciated.

Conflict of interest

The authors declare that there is no conflict of interest.

References

1. Roberts RJ. Fish pathology. 4th ed. London, UK: Wiley-Blackwell 2012; 383-395.
2. Haroon F, Iqbal Z, Pervaiz K, et al. Incidence of fungal infection of freshwater ornamental fish in Pakistan. *Int J Agri Biol* 2014; 16 (2): 411-416.
3. Sosa ER, Landsberg JH, Kiryu Y, et al. Pathogenicity studies with the fungi *Aphanomyces invadans*, *Achlya bisexualis*, and *Phialemonium dimorphosporum*: induction of skin ulcers in striped mullet. *J Aquat Anim Health* 2007; 19 (1): 41-48.
4. Chauhan R, Lone S, Tabsum HG. Mycotic studies of some freshwater fishes with emphasis on *Achlya* spp. *Int J Fish Aquac* 2013; 3(4): 165-169.
5. Shahbazian N, Ebrahimzadeh Mousavi HA, Soltani M, et al. Fungal contamination in rainbow trout eggs in Kermanshah province propagations with emphasis on Saprolegniaceae. *Iran J Fish Sci* 2010; 9 (1):151-160.
6. Fadaeifard F, Bahrami H, Rahimi E, et al. Freshwater fungi isolated from eggs and broodstocks with an emphasis on Saprolegnia in rainbow trout farms in the west of Iran. *Afr J Microbiol Res* 2011;4(22):3647-3651.
7. Chauhan R, Kaur P, Sharma S. Pathogenicity of some species of *Achlya* and Saprolegnia on Indian Major carps viz. *Catla catla*, *Cirrihinus mrigala* and *Labeo rohita*. *J Environ Sci Comp Sci Eng Technol* 2012; 1 (3): 422-428.
8. Froese R, Pauly D. *Astronotus ocellatus*, Oscar. US Fish and Wildlife Service. Available at: <https://www.fws.gov>. Accessed July 20, 2018.
9. Iqbal Z, Noreen H. Fungal infection in an imported ornamental fish Fantail, (*Carassius auratus* L.). *Biologia* 2015; 61 (1): 69-73.
10. Buller NB. Bacteria and fungi from fish and other aquatic animals: A practical identification manual. 2nd ed. Boston, USA: CABI 2014; 664- 670.
11. Holgerson MA, Post DM, Skelly DK. Reconciling the role of terrestrial leaves in pond food webs: A whole-ecosystem experiment. *Ecology* 2016; 97 (7): 1771-1782.
12. Kitancharoen N, Hatai K, Ogihara R, et al. A new record of *Achlya klebsiana* from snakehead, *Channa striatus*, with fungal infection in Myanmar. *Mycoscience* 1995; 36(2): 235-238.
13. Saraswathi R, Sumithra P, Sivakami R. Studies on the effect of *Achlya* species in various fish species cultured in different freshwater systems of Pudukkottai District, Tamilnadu, India. *Int J Curr Microbiol Appl Sci* 2015; 4(12), 670-674.