

## Effects of L-carnitine and betamethasone on ischemia-reperfusion injuries and sperm parameters following testicular torsion in a rat model

Siamak Kazemi-Darabadi<sup>1\*</sup>, Reza Asadpour<sup>1</sup>, Amir Ali Shahbazfar<sup>2</sup>, Sajjad Alizadeh<sup>3</sup>

<sup>1</sup> Department of Clinical Sciences, Faculty of Veterinary Medicine, University of Tabriz, Tabriz, Iran; <sup>2</sup> Department of Pathobiology, Faculty of Veterinary Medicine, University of Tabriz, Tabriz, Iran; <sup>3</sup> Graduate Student, Faculty of Veterinary Medicine, University of Tabriz, Tabriz, Iran.

Article Info	Abstract
<p><b>Article history:</b></p> <p>Received: 04 November 2017 Accepted: 09 January 2018 Available online: 15 June 2019</p> <p><b>Key words:</b></p> <p>Betamethasone Carnitine Reperfusion injury Spermatic cord torsion Sperm characteristics</p>	<p>Testicular torsion is a consequence of spermatic cord twisting which causes progressive damage to the structure of the testis and reduces sperm quality and usually results in infertility. In the present study, with the assumption of the protective effects of L-carnitine and betamethasone against ischemia-reperfusion (IR) injuries, their effects on twisted testicles were evaluated and compared. Twenty Wistar rats were randomly divided into four groups and used in this study. Except for the Sham (S) group, testicular IR was induced surgically in three other groups, including Control (C), Betamethasone (BM), and L-carnitine (LC) groups. Betamethasone and L-carnitine were injected before detorsion in the BM and LC groups, respectively. After twelve hours of reperfusion, the testicles were detached, and prepared for sperm parameters evaluation such as sperm count, motility, viability, morphology, and chromatin quality, and histopathologic evaluations, including mean seminiferous tubular diameter (MSTD), germinal epithelial cell thickness (GECT), and Johnsen's mean testicular biopsy scoring (MTBS). The MSTD, GECT, and healthy sperms in the C group were significantly lower than the other groups, while the BM and LC groups were significantly different from others in MTBS. The number of sperms and sperm motility in the BM group was significantly higher than the C group. Sperm viability in the BM and LC groups were significantly higher than the C group. The results of this study showed that both L-carnitine and betamethasone similarly can be effective in treating testicular IR injuries.</p> <p>© 2019 Urmia University. All rights reserved.</p>

### اثرات ال-کارنیتین و بتامتازون بر جراحات ایسکمی-رپرفیوژن و پارامترهای اسپرمی به دنبال چرخش بیضه در مدل رت

#### چکیده

چرخش بیضه پیامد پیچ خوردگی طناب اسپرماتیک است که سبب وارد آمدن آسیب پیش رونده به ساختار بیضه و کاهش کیفیت اسپرم می شود و معمولاً منجر به ناباروری می گردد. در این مطالعه، با فرض بر اثرات محافظتی ال-کارنیتین و بتامتازون بر جراحات ایسکمی-رپرفیوژن، اثرات آن‌ها بر بیضه‌های پیچ‌خورده ارزیابی و مقایسه شدند. این مطالعه بر روی ۲۰ رت ویستار در چهار گروه انجام گرفت. به جز گروه شم، در سه گروه دیگر شامل گروه‌های کنترل، بتامتازون و ال-کارنیتین، ایسکمی رپرفیوژن بیضه ایجاد شد. بتامتازون و ال-کارنیتین پیش از اصلاح پیچ خوردگی به گروه‌های مربوطه تزریق شدند. پس از دوازده ساعت رپرفیوژن، بیضه‌ها جدا شدند و برای ارزیابی پارامترهای اسپرمی از جمله تعداد اسپرم، تحرک، زنده‌مانی، مورفولوژی و کیفیت کروماتین و نیز ارزیابی‌های هیستوپاتولوژیک شامل میانگین قطر لوله‌های اسپرم‌ساز، ضخامت یاخته‌های زایگر اپیتلیال و شاخص میانگین درجه‌بندی بیوسی بیضه به روش جانسون، آماده‌سازی شدند. میانگین قطر لوله‌های اسپرم‌ساز، ضخامت یاخته‌های زایگر اپیتلیال و درصد اسپرم‌های سالم در گروه کنترل به‌طور معناداری کمتر از گروه‌های دیگر بود. درحالی که گروه‌های بتامتازون و ال-کارنیتین از نظر میانگین درجه‌بندی بیوسی بیضه با دو گروه دیگر تفاوت معناداری داشتند. تعداد و تحرک اسپرم‌ها در گروه بتامتازون به‌صورت معناداری بیشتر از گروه کنترل بود. زنده‌مانی اسپرم در گروه‌های بتامتازون و ال-کارنیتین نیز به‌طور معناداری بالاتر از گروه کنترل بود. نتایج این مطالعه نشان داد که ال-کارنیتین و بتامتازون به‌صورت مشابهی می‌توانند در درمان جراحات ایسکمی-رپرفیوژن بیضه مؤثر باشند.

**واژه‌های کلیدی:** بتامتازون، پیچ خوردگی طناب اسپرماتیک، جراحی رپرفیوژن، خصوصیات اسپرم، کارنیتین

#### \*Correspondence:

Siamak Kazemi-Darabadi. DVM, DVSc  
Department of Clinical Sciences, Faculty of Veterinary Medicine, University of Tabriz, Tabriz, Iran.  
E-mail: s.kazemi@tabrizu.ac.ir



This work is licensed under a Creative Commons Attribution-NonCommercial 4.0 International License which allows users to read, copy, distribute and make derivative works for non-commercial purposes from the material, as long as the author of the original work is cited properly.

## Introduction

Testicular torsion arises from spermatic cord twisting and is an emergency condition. It is essential to surgically reduce torsion and treat acute ischemia. Nonetheless, reperfusion injuries may be resulted after surgical correction of testes due to complex molecular signals which cause progressive damage to the function and structure of the testis.<sup>1</sup> This syndrome usually results in infertility of ipsilateral or contralateral testes. The mechanism of cellular injuries is not completely recognized yet.<sup>2</sup>

Infertility caused by testicular torsion is a consequence of the imbalance between the revival of oxygen supply and mitochondrial respiratory function, resulting in the excessive production of superoxide in mitochondria. Therefore, free oxygen radical scavengers are necessary to reduce oxidative stress and testicular tissue damage.<sup>3</sup> Pre-treatment of testicular torsion using antioxidants and enzymes like superoxide dismutase, catalase, melatonin, selenium, caffeic acid, and N-acetylcysteine have prevented testicular ischemia-reperfusion (IR) injuries.<sup>2</sup> For instance, the effects of melatonin on spermatogenesis and IR injuries have been evaluated and its antioxidant effect in preventing IR injuries has been documented.<sup>4</sup>

Ibuprofen which is a non-steroidal anti-inflammatory drug also shows such effect.<sup>2</sup> Similarly, Protective effects of erythropoietin<sup>5</sup> and vascular endothelial growth factor on testicular IR injury have been reported.<sup>6</sup> In previous studies, the effects of N-acetylcysteine and nitric oxide on the protection of testes from IR injuries had been documented.<sup>7,8</sup> Betamethasone is a well-known corticosteroid which has been used for the variety of purposes because of its immunosuppressive characteristics due to inhibition of cytokines.<sup>9</sup> Corticosteroids have beneficial effects against IR injuries in several organs such as the brain, kidney, and liver.<sup>10-12</sup>

L-carnitine is a natural antioxidant, which has an important role in the utilization of long chained fatty acids for energy production. It has numerous biological activities including anti-inflammatory, anti-apoptotic, cardio-protective, and gastroprotective properties. Furthermore, it involves in sperm metabolism, maturity, mobility, and spermatogenesis by providing energy.<sup>13</sup> L-carnitine shows an anti-apoptosis effect in irradiated testes.<sup>14</sup> Besides, there is a report regarding the positive effects of corticosteroids on spermatogenesis in testes suffering from IR.<sup>15</sup> These anti-inflammatory agents prevent the free radical formation and have a protective effect on the cell wall. They also prevent the increase of vessels permeability.<sup>16</sup>

Considering the above-mentioned reports, we hypothesized that both the L-carnitine and betamethasone can prevent testicular IR injuries. Therefore, in the present study, the effects of L-carnitine and betamethasone on testes with IR injuries and sperm parameters were evaluated and compared.

## Materials and Methods

**Ethical consideration.** This study was approved by the Ethics Committee for Animal Investigations of the Faculty of Veterinary Medicine, University of Tabriz (code D/43/7353) in accordance with the Declaration of Helsinki. All invasive interventions involving the rats were done only after proper sedation and anesthesia.

**Study design.** Twenty male adult Wistar albino rats (eight weeks of age and weighing  $300.00 \pm 10.00$  g) were used. The animals were kept at  $22.00$  °C with a 12 hr light/darkness cycles. They had free access to tap water and commercial rat pellets. A period of one week was allowed the animals to acclimatize prior to surgery. A completely randomized design was employed in this experiment. The rats were numbered and divided into four groups of five, using Microsoft Office Excel random number table (version 12.0, Microsoft Corp., Redmond, USA). In the Sham (S) group, scrotal incision and suturing were done. In the Control (C) group, testicular IR in rats was induced without any treatment. In the Betamethasone (BM) group, IR was induced in testicles and BM (0.40%, Sina Darou, Tehran, Iran) was injected. Finally, in the L-carnitine (LC) group testicular IR was induced and L-carnitine hydrochloride (Sigma Chemical Co., Steinheim, Germany) injection was performed as described below. One gram of L-carnitine was dissolved in 5.00 mL of normal saline solution to prepare 20.00% solution.<sup>17</sup>

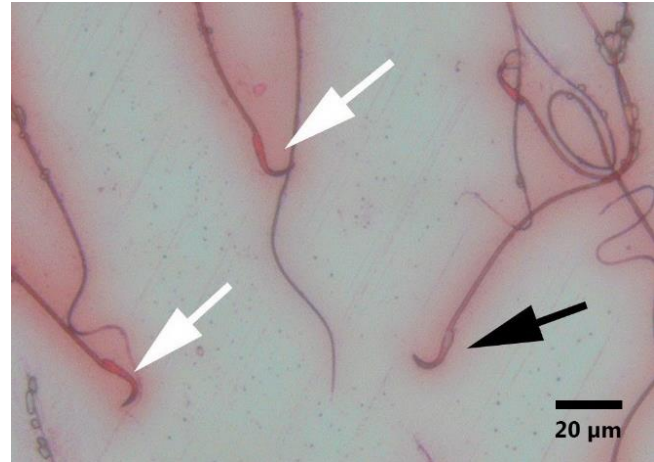
**Ischemia-reperfusion induction.** The operation was performed under general anesthesia by intraperitoneal injection of xylazine (10 mg kg<sup>-1</sup>, Alfasan, Woerden, the Netherlands) and ketamine hydrochloride (90 mg kg<sup>-1</sup>, Rotexmedice, Trittau, Germany) combination.<sup>18</sup> After aseptic preparation of the scrotal area, the right testis was approached through a midline scrotal incision. In the S group rats, incisions were made in the tunica vaginalis of the right testes, then a suture was placed through the tunica albuginea using 6-0 monofilament polyamide suture (Supa, Tehran, Iran) and the scrotum was closed with the same suture material. The right testes of the other groups were twisted 720° in clockwise direction and fixed at the position by suturing the tunica albuginea to the surrounding tissues using the 6-0 monofilament polyamide suture (Supa).<sup>18</sup> Afterward, the scrotum was closed in a simple continuous pattern with the aforementioned suture material. Immediately after surgery, betamethasone (0.10 mg kg<sup>-1</sup>)<sup>19,20</sup> and L-carnitine (500 mg kg<sup>-1</sup>)<sup>13</sup> were injected intraperitoneally into the animals of the BM and LC groups, respectively. Groups S and C were received normal saline solution intraperitoneally. Six hours after ischemia, the scrotum was opened again and the right testis was untwisted after removing the stay sutures, then the scrotum was closed as previously described. All the rats tolerated anesthesia satisfactorily and recovered from the anesthesia safely.

**Histopathologic evaluations.** The animals were anesthetized again 12 hr after detorsion,<sup>21</sup> the testicles were detached, and after separation of the epididymis for sperm parameter evaluations, the remains of the testicles were fixed in 10% neutral buffered formalin solution. The rats were euthanized after biopsy with intraperitoneal overdose of thiopental sodium (50 mg kg<sup>-1</sup>; VUAB Pharma Inc., Roztoky, Czech Republic). Sections with 4.00 µm thickness were prepared from the upper, middle, and lower portions of each testicle and they were stained using hematoxylin-eosin (H&E) method. Mean seminiferous tubular diameter (MSTD) was measured under the light microscope with a graticule eyepiece lens. Ten seminiferous tubules were evaluated and the mean diameter of seminiferous tubules was determined in micrometers.<sup>6</sup> Germinal epithelial cell thickness (GECT) was recorded by counting the number of epithelial cells from the basement membrane to the lumen of tubes. Finally, the assessment of spermatogenesis was performed based on Johnsen's mean testicular biopsy scoring (MTBS) criteria, which has ten scores based on the epithelial maturity as follow: 10- Complete spermatogenesis and full organization of the tubules, 9- Many spermatozoa along with disorganized epithelium, 8- A few spermatozoa, 7- Many spermatids with no spermatozoa, 6- Few spermatids, 5- Many spermatocytes without any spermatid, 4- Few spermatocytes, 3- Only spermatogonia, 2- Absence of germ cells, but presence of Sertoli cells, and 1- No epithelial and Sertoli cells in seminiferous tubules.<sup>22</sup>

**Evaluation of sperm parameters.** Evaluation of sperm parameters was performed based on the World Health Organization's instructions.<sup>23</sup> For sperm counting, the epididymides were transferred to the plates containing 5.00 mL of Hams F10 growth medium and they were cut into small pieces to facilitate emerging of spermatozoa. After 10 min, 1.00 mL of this fluid was diluted with 9.00 mL of 2.00% formalin solution. Sperm counting was performed using a Neubauer hemocytometer and then the number of spermatozoa in each mL was calculated.

The epididymis specimens were evaluated on wet slides under the light microscope for sperm motility within 30 min after sampling. About 100 spermatozoa were counted in each slide and this procedure was repeated. The sperms were classified as progressive mobile, non-progressive mobile, and non-mobile.

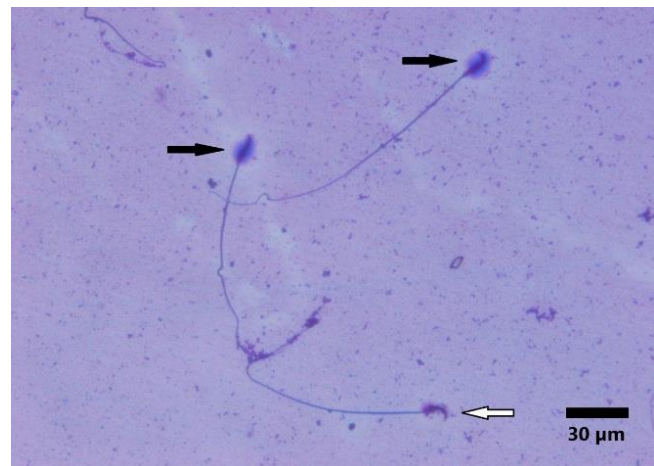
Eosin staining was performed for the sperm viability evaluations using Diff-Quick rapid sperm staining kit (Avicenna Research Institute, Tehran, Iran). Within 30 min after sampling, 5.00 µL of fluid was mixed with 5.00 µL of 0.50% isotonic eosin solution on slides. After 30 sec incubation at 37 °C, thin spreads of sperm samples were prepared and evaluated under the light microscope. The number of dead sperms (red or dark pink heads) and live sperms (white or pale pink heads) was recorded and data was presented as percentage (Fig. 1).



**Fig. 1.** Evaluation of sperm viability on eosin-stained slides. Dead sperms have red or dark pink heads (white arrows) and live sperms have white or pale pink heads (black arrow) in this staining method.

Eosin stained slides were used to assess sperm morphology. In each sample, 100 spermatozoa were evaluated under the microscope and the percentage of malformed sperms were recorded.

Chromatin quality was evaluated by the Sperm DNA Fragmentation Assay kit (Avicenna Research Institute, Tehran, Iran), in which sperms with different halos were graded. The full halo around spermatozoa indicates normal DNA, and the absence of a halo indicates damaged DNA (Fig. 2). Briefly, 50 µL of the diluted semen sample was added to 100 µL of incubated 0.70% agarose gel and mixed. The mixture (15 µL) was placed onto a super-coated slide, covered with a coverslip, and the slides were kept for 5 min at 4 °C in a refrigerator to create a microgel with the contained spermatozoa. After removing the coverslips, a few drops of solution A were added to the slide, and it was incubated for 7 min.



**Fig. 2.** Evaluation of sperm chromatin quality by sperm DNA fragmentation assay. The full halo around spermatozoa (black arrows) indicates normal DNA and lack of halo (white arrow) indicates damaged DNA.

Afterward, slides were incubated for 15 min in solution B, rinsed with distilled water and dehydrated for 2 min in increasing concentrations of ethanol (70.00%, 90.00%, and 100%). After air-drying, the slides were stained sequentially with solution C for 75 sec, solution D for 3 min, and solution E for 2 min, then rinsed and allowed to dry at room temperature.

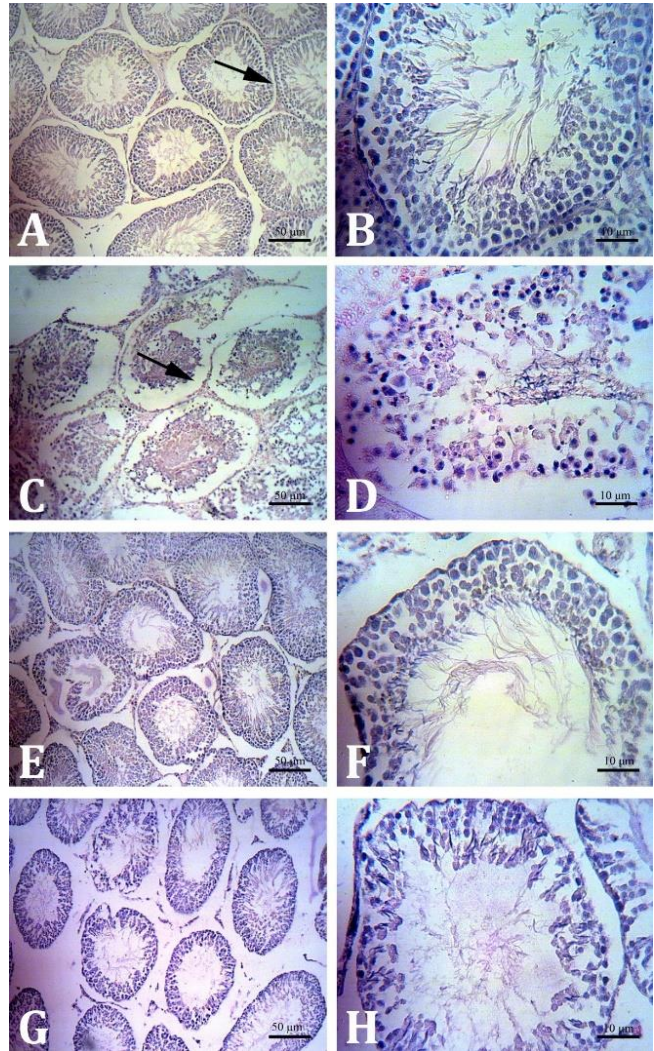
**Statistical analyses.** Statistical analyses were performed using Minitab (version 16.2.0; Minitab Inc., Boston, USA). All the results were presented as the mean  $\pm$  standard deviation (SD). Because of the number of animals in each group, the Kruskal-Wallis test was employed to analyze parameters, and comparisons between groups were performed by Mann-Whitney U-tests. The results were considered significantly different when the *p* value was less than 0.05.

## Results

**Histopathology.** The germinal epithelium of most seminiferous tubules was detached from the basement membrane and there were not any spermatozoa in the C group slides. Hemorrhage, hyperemia, and swelling of Sertoli cells (cells with round corners and bulged cell wall) were also visible and the tubules were highly edematous as a result of inflammation due to the intracellular fluid infiltration into the interstitial space in this group. Tubular swelling (enhancement in tubular diameter) was diminished in the BM group and some tubules had disassembled epithelium. The tubular swelling was also lesser in the LC group compared to the C group, but it was greater than the BM group. Most of the tubules had also disassembled epithelium (Fig. 3). Germinal cells detachment was not observed in the S group. MSTD and GECT values in the C group were significantly greater and lesser than the other three groups, respectively ( $p = 0.005$  and  $p = 0.02$ ). But the difference of the latter in the LC group compared to the S group was also significant. Based on Johnsen's MTBS criteria, the BM and LC groups had a significant difference ( $p = 0.01$ ) with the other two groups (Fig. 4).

**Sperm parameters.** The sperm count, progressive motility, and total motility in the LC group were significantly greater than the C group but lesser than the S group. The BM and LC groups had significantly less immobile sperms than the C group, and still more than the S group (Table 1).

Also, the percentage of viable sperms, as well as healthy sperms with normal morphology in the C group, was significantly less than the other three groups (Table 1).



**Fig. 3.** Histological sections of testicular tissue of the examined rats. **A and B)** Normal structure of seminiferous tubules in the Sham group. The germinal epithelium is attached to the basement membrane (arrow) and the epithelium has normal cellular layers. **C and D)** The germinal epithelium in the Control group has detached from the basement membrane in most tubules (arrow). There is not any sperm and the tubules are swollen. **E and F)** The swelling of tubules has been diminished in the Betamethasone group. **G and H)** The tubular swelling in the L-carnitine group is less than the Control group but still greater than the Betamethasone group, (H&E).

**Table 1.** Sperm parameters (%) in four experimental groups after ischemia-reperfusion. Data are presented as mean  $\pm$  SD.

Group	Sperm No. ( $\times 10^6$ )	Motility				Total motility	Viability	Healthy sperms
		Immobile	Progressive	Non-progressive				
Sham	19.40 $\pm$ 1.90 <sup>a</sup>	45.00 $\pm$ 3.00 <sup>a</sup>	40.50 $\pm$ 3.00 <sup>a</sup>	14.50 $\pm$ 3.00 <sup>a</sup>	55.00 $\pm$ 3.00 <sup>a</sup>	45.70 $\pm$ 0.90 <sup>a</sup>	61.90 $\pm$ 6.70 <sup>a</sup>	
Control	7.70 $\pm$ 1.50 <sup>b</sup>	97.50 $\pm$ 0.30 <sup>b</sup>	0.50 $\pm$ 0.30 <sup>b</sup>	2.00 $\pm$ 0.30 <sup>b</sup>	2.50 $\pm$ 0.30 <sup>b</sup>	2.80 $\pm$ 2.40 <sup>b</sup>	28.30 $\pm$ 5.20 <sup>b</sup>	
Betamethasone	12.20 $\pm$ 1.30 <sup>bc</sup>	80.00 $\pm$ 2.00 <sup>c</sup>	7.50 $\pm$ 2.00 <sup>c</sup>	12.50 $\pm$ 2.00 <sup>c</sup>	20.00 $\pm$ 2.00 <sup>c</sup>	38.50 $\pm$ 5.30 <sup>a</sup>	50.10 $\pm$ 3.20 <sup>a</sup>	
L-Carnitine	16.70 $\pm$ 1.90 <sup>c</sup>	75.00 $\pm$ 3.00 <sup>c</sup>	17.50 $\pm$ 3.00 <sup>c</sup>	6.50 $\pm$ 3.00 <sup>bc</sup>	24.00 $\pm$ 3.00 <sup>c</sup>	44.70 $\pm$ 9.40 <sup>a</sup>	52.90 $\pm$ 10.20 <sup>a</sup>	

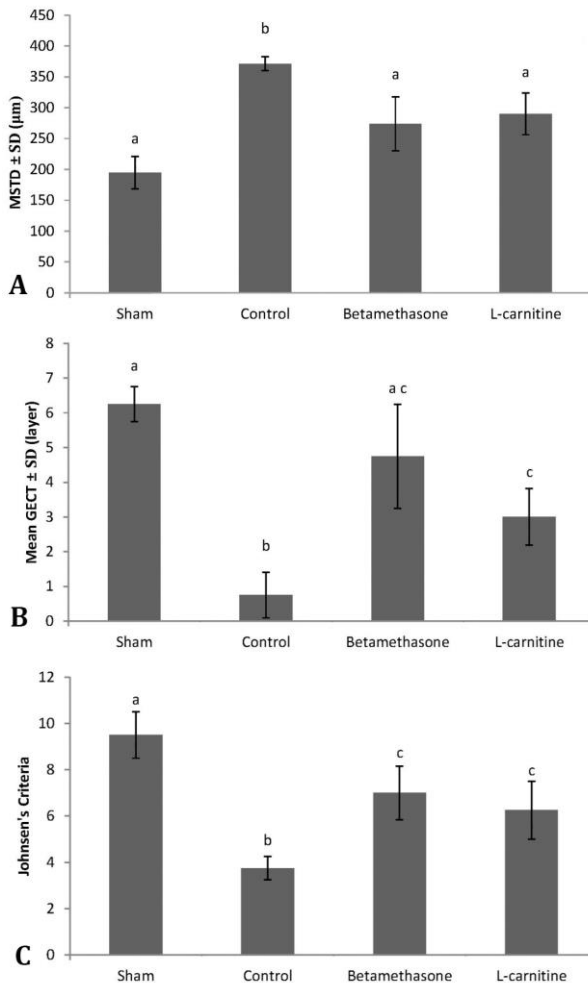
Different letters in each column indicate statistically significant differences ( $p < 0.05$ ).

Finally, the number of sperms with a large halo in the BM and LC groups differed significantly from the S and C groups (Table 2).

**Table 2.** Chromatin quality in four experimental groups after ischemia-reperfusion. Data are presented as mean  $\pm$  SD.

Group	Large halo (%)	Without halo (%)
Sham	27.00 $\pm$ 3.00 <sup>a</sup>	45.00 $\pm$ 3.00 <sup>a</sup>
Control	8.80 $\pm$ 4.00 <sup>b</sup>	73.00 $\pm$ 2.00 <sup>b</sup>
Betamethasone	14.00 $\pm$ 2.00 <sup>c</sup>	64.00 $\pm$ 2.00 <sup>c</sup>
L-Carnitine	17.00 $\pm$ 5.00 <sup>c</sup>	55.00 $\pm$ 4.00 <sup>c</sup>

Different letters in each column indicate statistically significant differences ( $p < 0.05$ ).



**Fig. 4.** **A)** Mean seminiferous tubular diameter (MSTD) values ( $\mu\text{m}$ ) measured in the experimental groups; **B)** Germinal epithelial cell thickness (GECT) values recorded based on the number of cellular layers; **C)** Johnsen's mean testicular biopsy scoring (MTBS) values calculated in the experimental groups. Different letters indicate a significant difference among the groups ( $p < 0.05$ ).

## Discussion

Ischemia-reperfusion (IR) injuries are responsible for infertility in males.<sup>2</sup> In the present study, presuming that

both betamethasone and L-carnitine have a protective effect against testicular IR injuries, their effects on the IR injuries of the rats' testes were compared by histopathology and sperm parameters evaluations.

At least 1-hour of ischemia in testis is necessary to develop testicular damage in rats.<sup>24</sup> Therefore, a 6-hour period of induced ischemia in the testis of rats in the present study seems to be sufficient for investigating the testicular damage. Ischemia alone leads to xanthine oxidase activation, which produces superoxide radicals. Moreover, leukocytes migrate into the affected tissue during ischemia, which will produce reactive oxygen species (ROS) in the reperfusion period.<sup>25</sup> Following detorsion of the twisted testis, some alterations in the biochemistry and morphology of testicular tissue may occur. Reperfusion increases the apoptosis and tissue damage.<sup>26</sup> A membrane-bound enzyme complex NADPH oxidase is suggested as an important source of ROS following IR injury in testis.<sup>27</sup> Oxidative stress resulting from ROS has a role in sperm damage during reperfusion.<sup>28</sup> Cellular proteins, membrane lipids, and DNA undergo oxidation as a result of ROS activity.<sup>29</sup>

L-carnitine mainly involves in fat metabolism in the body tissues. It helps in transporting long-chained fatty acids inside mitochondria and subsequent energy production.<sup>30,31</sup> It has been suggested that L-carnitine has a key role in sperm metabolism, as well as production, maturity, and motility of spermatozoa<sup>32</sup> that is consistent with our results, in which L-carnitine could significantly increase sperm counts and motility. Other beneficial effects such as anti-inflammatory, antioxidant, and anti-apoptotic activities have also been attributed to L-carnitine.<sup>33-35</sup> Anti-apoptotic properties of carnitine favored its usage to prevent cell death due to IR injuries to various organs.<sup>36</sup> In spite of various mechanisms of action attributed to carnitine in increasing the sperm counts and quality, in a review article about the role of L-carnitine in the male reproductive system, it was concluded that this latter property (i.e. anti-apoptotic) is the major mechanism in preventing testicular germ cell injuries.<sup>30</sup> Therefore, this substance is used in the treatment of infertility in males.<sup>37</sup> Several researchers have emphasized on protective activity of L-carnitine against DNA damage, as well as oxidants reduction.<sup>38-40</sup> Furthermore, carnitine can enhance sperm parameters in epididymis including motility, maturity, and number. Naturally, epididymis has a high concentration of carnitine, which enables sperm respiration and motility by enhancing oxidation process. Because of this property, this agent is used to increase sperm motility in asthenozoospermic patients.<sup>30,41</sup> Deliktas *et al.* reported that L-carnitine reduces seminiferous tubules' edema, and disturbances in the germinal epithelium, basement membrane, and tubules in rat testicles encountering IR injuries,<sup>42</sup> which were in agreement with the results in the present study.

Similarly, in a research work by Mogilner and coworkers, they demonstrated that reduction of seminiferous tubules' edema and improvement in the germinal epithelium, basement membrane, tubules structure, and spermatogenesis can be expected after injecting dexamethasone to the rats suffering from testicular IR injuries.<sup>15</sup> Corticosteroids have anti-inflammatory, immunosuppressive, pro- and anti-apoptotic (mostly apoptotic in the reproductive system), and antiproliferative effects.<sup>43,44</sup> They are acting as cytoprotective agents in different tissues. Hammer *et al.* reported that glucocorticoids protect fibroblast cells because of their antiapoptotic effect, despite suppressing their proliferation. This may be contributed to decreasing NF- $\kappa$ B activation, which can encourage apoptosis.<sup>45</sup> However, there is a report showing that dexamethasone cannot reduce apoptosis in ischemic testicles.<sup>15</sup> Anyways, corticosteroids reduce ROS formation through both inhibition of phospholipase A2, and leukocyte activity recuperation.<sup>16</sup> The results of a study by Mertoglu *et al.* showed that methylprednisolone can reduce protein oxidation and lipid peroxidation in rat testicular tissue following IR.<sup>46</sup> Hence, this mechanism of action is more likely to be involved in preventing testicular IR injuries.

Considering some similarity in the mechanism of action of corticosteroids and L-carnitine including antiapoptotic and antioxidant properties, the results of this study can be justified. In the present study, both betamethasone and L-carnitine could improve the sperm viability, and preserve more healthy cells compared to the Control group. Although, the differences in these parameters and also the counts, total motility, and chromatin quality of the sperms between rats treated with these two agents were not significant. Tubular swelling in the L-carnitine group was greater than the Betamethasone group, which can be attributed to the anti-inflammatory nature of corticosteroids.

Additionally, spermatogenesis assessed with Johnsen's criteria in both groups BM and LC was significantly better than the C group, similar to findings of Dokmeci and coworkers.<sup>12</sup> However, MSTD was insignificantly lower in the IR group in their study, which seems to be on the contrary to our results. In fact, IR injury causes interstitial edema and those researchers corroborated this finding. Therefore, the increase in MSTD in our study may be due to this mechanism. GECT was assessed for a clear description of the thickness of the seminiferous tubules. A thicker germinal epithelium in IR injury could be the sign of an effective intervention.<sup>47</sup> In this regard, in the L-carnitine and betamethasone treated groups, the thickness of the seminiferous tubules were significantly higher than those in the Control group, indicating the effectiveness of betamethasone as well as L-carnitine in protecting the testicular tissue. The difference between these two groups was also insignificant.

The results of this study revealed the protective effects of L-carnitine and betamethasone on short-term reperfusion injuries of rat testicles. The effects of these agents on long-term injuries need to be further studied.

In conclusion, the results of this study showed that L-carnitine and betamethasone can have beneficial effects on testicular IR injuries of rats, both in preventing testicular tissue damage, and improving sperm characteristics, including sperm counts, mobility, viability, healthy sperm percentage, and chromatin quality, despite they may act through different mechanisms of action. Although, in betamethasone treated rats better improvement in tissue characteristics was observed and, in L-carnitine treated rats enhancing sperm parameters was superior to betamethasone treated rats.

### Acknowledgements

The authors would like to express their gratitude to Vice-Chancellor for Research and Technology, University of Tabriz, for funding this research.

### Conflict of interest

The authors declare that they have no conflict of interest.

### References

1. Minutoli L, Irrera N, Squadrito F, et al. Effects of ischaemic post conditioning on the early and late testicular damage after experimental testis ischaemia-reperfusion. *Andrology* 2013; 2(1): 76-82.
2. Dokmeci D, Kanter M, Inan M, et al. Protective effects of ibuprofen on testicular torsion/detorsion-induced ischemia/reperfusion injury in rats. *Arch Toxicol* 2007; 81(9): 655-663.
3. Kim HJ, Lee JW, Hwang BR, et al. Protective effect of pterostilbene on testicular ischemia/reperfusion injury in rats. *J Pediatr Surg* 2016; 51(7):1192-1196.
4. Yurtcu M, Abasiyanik A, Avunduk MC, et al. Effects of melatonin on spermatogenesis and testicular ischemia-reperfusion injury after unilateral testicular torsion-detorsion. *J Pediatr Surg* 2008; 43(10): 1873-1878.
5. Ergur BU, Kiray M, Pekcetin C, et al. Protective effect of erythropoietin pretreatment in testicular ischemia-reperfusion injury in rats. *J Pediatr Surg* 2008; 43(4): 722-728.
6. Tunçkiran A, Cayan S, Bozlu M, et al. Protective effect of vascular endothelial growth factor on histologic changes in testicular ischemia-reperfusion injury. *Fertil Steril* 2005; 84(2): 468-473.
7. Aktas BK, Bulut S, Bulut S, et al. The effects of N-acetylcysteine on testicular damage in experimental testicular ischemia/reperfusion injury. *Pediatr Surg Int* 2010; 26(3): 293-298.

8. Ozokutan BH, Kucukaydin M, Muhtaroglu S, et al. The role of nitric oxide in testicular ischemia-reperfusion injury. *J Pediatr Surg* 2000; 35(1): 101-103.
9. Auphan N, DiDonato JA, Rosette C, et al. Immunosuppression by glucocorticoids: Inhibition of NF-kappa B activity through induction of I kappa B synthesis. *Science* 1995; 270(5234): 286-290
10. Wang M, Shen F, Shi LH, et al. Protective effect of prednisolone on ischemia-induced liver injury in rats. *World J Gastroenterol* 2008; 14(27): 4332-4337
11. Hasturk AE, Harman F, Arca T, et al. Neuroprotective effect of magnesium sulfate and dexamethasone on intrauterine ischemia in the fetal rat brain: ultrastructural evaluation. *Turk Neurosurg* 2013; 23(5): 666-671.
12. Takahira R, Yonemura K, Fujise Y, et al. Dexamethasone attenuates neutrophil infiltration in the rat kidney in ischemia/reperfusion injury: the possible role of nitroxyl. *Free Radic Biol Med* 2001; 31(6): 809-815.
13. Dokmeci D, Inan M, Basaran UN, et al. Protective effect of L-carnitine on testicular ischaemia-reperfusion injury in rats. *Cell Biochem Funct* 2007; 25(6): 611-618.
14. Kanter M, Topcu-Tarladacalisir Y, Parlar S. Antiapoptotic effect of L-carnitine on testicular irradiation in rats. *J Mol Histol* 2010; 41(2-3): 121-128.
15. Mogilner JG, Elenberg Y, Lurie M, et al. Effect of dexamethasone on germ cell apoptosis in the contralateral testis after testicular ischemia-reperfusion injury in the rat. *Fertil Steril* 2006; 85(1): 1111-1117
16. Yurtcu M, Abasiyanik A, Bicer S, et al. Efficacy of antioxidant treatment in the prevention of testicular atrophy in experimental testicular torsion. *J Pediatr Surg* 2009; 44(9): 1754-1758.
17. Coskun N, Hatipoglu MT, Ozogul C, et al. The protective effects of acetyl L-carnitine on testis gonadotoxicity induced by cisplatin in rats. *Balkan Med J* 2013; 30(2): 235-241.
18. Kanter M. Protective effects of melatonin on testicular torsion/detorsion-induced ischemia-reperfusion injury in rats. *Exp Mol Pathol* 2010; 89(3): 314-320
19. Ozturk A, Baltaci AK, Mogulkoc R, et al. The effect of prophylactic melatonin administration on reperfusion damage in experimental testis ischemia-reperfusion. *Neuro Endocrinol Lett* 2003; 24(3-4): 170-172.
20. Akpınar S, Hersekli MA, Demirors H, et al. Effects of methylprednisolone and betamethasone injections on the rotator cuff: An experimental study in rats. *Adv Ther* 2002; 19(4): 194-201.
21. Scheepens A, Waarenburg M, Hove D, et al. A single course of prenatal betamethasone in the rat alters postnatal brain cell proliferation but not apoptosis. *J Physiol* 2003; 552(1): 163-175.
22. Johnsen SG. Testicular biopsy score count—a method for registration of spermatogenesis in human testes: normal values and results in 335 hypogonadal males. *Hormones*. 1970;1(1):2-25.
23. World Health Organization. Laboratory manual for the examination and processing of human semen. 5<sup>th</sup> ed. World Health Organization 2010; 11-102.
24. Turner TT, Brown KJ. Spermatic cord torsion: loss of spermatogenesis despite return of blood flow. *Biol Reprod* 1993; 49(2): 401-407.
25. Parlaktas BS, Atilgan D, Ozyurt H, et al. The biochemical effects of ischemia-reperfusion injury in the ipsilateral and contralateral testes of rats and the protective role of melatonin. *Asian J Androl* 2014; 16(2): 314-318.
26. Sekmenli T, Gunduz M, Ozturk B, et al. The effects of melatonin and colchicine on ischemia-reperfusion injury in experimental rat testicular torsion model. *J Pediatr Surg* 2017; 52(4): 582-586.
27. Sener TE, Yuksel M, Ozyilmaz-Yay N, et al. Apocynin attenuates testicular ischemia-reperfusion injury in rats. *J Pediatr Surg* 2015; 50(8): 1382-1387.
28. Agarwal A, Said TM. Oxidative stress, DNA damage and apoptosis in male infertility: a clinical approach. *BJU Int* 2005; 95(4): 503-507.
29. Camhi SL, Lee P, Choi AM. The oxidative stress response. *New Horiz* 1995; 3(2): 170-182.
30. Ng CM, Blackman MR, Wang C, et al. The role of carnitine in the male reproductive system. *Ann N Y Acad Sci* 2004; 1033: 177-188.
31. Matalliotakis I, Koumantaki Y, Evageliou A, et al. L-carnitine levels in the seminal plasma of fertile and infertile men: correlation with sperm quality. *Int J Fertil Womens Med* 2000; 45(3): 236-240.
32. Agarwal A, Said TM. Carnitine and male infertility. *Reprod Biomed Online* 2004; 8(4): 376-384.
33. Izgüt-Uysal VN, Agac A, Derin N. Effect of L-carnitine on carrageenan-induced inflammation in aged rats. *Gerontology* 2003; 49(5): 287-292.
34. Onem G, Aral E, Enli Y, et al. Neuroprotective effects of L-carnitine and vitamin E alone or in combination against. *J Surg Res* 2006; 131(1): 124-130.
35. Moretti S, Famularo G, Marcellini S, et al. L-carnitine reduces lymphocyte apoptosis and oxidant stress in HIV-1-infected subjects treated with zidovudine and didanosine. *Antioxid Redox Signal* 2002; 4(3): 391-403.
36. Ishii T, Shimpo Y, Matsuoka Y, et al. Anti-apoptotic effect of acetyl-L-carnitine and L-carnitine in primary cultured neurons. *Jpn J Pharmacol* 2000; 83(2): 119-124.
37. Lenzi A, Sgro P, Salacone P, et al. A placebo-controlled double blind randomized trial of the use of combined L-carnitine and L-acetyl-carnitine treatment in men with asthenozoospermia. *Fertil Steril* 2004; 81(6): 1578-1584.

38. Arockia Rani PJ, Panneerselvam C. Carnitine as a free radical scavenger in aging. *Exp Gerontol* 2001; 36(10): 1713-1726.
39. Cetinkaya A, Bulbuloglu E, Kantarceken B, et al. Effects of L-carnitine on oxidant/antioxidant status in acetic acid-induced colitis. *Dig Dis Sci* 2006; 51(3): 488-494.
40. Calo LA, Pagnin E, Davis PA, et al. Antioxidant effect of L-carnitine and its short chain esters: relevance for the protection from oxidative stress related cardiovascular damage. *Int J Cardiol* 2006; 107(1): 54-60.
41. Jeulin C, Lewin LM. Role of free L-carnitine and acetyl-L-carnitine in post-gonadal maturation of mammalian spermatozoa. *Hum Reprod Update* 1996; 2(2): 87-102.
42. Deliktas H, Gedik A, Nergiz Y, et al. The effect of L-carnitine on testicular ischemia-reperfusion injury due to testicular torsion in rats. *Eur J Gen Med* 2012; 9(3): 192-196.
43. Gruver-Yates A, Cidlowski JA. Tissue-specific action of glucocorticoids on apoptosis: A double-edged sword. *Cells* 2013; 2(2): 202-223.
44. Herr I, Gassler N, Friess H, et al. Regulation of differential pro- and anti-apoptotic signaling by glucocorticoids. *Apoptosis* 2007; 12(2): 271-291.
45. Hammer S, Sauer B, Spika I, et al. Glucocorticoids mediate differential anti-apoptotic effects in human fibroblasts and keratinocytes via sphingosine-1-phosphate formation. *J Cell Biochem* 2004; 91(4): 840-851.
46. Mertoglu C, Senel U, Cayli S, et al. Protective role of methylprednisolone and heparin in ischemic-reperfusion injury of the rat testicle. *Andrologia* 2016; 48(7): 737-744.
47. Taati M, Moghadasi M, Dezfoulian O, et al. Effects of ghrelin on testicular ischemia/reperfusion-induced injury. *Acta Med Iran* 2016; 54(1): 32-38.