

Case report**Fungal urinary tract infection in an infant with posterior urethral valves**

Arash Ahmadzadeh, MD^{1*}, Ehsan Valavi, MD², Ahmad Shamsizadeh, MD^{3,4}, Ali Zarei Mahmoudabadi, PhD^{3,5}, Morteza Hydari, MD⁶, Ali Ahmadzadeh, MD²

¹Resident of Department of Radiology, Shariati Hospital, Tehran University of Medical Sciences, Tehran, Iran

²Pediatric Nephrology Division, Abuzar Children's Medical Center, Ahvaz Jundishapur University of Medical Sciences, Ahvaz, Iran

³Infectious and Tropical Diseases Research Center, Ahvaz Jundishapur University of Medical Sciences, Ahvaz, Iran

⁴Pediatric Infectious Division, Abuzar Children's Medical Center, Ahvaz Jundishapur University of Medical Sciences, Ahvaz, Iran

⁵Department of Medical Mycology, Ahvaz Jundishapur University of Medical Sciences, Ahvaz, Iran

⁶Resident of Pediatrics, Abuzar Children's Medical Center, Ahvaz Jundishapur University of Medical Sciences, Ahvaz, Iran

How to cite this article:

Ahmadzadeh AR, Valavi E, Shamsizadeh A, Zarei Mahmoudabadi A, Hydari M, Ahmadzadeh A. Fungal urinary tract infection in an infant with posterior urethral valves. Jundishapur J Microbiol. 2011; 4(Supplement 1): S71-S76.

Received: October 2010

Accepted: January 2011

Abstract

Children with urinary tract abnormalities are susceptible to bacterial urinary infection (UTI); fungal infection, although rare, is reported to be increasing. Here, we describe a seven month-old male infant with posterior urethral valves who had developed both bacterial and fungal (*Candida*) urinary tract infections. Direct and culture examinations of urine sample confirmed urinary tract candidiasis. Urine culture yielded more than 3×10^4 *Candida albicans*. Fluconazole started in the dose of 4mg/kg/day, single dose daily (25mg or 1/2 tablet) for two weeks. After two weeks antifungal therapy, urine sample was negative for *C. albicans* in both direct and culture examination. We concluded that fungal infection should be considered in the children with obstructing urinary tract abnormalities because its diagnosis may be missed.

Keywords: *Candida albicans*; Posterior urethral valves; Urinary tract infection

***Address for correspondence:**

Dr. Arash Ahmadzadeh, Department of Radiology, Shariati Hospital, Tehran University of Medical Sciences, Tehran, Iran, Telefax: +98611 4433715; Email: ahmadzadeh.ar@gmail.com

Jundishapur Journal of Microbiology, School of Medicine, Ahvaz Jundishapur University of Medical Sciences, Ahvaz, Iran, Tel: +98611 3330074; Fax: +98611 3332036; URL: <http://jjm.ajums.ac.ir>; E-mail: editorial office: jjm@ajums.ac.ir

JJM. (2011); 4(Supplement 1): S71-S76.

Introduction

Fungal infections of the kidneys and urinary tract occur most commonly as part of systemic fungal infections in patients with underlying immunodeficiency, focal urinary tract infections (UTI) with obstructive lesions, or as a result of indwelling catheters [1]. The vast majority of fungal infections of the kidney and bladder result from *Candida albicans* followed by *C. glabrata* and *C. tropicalis* [2]. Prior antibiotic therapy, diabetes, urinary tract pathology and malignancy have been considered as the risk factors in urinary tract candidiasis [3]. The application of urinary tract drainage devices can also trigger the infection [3].

Most patients with candiduria are asymptomatic, and the yeasts merely represent colonization [1]. Infected patients may have dysuria, frequency, and suprapubic discomfort, but others have no symptoms. The clinical characteristics of fungal kidney infections depend on whether the disease presents acutely or insidiously. Acute infection of the kidney associated with candidemia is usually bilateral, consisting of multiple microabscesses in the cortex and medulla.

The kidney is the most common organ involved in systemic *Candida* infections. Chronic *Candida* kidney infection is characterized by a subacute to chronic course from ascending infection. Invasion of the renal parenchyma in such patients tends to involve the renal pelvis and medulla with sparing of the cortex. The kidney is usually the only organ involved and the infection tends to be unilateral. Bezoars and perinephric abscesses can occur [4]. Here, we report an infant with posterior urethral valves (PUV) and fungal infection.

Case report

A seven month old male infant was admitted in Abuzar children's medical

centre, Ahvaz, in May 2010. He was referred for further evaluation from a town where he had been hospitalized to be treated as a case of UTI for a week. He was the first child of the related couples. He was born via vaginal delivery without problem. The birth body weight was 2.7kg, length was 49cm and head circumference was 34.5cm. On physical examination, the patient's general condition was found satisfactory but he had a low-grade fever ($T < 38.5^{\circ}\text{C}$). His weight was 7kg (5th percentile), length was 62cm (5th percentile) and the head circumference was 43cm (25th percentile).

The blood pressure was 100/60 mmHg. The laboratory data were as follows: Hb 10.7 g/dl, MCV 60 μm^3 , WBC 11000/mm³ (N 52%, L 44%, M 1%, E 0.3%), serum urea 30mg/dl, serum creatinine 1.3mg/dl and serum electrolytes (Na^+ 138meq/l, K^+ 4meq/l and Cl^- 97meq mmol/l). Blood gas parameters were as pH 7.31, PCO_2 34mmHg, HCO_3^- 18meq/l. Urinalysis revealed specific gravity 1.005, protein ++, many WBCs and RBCs, positive nitrite test and many yeasts. He was treated by intravenous ceftriaxone and amikacin as a case of complicated UTI with renal insufficiency (serum creatinine 1.3mg/dl and GFR 20ml/min/1.73m²), after taking a suprapubic urine sample.

Ultrasound examination showed bilateral hydronephrosis, dilated ureters and thinned cortexes. The kidney diameters and cortexes were as follows: the right kidney 78×40×6mm and the left kidney 72×42×5mm, with increased echogenesity. The patient's urine sample was sent for analysis, routine culture and sensitivity testing. The results of the first urine culture showed *Escherichia coli* (sensitive to ceftriaxone and amikacin) and many yeast cells. Two days later, the second urine sample was obtained, showing active sediments and many yeast cells again, with no bacterial growth.

Voiding cystourethrography (VCUG) showed bilateral VUR grade V and PUVs. Dimercaptosuccinic acid (DMSA) scan revealed multiple focal hypo-activities in both kidneys, more severe at right side. Renal contours were irregular (Fig 1). On the seventh hospital day, the serum creatinine level decreased to 0.5mg/dL. The patient had still dysuria and the urine sediments were active. Therefore, fungal infection was strongly suspected and another suprapubic urine sample was taken to send to the medical mycology laboratory at Ahvaz medical school.

Yeast cells, budding cells and pseudohyphae were identifying features of positive smears. In addition, clusters of yeast cells, budding cells and pseudohyphae (*Candida* fungus ball like) were also detected in direct smears (Fig. 2). 50µl of urine sample were spread on Sabouraud dextrose agar, SDA (Merck, Germany) plate (supplement with antibacterial antibiotics) and incubated at 37°C for 24h. Urine cultures yielded more than 3×10^4 CFU/ml. Isolated *Candida* was identified as *C. albicans* based on colony morphology on CHROM Agar *Candida*, Corn meal agar with Tween 80 (1%), and germ tube production [5].

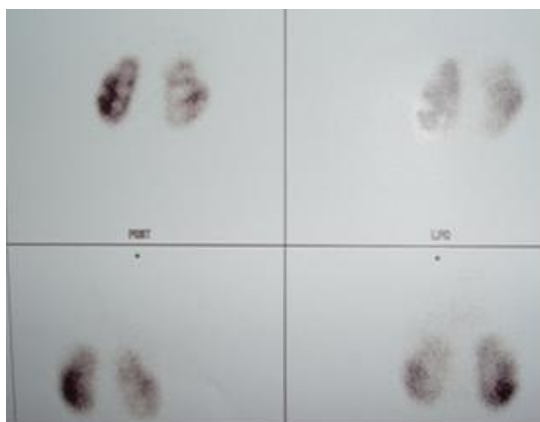


Fig. 1: Dimercaptosuccinic acid scan revealed multiple scathed areas in both kidneys. Split function: left: 57%, right: 43%

Sensitivity of *C. albicans* to antifungals was determined by SDA with disk diffusion method [6]. Several antifungals disks including fluconazole, miconazole, econazole, ketoconazole, nystatin and amphotericin B were used. Antifungal disks were provided by Mast Company (Italy). *C. albicans* was more sensitive to ketoconazole, followed by miconazole, econazole, fluconazole, nystatin and amphotericin B. Fungal infection was diagnosed by demonstration of yeast cells, budding cells and pseudohyphae in urine sample and yielded *C. albicans* in culture.

Therefore fluconazole was started in the dose of 4mg/kg/day, single dose daily (25mg or 1/2 tablet). After one week antifungal therapy, urine sample was also positive for *C. albicans* with lower colony count (15000 yeast colonies/ml). After two weeks antifungal therapy and disappearance of yeast in next urine samples, vesicostomy was performed to decrease intravesical pressure. Valve ablation and final correction were planned by the age of two years. The patient was put on nitrofurantoin (2mg/kg/night) as an antimicrobial prophylaxis and parents were advised to re-examine in a periodic manner.

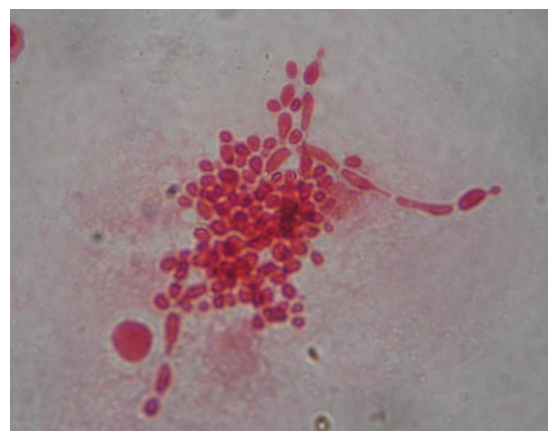


Fig. 2: Yeast cells, budding cells and pseudohyphae of *Candida albicans* (fungus ball like) in direct smears

Discussion

Posterior urethral valves (PUVs) are obstructing membranous folds within the lumen of the posterior urethra that are the most common aetiology of urinary tract obstruction in male newborn male, occurring in 1 in 8000 boys [7]. The diagnosis is often made prenatally with ultrasound showing a dilated fetal urinary system and reduced amniotic fluid volume. Postnatally, VUCG in these cases will demonstrate vesicoureteric reflux [8]. Male infants with PUVs may present failure to thrive, urosepsis, poor urinary stream, and straining or grunting while voiding [9].

Candiduria is rarely seen as a community acquired infection in a structurally normal urinary tract, and in healthy people [10]. The development of ascending infection of the kidney usually occurs in the setting of urinary tract obstruction [11]. Urinary infection with *C. albicans* is most commonly a component of systemic candidiasis in patients who are severely immunocompromised. The first clue to the diagnosis may be the presence of yeasts in the urine [12]. In the present case, firstly and as usual, we tried to eradicate infection causing by *E. coli* in the setting of an obstruction in the common urine pathway (PUVs), leading to renal failure.

Therefore, the diagnosis of bacterial infection was made, and ceftriaxone and amikacine was started. The presence of yeasts in the urine of the patient was also considered as contamination. But, the presence of yeasts in urine (direct or culture examination) does not necessarily imply clinical significance [13]. Regarding the fact that the same yeast was isolated in the consecutive suprapubic urine samples and the fact no bacteria were observed after antibiotic therapy, it can be concluded that *C. albicans* is the etiological agent of UTI in the patient. Therefore, the diagnosis of

candidal infection was made and miconazole was started.

The fact that there was clearance of organisms from the urinary tract with recovery of the patient following antifungal treatment strongly associates the yeast as a cause of UTI. Aggressive and broad spectrum antibiotics therapy, the presence of obstructive uropathy, renal failure, failure to thrive and hospitalization were the major risk factors to develop candidal UTI in this case. Even if the isolated *Candida* is found, it can be difficult to distinguish it among colonization, local bladder infection, and upper tract disease involving the renal parenchyma. Urine characteristics, such as the number of yeast or the presence of pyuria, do not lead to distinguish fungal colonization from fungal infection. Although uncommonly found, the identification of fungal casts in urine cytology specimens stained with periodic Acid-Schiff or silver stains is diagnostic of kidney involvement [14].

Lal *et al.* [15] reported a retrospective clinical study which highlighted the importance of fungal infections as cause of morbidity and mortality in children with PUVs treated at a tertiary care centre. The incidence of proven fungal infection of the urinary tract was 15.5% and fungal sepsis contributed to mortality in 53% patients of all the valve patients who died during the first hospital admission over a 4-year period.

The Infectious Diseases Society of America (IDSA) published guidelines for the treatment of candidiasis in 2009 [16]. Asymptomatic candiduria rarely requires antifungal therapy, unless it occurs in the setting of neutropenia, low birth-weight neonates, or urinary tract manipulation. For patients undergoing urologic procedures, and then who have asymptomatic candiduria, it is suggested to take fluconazole (3 to 6mg/kg orally daily) or

amphotericin B deoxycholate (0.3 to 0.6mg/kg intravenously daily) for several days prior to and following the procedure [16]. Amphotericin B is the most effective antifungal agent, but it is not excreted in the urine [1]. Symptomatic candiduria should always be treated. Therapy should be continued for 14 days. Complications associated with fungal infections of the kidneys include perinephric abscess and bezoar formation [1].

Conclusion

Candiduria is usually an insidious disease and its diagnosis is likely to be missed, because of a general lack of awareness and lack of characteristic features of the etiologic agent. Therefore, fungal infection should be considered in children with obstructing urinary tract abnormalities. It usually responds to selective drainage combined with antifungals.

Acknowledgement

The authors thank to our co-workers in the urologic department at Imam Khomeini hospital for helping to treat the patient.

References

- 1) Herberg J, Pahari A, Walters S, Levin M, Infectious diseases and the kidney. In: Avener ED, Harmon WE, Niaudet P, Yoshikawa N (eds.), 6th, Berlin, Springer-Verlag, 2009: 1267-68.
- 2) Zarei Mahmoudabadi A, Keradmand AR, Enayatollahi N. Frequency of candiduria in inpatients and outpatients in department of urology, Golestan hospital, Ahvaz, Iran. *Iranian JKD*. 2009; 3: 114-5.
- 3) Kauffman CA, Vazquez JA, Sobel JD. Prospective multicenter surveillance study of funguria in hospitalized patients. The National Institute for Allergy and Infectious Diseases (NIAID) Mycoses Study Group. *Clin Infect Dis*. 2000; 30: 14-8.
- 4) Lehner T. Systemic candidiasis and renal involvement. *Lancet*. 1964; 41: 1414-6.
- 5) Zarei Mahmoudabadi A, Zarrin M, Miry S. Phospholipase activity of *Candida albicans* isolated from vagina and urine samples. *Jundishapur J Microbiol*. 2010; 3: 169-73.
- 6) Pakshir K, Bahaedinie L, Rezaei Z, Sodaifi M, Zomorodian K. *In vitro* activity of six antifungal drugs against clinically important dermatophytes. *Jundishapur J Microbiol*. 2009; 2: 158-63.
- 7) Elder JS. Posterior urethral valves, In: Kliegman RM, Behrman RE, Jenson HB, Stanton BF (eds), Nelson textbook of pediatrics, 18th ed, Philadelphia, Saunders Elsevier, 2007: 2241-43.
- 8) Dixon AM. Genitourinary system pathology, In: Hardy M, Boynesv S (eds), Pediatric radiology, First ed, Bradford, Blackwell Science, 2003: 70-3.
- 9) Ghanem MA, Wolffbuttel KP, De Vylder A, Nijman RJ. Long-term bladder dysfunction and renal function in boys with posterior urethral valves based on urodynamic findings. *J Urol*. 2004; 171: 2409-12.
- 10) Richards MJ, Edwards JR, Culver DH, Gaynes RP. Nosocomial infections in medical intensive care units in the United States. National Nosocomial Infections Surveillance System. *Crit Care Med*. 1999; 27: 887-92.
- 11) Ang BS, Telenti A, King B, Steckelberg JM, Wilson WR. Candidemia from a urinary tract source: microbiological aspects and clinical significance. *Clin Infect Dis*. 1993; 17: 662-6.
- 12) Eckstein CW, Kass EJ. Anuria in a newborn secondary to bilateral ureteropelvic fungus balls. *J Urol*. 1982; 127: 109-10.
- 13) Bukhary ZA. Candiduria: A review of clinical significance and management. *Saudi J Kidney Dis Transpl*. 2008; 19: 350-60.
- 14) Bartone FF, Hurwitz RS, Rojas EL, Steinberg E, Franceschini R. The role of percutaneous nephrostomy in the management of obstructing candidiasis of the urinary tract in infants. *J Urol*. 1988; 140: 338-41.
- 15) Lal R, Lama TK, Bhatnagar V, et al. Fungal infections as a cause of morbidity and

- morality in posterior urethral valves. *J Indian Ass Pediatr Surg.* 1997; 2: 130-5.
- 16) Corbett HJ, Kenny SE, Mcandrew HF. Fungal infection in children with obstructing genito-urinary tract pathology: successful management with genito-urinary tract drainage and antifungal therapy. Abstracts of the European Society of Pediatric Urology (ESPU) XXI Annual Congress, Antalya, Turkey. *J Pediatr Urol.* 2010; 6: S60.