



The First Case of *Microsporum persicolor* Infection in Iran

Ali Naseri^{1*}, Abdolmajid Fata¹, Ali Reza Khosravi²

¹ Department of Medical Mycology and Parasitology, Imam Reza Hospital, School of Medicine, Mashhad University of Medical Sciences, Mashhad, IR Iran

² Mycology Research Center, Faculty of Veterinary Medicine, University of Tehran, Tehran, IR Iran

ARTICLE INFO

Article type:
Case Report

Article history:

Received: 01 Jun 2011

Revised: 10 Aug 2011

Accepted: 01 Sep 2011

Keywords:

Microsporum persicolor

Dermatophytosis

Tinea Corporis

ABSTRACT

We report the first case of *Microsporum persicolor* being isolated from an Iranian patient. An 8-year-old girl was examined for tinea corporis. Microscopic examination of the skin scraping performed using 15% KOH revealed hyaline septate branching mycelium and arthroconidia. Cultures of the clinical material yielded *M. persicolor* after 2 weeks of incubation. The isolate was identified on the basis of gross morphological characteristics of the fungal colony on Mycobiotic agar and peptone agar, microscopic characterization of slide culture, and biochemical reactions.

©2012, AJUMS. Published by Kowsar M.P.Co. All rights reserved.

► Implication for health policy/practice/research/medical education:

Microsporum persicolor can be causative agent of tinea corporis and This is the first report of *M.persicolor* as the causative agent of dermatophytosis in Iran.

► Please cite this paper as:

Naseri A, Fata A, Khosravi AR. The First Case of *Microsporum persicolor* Infection in Iran. *Jundishapur J Microbiol.* 2012;5(1):362-4. DOI:10.5812/kowsar.20083645.2430

1. Introduction

Microsporum persicolor is a zoophilic dermatophyte and is seldom reported as the causative agent of human infections (1). Most often, the fungus has been found in small wild mammals such as bank and field voles, wood mice, shrews, pipistrelle bats, horses, and dogs (1-4). *M. persicolor* is prevalent mainly in Europe and has been isolated from soil in Bulgaria, India, and South Africa (4). This species was classified as *Trichophyton persicolor* by Sabouraud, who had detected its presence in 2 human dermatomycosis cases (4, 5). Since Sabouraud discovered it, *M. persicolor* has been considered a rare cause of human ringworm in several countries. The spectrum of human involvement includes tinea capitis,

tinea pedis, tinea corporis and tinea faciei (4-6). There is no report of the isolation of *M. persicolor* from human infection in Iran and this is the first report of *M. persicolor* as the causative agent of ringworm infection in Iran, Mashhad.

2. Case History

An 8-year-old girl with tinea corporis was referred to the Medical Mycology Laboratory of Imam Reza Hospital, Mashhad University of Medical sciences. The patient had a lesion in the left region of the abdomen (Figure 1). After physical examination, the clinical signs and symptoms were recorded, and samples of skin scrapings were collected from the periphery of the affected area. Direct microscopic examination was carried out using 15% KOH preparations. Specimens were cultured on Sabouraud dextrose agar (Merck, Germany) with chloramphenicol, Mycobiotic agar (Difco, USA), and Dermatophyte Test Medium (Merck, Germany). These cultures were incubated at 25-30°C for 4 weeks under aerobic conditions and checked every 2-3 days for the appear-

* Corresponding author: Ali Naseri, Department of Medical Mycology and Parasitology, Imam Reza Hospital, School of Medicine, Mashhad University of Medical Sciences, Mashhad, IR Iran. Tel/FAX: +98-5118547255, E-mail: naseria@mums.ac.ir

ance of colonies. These colonies were subcultured in fresh Mycobiotic agar to avoid any contamination. The cultures were identified on the basis of their macro and microscopic characteristics, hair perforation test, urease test, and growth on peptone agar (Merck, Germany). Hyaline septate branching mycelium and arthroconidia were observed during direct examination of skin samples. Colonies grown on Mycobiotic agar were 35–40 mm in diameter after 2 weeks of incubation. Initially, the colonies were white, but on aging, turned yellowish buff to pale pink on the surface and yellowish to peach

on the reverse. The colonies were fluffy, flat, and gently folded in center (Figure 2 and Figure 3). Cultures on peptone agar developed a deeper rose-pink pigmentation. Microscopic examination revealed numerous micro and macroconidia. Microconidia appeared smooth, thin walled, spherical, borne en grappe, and en thyrses. Macroconidia often appeared spindle-shaped and thin walled with 5–8 cells and had echinulated walls. In addition, numerous spiral and coiled hyphae were observed (Figure 4). Urease test was also positive for this organism. Finally, the fungus was identified as *M. persicolor*.

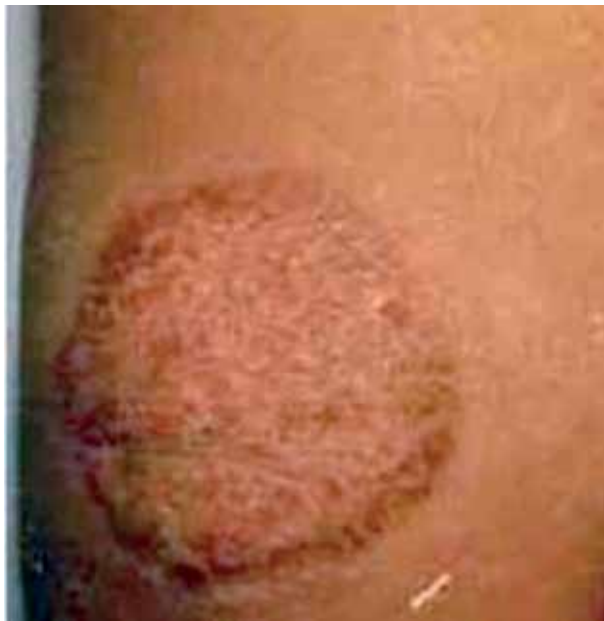

Figure 1. Lesion Caused by *M. persicolor*

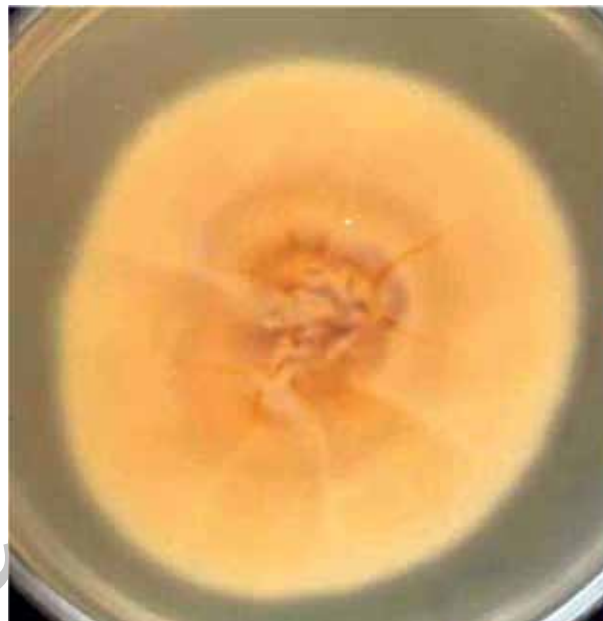

Figure 3. The Colony Reverse of *M. Persicolor* on Mycobiotic Agar

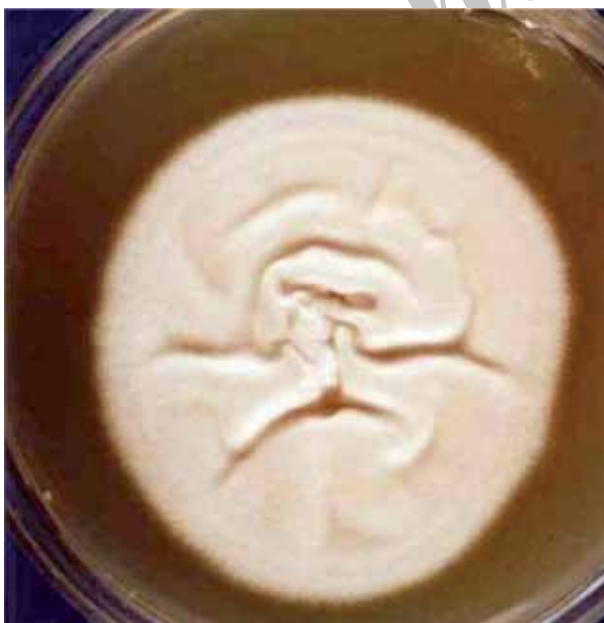

Figure 2. A *M. persicolor* Colony on Mycobiotic Agar after 2 Weeks of Incubation

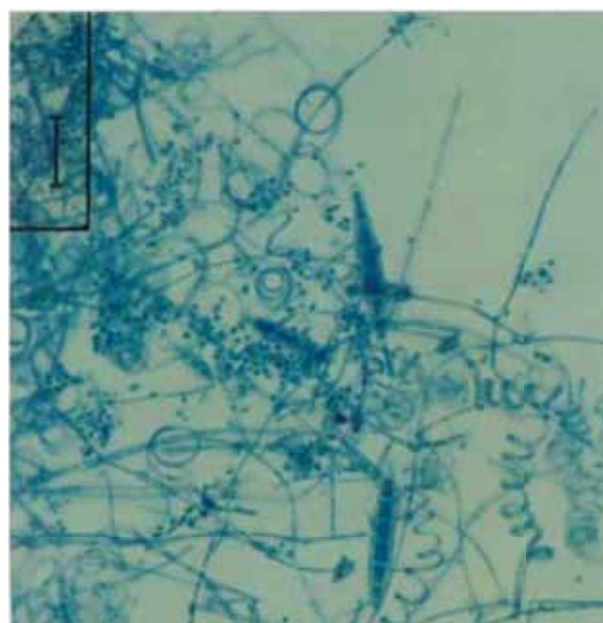


Figure 4. Macroconidia, Microconidia, and Coiled and Spiral Hyphae of *M. Persicolor*

3. Discussion

Tinea corporis is a dermatophyte infection of the glabrous skin, and this infection is most commonly caused by the genera *Trichophyton* and *Microsporum* (1). Tinea corporis is one of the most common form of dermatophytosis (7-12). This infection occurs in all age groups, but more predominant between 0-15 and 20-29 years (7, 13). This disease is common in both sexes, but several studies report that females are more frequently affected than male (7, 13, 14). The causative agents of tinea corporis vary according to the geographic region. *T. mentagrophytes* is reported as a chief causative agent of tinea corporis in Iran; other causative agents include the dermatophytes *M. canis*, *T. verrucosum*, *Epidermophyton floccosum*, *T. violaceum*, *T. tonsurans*, *M. gypseum*, and *T. rubrum* (7, 12, 14, 15).

M. persicolor is a zoophilic dermatophyte and it infrequently causes skin infections in humans (5). This species was originally described by Sabouraud as *T. persicolor* (4) and was later classified by Ajello as *M. persicolor* (16). The human lesions caused by *M. persicolor* have a similar appearance to those seen in cases of tinea corporis caused by other zoophilic dermatophytes (4). Infections are acquired primarily through exposure to small rodents (2, 3, 6). The patient's history showed that she had a pet cat, which probably was the source of infection. Few cases of dermatophytosis caused by *M. persicolor* have been documented worldwide (4-6). There are no previous records of infections caused by *M. persicolor* in Iran, except for a study that was carried out to investigate fungal flora of Persian squirrels, from which *M. persicolor* was isolated (17). *M. persicolor* is strikingly similar to *T. mentagrophytes* in terms of both clinical and microscopic morphology (18). This scarcity of reports might be because *M. persicolor* is frequently confused with *T. mentagrophytes* and is identified as the latter. Thus, a method for definitive identification is necessary for differentiating *M. persicolor* from *T. mentagrophytes*. In conclusion, *M. persicolor* infection is reported for the first time in Iran (Mashhad).

Acknowledgments

The authors would like to thank the personnel at the Medical Mycology & Parasitology Laboratory of Imam Reza Hospital, Mashhad, University of Medical Sciences for their help and the reviewers for reviewing the manuscript.

Financial Disclosure

None declare.

Funding/Support

None declare.

References

1. Rippon JW. Medical Mycology. 3rd Edition WB Saunders Co, Philadelphia, USA. 1988;247-9.
2. English MP. Trichophyton persicolor infection in the field vole and pipistrelle bat. *Sabouraudia*. 1966;**4**(4):219-22.
3. Muller A, Guaguere E, Degorce-Rubiales F, Bourdoiseau G. Dermatophytosis due to *Microsporum persicolor*: a retrospective study of 16 cases. *Can Vet J*. 2011;**52**(4):385-8.
4. Onsberg P. Human infections with *Microsporum persicolor* in Denmark. *Br J Dermatol*. 1978;**99**(5):531-6.
5. English MP, Kapica L, Maciejewska J. On the occurrence of *Microsporum persicolor* in Montreal, Canada. *Mycopathologia*. 1978;**64**(1):35-7.
6. Padhye AA, Blank F, Koblenzer PJ, Spatz S, Ajello L. *Microsporum persicolor* infection in the United States. *Arch Dermatol*. 1973;**108**(4):561-2.
7. Al Sheikh H. Epidemiology of dermatophytes in the eastern province of Saudi Arabia. *Res J Microbiol*. 2009;**4**(6):229-34.
8. Falahati M, Akhlaghi L, Lari AR, Alaghebandan R. Epidemiology of dermatophytoses in an area south of Tehran, Iran. *Mycopathologia*. 2003;**156**(4):279-87.
9. Khosravi A, Aghamirian M, Mahmoudi M. Dermatophytoses in Iran. *Mycoses*. 1994;**37**(12):43-8.
10. Omidinia E, Farshchian M, Sadjjadi M, Zmanian A, Rashidpouraie R. A study of dermatophytoses in Hamadan, the governmentship of west Iran. *Mycopathologia*. 1996;**133**:9-13.
11. Pakshir K, Hashemi J. Dermatophytosis in Karaj, Iran. *Indian J Dermatol*. 2006;**51**(4):262.
12. Sepahvand A, Abdi J, Shirkhani Y, Fallahi SH, Tarrahi M, Soleimanejad S. Dermatophytosis in Western Part of Iran, Khorramabad. *Asian J Bio Sci*. 2009;**2**:58-65.
13. Mahmoudabadi AZ. A study of dermatophytosis in South West of Iran (Ahwaz). *Mycopathologia*. 2005;**160**(1):21-4.
14. Rezvani SM, Sefidgar S, Hasanjani RMR. Clinical patterns and etiology of dermatophytosis in 200 cases in Babol, North of Iran. *CJIM*. 2010;**1**(1):23-26.
15. Bassiri-Jahromi S, Khaksari AA. Epidemiological survey of dermatophytosis in Tehran, Iran, from 2000 to 2005. *Indian J Dermatol, Venereol, Leprol*. 2009;**75**(2):142.
16. Ajello L. Sexual reproduction among fungi pathogenic to man. A historical review. *Mykosen*. 1971;**7**(6):343-52.
17. Rostami A, Shirani D, Shokri H, Khosravi A, Daieghazvini R, Tootian Z. Fungal flora of the hair coat of Persian squirrel (*Sciurus anomalus*) with and without skin lesion in Tehran, Iran. *J Med Mycol*. 2010;**20**(1):21-5.
18. Kane J, Sigler L, Summerbell RC. Improved procedures for differentiating *Microsporum persicolor* from *Trichophyton mentagrophytes*. *J Clin Microbiol*. 1987;**25**(12):2449-52.