



Neovascularization in Left Atrial Myxoma

Laxman Dubey^{1*}, Amit Kumar Chaurasia¹

¹Department of Cardiology, College of Medical Sciences & Teaching Hospital, Bharatpur-10, Nepal

ARTICLE INFO

Article Type:
Case Report

Article History:
Received: 11 Aug 2012
Revised: 16 Sept 2012
Accepted: 27 Oct 2012

Keywords:
Myxoma
Neovascularization
Coronary Angiography

ABSTRACT

We report a case with a left atrial mass who underwent coronary angiography to rule out coronary artery disease. Coronary angiography revealed an anomalous tortuous vascular structure originating from the left circumflex coronary artery to the left atrial tumor suggestive of neovascularization. Preoperative coronary angiography is useful for coronary artery evaluation and also provides additional information regarding the feeding vessel supplying the mass.

► Implication for health policy/practice/research/medical education:

In patients with the atrial myxoma, coronary angiography can provide additional information by visualizing possible neovascularization from coronary arteries, because presence of a large feeding artery to the atrial myxoma must be ligated in addition to excision of the myxoma.

► Please cite this paper as:

Dubey L, Chaurasia AK. Neovascularization in Left Atrial Myxoma. *Int Cardiovasc Res J*.2012;6(4):133-134.

1. Introduction

Primary cardiac tumours are rare with an autopsy frequency of only 0.001-0.03% (1). Cardiac myxomas are the commonest form of primary cardiac tumors in adults and accounts for nearly half of all benign cardiac tumors (2). In a report of 323 consecutive patients undergoing surgical resection of primary cardiac tumours between 1957 and 2006 at the Mayo Clinic, 94% were benign and half of these were myxomas (3).

Myxomas are generally localized in the atria, mostly in the left atrium (LA) (2). Patients with myxomas are usually asymptomatic, but may have triad of embolism, intracardiac obstruction, and constitutional symptoms (4).

Tumour neovascularisation in cardiac myxomas has been shown in previous case reports. In our case report, we demonstrated a LA mass after transthoracic echocardiography, and during preoperative evaluation, coronary angiography (CAG) revealed the presence of tumour neovascularisation from the left circumflex coronary artery, with no evidence of coronary artery stenosis. Pathological analysis confirmed the clinical diagnosis of LA myxoma. To our knowledge, this is the first case of neovascularized LA myxoma reported from Nepal.

2. Case Report

A 64-year-old man was referred to our department for transthoracic echocardiography. He had a history of ischemic stroke 2 years back with left hemiparesis. The physical examination revealed a low-pitched sound heard

*Corresponding author: Laxman Dubey, Department of Cardiology, College of Medical Sciences & Teaching Hospital, Bharatpur-10, Nepal, Tel: 00977-9851123288
 E-mail: dubeylax@yahoo.com

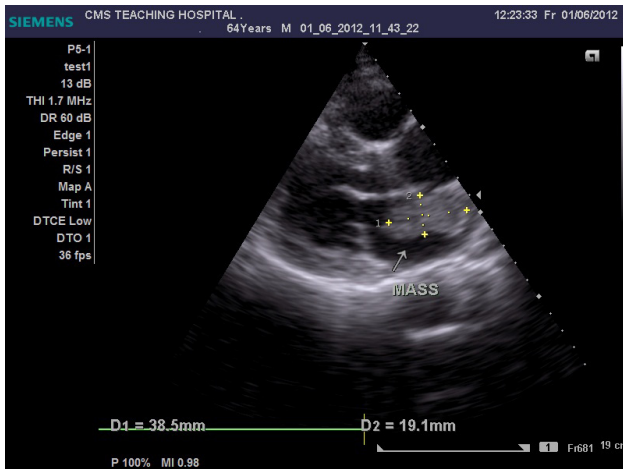


Figure 1. Transthoracic Echocardiography in Parasternal Long Axis View Showing a Heterogenous Mass in the Left Atrium Attached to the Interatrial Septum

during mid-diastole. Transthoracic echocardiography showed a large gelatinous mass measuring 38 x 19 mm in the LA arising from the interatrial septum (Figure 1). Coronary angiography was performed to rule out significant coronary artery stenotic lesions before surgery, which demonstrated the large feeding vessel arising from the proximal left circumflex artery (Figure 2) that supplied the mass (Figure 3) with no evidence of coronary artery stenosis. The mass was excised and the patient recovered uneventfully. Pathological analysis of the mass confirmed the clinical diagnosis of LA myxoma.

3. Discussion

Myxomas are the commonest primary tumours of the heart that have a typical echocardiographic appearance characterized by a gelatinous and friable mass (2). Myxomas are usually localized in the atria, majority in the LA. In rare cases, there is prominent vascularization of myxomas by supplying vessels from the coronary arteries. During CAG such neovascularization is usually verified,

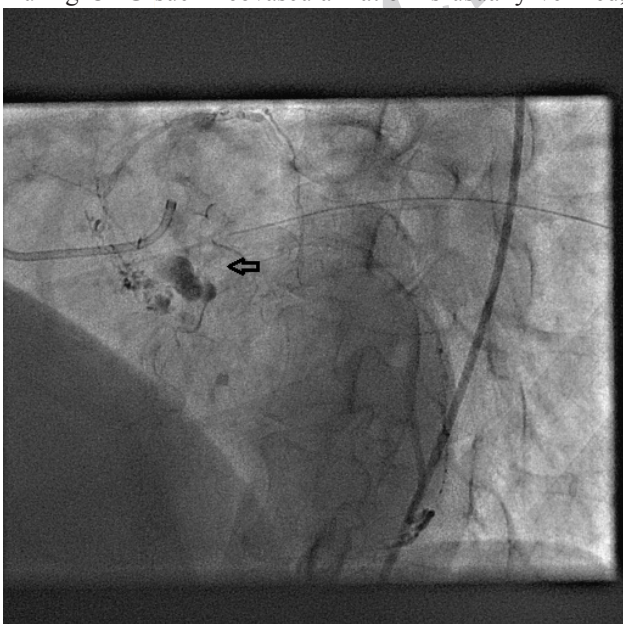


Figure 3. Left Atrial Mass (Arrow) Stained with Contrast Injected in the Left Coronary Artery System, Excellently Imaged Due to the Marked Contrast Enrichment in the Late Phase

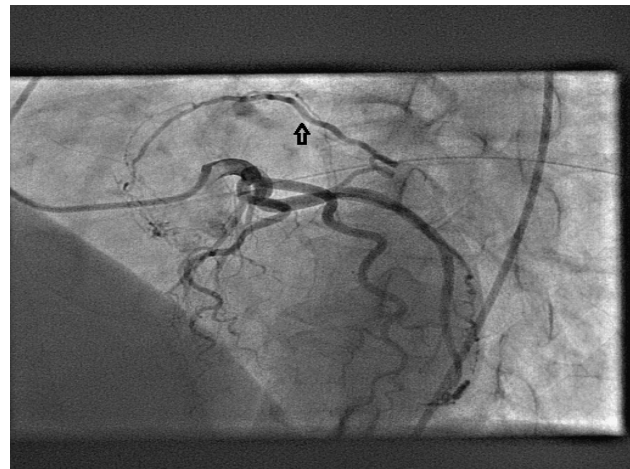


Figure 2. Selective Coronary Angiography of the Left Coronary System Showing a Feeding Artery (Arrow) Originating From the Left Circumflex Artery Supplying the Left Atrial Mass Visualized in the Early Phase

also three-dimensional imaging of the feeding vessels using multislice computed tomography has been reported (5). In our case, neovascularization of a LA myxoma from the left circumflex coronary artery was demonstrated in the CAG. This case demonstrated that CAG is important for ruling out coronary artery disease, and also can provide additional information to echocardiography for the diagnosis and evaluation of atrial myxoma by visualizing possible tumour neovascularization from coronary arteries, necessitating a surgical procedure. Presence of a large feeding artery substantially changes the operative strategy because large feeding arteries must be ligated in addition to excision of the myxoma.

Acknowledgements

There is no acknowledgements.

Financial Disclosure

None Declared.

Funding/Support

None Declared.

References

1. Lam KY, Dickens P, Chan AC. Tumors of the heart. A 20-year experience with a review of 12,485 consecutive autopsies. *Arch Pathol Lab Med.* 1993;117(10):1027-31.
2. Reynen K. Cardiac myxomas. *N Engl J Med.* 1995;333(24):1610-7.
3. Elbardissi AW, Dearani JA, Daly RC, Mullany CJ, Orszulak TA, Puga FJ, et al. Survival after resection of primary cardiac tumors: a 48-year experience. *Circulation.* 2008;118(14 Suppl):S7-15.
4. Pliakos C, Alexiadou E, Metallidis S, Papavramidis TS, Kapoulas S, Sapalidis K, et al. Right atrium myxoma coexisting with antiphospholipid syndrome: a case report. *Cardiovasc Ultrasound.* 2009;7:47.
5. Funabashi N, Komiyama N, Hasegawa H, Kato H, Yamamoto Y, Yoshida K, et al. Images in cardiovascular medicine. Feeding artery of a left atrial myxoma demonstrated by three-dimensional volume-rendering images with multislice computed tomography. *Circulation.* 2002;106(15):e63-4.