

Digestive Disease Case Records from the Hospitals of Tehran and Shiraz
Universities of Medical Sciences

Case 1-2011: A 26 Year-Old Man with Right Lower Limb Edema and Liver Mass

R Taslimi^{1*}, R Malekzadeh², M Rahmani³, F Azmodeh Ardalan⁴

1. Department of Gastroenterology, Imam Khomeini Hospital, Tehran University of Medical Sciences, Tehran, Iran
2. Digestive Disease Research Center, Shariati Hospital, Tehran University of Medical Sciences, Tehran, Iran
3. Department of Radiology, Imam Khomeini Hospital, Tehran University of Medical Sciences, Tehran, Iran
4. Department of Pathology, Imam Khomeini Hospital, Tehran University of Medical Sciences, Tehran, Iran

CASE PRESENTATION

Dr. Reza Taslimi (Internist): A 26 year-old man presented with right lower limb swelling and fullness in the right lower abdominal quadrant. He was in his usual healthy state until two months before admission when he gradually developed fatigue, malaise, fever, sweating, decreased appetite and a five kg weight loss. One month prior to admission, abdominal pain started with a constant and gradually progressive nature which was most severe in the right lower quadrant and was unrelated to eating. Three days before admission, he developed pain and swelling in right leg.

No history of nausea, vomiting and changes in bowel habit were noted. He did not smoke, drink alcohol or use illicit drugs. Family history was negative for any significant medical condition.

Five years before the onset of symptoms, the patient had an abdominopelvic ultrasonography performed because of blunt trauma to the abdomen which reported a heterogeneous echogenic mass with a diameter of 45×30 mm in the left liver lobe. Two months later, a dynamic CT scan showed a left liver lobe mass with a diameter of 50×30 mm suggestive of liver hemangioma (Figures 1, 2). He was advised to obtain an MRI. Since he was symptom-free, the patient did not follow this advice and was doing well until two months prior to admission.

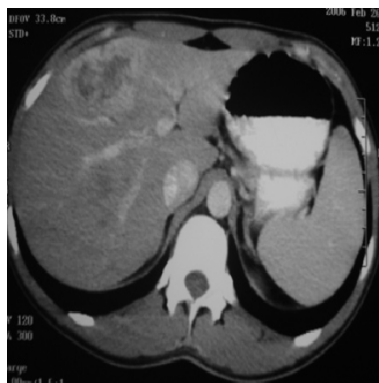

Fig. 1: Abdominal CT scan performed five years ago which showed peripheral enhancement in the arterial phase.

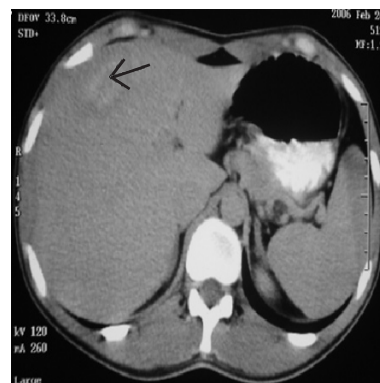

Fig. 2: Central hypodense area as seen in the delayed phase, five years ago (arrow).

***Corresponding Author:**

Reza Taslimi, MD
Assistant Professor of Medicine,
Department of Gastroenterology,
Imam Khomeini Hospital, Tehran
University of Medical Sciences,
Tehran, Iran
Email: rtaslimi@tums.ac.ir
Telefax: +98 21 66581650
Received: 15 Jan. 2010
Accepted: 08 Feb. 2011

On physical examination, blood pressure was 127/80 mm Hg with a pulse of 72 bpm. Temperature was 37.8°C. Right lower limb swelling extended above the knee joint and color Doppler ultrasound performed in the local hospital revealed deep vein thrombosis (DVT). On physical examination the abdomen was soft but a huge non-tender mass with an indistinguishable border was palpated which extended from 5 cm below the right costal margin to the pelvis. There were no stigmata of chronic liver disease such as ascitis, spider angioma, abdominal wall collateral veins, jaundice or splenomegaly.

Lymphadenopathy was not present and the remainder of the examinations which included heart, lungs, skin, testises, joints and neurologic system were normal.

Levels of tumor markers including carcino-embryonic antigen, CA 19-9 and beta-HCG were normal. Doppler sonography reported thrombosis in the inferior vena cava (IVC) and both sides of the common iliac veins and right femoral vein. Portal and hepatic veins were patent. Other laboratory results are shown in Table 1. A multislice triphasic abdomino-pelvic CT scan (Figures 3-4-5) and a diagnostic procedure was performed.

Table 1: Laboratory data.

Hemoglobin (gr/dL)	11(12-17.5)	Alanine Transaminase (IU/L)	38 (9-40)	HBsAg	Negative
WBC (/mm ³)	10,600 (4500-10000)	Aspartate Transaminase (IU/L)	24 (10-35)	HCV Ab	Negative
Platelet count (/mm ³)	485,000 (150000-450000)	Alkaline Phosphatase (IU/L)	284 (30-120)	HIV Ab	Negative
Creatinine (mg/dL)	0.9 (0.5-1.4)	LDH (IU/L)	468 (56-194)	α-Fetoprotein (ng/ml)	3.1 (< 5.4)
Serum Sodium (meq/L)	139 (135-147)	Total Bilirubin (mg/dL)	1.3 (0.1-1.2)		
Serum Potasium (meq/L)	4.6 (3.5-5.2)	Direct Bilirubin (mg/dL)	0.5 (0-0.3)		
Calcium (mg/dL)	8.8 (8.8-10.3)	PTT (sec)	34 (22-37)		
		PT (sec)	13 (10-13)		
		Albumin (gr/L)	3.6 (3.6-5)		

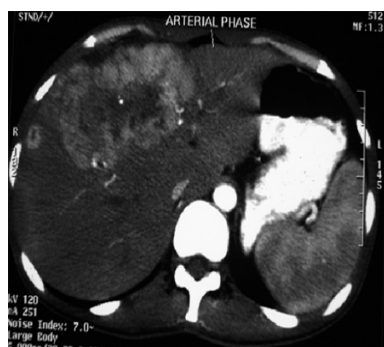

Fig. 3: In arterial phase, continuous peripheral enhancement with central calcification was seen.

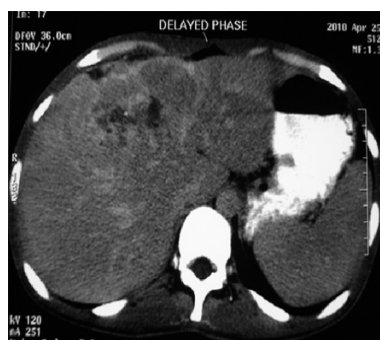

Fig. 4: Large central scar with calcification seen in delayed phase.

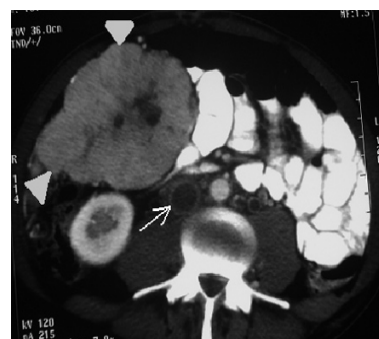

Fig. 5: Inferior vena cava thrombosis (arrow) and similar mass with central scar in pelvis (arrowheads).

Dr. Reza Malekzadeh: May we review the imaging studies first?

Dr. Maryam Rahmani (radiologist): In the first abdominal CT scan performed five years ago, there was a lobulated hepatic mass in the left liver lobe which shows early peripheral enhancement that did not correspond with

contrast in the aorta and not faded (Figure 1). A non-enhancing central scar was seen in the delayed phase (Figure 2).

The remainder of the liver including the parenchyma and adjacent biliary ducts, hepatic and portal veins, and intrahepatic inferior vena cava (IVC) appeared unremarkable.

Spleen, pancreas and other areas were normal. Also an ultrasound found a heterogeneous mass of about 30-40 mm in diameter. The liver mass enlarged during the past five years. On the second CT scan, continuous peripheral enhancement was seen in the early arterial phase (Figure 3). A large central scar with calcification was noted (Figure 4). Also, a peritoneal mass with similar characteristics is depicted around the pelvic inlet (Figure 5). A smaller enhancing homogenous mass located in the areas of the porta hepatis is suggestive of lymphadenopathy. Extensive abdominal IVC and iliac vein thrombosis is also noted. No direct invasion of the mentioned mass to the IVC or iliac veins is observed. Other organs appear unremarkable and no ascetic fluid is seen. A large hepatic mass with a central scar in an otherwise normal liver in a young patient is suggestive of several differential diagnoses that include fibrolamellar hepatocellular carcinoma (FL-HCC), focal nodular hyperplasia (FNH), giant cavernous hemangioma, hepatocellular carcinoma (HCC), cholangiocarcinoma and metastasis.¹ The pattern of enhancement in this patient is not consistent with hemangioma that was diagnosed five years prior. Hemangioma shows peripheral nodular enhancement and also appears as dense as aorta in the arterial phase.² Ultrasound usually shows a hyperechoic mass which was not the case in our patient. Also when considering extrahepatic extension of a mass, no benign diagnosis such as hemangioma or FNH could be possible.

On the other hand, the behavior of this mass during the past five years is in contrast to a progressive malignancy such as HCC, cholangiocarcinoma or metastatic lesions. The pattern of enhancement in this patient is not consistent with HCC. HCC shows early enhancement and rapid washout in the venous phase.³ When we consider that this patient is a young man with a healthy liver and an incidentally found mass, the most probable diagnosis is FL-HCC or FNH.

So between FL-HCC and FNH, a central scar in FNH enhances with contrast but not in FL-HCC.¹ In our patient the central scar did not enhance, and therefore is more consistent with FL-HCC. In addition, calcification in the central scar favored FL-HCC. Mass heterogeneity is seen more frequently in FL-HCC.⁴ As mentioned above, the behavior of the mass and pelvic involvement is more compatible with FL-HCC than FNH. Thus, in my opinion the most probable radiologic diagnosis is FL-HCC.

Dr. Malekzadeh: Our main clinical findings include:

- A 26 year-old male with a liver mass since five years ago.
- Progressive right lower quadrant pain, night sweats and weight loss during the last two months.
- Presentation of a huge mass in the right lower quadrant extending to the pelvis with IVC and femoral vein thrombosis.

The most important initial question is whether chronic liver disease exists or an extrahepatic disorder may have led to the development of a focal liver lesion, such as HCC, a metastatic mass or an abscess. In our patient there is no evidence of chronic liver disease such as sclerosing cholangitis or cystic fibrosis; markers for HBV, HCV, autoimmune hepatitis and Wilson's disease are all negative. We did not measure the level of alpha 1-antitrypsin, but its deficiency is unlikely based on the observed clinical behavior. We must consider the presence of a new mass that has arisen in an otherwise normal liver.

Except for liver abscesses, the most common primary hepatic lesions are hemangioma, focal nodular hyperplasia, hepatic adenomas, primary liver cancer and metastatic lesions.

Liver abscess

There are two different etiologies for liver abscesses, amebic and pyogenic. Amebic liver

abscess typically develops in the right hepatic lobe of a young adult (median age, 29 years) and appears as a well-defined lesion on imaging studies. This patient did not report diarrhea, which would have suggested the presence of amebic colitis, but fewer than half of the patients with an amebic liver abscess report antecedent diarrhea or have amebic trophozoites or cysts in their stools.

Infection can be diagnosed serologically, but serum IgG antibody to *Entamoeba histolytica* was not measured in this case. Abdominal CT scans in amebic abscesses typically show well-defined, round, low-density lesions; unlike the lesion in this patient.⁵ A pyogenic abscess may be primary or possibly secondary to bacterial superinfection of another liver lesion. Pyogenic abscess is not a likely diagnosis because of the long duration of symptoms, the absence of a history of clinically significant fever and rigors, and the absence of characteristic findings of abscess on the abdominal CT scan.

Hepatic cyst

Most hepatic cysts are asymptomatic and easily diagnosed on the basis of imaging studies. Ultrasonography and CT scan excluded a cystic lesion in our patient.

Hepatic hemangioma

It is the most common lesion found in subjects without liver disease. Hemangioma has been found in 0.4-20% of subjects, most commonly in women. Its size ranges between 1 to 20 cm in diameter and is usually asymptomatic. Symptoms, if present, are variable and unrelated to size. Bleeding is exceedingly rare even in patients with large hemangiomas. On ultrasound, it is almost always hyperechoic with a sharp, fixed border.

Hemangiomas under 2 cm are simply followed. If larger, a dynamic triphasic CT scan is performed. In the arterial phase of a dynamic CT, contrast comes to the periphery and produces nodular peripheral enhancement with

hypodensity in the center. In the venous phase the whole lesion gradually takes up the contrast and becomes isodense. With a triphasic CT scan, hemangiomas can almost always be diagnosed with certainty. Occasionally, an MRI is needed for confirmation. It is very important to make a confident diagnosis of hemangioma and prevent unnecessary biopsy, ablation and embolization which could be dangerous.

We have recently reviewed the medical records of 198 patients with cavernous hemangioma of the liver who visited our hepatology clinic in Tehran from 1997 to 2007. Of the 198 cases, 129 could be followed for a period of 3.2 ± 2.5 years. Patients were between 27 to 84 years old and 131 (66.2%) were female. Thirty-six patients (18.2%) had giant hemangioma (>5 cm). Abdominal pain was the reason for evaluation in 100 patients (50.5%). Presence of abdominal pain at the beginning of follow-up was significantly associated with other accompanying GI diseases, but not with hemangioma size, number or location. Location in the right lobe was seen in 179 (89%) cases and 13 (6.5%) were in the left lobe. Nine patients (7% of those available for follow-up) underwent surgical resection.⁶ As a whole, cavernous hemangioma is generally asymptomatic, although it occasionally causes abdominal pain, and is not associated with the constellation of findings in this patient. The lesion is usually easy to identify on imaging, but the features may be atypical, prompting a more detailed investigation such as MRI or even biopsy.

Focal nodular hyperplasia (FNH)

It is the second most common etiology (0.5%) for a mass lesion found in a person without underlying liver disease. Women constitute 20-50% of cases. Of these lesions, 60% are less than 5 cm in diameter, but the lesion may increase in size over time. They are usually asymptomatic. It is unclear if growth is affected by oral contraceptives, therefore contraceptives need not be discontinued. No

malignant potential exists.⁷ FNH has a central scar which may be due to degenerative arteriovenous malformation. Occasionally, the presence of a large lesion causes abdominal discomfort and upon imaging may be mistaken for a malignant tumor, particularly the fibrolamellar variant of HCC.

The lesion may be hypo or isodense on non-contrast CT with the central scar identified in one-third of patients.

The lesion becomes hyperdense during the arterial phase due to the arterial origin of its blood supply. FNH is generally isodense during the portal venous phase, although the central scar may become hyperdense as contrast diffuses into the scar. In T2 weighted MRI, the central scar is hypersignal and in T1 it is hyposignal. In T1 with injection, in the delayed phase, the scar uptakes contrast.⁸ The possibility of FNH is very unlikely in this patient due to the course of disease and image characteristics seen on CT scan.

Nodular regenerative hyperplasia (NRH)

This can be seen with autoimmune, myeloproliferative or lymphoproliferative disorders and following therapy with anti-neoplastic medications.

Disorders leading to thrombophilia are the most common underlying cause and hypercoagulability has been identified in up to 50% of patients.⁹ Most are known to cause vascular damage. Vascular injury causes remodeling of the surrounding tissue into a nodule which is composed of normal liver cells and no fibrosis. NRH may appear like cirrhotic nodules on imaging studies. No risk of malignant transformation exists, but it can be a cause of non-cirrhotic portal hypertension. NRH is very unlikely in this patient because of the course of the disease and characteristic image on CT scan.

Hepatic adenoma

This is the third most common lesion that

develops in an otherwise normal appearing liver. It occurs almost exclusively in young women, particularly those taking oral contraceptives and is frequently located in the right hepatic lobe. It also occurs in patients with tyrosinemia, type I or IV glycogen storage disease, or diabetes mellitus, during pregnancy and in those who use anabolic steroids. None of these factors are present in this case. Because the lipid content of hepatocytes is variable in hepatic adenoma, sonography may show a hypoechoic or hyperechoic lesion, although they usually appear hyperechoic.¹⁰ Hepatic adenomas may become large enough to cause abdominal discomfort, but their clinical importance lies in their potential for rupture and bleeding, and malignant change. Lesions more than 5 cm in diameter have a tendency for malignancy. Intralesional hemorrhage may result in a heterogeneous appearance on CT scanning that is suggestive of cancer. Adenomas can continue to grow during pregnancy and with contraceptive pills. We must discontinue contraceptive pills and monitor the lesion every six months with imaging until it becomes stable. Lesions may shrink and disappear when contraceptives are discontinued. Resection must be performed if its growth is concerning or if it doesn't decrease in size when contraceptives are stopped. Hepatic adenoma is very unlikely in this male patient because of the course of disease and characteristic image on CT scan.

Focal fatty change

Focal fat accumulation in the liver may present as a mass on imaging, which may be misinterpreted as neoplasia. In ultrasound it is bright but hypodense on CT scan. It can be seen with alcohol use, metabolic syndrome, total parenteral nutrition and HIV infection. MRI shows increased intensity on T1. Focal fatty accumulation is unlikely in this patient because of the course of disease and characteristic image on sonography and CT scan.

The imaging and clinical findings in our patient do not fit any of the above benign lesions. The lesion is heterogeneous, with a hypodense central scar which is increasing in size and resulted in a sick, symptomatic patient. The lesion appears to extend to the pelvis and surrounding vessels. So the possibility of a malignant lesion is more likely, therefore we focus on the possibility of a malignant mass.

Liver metastases

Hepatic metastases are approximately 30 times more frequent than primary liver cancer. Gastric, colonic and pancreatic adenocarcinomas account for over 40% of cases of hepatic metastases, but none of the findings in this case suggest the presence of these primary tumors. There is no evidence of metastatic melanoma, which often metastasizes to the liver but almost always has a rapid clinical course once the liver is involved. Liver metastasis is highly unlikely in this patient.

Cholangiocarcinoma (CAC)

CAC usually appears at the lower end of the common bile duct or within the major bile ducts, near their bifurcations. When the tumor develops within the hepatic parenchyma (intrahepatic CAC), it usually occurs during chronic liver disease. It may be associated with primary sclerosing cholangitis, oriental cholangiohepatitis, liver-fluke infestation or exposure to thorium dioxide,¹¹ none of which are pertinent to this case. No underlying bile duct disease such as sclerosing cholangitis exists in our patient. The average age of patients with cholangiocarcinoma ranges from 50 to 60 years. The serum carcinoembryonic antigen level is elevated in a minority of cases.

Cholangiocarcinoma is aggressive and chronic presentation is very rare. A central scar is also rare in dynamic CT scan. Thus, it is unlikely that this patient's lesion is a new intrahepatic cholangiocarcinoma.

Extrahepatic disease with liver involvement

Is there any evidence that this patient had a primary extrahepatic illness that caused a liver mass? Night sweats and weight loss are common symptoms of diseases such as lymphoma and/or infection. B-symptom occurs in 25 to 30% of persons with non-Hodgkin's lymphoma (NHL) or Hodgkin's disease which is common in males who are 15 to 30 years old. Hodgkin's disease usually accompanies lymphadenopathy and splenomegaly and has an infiltrative pattern, with multiple or occasionally single lesions that are well defined, large and uniformly low in density, unlike the lesion in this case. Also this patient had no evidence of lymphadenopathy or splenomegaly. The findings in this case are not consistent with the diagnosis of primary hepatic NHL, an uncommon disorder that is almost always aggressive, rarely causing symptoms of over two years' duration, and usually manifested as multiple low-density lesions on CT scans.

HCC

HCC constitutes 90% of primary liver cancers and has two types or variants: common and fibrolamellar. FL-HCC accounts for only 1 to 2% of all cases of which as many as 40% are younger than 35 years.

HCC common type: The common type of HCC is usually characterized by a shrunken, nodular liver surrounding the mass and other changes suggestive of cirrhosis on abdominal CT scans-findings that are absent in this case. Similarly, the serum α -fetoprotein level is elevated in more than 70% of patients with the common type of HCC, but the value is normal in our case.

Common HCC is unlikely in this case because HCC rarely develops in a person as young as this patient or in the absence of cirrhosis, unless the patient has chronic hepatitis B. Moreover, when cirrhosis is present, HCC is usually not the first clinical manifestation of

liver disease. The main cause of HCC is viral infections. In Iran HBV is the leading cause of HCC.¹²

Fibrolamellar carcinoma of liver

A diagnosis that can explain most of the clinical features of this case is fibrolamellar carcinoma. A slow growing cancer that typically occurs in young adults, the median age of affected persons is 25 years.¹³

Although usually considered a variant of HCC, fibrolamellar carcinoma may be a separate entity. Unlike typical HCC, FL-HCC has no known correlation with cirrhosis or chronic inflammatory liver disease and is usually not associated with an elevated serum α -fetoprotein level.

FL-HCC is a rare histologic variant of common HCC and should be suspected in patients with HCC who are young and do not have underlying hepatitis or cirrhosis.¹⁴ Microscopically, FL-HCC is composed of nests of tumor cells that are separated by dense, fibrous septa. Characteristics of triphasic CT scan and MRI often allow diagnosis before resection and there is usually no need for biopsy. The diagnosis of fibrolamellar carcinoma can be difficult to establish by examining a needle-biopsy specimen and several passes or an open wedge biopsy may be necessary to obtain adequate tissue.

FL-HCC generally has an indolent course, there may be a protracted prodromal period characterized by nonspecific symptoms, including abdominal discomfort, weight loss and night sweats. Jaundice is uncommon.

On non-contrast CT scans, it is heterogeneous with a hypodense central scar. Marked enhancement is seen after the administration of contrast material and this finding may result in a misdiagnosis of focal nodular hyperplasia (Figure 3).¹⁵ Focal scars may develop in tumors with an abundance of fibrous stroma and may be found in large tumors that outgrow

their blood supply during the process of tissue repair. A central scar may be noted on CT scan in FNH, FL-HCC, large hemangioma (≥ 3.5 cm) and rarely in cholangiocarcinoma, common HCC and liver metastasis.

Differential diagnosis of FL-HCC include FNH, common HCC, adenosquamous carcinoma of the gallbladder with extension into the liver, metastatic tumors associated with fibrosis-for example, breast cancer-pancreatic islet-cell tumor, carcinoid tumor and cholangiocarcinoma. Distinguishing FNH, FL-HCC and hemangioma is important because benign lesions usually require no treatment, while FL-HCC requires aggressive surgical resection. All three types of tumors occur in noncirrhotic livers, have no associated serum markers and are often classified as hypervascular. Several studies have been published about FL-HCC. The median age is 27 years, 60% are males who have never had cirrhosis or hepatitis, and only 7% have elevated α -fetoprotein. Solitary tumors are seen in 90%. FL-HCC ranges in size from 3 to 17 cm; particularly during the later stages, its size can increase rapidly. Complete surgical resection is curative in 50 to 75% of cases. Aggressive initial surgical resection along with regional lymphadenectomy should be performed for primary disease. Patients should be followed for at least ten years because late recurrence often occurs.¹⁶ If partial hepatectomy is not feasible because of the size of the tumor or extension into adjacent organs, orthotopic liver transplantation is required.

Dr. Reza Malekzadeh's diagnosis

Fibrolamellar variant of HCC.

Pathological discussion

Dr. Azmodeh: Histopathologic evaluation and immunohistochemical study (IHC) of the needle biopsy from the mass reported "compatible with HCC" in another laboratory. The IHC study revealed positive reaction for cy-

okeratin-7, α -fetoprotein and carcinoembryonic antigen (canalicular pattern) and negative reaction for cytokeratin-20.

Subsequently, the abdominal mass was resected and intra-operatively, a biopsy was taken from the liver mass. These specimens were studied in another center which reported “moderately differentiated HCC, trabecular variant”.

The remnants of the latter specimen, both processed and unprocessed, were submitted to our center for re-evaluation. The sample consisted of a well-circumscribed tan-grayish elastic to firm mass measuring up to 14 cm in diameter. The cut surface was grayish and vaguely nodular with a central stellate scar (Figure 6). Omental tissue, measuring 9×9×1.5 cm, was attached to the mass.

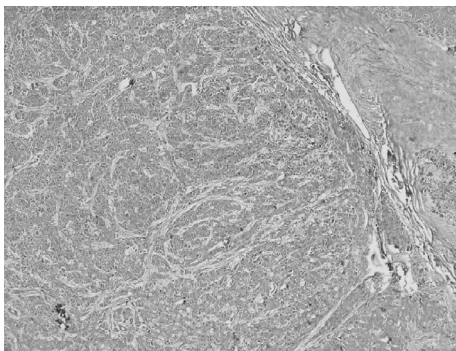


Fig. 6: This low power micrograph shows part of the central scar (upper right area of the image) and the neoplasm with a trabecular pattern of growth invested by thin laminae of collagen. H&E stain-4x

Microscopic examination of the abdominal mass showed a well-delineated, partially encapsulated tumor in fibrofatty tissue. The tumor was composed of large polygonal cells with abundant granular eosinophilic cytoplasm and centrally located vesicular nuclei with prominent nucleoli (Figure 7).

Intra- and extra-cellular hyaline globules and bile pigment were also seen. Tumor cells were surrounded by thin lamellar collagenous bundles (Figure 8). Lymph-vascular invasion

was also noted. Sections of the liver mass were histopathologically identical.

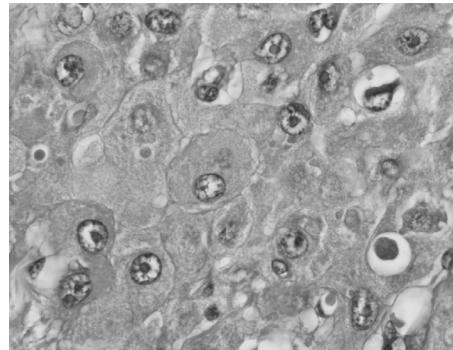


Fig. 7: Neoplastic cells with abundant eosinophilic and granular cytoplasm, and vesicular nuclei with prominent nucleoli are depicted. Also notice the round hyaline globules. H&E. 40x

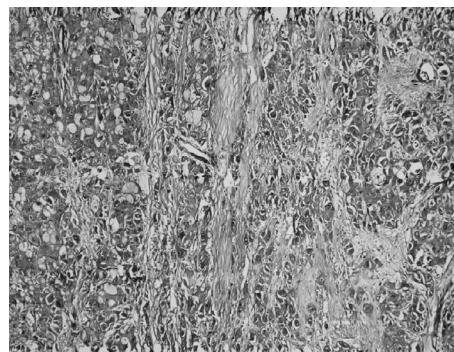


Fig. 8: Collagen bundles stained blue with this special stain spotlight the lamellar pattern of growth. Masson's trichrome. 10x

The aforementioned histopathologic findings are consistent with FL-HCC.¹⁷⁻¹⁹ Ancillary studies such as electron microscopy and immunohistochemistry may be indicated in equivocal cases for differentiating conventional HCC from its fibrolamellar variant. Canalicular pattern of staining with polyclonal CEA supports the hepatocellular origin of the neoplasm and therefore treatment is the same for both conventional and fibrolamellar variants of HCC.¹⁷ Cytokeratin-7 is strongly positive in FL-HCC, as was seen in our case. However, α -fetoprotein is usually negative in FL-HCC. Paradoxically, this marker was positive in our

case which probably led to an incorrect classification of the neoplasm by the first pathologist. A literature review shows that this marker may be positive in some unequivocal cases of FL-HCC.¹⁸

Pathological diagnosis

Fibrolamellar HCC.

Discussion of management and follow-up

Dr. R. Taslimi: The tumor usually presents as a large, single, well demarcated, lobulated and nonencapsulated intrahepatic mass.²⁰ Metastatic lymphadenopathy is present at the time of initial diagnosis of fibrolamellar carcinoma in 50-70% of patients. Lymph node metastases are found most often in the porta hepatis, hepatoduodenal ligament and peritoneum (as demonstrated in our patient), and they can have a CT scan appearance similar to that of intrahepatic lesions.^{21,22} Other distant metastases, such as those to the lungs, or more distant lymph nodes, also can be detected by CT scan. The lymph nodes are frequent sites for recurrent disease after surgical resection of primary lesions.

This patient was initially treated with anticoagulants (heparin and warfarin) and the DVT abated within days of initiating therapy. He subsequently underwent open abdominal surgery and the pelvic mass was completely excised. The pelvic mass adhered to adjacent omentum. The surgeon thought that the liver mass which extended to the porta hepatis was not resectable and therefore only biopsied the liver mass. Post-operatively, transarterial chemo-embolization (TACE) of the hepatic artery was performed three times. After his third cycle of TACE, and while he felt clinically well, the CT scan showed only partial response with a 50% decrease in size of the hepatic tumor. The pelvic mass disappeared and did not return, however, the mass at porta hepatis enlarged. Six months after the first surgery, he

underwent a second laparotomy which followed a left portal vein embolization by the radiologist. The left hepatic lobe and a small portion of the right hepatic lobe were resected, and the porta hepatis mass was removed. The patient had a steady recovery and was discharged from the hospital on postoperative day 12.

CONFLICT OF INTEREST

The authors declare no conflict of interest related to this work.

REFERENCES

1. Mergo, PJ, Ros, PR. Benign Lesions of the Liver In The Radiologic Clinics of North America 36(2). W.B. Saunders, Philadelphia 1998 p.319.
2. Dietrich CF, Mertens JC, Braden B, Schuessler G, Ott M, Ignee A. Contrast-enhanced ultrasound of histologically proven liver hemangiomas. *Hepatology* 2007;**45**:1139-45.
3. Colli A, Fraquelli M, Casazza G, Massironi S, Colucci A, Conte D, et al. Accuracy of ultrasonography, spiral CT, magnetic resonance, and alpha-fetoprotein in diagnosing hepatocellular carcinoma: a systematic review. *Am J Gastroenterol* 2006;**101**:513-23.
4. Carlson SK, Johnson CD, Bender CE, Welch TJ. CT of focal nodular hyperplasia of the liver. *AJR Am J Roentgenol* 2000;**174**:705-12
5. Lodhi S, Sarwari AR, Muzammil M, Salam A, Smego RA. Features distinguishing amoebic from pyogenic liver abscess: a review of 577 adult cases. *Trop Med Int Health* 2004;**9**:718-23.
6. Etemadi A , Hashemi H ,Golozar A , Ghassabian A , Zarei M , Dawsey S , et al. Cavernous hemangioma of the liver: factors affecting disease progression and outcome in general GI practice European Journal of gastroenterology and Hepatology 2011 (in Press).
7. Bioulac-Sage P, Rebouissou S, Sa Cunha A, Jeannot E, Lepreux S, Blanc JF, et al. Clinical, morphologic, and molecular features defining so-called telangiectatic focal nodular hyperplasias of the liver. *Gastroenterology* 2005;**128**:1211-8.
8. Lee MJ, Saini S, Hamm B, Taupitz M, Hahn PF, Senterre E, et al. Focal nodular hyperplasia of the liver: MR findings in 35 proved cases. *AJR Am J Roentgenol* 1991;**156**:317-20.
9. Hillaire S, Bonte E, Denninger MH, Casadevall N, Cadranet JF, Lebrec D, et al. Idiopathic non-cirrhotic intrahepatic portal hypertension in the West: a re-evaluation in 28 patients. *Gut* 2002;**51**:275-80.
10. Grazioli L, Federle MP, Brancatelli G, Ichikawa T, Olivetti L, Blachar A. Hepatic adenomas: imaging and pathologic findings. *Radiographics* 2001;**21**:877-92;

11. de Groen PC, Gores GJ, LaRusso NF, Gunderson LL, Nagorney DM. Biliary tract cancers. *N Engl J Med* 1999; **341**:1368-78.
12. Poustchi H, Sepanlou SG, Esmaili S, Mehrabi N, Ansary-moghadam A. Hepatocellular Carcinoma in the World and the Middle East. *Middle East J Dig Dis* 2010; **3**:31-41.
13. Klein WM, Molmenti EP, Colombani PM, Grover DS, Schwarz KB, Boitnott J, et al. Primary liver carcinoma arising in people younger than 30 years. *Am J Clin Pathol* 2005; **124**:512-8.
14. Moreno-Luna LE, Arrieta O, García-Leiva J, Martínez B, Torre A, Uribe M, et al. Clinical and pathologic factors associated with survival in young adult patients with fibrolamellar hepatocarcinoma. *BMC Cancer* 2005; **5**:142.
15. Blachar A, Federle MP, Ferris JV, Lacomis JM, Walts JS, Armfield DR, et al. Radiologists' Performance in the Diagnosis of Liver Tumors with Central Scars by Using Specific CT Criteria. *Radiology* 2002; **223**:532-9.
16. Stipa F, Yoon SS, Liao KH, Fong Y, Jarnagin WR, D'Angelica M, et al. Outcome of patients with fibrolamellar hepatocellular carcinoma. *Cancer* 2006; **106**:1331-8.
17. Chu PG, Ishizawa S, Wu E, Weiss LM. Hepatocyte antigen as a marker of hepatocellular carcinoma: an immunohistochemical comparison to carcinoembryonic antigen, CD10, and alpha-fetoprotein. *Am J Surg Pathol* 2002; **26**:978-88.
18. Berman MA, Burnham JA, Sheahan DG. Fibrolamellar carcinoma of the liver: an immunohistochemical study of nineteen cases and a review of the literature. *Hum Pathol* 1988; **19**:784-94.
19. Ferrell L. Liver Pathology: Cirrhosis, Hepatitis, and Primary Liver Tumors. Update and Diagnostic Problems. *Mod Pathol* 2000; **13**:679-704.
20. Marrannes J, Gryspeerdt S, Haspeslagh M, van Holsbeeck B, Baekelandt M, Lefere P. Fibrolamellar hepatocellular carcinoma in a 65-year-old woman: CT features. *JBR-BTR* 2005; **88**:237-40.
21. Liu S, Chan KW, Wang B, Qiao L. Fibrolamellar hepatocellular carcinoma. *Am J Gastroenterol* 2009; **104**:2617-24.
22. Craig JR, Peters RL, Edmondson HA, Omata M. Fibrolamellar carcinoma of the liver: a tumor of adolescents and young adults with distinctive clinico-pathologic features. *Cancer* 1980; **46**:372-9.