

Infant Boy with Microcephaly Gastroesophageal Reflux and Nephrotic Syndrome (Galloway-Mowat Syndrome): A Case Report

Majid Malaki ^{1*}, Mandana Rafeey²

1. Tabriz Children's Hospital, Tabriz University of Medical Sciences, Tabriz, Iran
2. Children Health Research Center, Tabriz Children's Hospital, Tabriz University of Medical Sciences, Tabriz, Iran

ABSTRACT

In this case report, we present the first diagnosed case of Galloway-Mowat syndrome in Iran. A 7 month old infant boy with microcephaly that had prominently stunted head growth after birth, gastroesophageal reflux, multiple craniofacial characters, hypothyroidism and nephrotic syndrome diagnosed at 5 months of age associated with rapid decline in renal function and heavy proteinuria in 2 months .

KEYWORDS :

Microcephaly; Nephrotic syndrome; Esophageal reflux; Galloway-Mowat syndrome.

Please cite this paper as :

M Malaki, M Rafeey. Infant Boy with Microcephaly Gastroesophageal Reflux and Nephrotic Syndrome (Galloway-Mowat Syndrome): A Case Report. *Middle East J Dig Dis* 2012;4:52-55.

INTRODUCTION

Galloway-Mowat syndrome, which is also known as microcephaly-hiatal hernia-nephrotic syndrome, is an extremely rare genetic disorder transmitted by an autosomal recessive trait. Recent linkage studies in two Algerian families identified a homozygous mutation in the *GMS1* gene. The protein encoded by this gene is expressed in many tissues, including brain and glomerular podocytes, and has yet an unknown function¹⁻³ characterized by varieties of physical and developmental abnormalities that usually appear before age^{3,4} Physical features may include an unusually small head (microcephaly) and additional abnormalities of the craniofacial area in addition to clusters of capillary damage in the kidneys (focal glomerulosclerosis and /or diffuse mesangial sclerosis), resulting in abnormal kidney function or nephrotic syndrome.⁵ Additional findings in this syndrome include seizures, hiatal hernia and deformities of the extremities.⁶ In this case report, we present the first Galloway-Mowat syndrome recognized in Iran with a constellation of renal, neurological and facial characters, in addition to gastroesophageal reflux.

* Corresponding Author:

Majid Malaki, MD
Tabriz Children's Hospital, Tabriz University of Medical Sciences, Postal Code: 5136735886, Tabriz, Iran
Tel: + 98 411 5262250
Fax: + 98 411 5262280
Email: madjidmalaki@gmail.com
Received: 20.Jun.2011
Accepted: 12.Aug.2011

CASE REPORT

A 7 month old male infant from consanguineous parents, born at the 40th week of gestation, had a birth weight of 2900 g (below -1 SD) and head circumference of 32 cm (-3SD) with microcephaly, dilated ventricles and decreased large cortical folds beside to some typical face features (Figure 1). There were no similar symptoms or previous abortions in the family history.

The infant had hypotonia, delayed developmental milestones with exaggerated tendon reflex and frequent regurgitation that caused him to come to our clinic for additional investigations. A barium swallow was performed that showed gastroesophageal reflux (Figure 2).

During the fifth month of life, gradually edema and ascites appeared due to heavy proteinuria, associated hyperlipidemia and hypoalbuminemia which were remarkable for nephrotic syndrome and hypothyroidism. In general, the patient's appearance was remarkable for microcephaly (head circumference at the 7th month of life was 37 cm, severely below -3SD) and his chest circumference was 40 cm. His weight with severe ascites was 6500g and height was 65 cm, both below -1SD. The patient's head was flat in the vertex and back (occiput) of his head with a narrow forehead, sparse hair, high arched palate, hyperthelorum, almond eyes, small jaw (microgenathia), large ears and strabismus (Figures 3).

The patient could not hold his neck, turn to his back or move in bed. He had severe proteinuria. The urine protein to creatinine ratio in a random sample was >100 (normal for age: < 0.7) and serum albumin dropped below 1.7 mg/dl with hyperlipidemia (triglycerides: 538 mg/dl, and cholesterol: 206 mg/dl) and decreased renal function (19 ml/min/1.73m² in 2 months). Torch panel study and complement level were within normal limits.

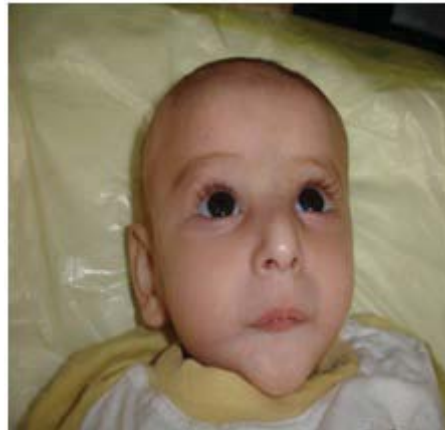

Fig 1: Microgenathia, Low set large ear, beak nose, high philtrum are prominent in this patient.

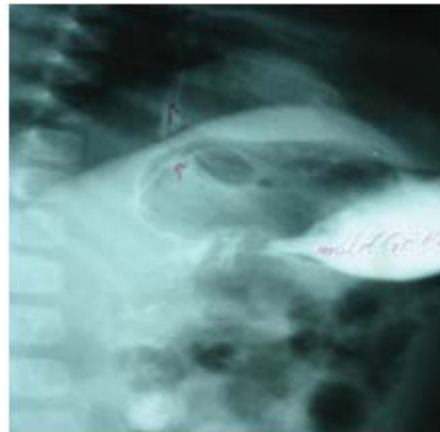


Fig 2: A barium swallow showed gastroesophageal reflux.

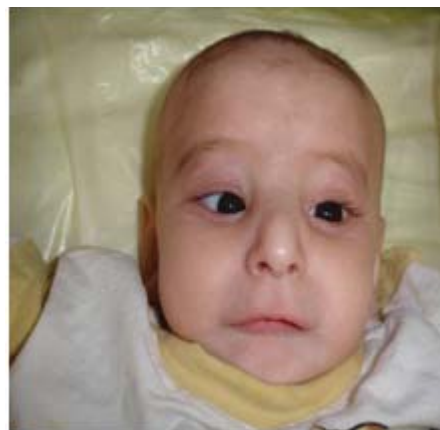

Fig 3: Sparse, almond eye, strabismus, high philtrum, beak nose are apparent.

DISCUSSION

This case report discussed an infant male who, for the first time in Iran, presented with hypotonia, microcephaly and slow growth of head circumference. His skull growth curve had a greater decrease in contrast to other physical growth indices. Additionally, he had frequent regurgitation that was diagnosed as gastroesophageal reflux, hypothyroidism and nephrotic syndrome, each of which appeared in turn.

Galloway-Mowat syndrome is a rare syndrome transmitted as an autosomal recessive pattern although nonsense mutation in the GMS1 gene has been suggested. Its gene defect has not been revealed completely.¹⁻³ It is known as a triad of microcephaly, nephrotic syndrome and hiatal hernia which was first described in 1968.⁷

During the past decades more than 40 infants having Galloway-Mowat syndrome type nephrotic syndrome together with primary microcephaly and mental retardation have been reported.⁸ Some published cases describe other extrarenal disorders such as hiatus hernia, dysmorphic features,⁴ and diaphragmatic defects.⁹ The age at onset of the nephrotic syndrome has varied from the first days of life to months, or even later in childhood.⁵ The early manifesting cases are often lethal while the later manifesting cases show a more variable renal prognosis including totally normal renal function, as reviewed by Meyers et al.⁸ However, in infants with Galloway-Mowat Syndrome, the outer layer of the brain may have folds that are abnormally small (microgyria), there may be a reduced number of folds that are larger than normal (pachygyria) or the folds may be absent or incompletely formed (lissencephaly). Developmental abnormalities in affected infants and children may include an inability to perform certain movements (motor), retarded mental activity (psychomotor retardation) and mental retardation.¹⁰

Our case was born from a term pregnancy with normal APGAR from consanguinous parents without any similar cases in his family. His hypotonia and microcephaly were prominent from birth due to brain atrophy and pachygyria with dilated ventricles and subarachnoid spaces associated with developmental and severe motor delay.

His frequent regurgitation lead to the diagnosis of gastroesophageal reflux as seen on barium swallow imaging. Lastly, hypothyroidism and proteinuria were diagnosed simultaneously in the 5th month, although his nephritic syndrome became more severe in the 7th month. His renal function, however, declined dramatically during 2 months. This confirmed other studies that early appearance of renal dysfunction was related to prognosis and decreased GFR has been seen more prominently in younger age groups who mostly have diffuse mesangial sclerosis.⁵

Although many facial characters have been described for Galloway-Mowat syndrome such as the shape of the skull, high arched palate, thin lips, saddle nose, almond eyes, sparse hair and microgenathia, all these features may not be seen in all cases.^{2,6,11,12} In this case, however, many of the facial hallmarks were present, such as: vertex that was flat at the top and back, high narrow forehead, sparse hair, strabismus, almond eyes, widely spaced eyes (ocular hypertelorism), small jaw bones (micrognathia), high arched palate roof, large low set ears, high length philtrum, narrow lips and deep nasal bridge.

Microcephaly that was accentuated after birth, craniofacial deformities, nephrotic syndrome, hypothyroidism and gastroesophageal reflux in addition to a rapid drop in glomerular filtration rate and increased proteinuria were hallmarks of our case that presented with Galloway-Mowat syndrome.

ACKNOWLEDGMENT

We express our appreciation to the authors

named and patients that came with us until now.

CONFLICT OF INTEREST

The authors declare no conflict of interest related to this work.

REFERENCES:

1. Dietrich A, Matejas V, Bitzan M, Hashmi S, Kiraly-Borri C, Lin SP, et al. Analysis of genes encoding laminin beta2 and related proteins in patients with Galloway-Mowat syndrome. *Pediatr Nephrol* 2008; **23**: 1779-86.
2. Srivastava T, Whiting JM, Garola RE, Dasouki MJ, Ruotsalainen V, Tryggvason K, et al. Podocyte proteins in Galloway-Mowat syndrome. *Pediatr Nephrol* 2001; **16**:1022-9.
3. Nadasdy T, Laszik Z, Lajoie G, Blick KE, Wheeler DE, Silva FG. Proliferative activity of cyst epithelium in human renal cystic diseases. *J Am Soc Nephrol* 1995; **5**:1462-8.
4. Cooperstone BG, Friedman A, Kaplan BS. Galloway - Mowat syndrome of abnormal gyral patterns and glomerulopathy. *Am J Med Genet* 1993; **47**:250-4.
5. Hazza I, Najada AH. Late-onset nephrotic syndrome in galloway-mowat syndrome: a case report. *Saudi J Kidney Dis Transpl* 1999; **10**:171-4.
6. Lin CC, Tsai JD, Lin SP, Tzen CY, Shen EY, Shih CS. Galloway-Mowat syndrome: a glomerular basement membrane disorder? *Pediatr Nephrol* 2001; **16**:653-7.
7. Galloway WH, Mowat AP. Congenital microcephaly with hiatus hernia and nephritic syndrome in two sibs. *J Med Genet* 1968; **5**:319-21.
8. Meyers KE, Kaplan P, Kaplan BS. Nephrotic syndrome, microcephaly, and developmental delay: three separate syndromes. *Am J Med Genet* 1999; **82**: 257-60.
9. Shapiro LR, Duncan PA, Farnsworth PB, Lefkowitz M. Congenital microcephaly, hiatus hernia and nephrotic syndrome: an autosomal recessive syndrome. *Birth Defects Orig Artic Ser* 1976; **12**:275-8.
10. Kozlowski PB, Sher JH, Nicastrì AD, Rudelli RD. Brain morphology in the Galloway syndrome. *Clin Neuropathol* 1989; **8**:85-91.
11. Cohen AH, Turner MC. Kidney in Galloway-Mowat syndrome: clinical spectrum with description of pathology. *Kidney Int* 1994; **45**:1407-15.
12. Sano H, Miyanoshita A, Watanabe N, Koga Y, Miyazawa Y, Yamaguchi Y, et al. Microcephaly and early-onset nephrotic syndrome-confusion in Galloway-Mowat syndrome. *Pediatr Nephrol* 1995; **9**:711-4.