

This work is licensed under a Creative Commons Attribution-NonCommercial 3.0 Unported License.



To review this article online, scan this QR code with your Smartphone



# Intestinal Obstruction in Acute Inhalational Toluene 2,4-Diisocyanate Gas Toxicity

S Shadnia<sup>1</sup>, M Ahmadimanesh<sup>2</sup>,  
M Ghazi-Khansari<sup>2</sup>, N Zamani<sup>1</sup>

## Abstract

The isocyanates are widely used as precursors of polyurethane products, as well as carbamate insecticides. Toluene 2,4-diisocyanate (TDI) is one of the most important commercially used isocyanates. Humans may be exposed to TDI by inhalation, ingestion, dermal and eye contact. TDI is a powerful irritant to the mucosal membranes of the gastrointestinal and respiratory tracts, eyes and the skin. Pulmonary manifestations, especially occupational asthma, are the predominant manifestations after TDI toxicity. Herein, we present intestinal obstruction as an extraordinary manifestation of acute TDI toxicity after occupational exposure. TDI toxicity may cause intestinal obstruction.

**Keywords:** Intestinal obstruction; Toluene 2,4 diisocyanate; Intestinal obstruction; General surgery; Toxicity

## Introduction

Toluene 2,4-diisocyanate (TDI) is extensively used in the production of inflexible sponge, covers such as dyes and elastomers, and for the protection of cement, wood, fiberglass, steel, and aluminum.<sup>1</sup> TDI is a clear, colorless to pale-yellow liquid with a pungent odor at room temperature.<sup>2</sup>

Humans may be exposed to TDI by inhalation, ingestion, dermal or eye contact.<sup>3</sup> It is a powerful irritant to the mucosal membranes and can cause severe allergy and asthma in those with chronic exposure; even mortality due to severe asthma has previously been reported. Pulmonary manifestations are the predominant signs and symptoms of acute TDI toxicity, but patients may present

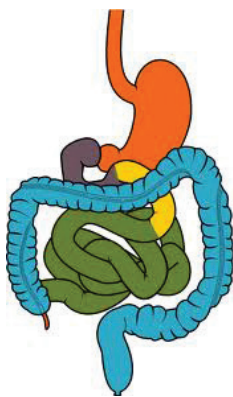
with ophthalmic, dermatological, and gastrointestinal manifestations as well.<sup>3</sup> Herein, we present an extraordinary manifestation of acute TDI toxicity after occupational exposure.

## Case Presentation

A 16-year-old male who had been working in a sponge production factory since 18 months before, referred to our center with nausea, vomiting, periumbilical pain, fever and chills. Problems had begun six days earlier when he had inhalational exposure to TDI for two hours. Soon after the exposure, he developed abdominal pain and diarrhea. Four days later (two days before admission), he developed constipation. At presentation, the patient had an oral temperature of 36.8 °C, blood

<sup>1</sup>Toxicological Research Center, Clinical Toxicology Department, Loghman Hakim Hospital Poison Center, Faculty of Medicine, Shahid Beheshti University of Medical Sciences, Tehran, Iran

<sup>2</sup>Pharmacology Department, School of Medicine, Tehran University of Medical Sciences, Tehran, Iran



Correspondence to Nasim Zamani, MD, Clinical Toxicology Department, Loghman Hakim Hospital Poison Center, Kamali St, South Karegar Ave, Tehran 1333431151, Iran

Tel/Fax: +98-21-5542-4041

E-mail: nasim.zamani@gmail.com

Received: Apr 3, 2013

Accepted: Jun 2, 2013

**Cite this article as:** Shadnia S, Ahmadimanesh M, Ghazi-Khansari M, Zamani N. Intestinal obstruction in acute inhalational toluene 2,4-diisocyanate gas toxicity. *Int J Occup Environ Med* 2013;4:164-166.

[www.SID.ir](http://www.SID.ir)

[www.theijoem.com](http://www.theijoem.com) Vol 4 Number 3; July, 2013

pressure of 100/70 mm Hg, pulse rate of 72 beats/min, and respiratory rate of 14 breaths/min. He was a known case of lymphoma and had been treated with cyclophosphamide, hydroxydaunorubicin, vincristine, and prednisolone almost six years earlier. He had also undergone an operative surgery due to gastric lymphoma. Twenty days before the exposure to TDI, his annual check-up for lymphoma was found normal.

In examination, the patient had a mild tenderness in deep palpation of the periumbilical area without radiation to other parts of the abdomen. There were no rebound tenderness and no abdominal distention. Bowel sounds had decreased. Abdominal sonography revealed that the abdomen was full of gas; he had splenomegaly and gall stones. The intestinal loops were dilated and filled with fluid, which could be due to intestinal obstruction and/or ileus. Abdominal CT showed disseminated dilatation of the intestinal loops, thickening of the ileal wall, and collapse of the distal colon reflecting a high probability of intestinal obstruction.

The patient had a mixed respiratory and metabolic alkalosis. He had mild hyponatremia (serum sodium = 131 mEq/L); other test results were within normal range.

With highly suspicious diagnosis of intestinal obstruction, the patient underwent operative surgery. In surgery, neither a mass indicating relapse of lymphoma nor severe adhesion causing obstruction was observed. However, mild adhesions due to previous surgery were noted. Enterolysis and milking of the distended loops toward the distal parts were done.

Six days later, the patient was discharged in good condition. At follow-up visit seven months later, he was completely fine.

## Discussion

The isocyanates are widely used as precursors of polyurethane products, as well as carbamate insecticides. The most common occupational disease associated with TDI is asthma. Acute TDI toxicity predominantly causes pulmonary problems including chemical bronchitis, hypersensitivity pneumonitis, asthma and acute nonspecific airway disease.<sup>4</sup> Intestinal obstruction is an extraordinary manifestation of acute and/or chronic TDI toxicity.

Diagnosis of the exact cause of intestinal obstruction in our patient could be difficult due to presence of many concurrent disorders. Our patient was young with a past history of lymphoma that had been treated with chemotherapy about six years before; he had undergone surgery due to stomach lymphoma. Although any of these could be considered the etiology of intestinal obstruction, we could not find any tumors, obvious intestinal adhesions, hernias, inflammatory bowel diseases, volvulus or intussusceptions in clinical and paraclinical evaluations and during the surgery. Hypokalemia, as another possible cause of ileus, was not detected, either.

The mechanisms through which TDI exerts its toxic effects are not well understood. TDI would invoke helper T cells with subsequent increase in neutrophil influx, interleukin-8, and interferon  $\gamma$  response.<sup>5</sup> Intestinal obstruction may happen due ileus caused by the interruption in the parasympathetic nervous system function after TDI exposure.<sup>6</sup> TDI poisoning itself may affect the intestinal smooth muscle and cause decreased bowel motility.

Although we could not find a definite cause and effect relationship between TDI exposure and intestinal obstruction, since the patient's signs and symptoms had just begun after the exposure, in the

For more information on methyl isocyanate exposure and atypical lymphocytosis see [www.thejjoem.com/ijournal/index.php/ijournal/article/view/238](http://www.thejjoem.com/ijournal/index.php/ijournal/article/view/238)

absence of all other possible causes of intestinal obstruction, and the patient had not been on any medications for the last six years, TDI toxicity can be considered as the most probable cause of intestinal obstruction in our patient. Further studies on people exposed to TDI are needed to elucidate this possible relationship.

**Conflicts of Interest:** None declared.

**Financial Support:** None

### References

1. CDC. Workplace safety and health topics; isocyanates. 2013, Available from [www.cdc.gov/niosh/topics/isocyanates](http://www.cdc.gov/niosh/topics/isocyanates) (Accessed March 31, 2013).
2. Toluene diisocyanates. 2013, Available from <http://ntp.niehs.nih.gov/ntp/roc/twelfth/profiles/Toluenediisocyanates.pdf> (Accessed March 31, 2013).
3. INCHEM. Toluene 2,4 diisocyanate. 2013, Available from <http://www.inchem.org/documents/pims/chemical/pim534.htm> (Accessed March 31, 2013).
4. Sullivan JB, Krieger GR. *Clinical Environmental Health and Exposures*. 2nd ed. Philadelphia, Lippincott Williams & Wilkins, 2001.
5. Wisniewski AV, Herrick CA, Liu Q, et al. Human gamma/delta T-cell proliferation and IFN-gamma production induced by hexamethylene diisocyanate. *J Allergy Clin Immunol* 2003;**112**:538-46.
6. Moshe S. Neuropathy in an artist exposed to organic solvents in paints: a case study. *Arch Environ Health* 2002;**57**:127-9.

### Guidelines for Filing a Competing Interest Statement

**Definition:** Conflict of interest (COI) exists when there is a divergence between an individual's private interests (competing interests) and his or her responsibilities to scientific and publishing activities such that a reasonable observer might wonder if the individual's behavior or judgment was motivated by considerations of his or her competing interests. COI in medical publishing affects everyone with a stake in research integrity including journals, research/academic institutions, funding agencies, the popular media, and the public.

COI may exist in numerous forms including financial ties, academic commitments, personal relationships, political or religious beliefs, and institutional affiliations. In managing COI, *The IJOEM* abides to the policy statement of the *World Association of Medical Editors (WAME)*. All authors should declare their COI, if any, during the manuscript submission. Reviewers are asked to declare their COI after they accept to review a manuscript. Editors should also declare their COI during handling of a manuscript.

Managing COI depends on disclosure because it is not possible to routinely monitor or investigate whether competing interests are present. COI disclosed by authors will be presented in the Editorial Board and an appropriate action will be taken. Those reviewers and Editors with COI will be excluded from the manuscript process. If competing interests surface from other sources after a manuscript is submitted or published, *The IJOEM* investigates allegations of COI and depending on their nature, appropriate actions will be taken if the allegations were found to be true. If a manuscript has been published and COI surfaces later, the journal will publish the results of the investigation as a correction to the article and ask the author to explain, in a published letter, why the COI was not revealed earlier.