



A Case Report of Cryptococcal Meningitis Presenting with Psychiatric Abnormalities

Mingyi Wo^{1,2}, Yongze Zhu², Tao Jiang², Youqi Ji¹, Yumei Ge^{2,*}

¹ School of Medical Technology and Information Engineering, Zhejiang Chinese Medical University, Hangzhou, Zhejiang, 310053, China

² Department of Clinical Laboratory, Laboratory Medicine Center, Zhejiang Provincial People's Hospital (Affiliated People's Hospital), Hangzhou Medical College, Hangzhou, Zhejiang 310014, China

* Corresponding author: Department of Clinical Laboratory, Laboratory Medicine Center, Zhejiang Provincial People's Hospital (Affiliated People's Hospital), Hangzhou Medical College, Hangzhou, Zhejiang 310014, China. Email: 11218070@zju.edu.cn

Received 2024 March 2; Revised 2024 April 12; Accepted 2024 April 16.

Abstract

Introduction: Cryptococcal infection is a significant pathogen causing meningitis, often manifesting early with psychiatric abnormalities. Due to the lack of other specific symptoms, these behavioral changes are frequently misattributed to other mental disorders or overlooked, leading to delays in diagnosis. This article reports on the diagnosis and treatment process of a patient with cryptococcal meningitis and summarizes the abnormal behavior in terms of mental and behavioral aspects of cryptococcal meningitis patients, providing a reference for the diagnosis and treatment of cryptococcal meningitis.

Case Presentation: We present a case of cryptococcal meningitis where the initial abnormal behaviors were attributed to stress, resulting in a lack of emphasis on cryptococcal treatment and subsequent failure of standard anti-infective therapy. Ultimately, we discovered abnormalities through cerebrospinal fluid examination and conducted targeted tests for *Cryptococcus*, resulting in a clear diagnosis and timely adoption of appropriate treatment measures. The patient's condition improved, and they were discharged.

Conclusions: It is crucial for clinicians to deepen their understanding of cryptococcal meningitis. When encountering patients with unexplained fever accompanied by psychiatric and behavioral changes, a high suspicion for cryptococcal infection should be maintained.

Keywords: *Cryptococcus*, Meningitis, Mental and Behavioral Abnormalities, Early Diagnosis, Treatment

1. Introduction

The *Cryptococcus* genus is a diverse group of fungi, with over 100 species identified to date, yet only a few of them are known to cause human diseases. Unlike other opportunistic pathogenic fungi, *Cryptococcus* is a deadly fungus with a high mortality rate once infection occurs (1, 2). In the late 19th century, the first documented cases of diseases in humans and animals caused by *Cryptococcus* were reported (3, 4). Subsequently, from 1940 to 1960, the incidence of cryptococcosis in Africa began to rise, which was believed to be linked to the emergence of the human immunodeficiency virus (HIV) (5). For a prolonged period, cryptococcosis was considered an HIV-associated disease. In reality, cryptococcosis does account for one-fifth of AIDS-related deaths (6).

Cryptococcus has the ability to cause pulmonary or disseminated infections, with cryptococcal meningitis being one of the most severe diseases it causes. It is estimated that there are 223,000 new cases annually, leading to the deaths of 181,100 HIV-infected individuals (7). With the improvement in diagnostic capabilities and advancements in immunotherapy, an increasing number of cases of cryptococcosis are being observed in non-HIV patients, with reports indicating that up to 20% of cases occur in immunocompetent individuals (8). The clinical manifestations of cryptococcal meningitis include acute or subacute fever, headache, vomiting, and focal neurological deficits (9), which lack distinct characteristics, posing a challenge to early diagnosis.

Here, we present a case of cryptococcal meningitis in a patient who exhibited noticeable psychiatric abnormalities before diagnosis. Through the

description of this case, our aim is to enhance the understanding of the clinical manifestations and management of cryptococcal meningitis, thus aiding in the early diagnosis of this condition.

2. Case Presentation

2.1. Clinical Feature

A male patient in his 50s developed fever symptoms 10 days ago and underwent examination and treatment at a local hospital 7 days ago. He was diagnosed with infectious fever and received combination therapy with benzylpenicillin sodium and levofloxacin, but showed no improvement. During the treatment, he continued to experience recurrent fevers, accompanied by headaches, occasional cognitive impairment, nocturnal restlessness, irritability, and even aggression. Seeking further treatment, the patient was transferred to Zhejiang Provincial People's Hospital.

Upon reviewing his medical history, we discovered that the patient had been diagnosed with nasopharyngeal cancer two years ago, had undergone chemotherapy, and subsequently developed lung metastases, receiving long-term immunotherapy since then. Previous behavioral abnormalities were attributed to the stress of cancer. After admission, in view of the patient's abnormal mental performance, we consulted clinical psychologists, who diagnosed him with an organic mental disorder. In addition, we conducted a comprehensive blood and cerebrospinal fluid (CSF) examination, with results shown in Table 1. Elevated infection markers combined with the results of cryptococcal capsular antigen testing (BIO-KONT, WK3023Q) led us to suspect cryptococcal infection in the patient. Considering his abnormal behavioral symptoms, we tentatively diagnosed him with cryptococcal meningitis.

2.2. Imaging Examination

The patient underwent a head magnetic resonance imaging (MRI) examination, which showed severe artifacts. Scattered abnormal signal shadows were observed in the semioval area on both sides and the lateral ventricle. T1WI showed a slightly low signal, while T2WI and FLAIR showed a high signal, with blurred boundaries. There was no edema or mass effect around the lesion, and no obvious abnormal enhancement was observed in the enhanced scan. The third ventricle and lateral ventricle were slightly enlarged, and the cerebral pool and sulcus were slightly widened. The midline structure was not displaced (Figure 1).

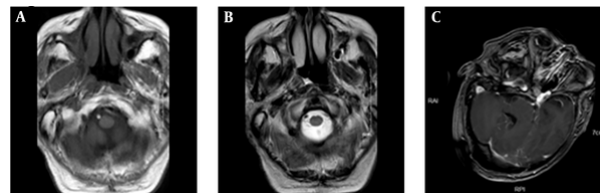


Figure 1. MRI images of the patient's head

2.3. Etiological Examination

Following the detection of positivity for serum capsule antigen, cerebrospinal fluid was collected from the lumbar region of the patient for examination. Gram staining revealed circular yeast-like fungi under the microscope (Figure 2A), while India ink staining exhibited thick capsules surrounding the fungal cells (Figure 2B). The cerebrospinal fluid was inoculated onto Sabouraud dextrose agar medium using a loop, and after 48 hours of incubation at 37°C, smooth white yeast-like colonies were observed. Additionally, the isolated colony was identified as *Cryptococcus neoformans* using matrix-assisted laser desorption/ionization time-of-flight mass spectrometry (MALDI-TOF MS). The Clinical and Laboratory Standards Institute (CLSI) has developed standardized methods for broth microdilution antifungal susceptibility testing of both yeasts and molds (10). We obtained the antibiotic sensitivity of this strain of *C. neoformans* using this method (Table 2).



Figure 2. The microscopic morphology of *Cryptococcus* after different staining techniques was examined. A, after Gram staining, some circular yeast like fungi were found under the microscope; B, pink staining revealed a thick capsule surrounding the pathogen; C, white smooth colonies grow at 37°C after CSF inoculation.

2.4. Treatment and Outcome

Upon admission, the patient was administered ceftriaxone sodium 0.2 g intravenously for standard anti-infective treatment. Following a confirmed diagnosis, the antibiotic was switched to amphotericin

Table 1. Laboratory Examination Results of the Patient

Laboratory Indicators	Result	Reference Range
Lymphocyte count (PB)	0.45 × 10 ⁹ /L ↓	1.1 - 3.2 × 10 ⁹ /L
C-reactive protein (PB)	107.3 mg/L ↑	≤ 10.0 mg/L
Serum total protein	57.3 g/L ↓	65.0 - 85.0 g/L
Serum albumin	32.9 g/L ↓	40.0 - 55.0 g/L
Serum procalcitonin	0.55 ng/mL ↑	≤ 0.25 ng/mL
CD3+ cell count (PB)	305 × 10 ⁶ /L ↓	952 - 2128 × 10 ⁶ /L
CD19+ cell count (PB)	43 × 10 ⁶ /L ↓	173 - 447 × 10 ⁶ /L
CD3+CD4+ cell count (PB)	70 × 10 ⁶ /L ↓	537 - 1282 × 10 ⁶ /L
CD3+CD8+ cell count (PB)	219 × 10 ⁶ /L ↓	258 - 1042 × 10 ⁶ /L
Pan's test (CSF)	Positive	Negative
Protein quantification (CSF)	172.5 mg/dL ↑	≤ 45.0 mg/dL
Glucose quantification (CSF)	1.24 mmol/L ↓	2.50 - 4.50 mmol/L
Lactic dehydrogenase (CSF)	54 U/L ↑	8 - 32 U/L
Chloride (CSF)	115.8 mmol/L ↓	120-132 mmol/L
Lactic acid (CSF)	7.7 mmol/L ↑	0.5 - 1.7 mmol/L
Serum <i>Cryptococcus</i> capsule antigen test	Positive	Negative

Abbreviations: PB, peripheral blood.

Table 2. Drug Sensitivity Results of the *Cryptococcus Neoformans*

Antibiotic	Method	Result	Break Point	Sensitivity Level
5-fluorocytosine	MIC	≤ 4 µg/mL	-	S
Itraconazole	MIC	≤ 0.125 µg/mL	≤ 0.25	S
Voriconazole	MIC	≤ 0.06 µg/mL	≤ 0.25	S
Amphotericin b	MIC	≤ 0.5 µg/mL	≤ 0.5	S
Fluconazole	MIC	≤ 1 µg/mL	≤ 8	S

Abbreviations: MIC, minimum inhibitory concentration test strip method; S, Sensitive.

B 3 mg intravenously, gradually increasing to 25 mg by the 6th day (the dose increased daily: 3/5/10/15/20/25 mg). Additionally, the patient's family was instructed to purchase flucytosine tablets for combined antifungal therapy. On the 13th day of hospitalization, treatment was switched to 400 mL (0.2 g/100 mL) fluconazole intravenous infusion. By the 16th day, the patient showed improvement in symptoms with no headaches, no delirium, and no hallucinations. Consequently, it was agreed for the patient to return to the local hospital for further treatment, with a recommendation to continue the original regimen of fluconazole combined with flucytosine for an additional 4 weeks (Figure 3).

3. Discussion

In the latest list of pathogenic fungi issued by the World Health Organization (WHO), *Cryptococcus* has

been classified as a crucial pathogen. It can enter the human body through the respiratory tract, depositing in the alveoli, and then further disseminate to skin tissues, internal organs, and the central nervous system, where the most severe clinical manifestation known as cryptococcal meningitis is observed (11). *Cryptococcus neoformans* and *C. gattii* are the main pathogenic fungi, primarily affecting HIV-infected patients (1). However, with advancements in medical technology in recent years, an increasing number of patients are able to receive organ transplants, immunotherapy, and other medical interventions. Consequently, the population with compromised immune systems is expanding, drawing attention to the issue of non-AIDS patients being infected with fungal pathogens.

Currently, there are well-established and specific methods for the detection of *Cryptococcus*—capsular

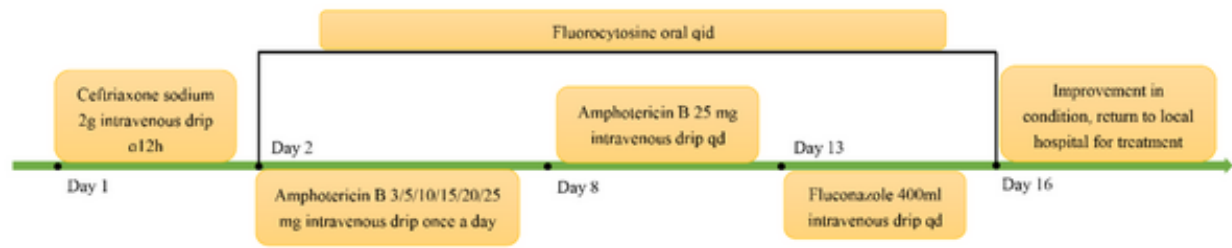


Figure 3. Patient treatment timeline

Table 3. Reported Psychiatric Abnormalities in Patients with Cryptococcal Meningitis

Year	Country	Age	Gender	Abnormal Mental Manifestations	Reference
2009	USA	62	Male	Headaches, dizziness, blurry vision, imbalance, become dull, frequent cursing, shouting at noisy people, gritting one's teeth, getting angry when disliked, having a hot temper, not brushing teeth, not taking a shower, and showing a lack of personal hygiene	(14)
2009	China	70	Male	Depressed mood, loss of interest, fatigue, poor concentration, pessimistic thought, initial insomnia, poor appetite, severe depression	(15)
2011	India	49	Male	Psychosis	(16)
2013	Singapore	30	Male	Solitary personality, ignoring others, anxiety, headache, walking like a zombie, hallucinations	(17)
2014	China	78	Male	Decreased sleep, elevated mood, increased energy, hyperactivity, racing thoughts, and eccentric behaviour (such as being stark naked at home)	(18)
2017	USA	45	Male	Yelling, combative, and not answering questions or following commands	(13)
2020	USA	26	Male	Blurred vision and confused language, unclear consciousness	(19)
2020	USA	30	Male	Headache, blurry vision, hearing loss, and gait imbalance	
2023	USA	55	Male	Progressive headache with unclear consciousness	(20)
2023	USA	73	Male	Headaches, progressive weakness, fatigue, and worsening confusion	(21)
2023	USA	44	Male	Elevated intracranial pressure and stubborn headache	
2024	China	50s	Male	Headaches, occasional cognitive impairment, nocturnal restlessness, irritability, and even aggression	Our report

antigen testing (serum or cerebrospinal fluid), which can serve as a direct indicator for diagnosing cryptococcal infection (12). Due to the lack of infection-specific clinical manifestations, cryptococcal infection is often not considered immediately when patients are admitted for infection, leading to delayed diagnosis. Hence, early diagnosis remains a significant challenge. The patient we report on presented with elevated inflammatory markers (high-sensitivity C-reactive protein, procalcitonin) on the day of admission. Additionally, abnormal lymphocyte levels were noted, including a deficiency in CD19+ B lymphocytes, CD4+ T lymphocytes, and CD8+ T lymphocytes. This immunocompromised state was attributed to cancer and prolonged immunotherapy, predisposing the patient to cryptococcal infection. Of particular concern is the patient's long-standing mental abnormalities prior to admission, characterized by recurring headaches and occasional hallucinations. Furthermore,

the patient exhibited personality changes, irritability, and even instances of physical aggression.

In the study by Seelig et al., patients exhibited similar psychiatric symptoms, initially suspected to be drug-induced mental disorders (13). In our study, these changes were initially attributed to significant psychological stress following the cancer diagnosis. Here, we have collected and summarized some case reports on patients with cryptococcal meningitis (Table 3). We found that cryptococcal meningitis mostly occurs in male patients, and they all exhibit varying degrees of mental abnormalities such as headaches, consciousness disorders, irritability, strong aggression, and hallucinations. Therefore, when managing patients with cryptococcal meningitis, such psychiatric behavioral anomalies should be carefully considered, especially in cases without a history of psychiatric illness or relevant drug usage.

In June 2022, WHO released new clinical management guidelines for cryptococcal meningitis, strongly recommending the use of single high-dose liposomal amphotericin B therapy combined with 2-week flucytosine and fluconazole as the preferred treatment approach (22). Liposomal amphotericin B is a common first-line drug for managing co-infections in HIV-infected individuals. However, in many low- and middle-income countries with public healthcare systems, the cost of this medication can pose a significant economic burden (23). Therefore, early and prompt diagnosis, proper guidance on medication use, and prevention of disease progression are crucial.

3.1. Conclusions

Cryptococcal meningitis is an extremely fatal disease, characterized by a high mortality rate. However, early diagnosis remains challenging due to the absence of clear clinical manifestations. The psychiatric and behavioral abnormalities exhibited in the early stages are often misdiagnosed as other mental disorders or simply attributed to stress, leading to delayed diagnosis and exacerbating the treatment burden. Therefore, the psychiatric and behavioral presentations in the diagnosis of cryptococcal meningitis should be emphasized.

Acknowledgements

We thank all members of the microbiology laboratory of Zhejiang Provincial People's Hospital for their help in the collection of clinical data.

Footnotes

Authors' Contribution: Study concept and design: Mingyi Wo; acquisition of data: Yongze Zhu; Analysis and interpretation of data: Tao Jiang; Drafting of the manuscript: Youqi Ji; Critical revision of the manuscript for important intellectual content: Yumei Ge.

Conflict of Interests Statement: The authors report no conflicts of interest.

Data Availability: The data presented in this study are uploaded during submission as a supplementary file and are openly available for readers upon request.

Ethical Approval: This study was supported by the Ethics Committee of Zhejiang People's Hospital (Ethics Committee Approval of Biomedical Research Involving Humans, Approval No. : 2022JS008) and was carried out

in accordance with the ethical standards of the Declaration of Helsinki.

Funding/Support: This study was supported by the [New Project of Zhejiang Provincial People's Hospital entitled "Construction of Rapid Nucleic Acid Detection Platform for Invasive Fungi"] under Grant [number 20211214].

Informed Consent: Written and informed consent was obtained from the patient for publication of this case report and any accompanying images.

References

- Hagen F, Khayhan K, Theelen B, Kolecka A, Polacheck I, Sionov E, et al. Recognition of seven species in the *Cryptococcus gattii*/*Cryptococcus neoformans* species complex. *Fungal Genet Biol.* 2015;78:16-48. [PubMed ID: 25721988]. <https://doi.org/10.1016/j.fgb.2015.02.009>.
- Gupta S, Paul K, Kaur S. Diverse species in the genus *Cryptococcus*: Pathogens and their non-pathogenic ancestors. *IUBMB Life.* 2020;72(11):2303-12. [PubMed ID: 32897638]. <https://doi.org/10.1002/iub.2377>.
- Barnett JA. A history of research on yeasts 14: medical yeasts part 2, *Cryptococcus neoformans*. *Yeast.* 2010;27(11):875-904. [PubMed ID: 20641025]. <https://doi.org/10.1002/yea.1786>.
- Springer DJ, Chaturvedi V. Projecting global occurrence of *Cryptococcus gattii*. *Emerg Infect Dis.* 2010;16(1):14-20. [PubMed ID: 20031037]. [PubMed Central ID: PMC2874352]. <https://doi.org/10.3201/eid1601.090369>.
- Ohnishi YO, Pantoja ASL, Abraao LSO, Alves NG, Ohnishi MDO, Libonati RMF, et al. Cryptococcal meningitis in patients with and without acquired immunodeficiency. *Acta Trop.* 2022;227:106228. [PubMed ID: 34864000]. <https://doi.org/10.1016/j.actatropica.2021.106228>.
- Rajasingham R, Govender NP, Jordan A, Loyse A, Shroufi A, Denning DW, et al. The global burden of HIV-associated cryptococcal infection in adults in 2020: a modelling analysis. *Lancet Infect Dis.* 2022;22(12):1748-55. [PubMed ID: 36049486]. [PubMed Central ID: PMC9701154]. [https://doi.org/10.1016/S1473-3099\(22\)00499-6](https://doi.org/10.1016/S1473-3099(22)00499-6).
- Rajasingham R, Smith RM, Park BJ, Jarvis JN, Govender NP, Chiller TM, et al. Global burden of disease of HIV-associated cryptococcal meningitis: an updated analysis. *Lancet Infect Dis.* 2017;17(8):873-81. [PubMed ID: 28483415]. [PubMed Central ID: PMC5818156]. [https://doi.org/10.1016/S1473-3099\(17\)30243-8](https://doi.org/10.1016/S1473-3099(17)30243-8).
- Stack M, Hiles J, Valinetz E, Gupta SK, Butt S, Schneider JG. Cryptococcal Meningitis in Young, Immunocompetent Patients: A Single-Center Retrospective Case Series and Review of the Literature. *Open Forum Infect Dis.* 2023;10(8):ofad420. [PubMed ID: 37636518]. [PubMed Central ID: PMC10456216]. <https://doi.org/10.1093/ofid/ofad420>.
- Pyrgos V, Seitz AE, Steiner CA, Prevots DR, Williamson PR. Epidemiology of cryptococcal meningitis in the US: 1997-2009. *PLoS One.* 2013;8(2): e56269. [PubMed ID: 23457543]. [PubMed Central ID: PMC3574138]. <https://doi.org/10.1371/journal.pone.0056269>.
- Wiederhold NP. Antifungal Susceptibility of Yeasts and Filamentous Fungi by CLSI Broth Microdilution Testing. *Methods Mol Biol.* 2023;2658:3-16. [PubMed ID: 37024691]. https://doi.org/10.1007/978-1-0716-3155-3_1.
- Hitchcock M, Xu J. Analyses of the Global Multilocus Genotypes of the Human Pathogenic Yeast *Cryptococcus neoformans* Species

- Complex. *Genes (Basel)*. 2022;**13**(11). [PubMed ID: 36360282]. [PubMed Central ID: PMC9691084]. <https://doi.org/10.3390/genes13112045>.
12. Donnelly JP, Chen SC, Kauffman CA, Steinbach WJ, Baddley JW, Verweij PE, et al. Revision and update of the consensus definitions of invasive fungal disease from the European Organization for Research and Treatment of Cancer and the mycoses study group education and research consortium. *Clin Infect Dis*. 2020;**71**(6):1367-76. [PubMed ID: 31802125]. [PubMed Central ID: PMC7486838]. <https://doi.org/10.1093/cid/ciz1008>.
 13. Seelig S, Ryus CR, Harrison RF, Wilson MP, Wong AH. Cryptococcal meningoencephalitis presenting as a psychiatric emergency. *J Emerg Med*. 2019;**57**(2):203-6. [PubMed ID: 31014972]. <https://doi.org/10.1016/j.jemermed.2019.03.016>.
 14. Hoffmann M, Muniz J, Carroll E, De Villasante J. Cryptococcal meningitis misdiagnosed as Alzheimer's disease: complete neurological and cognitive recovery with treatment. *J Alzheimers Dis*. 2009;**16**(3):517-20. [PubMed ID: 19276545]. <https://doi.org/10.3233/JAD-2009-0985>.
 15. Hsueh KL, Lin PY. Treatment-resistant depression prior to the diagnosis of cryptococcal meningitis: a case report. *Gen Hosp Psychiatry*. 2010;**32**(5):560 e9-10. [PubMed ID: 20851285]. <https://doi.org/10.1016/j.genhosppsych.2010.06.002>.
 16. Kumar A, Gopinath S, Dinesh KR, Karim S. Infectious psychosis: cryptococcal meningitis presenting as a neuropsychiatry disorder. *Neurol India*. 2011;**59**(6):909-11. [PubMed ID: 22234213]. <https://doi.org/10.4103/0028-3886.91379>.
 17. Jacob R, Zhimin Z, Rayapureddy S, Isaacs RT. Cryptococcal meningitis presenting as acute psychosis in a HIV positive patient. *Asian J Psychiatr*. 2013;**6**(6):624-5. [PubMed ID: 24309889]. <https://doi.org/10.1016/j.ajp.2013.06.002>.
 18. Chou PH, Ouyang WC, Lan TH, Chan CH. Secondary mania due to AIDS and cryptococcal meningitis in a 78-year-old patient. *Psychogeriatrics*. 2016;**16**(2):135-8. [PubMed ID: 25919146]. <https://doi.org/10.1111/psyg.12127>.
 19. Polk C, Meredith J, Kuprenas A, Leonard M. Cryptococcus meningitis mimicking cerebral septic emboli, a case report series demonstrating injection drug use as a risk factor for development of disseminated disease. *BMC Infect Dis*. 2020;**20**(1):381. [PubMed ID: 32460792]. [PubMed Central ID: PMC7254669]. <https://doi.org/10.1186/s12879-020-05108-1>.
 20. El-Atoum M, Hargarten JC, Park YD, Ssebambulidde K, Ding L, Chittiboina P, et al. Persistent neurological symptoms and elevated intracranial pressures in a previously healthy host with cryptococcal meningitis. *BMC Infect Dis*. 2023;**23**(1):407. [PubMed ID: 37316806]. [PubMed Central ID: PMC10265895]. <https://doi.org/10.1186/s12879-023-08349-y>.
 21. Hargarten JC, Anjum SH, Ssebambulidde K, Park YD, Vaughan MJ, Scott TL, et al. Tocilizumab as a potential adjunctive therapy to corticosteroids in cryptococcal post-infectious inflammatory response syndrome (PIIRS): a report of two cases. *J Clin Immunol*. 2023;**43**(8):2146-55. [PubMed ID: 37814084]. <https://doi.org/10.1007/s10875-023-01592-7>.
 22. World Health Organization. *Guidelines for Diagnosing, Preventing and Managing Cryptococcal Disease Among Adults, Adolescents and Children Living with HIV [Internet]*. Geneva; 2022. Available from: <https://www.ncbi.nlm.nih.gov/books/NBK581832/>.
 23. Burry J, Casas CP, Ford N. Access to Medicines for Treating People With Cryptococcal Meningitis. *Clin Infect Dis*. 2023;**76**(3):e773-5. [PubMed ID: 36037037]. [PubMed Central ID: PMC7614173]. <https://doi.org/10.1093/cid/ciac689>.