



ORIGINAL ARTICLE

Visual Outcomes in Acute Methyl Alcohol poisoning and its Biochemical Predictors: A Hospital-Based Study in Eastern India

Suchismita Mishra, Pradeep Kumar Panigrahi*, Priya Gupta, Keya Chakrabarti

Department of Ophthalmology, Institute of Medical Sciences & SUM Hospital, Siksha O Anusandhan (deemed to be University), 8-Kalinga Nagar, Bhubaneswar-751003

(Received: 14 February 2022

Accepted: 26 October 2022)

KEYWORDS

Methyl alcohol;
Methanol;
Metabolic acidosis;
Hemodialysis;
Anion gap

ABSTRACT: Acute methyl alcohol toxicity can lead to severe ocular morbidity. In the present study, we aimed to observe the ocular outcomes in acute methyl alcohol poisoning and determine the biochemical predictors of the final visual outcome. This was a hospital-based descriptive study conducted on 19 consecutive patients of acute methanol poisoning presenting to the Ophthalmology department of a tertiary care multispecialty hospital in Eastern India. Thorough clinical history was obtained in each case. A comprehensive ocular examination was done. Details of systemic treatment provided were obtained in all cases. Nineteen patients were included in the study. All patients were males. The average age of patients was 35.84 ± 9.25 years. All patients complained of bilateral blurring of vision. One patient had severe vision loss with visual acuity of hand movements in both eyes. Colour vision was absent in 7 eyes (18.41%), and impaired in 5 eyes (13.15%). Disc edema was seen in 5 eyes (13.15%). High anion gap metabolic acidosis was seen in 13 (78.9%) cases. Serum bicarbonate level was $< 22 \text{ mmol L}^{-1}$ in 13 (68.42%) patients. Eleven (57.89%) patients underwent hemodialysis. The presence of metabolic acidosis, high anion gap, and high base deficit were associated with poor visual acuity and defective color vision both at the initial presentation and final follow-up. Metabolic acidosis, high anion gap, and base deficit at the time of presentation are associated with defective color vision, abnormal pupillary reaction, and poor vision both during initial and final visits. Prompt management of these metabolic abnormalities can decrease ocular morbidity and improve the final visual outcomes.

INTRODUCTION

Acute methyl alcohol (methanol) poisoning occurs most commonly due to the intake of adulterated drinks [1]. It is an uncommon but extremely hazardous intoxication. The adverse effects are due to the accumulation of formic acid, a metabolite of methanol poisoning. On ingestion, methanol is quickly absorbed from the gut and rapidly metabolized in the liver to formaldehyde by the enzyme alcohol dehydrogenase. This reaction is slower than the next step, the conversion of formaldehyde to formic acid by

the enzyme aldehyde dehydrogenase. The metabolism of formic acid in the body is very slow, causing its accumulation ultimately leading to metabolic acidosis [2]. Ocular findings in acute methanol poisoning include photophobia, blurred vision, painful ocular movements, sluggish pupillary reactions, and optic disc edema with tortuous retinal blood vessels [3]. There are reports of circumscribed myelin damage behind the lamina cribrosa of the optic nerve [4]. Electrophysiological changes

*Corresponding author: doc.pkp25@gmail.com (P. Kumar Panigrahi)
DOI: 10.22034/jchr.2022.1952634.1506

following acute methanol ingestion suggest damage to photoreceptors, Muller cells, and the retrolaminar portion of the optic nerve [3]. Systemic and ocular manifestations correlate with the severity of metabolic acidosis. So treatment is directed towards rapid correction of acidosis by parenteral administration of sodium bicarbonate and hemodialysis. Hemodialysis corrects metabolic acidosis and helps in eliminating methanol and formic acid [5].

In the present study, we aimed to study the visual outcomes following acute methyl alcohol poisoning and determine the biochemical predictors which can be associated with poor visual outcomes.

MATERIALS AND METHODS

The present study is a descriptive, longitudinal, hospital-based study conducted on 19 consecutive patients of acute methanol poisoning. The study was conducted in the department of Ophthalmology of a tertiary care multispecialty hospital in Eastern India. The study was conducted in collaboration with the departments of emergency medicine, internal medicine, and nephrology of the same hospital. Institutional ethical committee clearance was obtained before starting the study. The study followed the basic tenets of the Helsinki declaration and all patients involved in the study provided informed consent before the start of the study.

There was an outbreak of acute methanol poisoning following the intake of adulterated alcohol in the district of Khurda, Odisha involving 50 cases. Twenty patients were brought to the casualty department of our hospital. Acute methanol poisoning was diagnosed based on the history of adulterated alcohol intake and clinical signs and symptoms. Patients were referred to the department of Ophthalmology after receiving initial treatment in the emergency medicine department.

Thorough clinical history, including the amount of alcohol intake and ocular symptoms, were obtained from each patient or their kin (in case of an unreliable patient). Comprehensive ocular examination was done in all cases by 2 ophthalmologists, one being a neuro-ophthalmologist (SM) and the other being a retina specialist (PKP). Visual

acuity (VA) and color vision (CV) assessment was done using Snellen's and Ishihara's charts (38 plates edition 1994) respectively. The pupillary reaction was checked using an indirect ophthalmoscope. A slit lamp examination of the anterior segment was done in each case. The intraocular pressure (IOP) was measured using Goldmann's applanation tonometer. The retinal examination was done using an indirect ophthalmoscope and 78 diopters slit lamp biomicroscopy after dilating the pupils with a combination of tropicamide (0.5%) and phenylephrine (10%). Visual field charting using Humphrey field analyzer745i (Carl Zeiss Meditec, Germany) using the full threshold 30-2 program was done in co-operative patients. Clinical and laboratory investigations were done in all cases which included arterial blood gas analysis (ABG), serum electrolytes, serum bicarbonate, liver, and renal function tests, and random blood sugar (RBS). Serum methanol estimation and formate analysis could not be done due to the non-availability of the test procedures in our hospital.

All patients with clinical and laboratory evidence of systemic acidosis received intravenous sodium bicarbonate infusion (1-2 meq/kg) aimed at achieving full correction of acidosis and intravenous Fomepizole in a bolus dose of 15mg/kg followed by 10 mg/kg 12 hourly. They also received intravenous folinic acid (50 mg every 6 hours), thiamine hydrochloride (100 mg IV), pyridoxine hydrochloride (50 mg IV), and methylcobalamin supplementation. Hemodialysis was done in patients with severe metabolic acidosis and optic nerve involvement. Patients with optic disc changes received intravenous methylprednisolone (1 gram in 300 ml normal saline) followed by oral steroids (1 mg kg⁻¹) for 14 days.

Patients were followed up 1 week, 1 month, and 3 months following the initial presentation. VA, CV, pupillary reaction, and fundus evaluation was done during each visit.

Statistical analysis

Data obtained were entered into a Microsoft excel sheet. Results have been denoted in the form of mean, standard deviation and percentages wherever appropriate. Student t-test was used to test the association between categorical

variables. A p value less than 0.05 was considered statistically significant. Statistical analysis was done using SPSS software version 21 (Chicago, IL, USA).

RESULTS

In the present study, 20 patients got admitted to the emergency medicine department of our hospital with a history of intake of adulterated alcohol. Nineteen patients were included in the study. One patient was excluded as he was unconscious and ocular evaluation was not possible. All patients included in the study were males. The mean age of the patients was 35.84 ± 9.25 years (range 17 to 50 years). All patients complained of blurring of vision which was sudden in onset. A Gross decrease in vision was noted in one patient (P6) which was hand movements bilaterally. VA of 4 eyes was between 20/400- <20/60 and rest of 32

eyes vision was between 20/60-20/20. IOP was within the normal range in all patients.

Color vision could be recorded, in 18 patients. It was normal in 24 eyes (63.15%), absent in 7 eyes (18.41%), and impaired in 5 eyes (13.15 %) In one patient color vision could not be recorded due to very poor vision. Pupil diameter was around 3-4 mm with sluggish reaction in 8 patients (P2, P3, P4, P5, P10, P11, P13, P 17). One patient (P6) had a pupil size of 5-6mm which was ill-sustained. Visual field charting could be done in 13 (68.42%) of the cases and field defects were seen in 5 eyes (13.15 %). Defects were in form of centrocaecal scotoma and constricted peripheral field. Fields were normal in the rest of the 10 patients. Optic disc change in the form of disc edema was seen in 5 eyes (13.15%) patients [Figure 1]. Ocular manifestations have been briefly summarized in Table 1.

Table 1. Summary of the Ocular findings.

S/L	Vision		Pupillary reaction	Color Vision		Fundus	Fields	Vision (3 months)		Color vision (3 months)
	RE	LE		RE	LE			RE	LE	
1	20/20p	20/20	Brisk	N	N	Normal	Normal	20/20	20/20	Normal
2	20/60	20/50	Sluggish	N	N	Normal	Normal	20/25	20/30	Normal
3	20/80	20/80p	Sluggish	D	D	Disc edema (BE)	Centrocaecal scotoma(RE)	20/30p	20/25p	Demoplates
4	20/25	20/20	Sluggish	D	D	Normal	Normal	20/20	20/20	Demoplates
5	20/25	20/20	Sluggish	I	I	Normal	Normal	20/20	20/20	Impaired
6	HM	HM	Ill sustained	Could not be tested		Disc edema (BE)	-	20/40	20/100	Demoplates
7	20/20p	20/20	Brisk	N	N	Normal	-	20/20	20/20	Normal
8	20/20p	20/20	Brisk	N	N	Normal	-	20/20	20/20	Normal
9	20/20p	20/20	Brisk	N	N	Normal	-	20/20	20/20	Normal
10	20/80	20/50p	Sluggish	I	I	Disc edema (RE)	-	20/30	20/30p	Impaired
11	20/25	20/20p	Sluggish	N	N	Normal	Centrocaecal scotoma (BE)	20/20	20/25	Normal
12	20/20p	20/20p	Brisk	N	N	Normal	Normal	20/20	20/20	Normal
13	20/60	20/50p	Sluggish	D	D	Normal	Peripheral constriction (20-30 degrees) (BE)	Lost to follow up		-
14	20/20p	20/20	Brisk	N	N	Normal	Normal	20/20	20/20	Normal
15	20/20p	20/20p	Brisk	N	N	Normal	Normal	20/20	20/20	Normal
16	20/20p	20/20p	Brisk	N	N	Normal	Normal	20/20	20/20	Normal
17	20/40	20/50	Sluggish	D	I	Normal	-	20/30	20/40	Demoplates
18	20/20p	20/20p	Brisk	N	N	Normal	Normal	20/20	20/20p	Normal
19	20/20p	20/20p	Brisk	N	N	Normal	Normal	Lost to follow up		-

N- Normal color vision, D- demo plates, I- impaired color vision, RE- right eye, LE- left eye, BE- both eyes, HM- hand movements

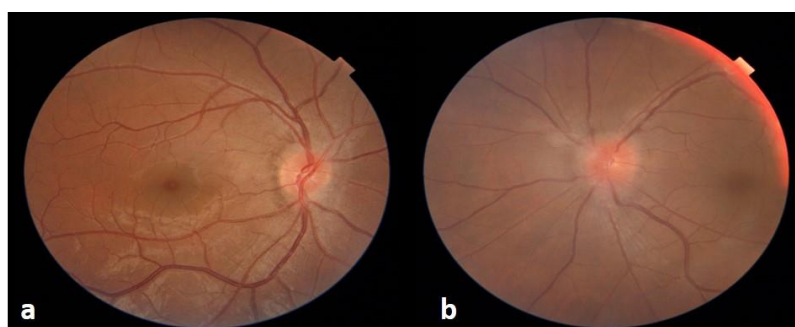


Figure 1. a. Colour fundus photograph of the right eye of P3 at presentation showing disc edema.
b. Colour fundus photograph of the left eye of P3 at presentation showing hyperemic disc and disc edema.

Systemic complaints were present in all patients. Vomiting, abdominal pain, breathlessness, headache, and dizziness were present in 76.9%, 68.4%, 26.5%, 15.7%, and 10.52% cases respectively. Metabolic acidosis can lead to acidemia, which is defined as arterial blood pH that is lower than 7.35 [6]. The serum anion gap refers to the difference between unmeasured anions and unmeasured cations in the body. Normal anion gap lies in the range between 10-12 mmol L⁻¹ [7]. High anion gap metabolic acidosis happens when the anion gap is > 12 mmol L⁻¹. Fifteen (78.9%) patients had blood pH <7.35 indicating metabolic acidosis. The blood pH of the remaining 4 (21.05%) patients was between 7.35 to 7.45. Out of these 15 patients, serum bicarbonate was

normal in 2 (13.3%) and < 22 mmol L⁻¹ in 13 (68.42%) patients. These 13 patients had typical clinical features of metabolic acidosis. All these 13 patients had high anion gap metabolic acidosis (anion gap > 12 mmol L⁻¹). Among these cases of metabolic acidosis, 7 (36.84%) patients had a pH values <7.2 (severe acidosis). All these patients had ocular findings either in form of defective vision defective CV or visual field defects. Eleven (57.89%) patients underwent hemodialysis. Patients with low pH, high anion gap, and high base deficit showed significant ocular findings in form of defective CV, visual field defect, and decrease in VA. Salient systemic findings have been summarized in Table 2.

Table 2. Summary of systemic findings.

S/L	Age/Gender	TOP (Hours)	Manifestation	Amount of alcohol intake (ml)	GCS
1	17/M	72	A	50	15/15
2	45/M	48	A	135	14/15
3	42/M	48	A, V	180	14/15
4	32/M	48	A, V, Br	180	14/15
5	40/M	48	A, V	180	14/15
6	45/M	48	V, Br	90	15/15
7	31/M	48	V, Br	90	15/15
8	30/M	48	A, V	90	15/15
9	50/M	48	A, V	90	15/15
10	42/M	48	A, V	80	15/15
11	23/M	48	A, V	90	15/15
12	35/M	48	A, V, Hr	180	15/15
13	48/M	72	V, H, Br	90	15/15
14	31/M	48	Hr	90	15/15
15	30/M	48	A	90	15/15
16	40/M	48	V, A	90	15/15
17	45/M	48	V, Br	180	14/15
18	32/M	48	V	90	15/15
19	23/M	72	V, A	90	15/15

TOP-Time of presentation, V-Vomiting, A- Abdominal pain, Br- Breathlessness, Hr- Head reeling, H-Headache, GCS-Glasgow Coma Scale

At 1 week, 1 patient (P13) was lost to follow up and at 3 months, 2 patients (P13, P19) were lost to follow up. VA of patient P6 who had the initial vision of HM improved to 20/100 and 20/80 in right and left eyes respectively. Excluding the patient who was lost to follow-up,

improvement of vision by 2 lines was seen in 8 eyes (21.05%) and by 1 line in 5 eyes (13.15%). The temporal pallor of the optic disc was noted in 8 eyes and 1 patient (P6) showed pronounced cupping [Figure 2].

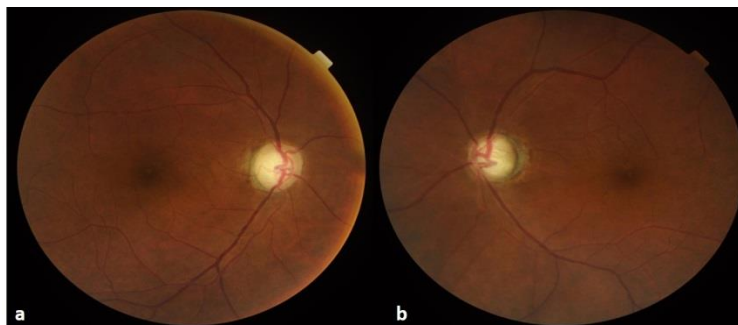


Figure 2. Colour fundus photograph of right and left eyes of P6, 3 months following initial presentation showing optic disc pallor and pronounced cupping.

Pupillary involvement in the form of sluggishly reacting to ill sustained was both clinically and statistically associated with poor VA ($P=0.0006$) at presentation and 3rd month ($P=0.0001$) follow-up. The presence of metabolic acidosis was associated with poor initial VA ($P=0.006$) and initial defective CV ($P<0.0001$) and at 3 months of follow-up VA ($P=0.0002$) and CV ($P=0.0001$). Patients who had a high anion gap showed both clinical and statistical correlation with initial VA ($P=0.0344$) and initial defective CV ($P=0.0090$) and final VA ($P=0.0007$) and final CV ($P=0.0025$). Similarly, patients with high base deficit showed clinical and statistical association with both initial defective CV ($P=0.0027$) and initial VA ($P<0.0001$) and final follow-up VA ($P=0.0158$) and CV ($P=0.0003$).

DISCUSSION

Very small amounts of ingested methanol can lead to severe visual dysfunction and death through acute destruction of parts of the central nervous system. It may also cause neurological dysfunction and irreversible blindness. Without prompt treatment, ingestion of even a small amount of methanol can lead to permanent blindness [8]. Serum bicarbonate levels tend to fall with a

concomitant rise in anion gap as the methanol metabolism proceeds. The primary toxin resulting from methanol metabolism is formic acid which is responsible for the majority of the anion gap metabolic acidosis and ocular toxicity [9]. The ocular changes are reported to correlate with the degree of metabolic acidosis [10]. Formaldehyde has been hypothesized to cause retinal damage by inhibiting retinal hexokinase [11]. After having entered into the retinal circulation, formaldehyde inhibits the enzyme cytochrome oxidase leading to mitochondrial dysfunction and decreased ATP production. This finally results in disruption of axoplasmic flow and swelling of axons in the optic disc and resultant retinal nerve fiber layer edema [12]. The diagnosis of acute methanol poisoning is based on the positive history of methanol ingestion or ingestion of a product containing methanol. Serum methanol concentration, anion gap metabolic acidosis, and osmolal gap help in confirming the diagnosis [13]. In the present study, there was a positive history of intake of adulterated country liquor containing methanol in all cases. Serum methanol levels could not be estimated due to the non-availability of the test in our hospital setting. Laboratory markers like low pH, metabolic acidosis, base deficit, and anion gap helped in confirming the diagnosis. Nausea,

headache, vomiting, abdominal discomfort, generalized weakness, and altered sensorium are the early nonspecific symptoms of acute methanol poisoning. This clinical picture can then proceed to blindness, coma, and death in cases of severe metabolic acidosis [14]. Prior studies have emphasized that pupillary status provides the best prognostic information about morbidity and mortality [15]. Pupillary abnormality in the form of sluggish reaction to ill sustained was noted in 6 (31.58%) cases. Our findings differ from the study by Sharma R et al [13] who reported 100 % pupillary involvement. Fixed dilated pupils were the most common pupillary abnormality reported in the above study. In the present study, all patients who had pupillary involvement had some improvement in vision with time. This is in contrast to Sharma R et al [13] where only 87.5% of cases had improvement in vision. Visual field defects were seen in 5 eyes (13.15 %) in form of centrocaecal scotoma (7.89%) and peripheral field loss (5.26%). Our findings differ from Jacobson BM et al [16] who found loss of central fields bilaterally in all cases where perimetry was possible and peripheral field remained normal till late. Patel JK and Narang SK [17] have reported cases that had peripheral field loss similar to our study.

Different studies have reported varying funduscopy findings. Sharma R et al [13] have reported hyperemic disc with RNFL edema and optic disc edema in 37.5 % and 25 % cases respectively at presentation. Neuroretinitis with peripapillary retinal edema was noted in 34 % of cases by Patel JK and Narang SK [17]. We noted optic disc change in the form of disc edema in 5 eyes (13.15 %). was normal in all other cases. Our findings are similar to the findings of Roe O [18] who noted that the fundus is usually normal in the majority of cases with an occasional blurring of disc margins and vascular tortuosity. The disc pallor and narrowing of blood vessels start within 4-6 weeks. One patient who presented with hand movements and disc edema, showed significant cupping and pallor after 3 months [Figure 2], similar to the case reported by Shin YW et al [19].

The primary goals of treatment are correction of metabolic acidosis, inhibition of methanol metabolism, and enhanced elimination of existing toxic metabolites [20]. Ethanol and

Fomepizole are specific antidotes that block the conversion of methanol to formic acid. Fomepizole (4-methyl pyrazole) has 500 to 1000 times greater affinity for the enzyme alcohol dehydrogenase and can completely inhibit it at lower serum concentrations [21]. Bicarbonate and hemodialysis are used to correct metabolic acidosis. Folic acid enhances the metabolism of formic acid. All patients in our study received intravenous Fomepizole. Intravenous bicarbonate infusion was done with the aim of full correction of metabolic acidosis. Hemodialysis was done in 11 (57.89%) cases. There was a prompt improvement in systemic and ocular complaints following hemodialysis. There are reports of improvement in visual acuity following the use of high doses of intravenous corticosteroids [22]. Shukla M et al used 3 doses of intravenous methylprednisolone (1 gm in 500 ml ringer lactate) followed by oral prednisolone (40mg) for 14 days to treat their cohort of 17 patients with methyl alcohol poisoning. [22] They reported significant improvement in VA in 10 out of 17 cases. A similar dosage of systemic steroids has been used in our study. Intravenous methylprednisolone was used in 3 cases. There was significant visual improvement following intravenous steroids.

Our study showed metabolic acidosis to be clinically and statistically significantly associated with initial ($P=0.0006$) and final VA ($P=0.0002$) which was similar to the study by Desai et al [23] who have reported pH to be the strongest laboratory marker determining initial and final visual outcomes. However, they haven't compared the initial and final CVs like the present study. Our study showed both clinical and statistical correlation of high anion gap and base deficit with initial and final VA and CV. We could not find any study analyzing or taking into account anion gap and base deficit similar to ours. No relationship has been noted between the amount of methyl alcohol consumed and eye involvement, similar to the study by Patel JK and Narang SK [17].

Limitations of this study include less number of patients and the inability to perform tests like contrast sensitivity and serum methanol levels due to non-availability in our center, which could be one of the parameters for visual outcome. The osmolal gap is a useful indicator to assess the

indication and duration of hemodialysis. We could not calculate the osmolal gap in all patients which could be one of the important clinical-biochemical parameters. Despite various limitations, we compared various biochemical markers with initial and final CV and VA which is not recorded in other studies.

CONCLUSIONS

Methyl alcohol toxicity poses a serious threat to both the mortality and morbidity of patients. Patients who have metabolic acidosis, high anion gap, and base deficit at the time of presentation are associated with defective color vision, abnormal pupillary reaction, and poor initial and final visual acuities. Prompt management with correction of metabolic acidosis, early hemodialysis, and intravenous methylprednisolone could decrease the morbidity rate and improve visual outcomes respectively.

Conflict of interests

Authors declare that they have no conflict of interest regarding the publication of this research article.

REFERENCES

1. Kadam D.B., Salvi S., Chandanwale A., 2018. Methanol poisoning. *Journal of the Association of Physicians of India*. 66, 47-50.
2. Rathi M., Sakhuja V., Jha V., 2006. Visual blurring and metabolic acidosis after ingestion of bootlegged alcohol. *Hemodial Int*. 10, 8-14.
3. Cursiefen C., Bergua A., 2002. Acute bilateral blindness caused by accidental methanol intoxication during fire "eating". *Br J Ophthalmol*. 86, 1064-1065.
4. Sharpe J.A., Hostovsky M., Bilbao J.M., Rewcastle N.B., 1982. Methanol optic neuropathy: a histopathological study. *Neurology*. 32, 1093-1100.
5. Kruse J.A., 1992. Methanol Poisoning. *Intensive Care Med*. 18, 391-7.
6. Eren N., Gungor O., Sarisik F.N., Sokmen F., Tutuncu D., Cetin G.Y., 2020. Renal Tubular Acidosis in Patients with Systemic Lupus Erythematosus. *Kidney Blood Press Res*. 45, 883-889.

7. Lim S., 2007. Metabolic acidosis. *Acta Med Indones*. 39, 145-50.
8. Dethlefs R., Naraqi S., 1978. Ocular manifestations and complications of acute methyl alcohol intoxication. *Med J Aust*. 2, 483-5.
9. Onder F., Ilker S., Kansu T., Tatar T., Kural G., 1998. Acute blindness and putaminal necrosis in methanol intoxication. *Int Ophthalmol*. 22, 81-4.
10. Mahieu P., Hassoun A., Lauwerys R., 1989. Predictors of methanol intoxication with unfavourable outcome. *Hum Toxicol*. 8, 135-137.
11. Martin-Amat G., McMartin K.E., Hayreh S.S., Hayreh M.S., Tephly T.R., 1978. Methanol poisoning: ocular toxicity produced by formate. *Toxicol Appl Pharmacol*. 45, 201-8.
12. Kraut J.A., Kurtz I., 2008. Toxic alcohol ingestions: clinical features, diagnosis, and management. *Clin J Am SocNephrol*. 3, 208-25.
13. Sharma R., Marasini S., Sharma A.K., Shrestha J.K., Nepal B.P., 2012. Methanol Poisoning: Ocular and Neurological Manifestations. *Optom Vis Sci*. 89, 178-182
14. Lin E.S., Buckley T., Li E., Lai K.N., Oh T.E., 1989. Case reports: a case of severe methanol intoxication. *J Hong Kong Med Assoc*. 41, 273-4.
15. Sullivan-Mee M., Solis K., 1998. Methanol-induced vision loss. *J Am Optom Assoc*. 69, 57-65.
16. Jacobson B.M., Russel H.K., 1945. AcuteMethyl alcohol poisoning. *U.S. Nav M Bull*. 44, 1099-1106.
17. Patel J.K., Narang S.K., 1970. Eye changes in methyl alcohol poisoning. *Indian J Ophthalmol*. 18, 125-7
18. Roe O., 1943. Clinical investigations of methyl alcohol poisoning. *Acta Med Scand*. 113, 558-608.
19. Shin Y.W., Uhm K.B., 2011. A case of optic nerve atrophy with severe disc cupping after methanol poisoning. *Korean J Ophthalmol*. 25, 146-50.
20. Ravichandran R., Dudani R.A., Almeida A.F., Chawla K.P., Acharya V.N., 1984. Methyl alcohol poisoning. (Experience of an outbreak in Bombay). *J Postgrad Med*. 30, 69-74.
21. Barceloux D.G., Bond G.R., Krenzelok E.P., Cooper H., Vale J.A., 2002. American Academy of Clinical Toxicology Ad Hoc Committee on the Treatment

Guidelines for Methanol Poisoning. American Academy of Clinical Toxicology practice guidelines on the treatment of methanol poisoning. *J Toxicol Clin Toxicol.* 40, 415-46.

22. Shukla M., Shikoh I., Saleem A., 2006. Intravenous methylprednisolone could salvage vision in methyl alcohol poisoning. *Indian J Ophthalmol.* 54, 68-9.

23. Desai T., Sudhalkar A., Vyas U., Khamar B., 2013. Methanol poisoning: predictors of visual outcomes. *JAMA Ophthalmol.* 131, 358-364.