

# Evaluation of Therapeutic Efficacy of Pulsed Dye Laser in Facial Melanocytic Junctional Nevi; A Single-arm Non-randomized Clinical Trial

Mohammad Hossein Alaghmand<sup>1</sup>, Hamideh Molaei<sup>2</sup>, Ali Akbar Karimi Zarchi<sup>3</sup>, Seyyed Masoud Davoudi<sup>4,\*</sup>

1. Student Research Committee, Baqiyatallah University of Medical Science, Tehran, Iran.
2. Trauma Research Center, Baqiyatallah University of Medical Sciences, Tehran, Iran.
3. Department of Epidemiology and Biostatistics, Faculty of Health, Baqiyatallah University of Medical Sciences, Tehran, Iran.
4. Department of Dermatology, Baqiyatallah University of Medical Sciences, Tehran, Iran.



## Abstract

**Background:** Mostly located in the dermo-epidermal junction, junctional nevus is a type of melanocytic nevi which is consisted of nevoid cells. A variety of treatment methods have been introduced so far for facial junctional nevi; however, they may be associated with scars. We aimed to evaluate the therapeutic efficacy of pulsed dye laser (PDL) and aesthetic improvement in patients with melanocytic junctional nevi. **Method:** This quasi-experimental study was conducted between January and April 2019 in Baqiyatallah dermatology clinic. We included patients with melanocytic junctional nevi in neck and face equal to or less than 10 mm as well as those between 15 and 30 years of age. Before intervention, we took a photograph of Nevus. Then this photograph was repeated at the beginning of each session and one month after the last session of laser therapy. The laser parameters for treatment were set to 10 joules energy and pulse width of 3 milliseconds. We asked a non-participant faculty member to determine the rate of improvement by visual analogue scale (VAS). **Results:** Eventually, 37 patients (120 nevi in 25 male and 12 female) were analyzed. Male patients had a mean age of  $24.9 \pm 2.3$  years and this was  $23.4 \pm 1.9$  for female individuals. Four (10.8%) patients experienced an improvement of less than 50%, 10 (27.1%) patients had an improvement rate between 50% and 75% and 23 (62.1%) patients had improvements more than 75%. **Conclusion:** It seems that PDL may efficiently and sufficiently improve the facial junctional nevus with no side effects.

**Keywords:** PDL; Pulsed Dye Laser; Junctional nevi; Melanocytic Junctional Nevus

Receive Date: 27 December 2022  
 Revise Date: 06 June 2023  
 Accept Date: 07 June 2023  
 Published Date: 27 July 2023  
 Editor: Z. Tajabadi (Conflict of Interests: None)  
 Reviewers: AR. Rafiei Javazm (Conflict of Interests: None), AR. Soleymanitabar (Conflict of Interests: None)

\*Correspondence to: Seyyed Masoud Davoudi M.D; Dermatology Clinic, Baqiyatallah Hospital, Mollasadra st., Vanaq ave., Tehran, Iran  
 Email: info@drdavoudi.ir



Cite as : Mohammad Hossein Alaghmand, Hamideh Molaei, Ali Akbar Karimi Zarchi, Seyyed Masoud Davoudi. Evaluation of Therapeutic Efficacy of Pulsed Dye Laser in Facial Melanocytic Junctional Nevi; A Single-arm Non-randomized Clinical Trial. Canon Journal of Medicine. 2023 June; 4(2), 68-70.

## INTRODUCTION

Most located in the dermo-epidermal junction, junctional nevus is a type of melanocytic nevi which consists of nevoid cells. They are usually found in dark colors and are located as a very thin papular or macular lesions on the skin (1). Junctional nevi are seen in nearly all the age groups in both congenital and acquired forms (2). The high prevalence of these nevi has made this belief that they cannot be considered as pathologic lesions; at least in people with light skins and a few nevi (1).

Although the exact rate of malignant transformation of junctional nevi is undetermined, it seems to be low for small lesions. According to worldwide increasing prevalence of malignant melanomas and this fact that about 20% of these malignancies occur in head and neck region, it is necessary for these lesions to be properly diagnosed and managed in golden time (3).

A variety of treatment methods have been introduced so far for facial junctional nevi. Surgery, radiofrequency, and shaving are some of these methods; however, they may be associated with scars. So, dermatologists are considering alternative methods with less aesthetic complications. Pulsed Dye Laser which works based on selective thermal effect, is one of these alternative methods (4-6). PDL has an extensive application in dermatology for treatment of both vascular and non-vascular skin lesions such as warts, molluscum and psoriasis(1). In the present study, we aimed to evaluate the therapeutic efficacy of PDL and final aesthetic improvement in patients with facial melanocytic junctional nevi.

## MATERIAL AND METHODS

This quasi-experimental study was conducted between January and April 2019 in Dermatology clinic of Baqiyatallah University of Medical Sciences, Tehran, Iran. The protocol was registered at

the ethics committee of Baqiyatallah University of Medical Sciences (Ref. No: IR.BMSU.REC.1395.179). Figure 1 shows a flow-chart of the study.

We assessed 40 patients with melanocytic junctional nevus attending our clinic for eligibility. We included patients with melanocytic junctional nevi in neck and face equal to or less than 10 mm as well as those between 15 and 30 years of age. Patients with history of collagen vascular diseases, hypertrophic scar, or keloid as well as skin lesions in which the laser therapy is prohibited (eg. Vitiligo, Psoriasis and Systemic Lupus Erythematosus) or those using systemic retinoid derivatives were excluded from the study. The advantages and disadvantages of the procedure were explained to all patients and entered the study by signing an informed consent form.

Before intervention, we took a photograph of nevus by a 12 mega pixel camera. Then this photograph was repeated at the beginning of each session and one month after the last session of laser therapy. The number of therapy sessions was decided by the patients themselves to reach their desired amount of improvement. We used Vbeam Perfecta PDL (CANDELA™, Candela Medical), a 595-nm device with 7-mm spot hand piece, specified for pigmented

lesions. The laser parameters for treatment were set at energy of 10 joules and pulse width of 3 milliseconds was considered.

Finally, the first and last photograph of each patient was evaluated by a non-participant faculty member to determine the rate of improvement by visual analogue scale (VAS). The percentage of improvement was considered by the referee as the final impact rate. An improvement rate of less than 25% was considered as grade 1, 25 to 50% as grade 2, 50 to 75% as grade 3 and more than 75% as grade 4.

We performed data analysis using SPSS software (SPSS Inc. Released 2007. SPSS for Windows, Version 16.0. Chicago, SPSS Inc.). The chi-square test was used to compare categorical variables in the 2 groups. A p value of less than 0.05 was considered statistically significant.

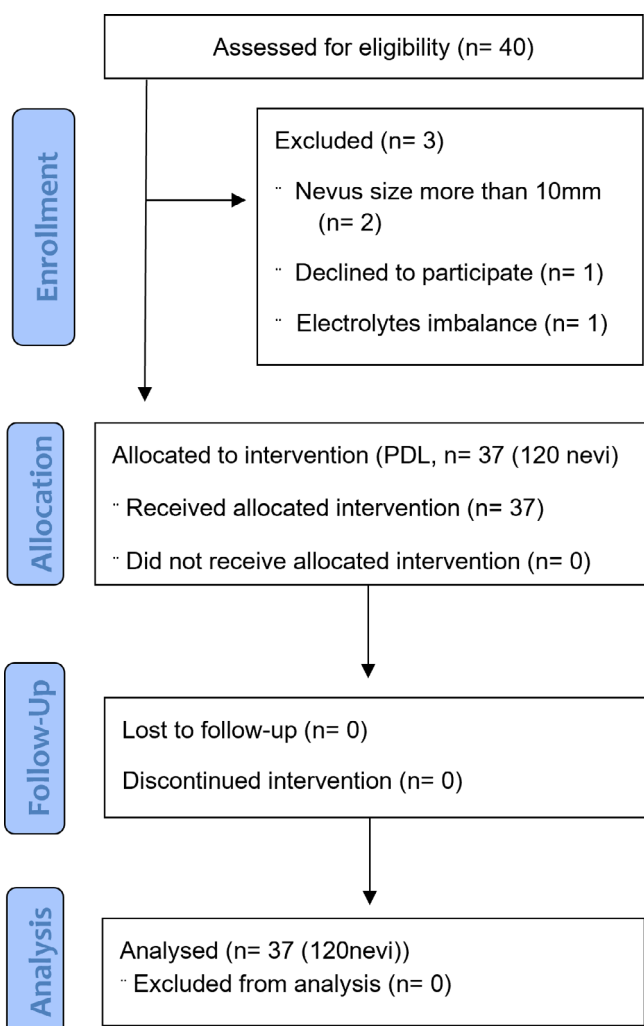
**RESULTS**

Eventually, 37 patients (a total of 120 nevi in 25 male and 12 female) were analyzed. Male patients had a mean age of 24.9±2.3 years and this was 23.4±1.9 for female individuals. Among male patients, 13(52.3%) had one to three nevi, 8(31.7%) had four to six nevi and 4 (16.3%) had more than 6 nevi. Also, 7 (58.2%) female patients had 1 to 3, 2(16.6%) had 4 to 6 and 3 (18.5%) had more than 6 nevi. Table 1 summarizes the distribution of skin color and type by gender. All of our patients were among types II, III, IV and V of Fitzpatrick grading (2).

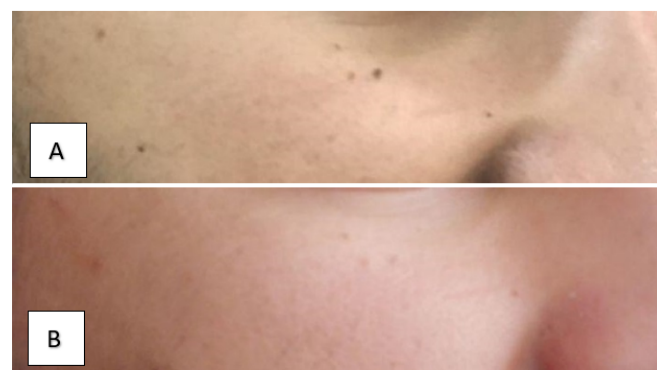**Table 1.** Distribution of skin color and type by gender

Skin Color Gender	Dark*	Light**	Total
Male	17(68%)	8(32%)	25(100%)
Female	9(75%)	3(25%)	12(100%)
Skin Type Gender	Oily	Dry	
Male	14(56%)	11 (44%)	15(100%)
Female	7(58.3%)	5(41.6%)	12(100%)

\*Types IV and V of Fitzpatrick classification  
\*\* Types II and III of Fitzpatrick classification



**Figure 1.** Study flowchart



**Figure 2.** Before (A) and one month after the last therapeutic session (B)



At the end of the study, 4(10.8%) patients experienced an improvement of less than 50%, 10(27.1%) patients had an improvement rate between 50% and 75% and 23(62.1%) patients had improvements of more than 75%. In Table 2, we have shown the rate of response to treatment by gender, skin color, type and number of nevi. There was no significant association between these factors and response to treatment by PDL ( $p>0.05$ ).

## DISCUSSION

We found that most patients experienced an improvement rate of more than 75% by PDL. In addition, we found that gender, skin color, type (dark or light and oily or dry) and number of nevi have no direct association with treatment response.

To the best of knowledge, this the first study assessing the effect of pulsed dye laser on treatment and aesthetic improvement of junctional nevi; however, previous studies have extensively assessed the application of PDL in other skin lesions.

Ehsani et al. evaluated the therapeutic effects of PDL on 9 patients with xanthelasma. Patients underwent treatment by two PDL sessions within 4 weeks. Laser parameters were adjusted for 10 Jules of energy and pulse width of 1.5 milliseconds. They concluded that PDL was not effective in treatment of Xanthelasma lesions(7). In contrast with this study, Karsai et al. treated 38 patients with Xanthelasma in 5 sessions using PDL and wave length of 585 nm, 7 Joules of energy and pulse width of 0.45 millisecond. They reported an improvement rate of more than 50% in two-third of the patients and an improvement rate of 75% in one-fourth of the patients. (8).

In another study, Ghaninejhadi et al. assessed the therapeutic effects of PDL on Solar Lentiginous lesions. In this study, 21 patients with lentiginous underwent treatment by PDL, 10 Joules of energy and 7-mm spot. They reported PDL as a safe and beneficial method for lentiginous (9).

## LIMITATIONS

The present study has some limitations. Although, the application of PDL for treatment of junctional nevus is a new concept and point of strength for our study, we did not have enough background studies which will be resolved by pursuing the current subject. In addition, we did not include any control groups as this was the first trial in this subject. In addition, the low sample size was another limitation.

## CONCLUSION

In conclusion, it seems that PDL may efficiently and sufficiently improve the facial junctional nevus with no side effects. Further studies are recommended to be conducted with a larger sample size.

## CONFLICT OF INTERESTS:

None.

## ABBREVIATIONS

PDL; pulsed dye laser, VAS; visual analogue scale.

## REFERENCES

1. Xiong M, Charifa A, Chen CSJ. Lentigo Maligna Melanoma.
2. Puccio FB, Chian C. Acral junctional nevus versus acral lentiginous melanoma in situ: a differential diagnosis that should be based on clinicopathologic

3. Liang Z-P, Xu S-E, Jiang L, Zhao C, Sun X-Q, Qin G. Scalp junctional nevus with malignant transformation (melanoma) metastatic to parotid lymph node region, cervical lymph nodes and the back: A case report and review of literature. *International journal of clinical and experimental pathology*. 2015;8(1):954.
4. Jalalabadi F, Trost JG, Cox JA, Lee EI, Pourciau CY, editors. *Dermatology for Plastic Surgery: Common Pediatric Skin Lesions: A Comprehensive Review of the Current Literature*. Seminars in plastic surgery; 2016: Thieme Medical Publishers.
5. Artzi O, Friedman O, Al-Niaimi F, Wolf Y, Mehrabi JN. Mitigation of postsurgical scars using lasers: a review. *Plastic and Reconstructive Surgery Global Open*. 2020;8(4).
6. Ahluwalia J, Avram MM, Ortiz AE. The evolving story of laser therapeutics for basal cell carcinoma. *Dermatologic Surgery*. 2020;46(8):1045-53.
7. Ehsani, A, Noormohammadpour, P, Shakib A, Gholamali, F. Efficacy of pulsed dye laser (PDL) in the treatment of xanthelasma palpebrarum (Article in Persian). *JDC*. 2013; 4 (2) :92-97
8. Karsai S, Czarnecka A, Raulin C. Treatment of xanthelasma palpebrarum using a pulsed dye laser: a prospective clinical trial in 38 cases. *Dermatologic surgery*. 2010;36(5):610-7.
9. Ghaninejhadi H, Ehsani A, Edrisi L, Gholamali F, Akbari Z, Noormohammadpour P. Solar lentiginous: Evaluating pulsed dye laser (PDL) as an effective treatment option. *Journal of lasers in medical sciences*. 2013;4(1):33.

**Author Contribution:** All authors have contributed in this study.

**Funding statement:** None.

**Acknowledgements:** None.

© **Canon Journal of Medicine 2023**. This is an open-access article distributed under the terms of the Creative Commons Attribution-Noncommercial 4.0 International License (CC-BY), which permits unrestricted use, distribution, and reproduction in any medium, including commercial gain.