

## Case report of an early diagnosed ameloblastic fibroma

Parichehr Ghalayani(DDS)<sup>1</sup>, Mina Hamian(DDS)<sup>2</sup>, Maryam Jafari(DDS)<sup>3</sup>, Samira Hajisadeghi(DDS)<sup>2✉</sup>

1. Associate Professor, Department of Oral & Maxillofacial Medicine, School of Dentistry, Isfahan University of Medical Sciences, Isfahan, Iran.
2. Assistant Professor, Dental and Oral Research Center, Department of Oral & Maxillofacial Medicine, School of Dentistry, Qom University of Medical Sciences, Qom, Iran.
3. Oral& Maxillofacial Pathologist, School of Dentistry, Ilam University of Medical Sciences, Ilam, Iran.

✉ **Corresponding Author:** Samira Hajisadeghi, School of Dentistry, Qom University of Medical Sciences, Qom, Iran.

**Email:** hajisadeghi@dnt.mui.ac.ir

**Tel:** +982537700094

**Received:** 30 Dec 2014

**Accepted:** 17 Aug 2015

### Abstract

Ameloblastic fibroma is a relatively rare benign odontogenic tumor with two neoplastic components; both epithelial and ectomesenchymal. A 10-year-old girl was referred to a dentist for routine dental treatments for evaluation of the distance between mandibular right first permanent molar and mandibular right second deciduous molar and it was associated with an undesirable backward movement of erupted mandibular right first permanent molar and forward movement of mandibular right second deciduous molar. The lesion was enucleated and the material was sent for histopathologic examination. Microscopically, it was composed of neoplastic proliferation of odontogenic epithelium consisted of cords and islands in a cell-rich mesenchymal stroma, with histopathological diagnosis of ameloblastic fibroma. After 24 months of follow-up, no recurrence was observed and the mandibular right first molar was spontaneously aligned. Early diagnosis and proper management will prevent comprehensive orthodontic treatment.

**Keywords:** Dental tissue neoplasms, Mandibular neoplasms, Odontogenic tumors

**Citation for article:** Ghalayani P, Hamian M, Jafari M, Hajisadeghi S. Ameloblastic fibroma: report of an early diagnosed case and literature review. *Caspian J Dent Res* 2015; 4: 44-9.

## گزارش یک مورد آملوبلاستیک فیبروما با تشخیص زود هنگام

پریچهر غلبانی، مینا حامیان، مریم جعفری، سمیرا حاجی صادقی\*

### چکیده

آملوبلاستیک فیبروما یک تومور ادنتوژنیک خوش خیم نسبتاً نادری است که از دو جزء نئوپلاستیک اپیتالیایی و اکتومزانسیمال تشکیل شده است. دختری ۱۰ ساله برای معاینه دندان‌ها و به علت فضای نامتناسبی که در سمت راست فک پایین بین دندان مولر دوم شیری و مولر اول دائمی ایجاد شده بود به دندانپزشک مراجعه کرد. این فاصله با جابجایی دیستالی مولر اول دائمی و جابجایی مزیالی مولر دوم شیری همراه بود. ضایعه به طور کامل توسط جراحی برداشته شد و برای بررسی بافت شناسی ارسال شد. ضایعه از نظر میکروسکوپی حاوی پرولیفراسیون نئوپلاستیک اپیتلیوم ادنتوژنیک و متشکل از طناب‌ها و جزایر در استرومای پرسلول مزانشیمی بود. تشخیص هیستوپاتولوژی ضایعه آملوبلاستیک فیبروآدنوما بود. در پیگیری ۲۴ ماهه هیچ عودی رخ نداد و دندان مولر اول دائمی بصورت خودبخود به محل عادی برگشت. این گزارش بر اهمیت تشخیص زودهنگام ضایعه و درمان مناسب تاکید دارد که از درمان‌های پیچیده ارتودنسی در آینده پیشگیری کرد.

**واژگان کلیدی:** نئوپلاسم‌های بافت دندانی، نئوپلاسم‌های فک پایین، تومورهای ادنتوژنیک

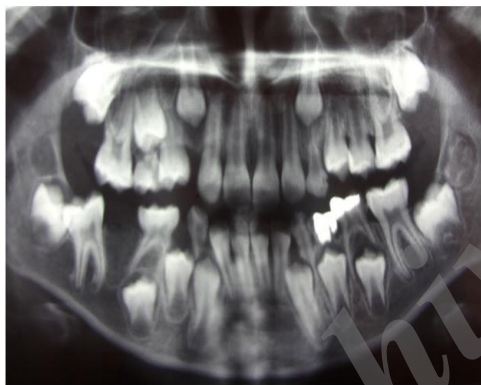
### Introduction

Ameloblastic fibroma (AF) is defined as a benign, rare odontogenic tumor with two histologic components that results in classifying the tumor in true mixed odontogenic tumors.<sup>[1,2]</sup> It composes 1.5-4.5% of all odontogenic tumors according to the literature.<sup>[1-6]</sup> AF has been reported in a wide age group from 7 weeks to 57 years<sup>[7]</sup>, but basically it is considered as a tumor of childhood and adolescence that occurs mostly in the first two decades.<sup>[6,8,9]</sup> In the majority of cases, the lesion is seen in the mandible with the presentation of a slow-growing, painless swelling and/or failure of tooth eruption.<sup>[8,9]</sup> However, the tooth impaction and delayed eruption may be due to dental developmental defects or abnormalities such as amelogenesis imperfecta.<sup>[10]</sup> In some cases; however, the tumors are asymptomatic and are noticed during a routine oral/radiographic examination.<sup>[9]</sup> Radiographic view of AF is a well-defined unilocular or multilocular radiolucency.<sup>[3,7]</sup> It has been reported that unilocular radiolucence is usually appear as asymptomatic cases, whereas multilocular cases are associated with jaw swelling.<sup>[11]</sup> The exact pathogenesis is not clear. The tall columnar ameloblast-like cells in the epithelial component are too primitive to induce the cells of the ectomesenchyme, and only little is known about their interactions. It is also unknown why the induction of odontoblastic

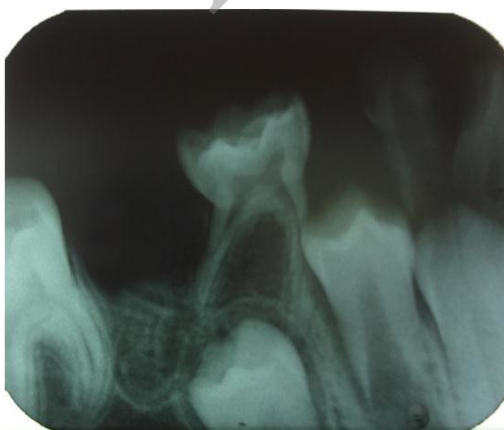
differentiation is lacking in AF. Immunohistochemical analysis shows positive staining of odontogenic epithelium for cytokeratin, mesenchymal tissue around the dental lamina-like epithelium for tenascin, focal areas of immature dental papilla-like cells, and basement membrane of the epithelium for vimentin. These findings suggest that AF develops at an early stage of tooth formation.<sup>[12,13]</sup> Mitotic figures may be a part of the histopathologic view in AF. In the case of presence of a large number of mitosis and especially atypical mitosis, malignant entities, like Ameloblastic fibrosarcoma should be considered as differential diagnosis.<sup>[1]</sup> The best appropriate treatment for AF still remains uncertain. Several authors have suggested a conservative approach.<sup>[1]</sup> However, recurrence following surgical removal and progress to malignancy is probable to occur.<sup>[7,14]</sup> Recurrence is usually thought to be related to incomplete removal and remaining of the residual tumor.<sup>[6]</sup> Hence, long-term follow-up is recommended.<sup>[15]</sup> The aim of this study was to report an interesting early diagnosed case of AF which affected mandible of a young girl and was associated with an undesirable movement of erupted mandibular right first permanent molar and mandibular right second deciduous molar. Early diagnosis and proper management will prevent comprehensive orthodontic treatment.

**Case report**

A 10-year-Old Iranian girl was referred to the dentistry department with the chief complaint of failed eruption of the right permanent mandibular first molar. Physical examination showed a generally healthy child and the medical, surgical, familial and social histories were unremarkable. Intraoral examination revealed no expansion of the buccal or lingual cortical mandibular plate. The overlying mucosa was intact and normal in color and consistency. Radiographic examination by means of a panoramic radiography (Fig. 1-A) indicated a well defined multilocular radiolucent lesion in the right mandible. The second deciduous molar was displaced forward and the first permanent molar was displaced backward. But the periodontal ligament of both teeth was intact. The periapical radiography of the area showed the same mixed radiolucent lesion (Fig.1-B).

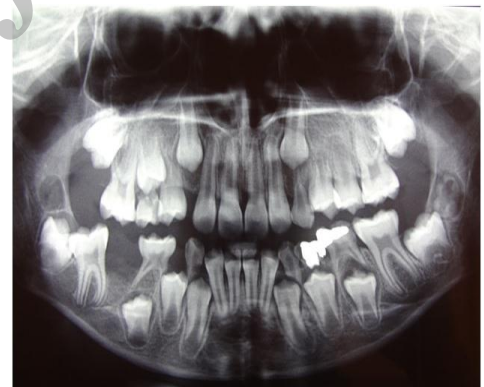

**Fig 1-A.** Initial panoramic view showed a well-defined mixed radiolucent lesion in the right mandible. The second deciduous molar was displaced forward and the first permanent molar was displaced backward.

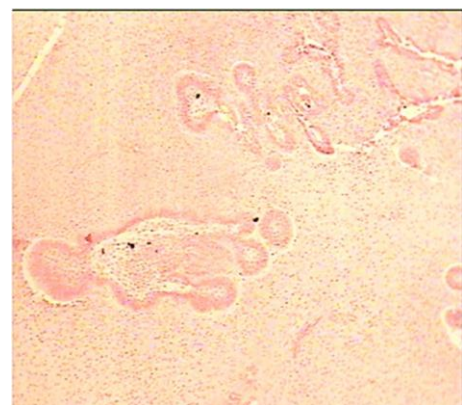


**Fig1-B.** The periapical radiography of the area illustrated the mixed radiolucent lesion

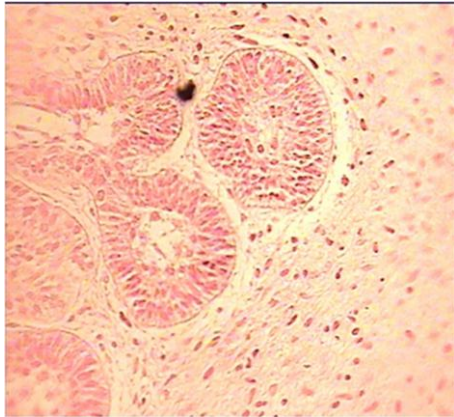Based on clinical and radiographic findings, a presumptive preoperative diagnosis of ameloblastoma or odontogenic cyst was made. Under local anesthesia, the lesion was totally removed through an intraoral approach (Fig.1-C). The enucleated material was sent to the Oral & maxillofacial Pathology Department of the Dentistry School of Isfahan University of Medical Science for histological diagnosis. Microscopically, neoplastic proliferation of odontogenic epithelium consisted of cords and islands was seen; (Fig. 2-A).Histopathologic view revealed double layer of cuboidal or columnar cells in a cell-rich mesenchymal stroma with plump stellate and ovoid cells and little collagens closely resembling the primitive dental papilla (Fig.2-B). Evidence of hard tissue formation in the sample was not observed, so the histopathological diagnosis was considered as ameloblastic fibroma. After 24-month follow-up, no recurrence was observed. The first molar was spontaneously aligned and the patient won't need any comprehensive orthodontic treatment (Fig. 3).



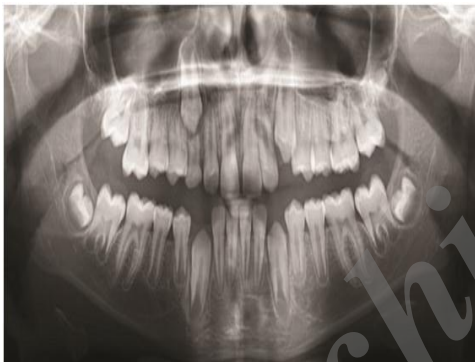**Fig 1-C.** a panoramic view after surgery. The lesion was totally removed



**Fig 2-A.** Microscopically, neoplastic proliferation of odontogenic epithelium consisted of cords and islands were seen



**Fig 2-B.** double layer of cuboidal or columnar cells was seen in a cell-rich mesenchymal stroma with plump stellate and ovoid cells and little collagens closely resembling the primitive dental papilla. The histopathological diagnosis was considered as ameloblastic fibroma.



**Fig 3.** After 24-month follow-up, no recurrence was observed. The first molar was spontaneously aligned and the patient won't need any comprehensive orthodontic treatment

The recommendations of Helsinki declaration were thoroughly maintained during this study. Ethical approval of this article was confirmed by the ethics committee of Isfahan University of Medical sciences.

## Discussion

Ameloblastic Fibroma (AF) was first described in 1891 by Kruse. Up to now, 123 patients have been reported in the English literature.<sup>[16]</sup> It is defined by WHO as “consists of odontogenic ectomesenchyme resembling the dental papilla and epithelial strands and nests resembling dental lamina and enamel organ. No dental hard tissues are present.”<sup>[6]</sup> Tomich was the first

to classify this tumor as a separate entity.<sup>[17]</sup> It is a mixed tumor with both epithelial and mesenchymal components<sup>[1]</sup>

In this case, an AF has been reported in a 10-year-old girl at the posterior of mandible. In line with our case, the most common age for AF is the first and second decades in the literature although it has the potential to be diagnosed in 7-week infants to 57-year-old patients. Unlike this case which has occurred in a girl, a slight higher prevalence has been reported in males.<sup>[3,9,11]</sup> Along with this case, the majority of cases has been reported in mandible with a predilection for the posterior regions.<sup>[6]</sup> Still, few cases of the AF in the maxilla have been reported.<sup>[8]</sup>

Swelling of the jaw is the most common finding which is occasionally associated with pain, tenderness, drainage and ulceration.<sup>[6]</sup> While none of these common features was observed in this patient, the only finding was displacement of the teeth which is a rare accompanied feature. Since it is benign and slow-growing, it can also be frequently discovered in a routine dental and radiographic examination<sup>[1,8]</sup> According to the literature review, radiographic view might be either unilocular or multilocular with well-defined borders as in the present case in which a multilocular radiolucency was noticed in the panoramic view.<sup>[6]</sup> The differential diagnosis is dentigerous cysts, ameloblastoma, odontogenic keratocysts and Ameloblastic fibrosarcoma according to the radiographic view.<sup>[8,14]</sup> When the internal pattern of the lesion is a mixed radiolucent-radiopaque then calcifying odontogenic tumor is one of the possible differential diagnosis.<sup>[12]</sup>

Previously, these lesions were categorized as a spectrum of a single entity with ameloblastic fibromas, the least differentiated of the tumors, maturing and developing into ameloblastic fibro-odontomas and later odontomas. However, nowadays, it is considered as an independent entity with its special characteristics. They can be differentiated according to the demographic features of the patient.

The least differentiated lesion, ameloblastic fibroma, actually occurs, on average, at an older age than the more differentiated ameloblastic fibro-odontoma and odontoma. In addition, Ameloblastic fibro-odontomas and odontomas have a different nature and are categorized as hamartomas and unlike the ameloblastic fibroma have little chance of recurrence or susceptibility to malignant transformation.<sup>[18]</sup> Therefore, despite the

common apparent features, these lesions should be differentiated and treated differently. Due to the true neoplastic nature of AF, the treatment plan differs from the other lesions which are considered mainly as hamartomas.<sup>[19]</sup>

Regarding the treatment procedure of this tumor, there are some controversies. Philipsen et al.<sup>[13]</sup>enucleated AF and afterwards careful follow-up of the lesion was performed. Recurrence of the AF may not be a true one rather a residual lesion as a result of incomplete enucleation. Some authors believe that aggressive treatment is not reasonable.<sup>[3,7, 15]</sup> However, Chen et al.<sup>[7]</sup> reported that recurrence is more common among patients treated with a more conservative approach. Those authors found recurrence in 14 out of 41 cases.

Dallera et al.<sup>[3]</sup>, on the other hand, reported no recurrence for 6 cases with an average follow up of 15 years. Therefore, it is necessary to follow a step-wise treatment principle when the diagnosis of AF has been made. There is a great emphasis on the patient's age during treatment planning. It is recommended to treat patients under 22 with conservative surgeries; however, a radical surgery should be considered for patients older than 22.<sup>[6]</sup> Consistent with data from other studies, the treatment plan applied for the patient in this case was enucleation and no recurrence was observed after 24 months follow up.

Although it is uncommon, the possibility of malignant transformation of AF into Ameloblastic fibrosarcoma has been mentioned by Chen et al.<sup>[7]</sup> and Kobayashi et al.<sup>[14]</sup> According to their reports, AF showed no signs of malignancy until the second recurrence. Chen et al.<sup>[7]</sup> during two 5-year and 10-year follow-ups reported transformation to malignancy 10.2% and 22.2%, respectively. However, Kousar et al. have presented<sup>[15]</sup> a rapid sarcomatous transformation of one case of AF within 6 months.

In the case reported here, the main feature was mandibular first molar failure of eruption. This disturbance may or may not be associated with pathology, such as AF. Thus, this case highlights the importance of careful differential diagnosis and early detection, while it reports a rare lesion. Tooth displacement and delayed eruption were the only signs of the lesion. These findings are not common accompanied features of ameloblastic fibroma. Note the early diagnosis of the lesion leads to early treatment with no recurrence.

## References

1. Barnes L, Eveson JW, Reichart P, Sidransky D. Pathology and genetics of tumors of the head and neck. 3<sup>rd</sup> ed. Lyon: IARC Press; 2005. p.308-309.
2. Vij R, Vij H. Ameloblastic fibroma: an uncommon entity. *BMJ Case Rep* 2013; pii: bcr2013010279.
3. Dallera P, Bertoni F, Warchetti C, Bacchini P, Campobassi A. Ameloblastic fibroma: A follow-up of six cases. *Int J Oral Maxillofac Surg* 1996;25:199-202.
4. Tawfik MA, Zyada MM. Odontogenic tumors in dakahlia, egypt: analysis of 82 cases. *Oral Surg Oral Med Oral Pathol Oral Radiol Endod* 2010;109:e67-73.
5. Osterne RL, Brito RG, Alves AP, Cavalcante RB, Sousa FB. Odontogenic tumors: a 5-year retrospective study in a Brazilian population and analysis of 3406 cases reported in the literature. *Oral Surg Oral Med Oral Pathol Oral Radiol Endod* 2011;111:474-81.
6. Chen Y, Wang JM, Li TJ. Ameloblastic fibroma: a review of published studies with special reference to its nature and biological behavior. *Oral Oncol* 2007;43:960-9.
7. Chen Y, Li TJ, Gao Y, Yu SF. Ameloblastic fibroma and related lesions: a clinicopathologic study with reference to their nature and interrelationship. *J Oral Pathol Med* 2005;34:588-95.
8. Martín-Granizo López R, Ortega L, González Corchón MA, Berguer Sánchez A. Ameloblastic fibroma of the mandible: report of the two cases. *Med Oral* 2003;8:150-3. [In English, Spanish]
9. Pitak-Arnnop P, Chaine A, Dhanuthai K, Bertrand JC, Bertolus C. Extensive ameloblastic fibroma in an adolescent patient: a case report with a follow-up of 4 years. *Eur J Dent* 2009;3:224-7.
10. Canger EM, Celenk P, Yenisey M, Odyakmaz SZ. Amelogenesis imperfecta, hypoplastic type associated with some dental abnormalities: a case report. *Braz Dent J* 2010;21:170-4.
11. Deboni MC, Naclério-Homem Mda G, Pinto Junior DS, Traina AA, Cavalcanti MG. Clinical, radiological and histological features of calcifying epithelial odontogenic tumor: case report. *Braz Dent J* 2006;17:171-4.
12. Jindal C, Bholá RS. Ameloblastic fibroma in six-year-old male: hamartoma or a true neoplasm. *J Oral Maxillofac Pathol* 2011;15:303-5.

13. Philipsen HP, Reichart PA, Praetorius F. Mixed odontogenic tumors and odontomas. considerations on interrelationship. review of the literature and presentation of 134 new cases of odontomas. *Oral Oncol* 1997;33:86-99.
14. Kobayashi K, Murakami R, Fujii T, Hirano A. Malignant transformation of ameloblastic fibroma to Ameloblastic fibrosarcoma: case report and review of the literature. *J CranioMaxillofacSurg* 2005;33:352-5.
15. Kousar A, Hosein MM, Ahmed Z, Minhas K. Rapid sarcomatous transformation of an ameloblastic fibroma of the mandible: case report and literature review. *Oral Surg Oral Med Oral Pathol Oral RadiolEndod* 2009;108:e80-5.
16. Gupta S, Tandon A, Mehrotra D, Gupta OP. Ameloblastic fibroma: report of 3 cases and literature review. *Int J Oral MaxillofacPathol* 2011;2:59-63.
17. Tomich CE. Benign mixed odontogenic tumors. *SeminDiagnPathol* 1999;16:308-16.
18. Sloomweg PJ. An analysis of the interrelationship of mixed odontogenic tumors—ameloblastic fibroma, ameloblastic fibroodontoma, and the odontomas. *Oral Surg Oral Med Oral Pathol* 1981;51:266-76.
19. Nelson BL, Folk GS. Ameloblastic fibroma. *Head and Neck pathol* 2009;31:51-3.

Archive of SID