

A comparison of image artifacts with gutta-percha and different sealers on root filled teeth using cone beam computed tomography: An in vitro study

Atefeh Gholampour¹, Ali Soleymani², Ali Bijani³, Sina Haghanifar⁴✉

1. Postgraduate Student, Student Research Committee, Babol University of Medical Sciences, Babol, IR Iran. **ORCID** (0000-0002-3170-8517)
2. Assistant Professor, Dental Materials Research Center, Health Research Institute, Babol University of Medical Sciences, Babol, IR Iran.
3. Assistant Professor, Social Determinants of Health Research Center, Health Research Institute, Babol University of Medical Sciences, Babol, IR Iran.
4. Professor, Oral Health Research Center, Health Research Institute, Babol University of Medical Sciences, Babol, IR Iran.

✉**Corresponding Author:** Sina Haghanifar, Department of Oral & Maxillofacial Radiology, Faculty of Dentistry, Babol University of Medical Sciences, Babol, IR Iran.

Email: dr_haghanifar@yahoo.com

Tel: +981132291408

ORCID (0000-0001-5949-8913)

Received: 11 Jul 2020

Accepted: 5 Sept 2020

Abstract

Introduction: Different materials cause artifacts in cone-beam computed tomography (CBCT) images, which, in turn, reduce the quality of images. The aim of this study was to investigate the abundance of artifacts induced by different root canal therapy sealers with two different CBCT resolutions.

Materials & Methods: Roots of four maxillary central phantom teeth were prepared using rotary files in three steps. In the first step, the first tooth was scanned first without gutta-percha and then with gutta-percha No. 25. Gutta-percha No. 25 with resin, the zinc oxide-eugenol (ZOE)-based sealer and the ceramic-based sealer were placed in the teeth No. 2, 3 and 4, respectively. The second step was performed similar to the first step, except that gutta-percha No. 35 was used in the tooth No. 1 with resin- and ZOE-based sealers in the teeth No. 2 and 3. due to the lack of access to the ceramic-based sealer that was not used to continue the study. In the third step, canal obturation was performed in the teeth No. 2 and 3 with resin and ZOE-based sealers. At each step, three CBCT scans were obtained in high and standard resolution conditions. Contrast-to-noise ratio was obtained in three root plans, and the data were analyzed.

Results: Gutta-percha alone produced more artifacts than gutta-percha with sealers. Moreover, ZOE-based sealers induced more artifacts than other sealers. There was no significant difference between the three steps. Similarly, at different resolutions, there was no significant difference between gutta-percha and sealer artifacts. The ZOE-based sealers had more artifacts at 1/3 apical whereas resin sealers had more artifacts at 1/3 coronal.

Conclusion: The higher artifact of gutta-percha in comparison with gutta-percha and sealer and the artifact decrease in the combination of gutta-percha and resin-based sealer than ZOE-based sealer has led us to recommend the use of resin-based sealer while root canal therapy in order to better evaluation of the CBCT Images of root canal.

Keywords: Cone beam computed tomography, Artifacts, Gutta-percha

Citation for article: Gholampour A, Soleymani A, Bijani A, Haghanifar S. A comparison of image artifacts with gutta-percha and different sealers on root filled teeth using cone beam computed tomography: An in vitro study. *Caspian J Dent Res* 2020; 9: 42-9.

بررسی آزمایشگاهی میزان آرتیفکت تصویر ناشی از گوتا پرکا و سیلرهای مختلف با تصاویر توموگرافی کامپیوتری با اشعه مخروطی: مطالعه آزمایشگاهی

عاطفه غلامپور^۱، علی سلیمانی^۲، علی بیژنی^۳، سینا حقانی فر^{۴*}

۱- دانشجوی دستیاری، مرکز تحقیقات دانشجویی، دانشگاه علوم پزشکی بابل، بابل، ایران.
 ۲- استادیار، مرکز تحقیقات مواد دندان، پژوهشکده سلامت، دانشگاه علوم پزشکی بابل، بابل، ایران.
 ۳- استادیار، مرکز تحقیقات عوامل اجتماعی موثر بر سلامت، پژوهشکده سلامت، دانشگاه علوم پزشکی بابل، بابل، ایران.
 ۴- استاد، مرکز تحقیقات سلامت و بهداشت دهان، پژوهشکده سلامت، دانشگاه علوم پزشکی بابل، بابل، ایران.
 *نویسنده مسئول: سینا حقانی فر، گروه رادیولوژی دهان، فک و صورت، دانشکده دندانپزشکی، دانشگاه علوم پزشکی بابل، بابل، ایران.
 پست الکترونیکی: dr_haghanifar@yahoo.com تلفن: +۹۸۱۱۳۲۹۱۴۰۸

چکیده

مقدمه: مواد مختلف سبب ایجاد آرتیفکت در تصاویر CBCT شده که به نوبه خود سبب کاهش کیفیت تصاویر می شود. در این مطالعه میزان آرتیفکت ناشی از سیلرهای مختلف مورد استفاده در درمان ریشه در دو رزولوشن مختلف دستگاه CBCT بررسی شد. **مواد و روش ها:** ریشه ۴ دندان فانتوم سانترال ماگزایلا در ۳ مرحله به وسیله فایل های روتاری آماده سازی شد. در مرحله اول دندان شماره ۱ ابتدا بدون گوتا پرکا و سپس با گوتا پرکای شماره ۲۵ اسکن شد. گوتا پرکای شماره ۲۵ با سیلرهای با بیس رزینی، Zinc Oxide Eugenol (ZOE) و سرامیک به ترتیب در دندانهای شماره ۲، ۳، ۴ قرار گرفت. مرحله دوم همانند مرحله اول انجام شد با این تفاوت که از گوتا پرکای شماره ۳۵ در دندان شماره ۱ و همراه با سیلرهای رزینی و ZOE در دندان های شماره ۲ و ۳ استفاده شد. در مرحله سوم آپچوریشن کانال در دندان های ۲ و ۳ با استفاده از سیلرهای رزینی و ZOE انجام شد. در هر مرحله ۳ اسکن CBCT در شرایط رزولوشن بالا و استاندارد تهیه شد. (Contrast Noise Ratio) CNR در سه پلن ریشه به دست آمد و داده ها با آنالیزهای آماری آنالیز شد.

یافته ها: گوتا پرکا به تنهایی آرتیفکت بیشتری در مقایسه با گوتا پرکا همراه با سیلر داشت. سیلر با بیس ZOE آرتیفکت بیشتری از سایر سیلر ها داشت. بین مراحل سه گانه مختلف اختلاف معناداری مشاهده نشد. و همچنین در رزولوشن های مختلف اختلاف معنی داری در آرتیفکت گوتا پرکا و سیلر ها مشاهده نشد. سیلر با بیس ZOE در ۱/۳ اپیکال و رزینی در ۱/۳ کروئال آرتیفکت بیشتری داشت.

نتیجه گیری: باتوجه به آرتیفکت بیشتر گوتا پرکا نسبت به ترکیب گوتا پرکا - سیلر و کاهش آرتیفکت در ترکیب گوتا پرکا - سیلر رزینی نسبت به گوتا پرکا - ZOE جهت بررسی بهتر تصاویر CBCT از کانال ریشه دندان استفاده از ترکیب گوتا پرکا - سیلر رزینی به هنگام درمان کانال ریشه توصیه می شود.

واژگان کلیدی: توموگرافی کامپیوتری با اشعه مخروطی، آرتیفکت، گوتا پرکا

Introduction

Cone beam computed tomography (CBCT) is a valuable imaging modality in dentistry, which improves the diagnosis, treatment plan and follow-up of patients in various dentistry fields such as implantology, surgery, endodontics and orthodontics due to creation of images in different planes.^[1, 2] It also imposes less costs and radiation dosage compared to computed

tomography.^[3, 4] In CBCT, the polychromatic X-ray interferes with high density and atomic number dental materials such as amalgam, dental implants, metal posts, gutta-percha, orthodontic appliances and so on cause more beam hardening artifacts due to higher absorption of low energy photons compared with higher energy photons.^[5, 6] Artifacts created in images represent a

discrepancy between actual attenuation features of the object and its reconstructed image.^[7] They also reduce the quality and increase the interpretation time by fading out anatomical structures of the region, thereby diminishing the diagnostic accuracy of images.^[8]

Contrast-to-noise ratio (CNR) is an objective indicator of quality control of images^[9] described as the ratio of signal difference (contrast) to image noise level. Artifacts cause lower image contrast and CNR.^[10] Although artifacts cannot be eliminated, they can be reduced by altering exposure parameters, lower-density materials or artifact reduction algorithms.^[11, 12]

Some studies have demonstrated that root canal-treated teeth show many artifacts in CBCT images, which are caused by high-density materials used in root canal treatment such as sealers, intra-canal pins, gutta-percha cone and so on. Moreover, variance has been observed in the abundance of artifacts created by different sealers.^[12, 13] Configuration of CBCT machines such as mA, kVp, voxel size and field of view (FOV) can also affect the observation and detection of filled canals when different materials are used in root canal.^[14]

An ideal sealer for root treatment should have physical and chemical properties including sufficient radiopacity so that it can be distinguished from adjacent anatomical structures such as bones and teeth. Different types of resin-, ZOE-, calcium hydroxide-, glass ionomer- and ceramic-based sealers are available, but each has its own advantages and disadvantages. The purpose of this in vitro study was to quantitatively evaluate and compare CNR in three different sealers including resin-, ZOE- and ceramic-based sealers with two different CBCT resolutions.

Materials & Methods

This study was approved by the Ethics Committee of Babol University of Medical Sciences, Babol, Iran (with the code of IR.MUBABOL.HRI.REC.1398.011). In this experimental study, four maxillary central incisor phantom teeth (Nissin Dental Products Inc., Kyoto, Japan) were used. First, each tooth was placed in a mold under similar conditions, and then an access cavity was created for it. Teeth filling was performed with ProTaper Universal rotary (Dentsply Maillefer, Ballaigues, Switzerland) using Sx, S1, S2 and F1 sequences (canal preparation up to the canal No. 25). Next, the tooth No. 1 (control) was scanned three times

using X MIND (ACTEON Olgiate olona Italy) in standard and high resolution situations. The scan parameters were set as follows:

90 kVp, current of 8 mA, FOV of 8×8 cm, exposure duration of 6 s, and pixel size of 150 μm at standard resolution

90 kVp, current of 8 mA, FOV of 8×8 cm, exposure duration of 9 s, and pixel size of 100 μm at high resolution.

Afterward, the gutta-percha (DiaDent, Korea) No. 25 with 2% taper was placed in canal of tooth No.1, and scans were obtained three times in each of the above-mentioned situations.

The resin-based sealer AH26, Dorifill ZOE-based sealer and sure seal root ceramic-based sealer in the teeth No. 2, 3, and 4, respectively, (Table 1) were injected into the canal. In addition, the gutta-percha No. 25 with 2% taper was placed in teeth canal (No 2,3,4). Scanning was performed three times for each tooth in both high and standard resolution conditions after 24 h and also after completion of the setting process.

From the second phase, due to the lack of access to the sure seal root sealer, AH26 and Dorifill sealers were used to continue the study. In the second phase, gutta-percha and sealers were removed and filling was continued by rotary with F2 and F3 sequences (canal preparation up to the canal No. 35). The tooth No. 1 was scanned three times in high and standard resolution conditions. Then, the gutta-percha No. 35 with 2% taper was placed in the tooth No. 1 canal, and scans were obtained three times in both conditions. Canals of the teeth No. 2 and 3 were filled with AH26 and Dorifill sealers, respectively, and the gutta-percha No. 35 was placed in the canal with 2% taper. After 24 hours, three scans were taken in both conditions.

In the third phase, the gutta-percha and sealers of the previous phase were removed and complete obturation was performed on the teeth No. 2 and 3 respectively with AH26 and Dorifill sealers. Afterward, equal quantities of gutta-percha were placed using the lateral compaction method. After 24 hours, three scans were obtained in high and standard resolution conditions. A total of 66 scans were prepared, and the images were processed using OnDemand3D Dental software. Each scan was examined twice and was considered as an independent sample by one observer.

ICC = 0.823 (CI 95% : 0.786 - 0.854) P<0.001

Mean difference =0.017


Table 1 .The components and manufacturers of root canal sealers used in the study

AH 26	Powder: bismuth trioxide, calcium hydroxide, hexamethylenetetramine and titanium dioxide Paste: bisphenol epoxy resin	Dentsply, Detrey, Konstanz, Germany
Sure Seal Root	Calcium silicate – Calcium sodium phosphosilicate – Zirconium oxide – Thickening agent	Sure-Endo, Seoul, Korea
Dorifill	Zinc oxide –bismuth oxide - titanium oxide	Dorident Company, Vienna, Austria

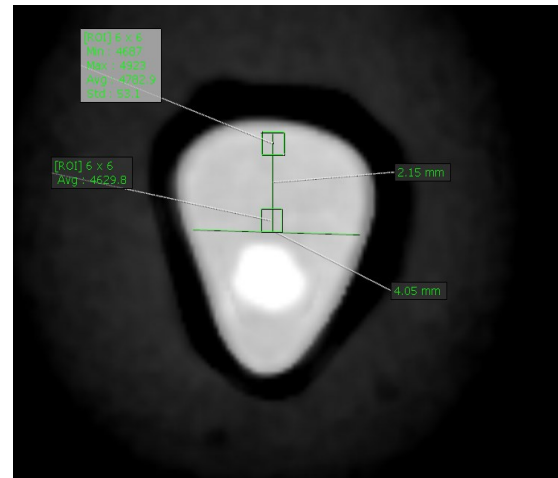
Artifact measurement: To standardize the region of interest (ROI) positions and include the area where the artifact was created, each root was first divided into coronal, medial and apical levels (4.5, 8.5, and 12.5 mm distances from the cemento-enamel junction, respectively). In the axial view, the three levels were considered in two areas (near the canal and near the root wall) (Figure 1). Gray value and standard deviation were obtained in six squares (6×6 pixels) as ROI, and the numbers were placed in the following formula to gain CNR values. Lower CNR values indicate higher artifacts and cause negative influence on image quality.

$$CNR = \frac{|mean_{control} - mean_{tooth}|}{\sqrt{SD_{control}^2 + SD_{tooth}^2}}$$

The obtained data were analyzed with ANOVA, ANOVA repeated measurement, paired t-test and post hoc test.



A



B

Figure 1. Obtained mean and standard deviation of gray value in control (A) and root filled canal (B)

Results

In this study, it was found that gutta-percha alone had less CNR (more artifacts) compared to the combination of gutta-percha with each of the other sealers.

In the first phase (canal preparation up to the canal No.25), the gutta-percha alone had significantly more artifacts than the combination of gutta-percha with other sealers. Moreover, the gutta-percha with ZOE-based sealer had significantly more artifacts than the combination of gutta-percha with ceramic- or resin-based sealers (p=0.001). After the post hoc test was done, the difference between gutta-percha with resin – based sealer and ceramic- based sealer was not significant (p=0.73).

In the second phase (canal preparation up to the canal No.35) as well, the gutta-percha alone had significantly more artifacts compared to the combination of gutta-percha with resin- or ZOE-based sealers. Furthermore, the gutta-percha with ZOE-based sealer had significantly more artifacts than resin-based sealers (p=0.002). This significant difference was evident in obturation phase, too (p=0.001) (table 2). After post hoc test was done, the difference in groups was significant in the second and third phase (p<0.05).

In the canal with ZOE-based sealer, the artifact was lower at the coronal third in comparison with middle and apical thirds (p=0.001). However, in the resin-based sealer, the artifact was significantly higher in the coronal third than middle and apical thirds. Nevertheless, the difference was not significant at the

three root levels in the groups of gutta-percha and ceramic-based sealer (Table 3). In addition, the difference of CNR in standard and high resolution of CBCT was not significant. The assessment of artifact in two areas of close to the canal and far from the canal illustrated that the difference only in gutta-percha group

with standard resolution and in resin-based sealer group with high resolution was significant. Further, the artifact was observed to be higher significantly in the area adjacent to the root canal ($p=0.001$ and 0.04 , respectively) (Table 4).

Table 2. Mean±SD of CNR values for Gutta Percha, Gutta Percha +Resin, Gutta Percha +ZOE Gutta Percha +Ceramic by steps of preparation

	First preparation (25)	Second preparation (35)	Third preparation (Obturation)	p-value*
Gutta Percha	0.35±0.32	0.35±0.24	—	0.99
Gutta Percha +Resin	1.01 ± 0.70	1.00 ± 0.57	0.87 ± 0.5	0.28
Gutta Percha +ZOE	0.59 ± 0.45	0.63 ± 0.36	0.53 ± 0.28	0.27
Gutta Percha +Ceramic	1.02 ± 0.61	—	—	—
p-value*	0.001	0.002	0.001	—

*ANOVA test

Table 3. Mean±SD of CNR values for Gutta Percha +ZOE Gutta Percha +Resin, Gutta Percha Gutta Percha +Ceramic by coronal, middle and apical sections of teeth

	Coronal	Middle	Apical	p-value*
Gutta Percha	0.43 ± 0.36	0.41 ± 0.30	0.33 ± 0.22	0.14
Gutta Percha +Resin	0.71 ± 0.37	0.95 ± 0.68	1.22 ± 0.59	0.001
Gutta Percha +ZOE	0.83 ± 0.39	0.49 ± 0.32	0.43 ± 0.27	0.001
Gutta Percha +Ceramic	1.00 ± 0.44	0.91 ± 0.91	1.16 ± 0.30	0.34

*ANOVA test

Table 4. Mean±SD of CNR values for Gutta Percha Gutta Percha +Resin Gutta Percha +ZOE Gutta Percha +Ceramic by the distance to root canal

	High Resolution		pvalue*	Standard Resolution		p-value*
	closed to canal	far to canal		closed to canal	far to canal	
Gutta Percha	0.40 ± 0.26	0.31 ± 0.25	0.47	0.20 ± 0.15	0.65 ± 0.31	0.001
Gutta Percha +Resin	0.88 ± 0.54	0.97 ± 0.69	0.04	1.01 ± 0.58	0.98 ± 0.56	0.92
Gutta Percha +ZOE	0.67 ± 0.33	0.43 ± 0.32	0.76	0.74 ± 0.41	0.49 ± 0.34	0.70
Gutta Percha +Ceramic	0.75±0.46	1.46±0.71	0.22	0.87 ± 0.60	1.02 ± 0.43	0.17

*t- test

Discussion

In this study, it was found that the gutta-percha alone created more artifacts (less CNR) compared to the combination of gutta-percha with either resin-, ceramic- or ZOE-based sealers. The gutta-percha is the most popular material for root canal filling due to its acceptable biological, mechanical and technical features. Moreover, the gutta-percha is easily observable in conventional images. Nonetheless, it creates a significant quantity of artifacts in images, and, in turn, reduces the quality of CBCT images. Features that

cause radiopacity in gutta-percha are associated with its non-organic fillers, including zinc and barium.^[7] Freitas-e-Silva et al. showed that due to the high volume of intra-canal gutta-percha, the use of different sealers had no effect on the vertical root fracture diagnosis.^[15] The higher number of artifacts could be due to the higher density of gutta-percha compared to the density of the gutta-percha and sealer combination.

The present study demonstrated that the ZOE-based sealers produced more artifacts than ceramic- and resin-based sealers, and the difference between ceramic- and resin-based sealers was not significant. However, in the

studies of Celikten et al. ^[11] and Brito -Junior et al. ^[13], the ceramic-based sealers created less artifacts compared to resin-based sealers. The discrepancy in results might be due to differences in used resin and ceramic sealers. Further, in the current study, the ceramic-based sealer was used only in the first phase, which may be the reason for different results from those of the previous studies. The presence of radiopacifier and other chemicals (bismuth oxide, barium sulfate, zinc oxide, etc.) in sealers can lead to their different densities. Sealers create a number of artifacts in the form of hypodense lines that can mimic fractures. ^[15] In the ongoing study, the presence of zinc oxide and bismuth oxide caused more artifacts in the sealer structure with ZOE base (Table 1) due to its higher density. Moreover, phantom teeth rather than extracted teeth were used in the present study. The advantages of phantom teeth include standard morphology and possibility to produce radiographs. In addition, different dentin thicknesses observed in normal teeth, which result in the loss of heterogeneous X-rays, are not observed in phantom teeth. Thus, they can show the effects of weakening of materials inside the canal regardless of other factors such as dentin thickness. However, the disadvantage of using phantom teeth is that they are not yet examined on natural teeth.

We noted that the difference in scan time and voxel size had no effects on the quantity of artifacts, which is in agreement with the study of Pauwels. ^[16]

Based on the study of Iikubo et al. ^[17], the use of scanning mode with smaller voxel size and target placement at the FOV center is the best way to reduce gutta-percha cone artifacts in CBCT imaging, which is inconsistent with the results of this study. This discrepancy could be due to differences in FOV and used devices. In the study of Demirtürk-Kocasarac et al., higher kVp with low resolution and metal artifact reduction (MAR) application led to higher CNR compared to lower kVp with normal or high resolution without MAR. ^[18]

In the current study, there was no significant difference between artifacts in areas near to and far from the canal. The only exceptions were in the gutta-percha group with standard resolution and resin-based sealer group with high resolution, which may be due to their proximity to each other. In the present study, the artifacts were mostly observed in ZOE-based sealers in the apical part and in resin-based sealers in the coronal part. In the study conducted by Fox et al., the artifacts

were different in various root parts. Artifacts were more abundant in the coronal segment of the filled root due to the higher volume of the material. Moreover, by tapering the canal, less artifacts were found in the 1/3 medial and apical parts. ^[7] The greater quantity of artifacts produced by ZOE-based sealers in the apical part was probably due to its lower concentration and accumulation in the apical part than in the coronal part. An ideal sealer has characteristics such as good adhesion, adequate sealing, radiopacity, dimensional stability during setting, tissue tolerance, antibacterial effect, insolubility in tissue fluids and discoloration for dental structures. ^[19] Calcium silicate-based bioactive sealers such as sure-seal root have become popular due to their good mechanical, chemical and cytocompatibility properties. They are premixed, insoluble and hydrophilic. In general, bioceramic sealers are recommended owing to their low particle size, excellent viscosity, and minimum shrinkage during the setting phase. ^[20]

Nowadays, different sealers with better sealing characteristics have been replaced with ZOE-based sealers as well as canal filling with gutta-percha and ZOE-based sealer is considered below the standard of care. ^[21] According to the results of this study and higher quantities of artifacts induced by ZOE-based sealers, it is recommended to exclude the use of this sealer group. One of the limitations of this study was the lack of access to ceramic sealers after the first phase. It is suggested to perform a more thorough study on ceramic-base sealers. In addition, a further study is recommended with variable kVp and FOV values.

Conclusion

Considering the greater artifact of gutta-percha than gutta-percha sealer and the reduction of artifact in the gutta-percha-resin sealer compared to gutta-percha-ZOE sealer, the use of a gutta-percha-resin sealer is recommended for better evaluation of the CBCT images from root canal.

Funding: This study was a part of research project (Grant no: 9707138), supported and funded by Babol University of Medical Sciences. There is no conflict of interests.

Conflict of interest disclosure: The authors state that they have no conflict of interest

Author's Contribution

The study was designed by Sina Haghanifar and Atefeh Gholampour. Sina Haghanifar, Atefeh Gholampour and Ali Soleymani defined the conceptual content of the research. The study data were collected by Atefeh Gholampour. Statistical analysis and interpretation of data were accomplished by Ali Bijani. Preparation of manuscript was performed by Atefeh Gholampour and Sina Haghanifar. Study supervision was performed by Sina Haghanifar.

References

1. Panjnoush M, Kheirandish Y, Kashani PM, Fakhari HB, Younesi F, Mallahi M. Effect of exposure parameters on metal artifacts in cone beam computed tomography. *J Dent (Tehran)* 2016;13:143.
2. Yuan F, Chen L, Wang X, Wang Y, Lyu P, Sun Y. Comparative evaluation of the artefacts index of dental materials on two-dimensional cone-beam computed tomography. *Sci Rep* 2016; 6: 26107..
3. Rabelo KA, Cavalcanti YW, de Oliveira Pinto MG, Sousa Melo SL, Campos PSF, de Andrade Freitas Oliveira LS, et al. Quantitative assessment of image artifacts from root filling materials on CBCT scans made using several exposure parameters. *Imaging Sci Dent* 2017;47:189-97.
4. Chang E, Lam E, Shah P, Azarpazhooh A. Cone-beam computed tomography for detecting vertical root fractures in endodontically treated teeth: a systematic review. *J Endod* 2016;42:177-85.
5. Hekmatian E, Karbasi Kheir M, Fathollahzade H, Sheikhi M. Detection of vertical root fractures using cone-beam computed tomography in the presence and absence of gutta-percha. *Sci World J* 2018;2018:1920946.
6. Fakhari HB, Emami R, Moloudi K, Mosavat F. Effects of artifact removal on cone-beam computed tomography images. *Dent Res J (Isfahan)* 2018;15:89.
7. Fox A, Basrani B, Kishen A, Lam EWN. A novel method for characterizing beam hardening artifacts in cone-beam computed tomographic images. *J Endod* 2018;44:869-74.
8. Freitas DQ, Fontenele RC, Nascimento EHL, Vasconcelos TV, Noujeim M. Influence of acquisition parameters on the magnitude of cone beam computed tomography artifacts. *Dentomaxillofac Radiol* 2018;47:20180151
9. Tadinada A, Jalali E, Jadhav A, Schincaglia GP, Yadav S. Artifacts in Cone Beam Computed Tomography Image Volumes: An Illustrative Depiction. *J Mass Dent Soc* 2015;64:12-5.
10. Kursun-Cakmak EŞ, Demirturk Kocasarac H, Bayrak S, Ustaoglu G, Noujeim M. Estimation of contrast-to-noise ratio in CT and CBCT images with varying scan settings in presence of different implant materials. *Dentomaxillofac Radiol* 2019;48:20190139.
11. Celikten B, Jacobs R, de Faria Vasconcelos K, Huang Y, Shaheen E, Nicolielo LFP, et al. Comparative evaluation of cone beam CT and micro-CT on blooming artifacts in human teeth filled with bioceramic sealers. *Clin Oral Investig* 2019;23:3267-73.
12. Vasconcelos KF, Nicolielo LF, Nascimento MC, Haiter-Neto F, Bóscolo FN, Van Dessel J, et al. Artefact expression associated with several cone-beam computed tomographic machines when imaging root filled teeth. *Int Endod J* 2015;48:994-1000.
13. Brito-Júnior M, Santos LA, Faria-e-Silva AL, Pereira RD, Sousa-Neto MD. Ex vivo evaluation of artifacts mimicking fracture lines on cone-beam computed tomography produced by different root canal sealers. *Int Endod J* 2014;47:26-31.
14. Celikten B, Jacobs R, deFaria Vasconcelos K, Huang Y, Nicolielo LFP, Orhan K. Assessment of volumetric distortion artifact in filled root canals using different cone-beam computed tomographic devices. *J Endod* 2017;43:1517-21.
15. Freitas-e-Silva A, Mármora B, Barriviera M, Panzarella FK, Raitz R. CBCT performance and endodontic sealer influence in the diagnosis of vertical root fractures. *J Contemp Dent Pract* 2019;20:553.
16. Pauwels R, Stamatakis H, Bosmans H, Bogaerts R, Jacobs R, Horner K, et al. Quantification of metal artifacts on cone beam computed tomography images. *Clin Oral Implants Res* 2013;24 Suppl A100:94-9.
17. Iikubo M, Nishioka T, Okura S, Kobayashi K, Sano T, Katsumata A, et al. Influence of voxel size and scan field of view on fracture-like artifacts from gutta-percha obturated endodontically treated teeth on cone-beam computed tomography images. *Oral Surg Oral Med Oral Pathol Oral Radiol* 2016;122:631-7.

18. Demirturk- Kocasarac H, Helvacioğlu Yigit D, Bechara B, Sinanoglu A, Noujeim M. Contrast-to-noise ratio with different settings in a CBCT machine in presence of different root-end filling materials: an in vitro study. *Dentomaxillofac Radiol* 2016;45:20160012.
19. Zare Jahromi M, Navabi AA, Ekhtiari M. Comparing coronal discoloration between AH26 and ZOE sealers. *Iran Endod J* 2011;6:146.
20. Huang Y, Celikten B, de Faria Vasconcelos K, Ferreira Pinheiro Nicolielo L, Lippiatt N, Buyuksungur A, et al. Micro-CT and nano-CT analysis of filling quality of three different endodontic sealers. *Dentomaxillofac Radiol* 2017;46:20170223.
21. Mohammadian F, Farahanimastary F, Dibaji F, Kharazifard MJ. Scanning electron microscopic evaluation of the sealer-dentine interface of three sealers. *Iran Endod J* 2017;12:38.