

CASE REPORT

Plastic Bronchitis in a Five-Year-Old Boy Treated Using Extracorporeal Membrane Oxygenation; a Case Report

Tsuyoshi Nojima¹, Hiromichi Naito^{1*}, Takafumi Obara¹, Kohei Tsukahara¹, Atsunori Nakao¹

1. Department of Emergency, Critical Care and Disaster Medicine, Okayama University Graduate School of Medicine, Dentistry and Pharmaceutical Sciences, Okayama, Japan.

Received: December 2020; Accepted: December 2020; Published online: 27 January 2021

Abstract: Plastic bronchitis is an uncommon disorder marked by the production of bronchial casts and acute respiratory failure development. In pediatric cases, influenza infection sometimes results in the obstruction of bronchi and leads to this potentially life-threatening condition. We report the case of a five-year-old boy with plastic bronchitis related to influenza A infection, which could only be recovered by the use of extracorporeal membrane oxygenation (ECMO). ECMO could effectively provide sufficient oxygenation for patients suffering from severe reversible acute respiratory failure. If patients infected with the influenza virus present acute respiratory distress with total lung atelectasis, clinicians should consider the diagnosis of plastic bronchitis and the subsequent treatment interventions with ECMO in a severe cases.

Keywords: Bronchitis; Influenza A virus; extracorporeal membrane oxygenation; respiratory distress syndrome

Cite this article as: Nojima T, Naito H, Obara T, Tsukahara K, Nakao A. Plastic Bronchitis in a Five-Year-Old Boy Treated Using Extracorporeal Membrane Oxygenation; a Case Report. Arch Acad Emerg Med. 2021; 9(1): e16.

1. Introduction

Plastic bronchitis is a life-threatening complication defined by the production of large, branching bronchial casts that are often expectorated but may be only recognized during bronchoscopy. Clinical manifestations may include fast and incremental respiratory distress with lung consolidation or atelectasis showing on chest radiograph. In most patients, bronchial casts are secondary to underlying heart or lung diseases known to be associated with allergy, asthma, or influenza infection (1-4).

Here, we report the case of a five-year-old boy with plastic bronchitis associated with influenza A successfully treated with extracorporeal membrane oxygenation (ECMO). Our case indicates that in pediatric patients suffering from severe plastic bronchitis with acute respiratory failure, venovenous (VV) ECMO may be the only effective lifesaving procedure for providing sufficient oxygenation. If patients infected with the influenza virus present the combination of total lung atelectasis and acute respiratory distress, clinicians should con-

sider the diagnosis of plastic bronchitis and intervene with early bronchoscopy and consider application of ECMO.

2. Cases presentation

A five-year-old boy, 15 kilograms in weight and 107 cm in height, was admitted to a local hospital after three days of fever, coughing, and aggravating dyspnea. A rapid influenza test conducted using a nasopharyngeal swab was positive for the influenza A virus. He was transported to our tertiary emergency medical center due to respiratory failure. Upon physical examination after emergent transfer to our emergency department, his blood pressure was 174/101 mmHg, pulse rate was 179 bpm, respiratory rate was 30/minute, and body temperature was 37.8°C. His percutaneous oxygen saturation was 86% with a respirator delivering 100% oxygen, and breathing sounds were decreased in both lungs. His venous blood gas analysis and blood chemical analysis results are shown in Table 1. His chest X-ray and computed tomography showed pneumothorax in both lungs and consolidation in the right lung (Figure 1).

Due to deoxygenation and deterioration as a result of respiratory distress, the patient had to be intubated and placed under mechanical ventilation. Flexible bronchoscopy revealed thick secretions and right lower lobe bronchus lumen obstruction with a rubbery, whitish substance consistent with

*Corresponding Author: Hiromichi Naito; Okayama University Graduate School of Medicine, Dentistry and Pharmaceutical Sciences, Department of Emergency, Critical Care, and Disaster Medicine. 2-5-1 Shikata, Okayama, Japan 700-8558. Tel: +81-86-235-7426, Fax: +81-86-235-7427, e-mail: naito.hiromichi@gmail.com



Table 1: Blood chemical analysis on arrival

Variable	Value	Variable	Value
Venous blood gas		Clinical chemistry test	
pH	7.201	CRP (mg/dL)	10.21
PaCO ₂ (mmHg)	73.7	TP (g/dL)	6.4
HCO ₃ (mmol/L)	27.4	ALB (g/dL)	3.7
BE (mmol/L)	-8.1	AST (IU/L)	28
AG (mmol/L)	18.7	ALT (IU/L)	15
Lactate (mmol/L)	0.8	LDH (IU/L)	428
Complete blood count		ALP (IU/L)	700
WBC (/μL)	34,010	G-GTP (IU/L)	10
Neut (%)	94	CK (IU/L)	56
Lymp (%)	3	T-Bil (mg/dL)	0.7
Mono (%)	2.5	S-AMY (IU/L)	26
Hb (g/dL)	13.1	BUN (mg/dL)	16.7
Plt (/μL)	40.5 × 10 ⁴	Crea (mg/dL)	0.28
Blood coagulation test		UA (mg/dL)	4.9
INR	1.22	Na (mEq/L)	146
aPTT (sec)	29.2	K (mEq/L)	4.6
Fibrinogen (mg/dL)	454	Cl (mEq/L)	106
FDP (μg/mL)	34	Ca (mg/dL)	9.4
D-dimer (μg/mL)	18.1		

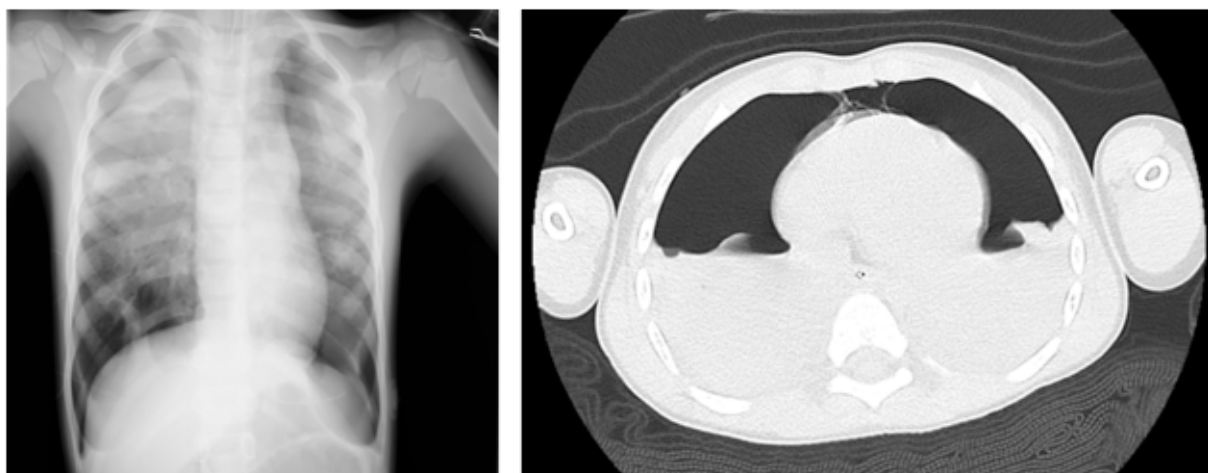


Figure 1: The chest X-ray and computed tomography on arrival showed pneumothorax and pleural effusion in both lungs.

an endobronchial cast (Figure 2). The clinical diagnosis of acute respiratory failure, pneumothorax, and plastic bronchitis associated with influenza A infection was made. Considering persistent respiratory distress in 41 of peak inspiratory pressure and subsequent circulatory collapse, the patient was placed on venous-arterial (VA) ECMO through the right cervical artery and vein with chest drainage tubes on both chest cavities. Initial VA-ECMO conditions were as follows: oxygenator; Biocube (NIPRO, Japan), venous line; right internal jugular vein using BioMedicusTMNextGen catheter 17Fr (Medtronic, Mexico), arterial line; right internal jugular artery using BioMedicus catheter 12Fr (Medtronic, Mexico),

blood flow 1.5L/min, speed 2,780 rpm, oxygen sweep gas 3.0L/min, and the fraction of oxygen 0.8 using heparin. Antimicrobial treatment included 2,250 mg/day of cefotaxime, 900 mg/day of vancomycin, and 150 mg/day of peramivir. Figure 3 shows the progress after hospitalization. On the fourth day, since initiation of VA-ECMO had stabilized the patient's circulatory condition, VA-ECMO was converted to VV-ECMO through the right cervical vein and femoral vein. Initial VV-ECMO conditions were as follows: oxygenator; Biocube (NIPRO, Japan), venous line; right internal jugular vein using BioMedicusTMNextGen catheter 17Fr (Medtronic, Mexico), arterial line; right femoral vein us-

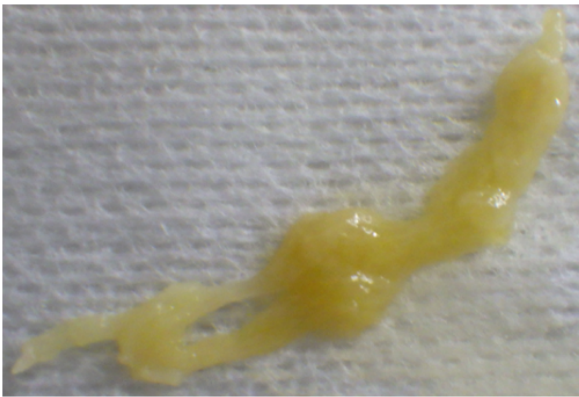


Figure 2: Photograph of a representative cast spontaneously expectorated from a patient with plastic bronchitis during bronchoscopy.

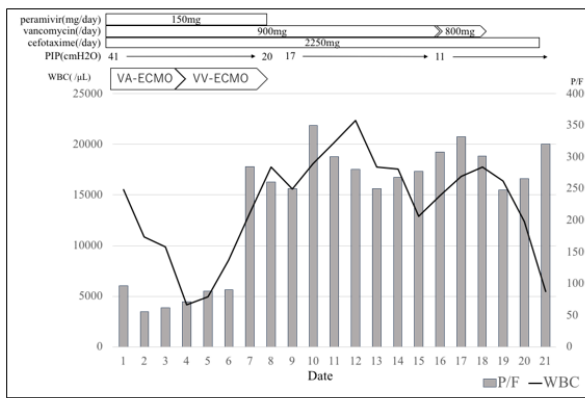


Figure 3: Progress of respiratory parameters of the patient during hospitalization. PIP: peak inspiratory pressure, VA-ECMO: Venous-Arterial extracorporeal membrane oxygenation, VV-ECMO: Veno-Venous extracorporeal membrane oxygenation, P/F: PaO₂/FiO₂.

ing BioMedicusTMNextGen cateter 15Fr (Medtronic, Mexico), blood-flow 1.52 L/min, speed 2010 rpm, oxygen sweep gas 2.0 L/min, and the fraction of oxygen 1.0 using heparin. On the eighth day, his breathing improved, so we switched from VV-ECMO to ventilation management only. Mechanical ventilator conditions were as follows: assist mode and control mode by pressure control ventilation; positive end-expiratory pressure 5 cmH₂O; the fraction of oxygen 0.6; pressure control 15 cmH₂O; and respiratory rate 15. Frequent removal of purulent mucous plugging of the airway was required. ECMO support was discontinued after nine days. The patient was gradually weaned off respiratory support, extubated on day 20, and transferred to a rehabilitation hospital on day 21. He has remained well over a 2-month follow-up period.

3. Discussion

Plastic bronchitis is an uncommon and underrecognized but life-threatening condition marked by notable blockage of the large airways by mucous plugs (5). Prompt diagnosis and early intervention, including removing the firm, cohesive, branching casts using bronchoscopy, are critical. Mechanical ventilation is not always successful in critically ill plastic bronchitis patients. High airway pressure to achieve adequate oxygenation may result in barotrauma, as seen in our patient. The fast clinical deterioration that does not respond to standard therapies makes ECMO a critical adjunct therapy for plastic bronchitis treatment. The rubbery casts in the airway seen in plastic bronchitis are known to comprise fibrin, mucin, or a mixture of both and can obstruct the airways completely or partially. According to a recent well-defined classification of casts based on their composition and underlying pathology (6), casts are divided into two types: inflammatory casts comprising fibrin and dense inflammatory infiltrate associated with respiratory infection or asthma (type 1), and acellular casts comprising mostly mucin related to congenital heart diseases (type 2). Histological examination of the casts can point to underlying diseases and may be helpful in therapeutic decision making. Although acute mortality can occur in patients with both types of casts, standard therapeutic strategies have not been established. Type 1 cast survivors seem to be well-controlled with inhaled steroids. Optimal therapy for type 2 cast patients has not been fully determined; prognosis probably depends on underlying cardiac status. Various treatment options have been advocated (7). In addition to repeated bronchoscopic extraction of casts, clinicians should consider inhalation heparin when treating the underlying disorders fail, and the casts are largely composed of fibrin (1, 8, 9). Heparin is ineffective for fibrin-containing casts but has anti-inflammatory properties that can reduce the secretion of mucin. Chest physiotherapy, acetylcysteine, DNase, and systemic corticosteroids have all been used (10). Since tissue factor activation of the fibrin pathway can attenuate vascular leak, case reports have shown that inhalation of recombinant tissue plasminogen activator can improve plastic bronchitis through fibrin depolymerization (8). Of note, asthma medication administration, like inhaled corticosteroids or beta-agonists, provides only a marginal benefit in most plastic bronchitis cases.

4. Conclusion

In pediatric patients with fast and progressive respiratory distress and lung consolidation or atelectasis showing on chest radiograph associated with influenza infection, clinicians should consider the possibility of plastic bronchitis and should intervene with early bronchoscopy treatment. For patients with life-threatening progressive respiratory failure, in



whom significant cast obstruction may advance to cardiorespiratory collapse, prompt therapy with ECMO may be effective and lifesaving, and it may facilitate full recovery of normal pulmonary function.

5. Ethical issues

Written informed consent was obtained from the patient for publication of this case report and accompanying images. This case report was approved by the Ethics Committee of Okayama University (ethics code: K2103-032).

6. Declarations

6.1. Acknowledgements

No funding supported this study.

6.2. Authors' relationships

All authors met the criteria for authorship contribution based on the international committee of medical journal editors' recommendations.

6.3. Conflict of interest

The authors declare no conflicts of interest.

6.4. Funding

None.

References

- Deng J, Zheng Y, Li C, Ma Z, Wang H, Rubin BK. Plastic bronchitis in three children associated with 2009 influenza A(H1N1) virus infection. *Chest*. 2010;138(6):1486-8.
- Zhang X, Vinturache A, Ding G. Plastic bronchitis in a 3-year-old boy. *CMAJ*. 2019;191(48):E1336.
- Okada Y, Okada A, Narumiya H, Iiduka R, Katsura K. Bloody Bronchial Cast Formation Due to Alveolar Hemorrhage Associated with H1N1 Influenza Infection. *Intern Med*. 2017;56(20):2747-51.
- Kim S, Cho HJ, Han DK, Choi YD, Yang ES, Cho YK, et al. Recurrent plastic bronchitis in a child with 2009 influenza A (H1N1) and influenza B virus infection. *J Korean Med Sci*. 2012;27(9):1114-9.
- Brogan TV, Finn LS, Pyskaty DJ, Jr., Redding GJ, Ricker D, Inglis A, et al. Plastic bronchitis in children: a case series and review of the medical literature. *Pediatr Pulmonol*. 2002;34(6):482-7.
- Seear M, Hui H, Magee F, Bohn D, Cutz E. Bronchial casts in children: a proposed classification based on nine cases and a review of the literature. *Am J Respir Crit Care Med*. 1997;155(1):364-70.
- Rubin BK. Plastic Bronchitis. *Clin Chest Med*. 2016;37(3):405-8.
- Heath L, Ling S, Raczy J, Mane G, Schmidt L, Myers JL, et al. Prospective, longitudinal study of plastic bronchitis cast pathology and responsiveness to tissue plasminogen activator. *Pediatr Cardiol*. 2011;32(8):1182-9.
- Soyer T, Yalcin S, Emiralioglu N, Yilmaz EA, Soyer O, Orhan D, et al. Use of serial rigid bronchoscopy in the treatment of plastic bronchitis in children. *J Pediatr Surg*. 2016;51(10):1640-3.
- Madsen P, Shah SA, Rubin BK. Plastic bronchitis: new insights and a classification scheme. *Paediatr Respir Rev*. 2005;6(4):292-300.