



Histological Study of the Placenta in Neonates With Intrauterine Growth Retardation

Hossein Mohammad Alizadeh Fard¹, Fatemehe Afshari^{1*}, Zahra Ghatre Samani²

Abstract

Objective: Placenta is the maternofetal contact zone, provided by normal membranes and endometrium, for which the intrauterine fetal life depends on. Regarding the importance of placenta in embryonic period, this study aims at investigating the histopathological changes of placenta in newborns with intrauterine growth retardation (IUGR).

Materials and Methods: This study was performed on two groups (control and experimental) of pregnant women with IUGR fetus in the Histological Department of Medical School of Azad University, Tabriz. In the experimental group, 30 samples of IUGR placentas were examined. The samples were first fixed in formalin, embedded in paraffinized mold, and cut into 5 μ m sections. After that, the samples were prepared for staining with Hematoxylin and Eosin (H&E), trichrome, and PAS techniques.

Results: Findings showed the increase of syncytial knots and fibrinoid, the presence of villous fibrosis, and decrease of glycogen deposit in the experimental group. In addition, statistical investigations suggested that placental and fetal weights in the experimental group were significantly lower than control group ($P < 0.05$).

Conclusion: The results obtained from this study showed that fetal placental and birth weights were lower than control group. Pathological results showed increase of syncytial knots and fibrinoid in the experimental group in comparison to control group.

Keywords: Fetal growth retardation, Fibrosis, Gestational age, Placenta

Introduction

Placenta is the maternofetal contact zone, provided by normal membranes and endometrium, for which the intrauterine fetal life depends on. The placenta is composed of both maternal and fetal tissues. It allows the transfer of nutrients and oxygen from the mother to the fetus and the transfer of metabolic wastes back from the fetus to the mother. The first and most important cause of fetal death is low birth weight (LBW). Intrauterine growth retardation (IUGR) or small for date (SFD) babies are those whose birth weight is less than 10th percentile (1). There are several proven reasons for IUGR, including maternal diseases such as preeclampsia, dietary restrictions, fetal infections and genetic malformations; however, in some IUGR cases there is not any certain fetal or maternal cause. Placenta of IUGR neonates may yield a clue about the cause of growth restriction (2). The risk of mortality is high among IUGR neonates during neonatal (28 days postpartum) and nursing periods (3).

In a study done for the first time by Aherne and Dunnill, quantitative aspects of placental structure of 50 samples were investigated. These researchers worked out volume proportions of placental villi and observed that IUGR

neonates had placentas with reduced mean volumes (350 mL). Parenchyma and placental capillary surface area of IUGR neonates was significantly lower than the normal level (4). In a study by Teasdale, placentas of IUGR and normal neonates were examined. They concluded that the placental villous surface area of IUGR neonates was smaller than that of normal neonates (5).

Regarding the importance of placenta in embryonic period, this study aims at investigating the histopathological changes of placenta in IUGR neonates.

Materials and Methods

To perform this study, two groups (control and experimental) were used, and 30 samples were examined in each group. This was done by studying the appearance of maternal and fetal placenta after delivery and removal of it in IUGR neonates. Then, placental samples were drawn, and then fixed in formalin, embedded in paraffinized mold, cut into 5 μ m sections and prepared for staining with Hematoxylin and Eosin (H&E), trichrome and PAS techniques. The samples were then investigated and compared with an optical microscope. Quantitative information about placenta and fetus was assessed through histological

Received 6 February 2016, Accepted 12 June 2016, Available online 22 June 2016

¹Department of Histopathology, Tabriz Branch, Islamic Azad University, Tabriz, Iran. ²Department of Gynecology, Tabriz Branch, Islamic Azad University, Tabriz, Iran

*Corresponding author: Fatemehe Afshari, Department of Histopathology, Tabriz Branch, Islamic Azad University, Tabriz, Iran. Tel: +984134784090, Email: f-afshar@iaut.ac.ir

evaluation of the samples using SPSS.

Results

The results obtained from this study were evaluated statistically and histopathologically. Histochemical analysis showed that H&E reactivity for syncytial knot was much stronger in experimental group (Figures 1A and 1B) and analysis also showed decrease of PAS and trichrom reaction intensity in comparison with control group (Figure 1C-F). There is not any significant difference in the first and fifth-minute APGAR score between the two groups (Figures 2 and 3), but birth weight and placental weight in control group was significantly higher than experimental group (Figures 4 and 5).

Statistical Results

The Assessment of the First APGAR

There is not any significant difference in the 1st-minute APGAR score between the two groups (Figure 2).

The Assessment of the Fifth-Minute APGAR

There is not any significant difference in the 5th-minute APGAR score between the two groups ($P=0.335$; Figure 3).

Birth Weight

Birth weight in control group was significantly higher than that of experimental group ($P<0.001$) (Figure 4).

Placental Weight

Placental weight in control group was significantly higher than that of experimental group ($P<0.001$).

Histopathological Results

The results obtained from this study showed increase of syncytial knots and fibrinoid, the presence of villous fi-

brosis and decrease of glycogen deposit in the experimental group. In addition, statistical investigations suggested that placental and fetal weights in the experimental group were significantly lower than control group.

Discussion

Placenta is a structure that allows the transfer of nutrients required for fetal growth, and also the removal of toxins and harmful substances from the fetus. In fact, this structure significantly improves normal growth of fetus during pregnancy (6).

Having nutritious diet and avoiding harmful substances such as alcohol, drugs and tobacco smoke improves the chance of normal fetal growth.

In some rare cases, the placenta may malfunction by inadequate supply of nutrients to the fetus and thus inhibits its development, leading to devastating and irrecoverable effects on fetal growth (7). Fetal growth restriction (FGR) contributes not only to neonatal morbidity and mortality but also to major psychiatric sequelae as depression and suicide. FGR affects 5%-10% of pregnancies (8).

In a series of stereological studies on formalin-fixed placental samples, trichrome-stained tissue sections were selected randomly. Using stereological methods, the exchange surface areas of their peripheral villi and capillaries were estimated; in addition, IUGR was associated with reduced surface areas of villi and this was the principal factor leading to the reduction of layers and membranes in these placentas (9,10).

In our pathological study on investigated placentas, the frequency of intervillous fibrin deposition was higher in IUGR neonates than control group. The pathologic study on the experimental group showed greater frequency of

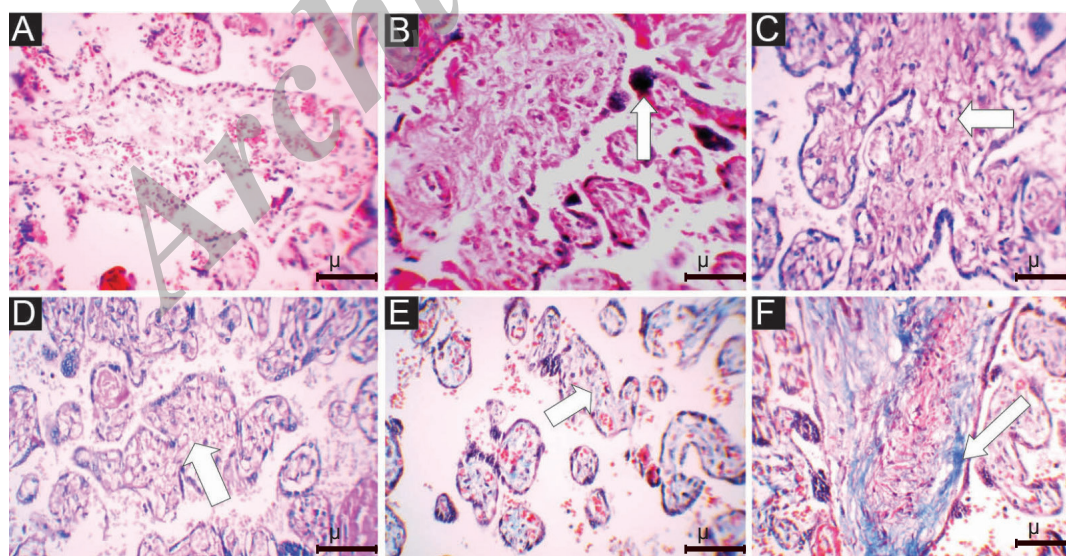


Figure 1. (A) The photomicrograph of placenta in the control group, H&E staining, 400X. (B) The photomicrograph of placenta in the experimental group, H&E staining. Pay attention to increase of syncytial knot, 400X. (C) The photomicrograph of placenta in the control group, PAS staining. Pay attention to glycogen deposition, 400X. (D) The photomicrograph of placenta in the experimental group, PAS staining. Pay attention to decrease of PAS reaction intensity in comparison to control group, 400X. (E) The photomicrograph of placenta in the control group, trichrome staining, 400X. (F) The photomicrograph of placenta the experimental group, trichrome staining. Pay attention to decrease of trichrome reaction intensity in comparison to control group, 400X.

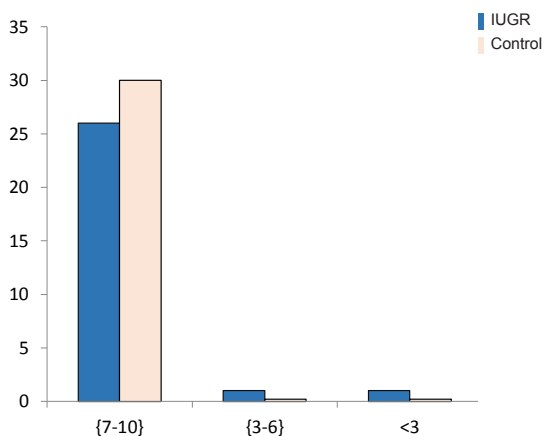


Figure 2. Frequency of the First-Minute APGAR Score in Both Groups

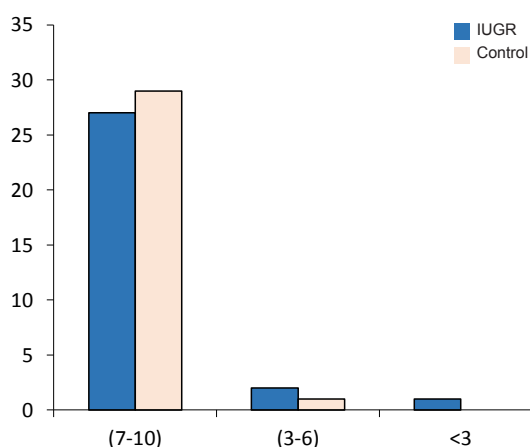


Figure 3 Frequency of the Fifth-Minute APGAR Score in Both Groups

syncytial knotting than control group. Results from some studies indicated increased number of syncytial knots in placentas of IUGR fetuses (11,12).

Findings of Sinclair showed that placental weight and its capacity for transferring metabolites increased linearly in order to compensate the fetus's need when placental/fetal growth ratio was low (13).

Salafia et al investigated placental pathology of IUGR neonates and concluded that placentas of IUGR infants were characterized by decreased fetal-placental weight ratio and placental weight in comparison with placentas of infants with normal weight (14). Their findings supported those of our study.

Consistent with our findings, Davies et al observed that IUGR placentas were smaller in weight, volume and area compared to normal neonates; in addition, marginal insertion of cord was a significant finding in the placentas of IUGR fetuses (15).

Afshari et al in a study showed that maternal chronic diseases like diabetes are associated with increased formation of syncytial knots and increased villous fibrosis (16). The results indicated that placenta of the IUGR group was smaller in comparison to control group. Although some

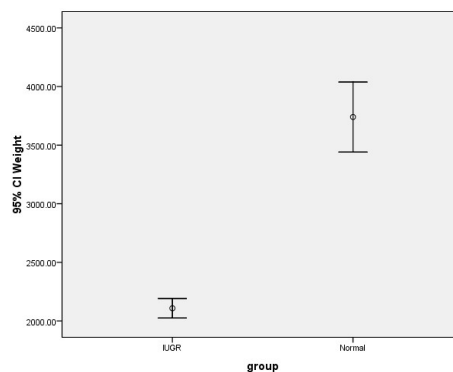


Figure 4. Birth Weight in Control and Experimental Groups ($P < 0.001$).

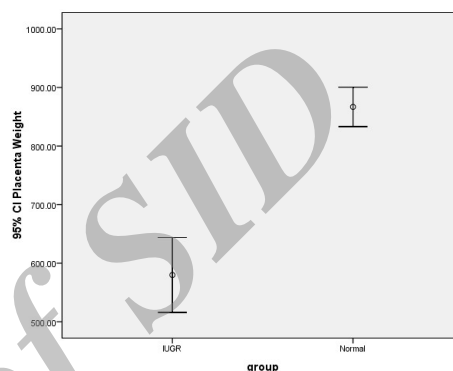


Figure 5. Placental Weight in Control and Experimental Groups Experimental ($P < 0.001$).

studies have shown infarction, thrombosis, ischemia, avascular villi, increased placental membranes thickness and intervillous fibrosis in IUGR (17,18), certain previous researches on IUGR have not demonstrated obvious differentiation between constitutionally and pathologically small fetuses (19). Also some studies reported pathological changes including: fibrin deposition, fibrinoid necrosis, infarction, intervillous chronic villitis, placental intravascular thrombi and villous edema in the placenta of experimental group (20,21). Another study showed that each of the placental findings related to fetal circulatory disorders was more common in IUGR than control group (22).

The findings of the current study demonstrate increase of syncytial knots and fibrinoid, presence of villous fibrosis and decreased level of glycogen deposition in the experimental group. In addition, statistical investigations suggested that placental and fetal weights in the experimental group were significantly lower than control group.

Ethical issues

The ethical issue of this research work was approved by Tabriz Islamic Azad University.

Conflict of interests

We declare that we have no conflict of interests.

Financial support

None.

Acknowledgments

This research was done in Faculty of Medicine, Islamic Azad University, Tabriz in the Histology Department. We are grateful to the staff for their help and support. The authors would like to thank Tabriz Branch Islamic Azad University for financial support of this research, which is based on a research project contract.

References

- Salafia CM. Placental pathology of fetal growth restriction. *Clin Obstet Gynaecol.* 1997;40(4):740-749.
- Goldenberg RL, Nelson KG, Koski JF, Cutter GR. Low birth weight, intrauterine growth retardation and preterm delivery. *Am J Obstet Gynaecol.* 1985;152(8):980-984.
- Park JE. Preventive medicine in obstetrics, pediatrics and geriatrics. In: Park K, ed. *Park's Textbook of Preventive and Social Medicine.* 18th ed. Jabalpur, India: Banarsidas Bhanot Publishers; 2005:395-396.
- Aherne W, Dunnill MS. Quantitative aspects of placental structure. *J Pathol Bacteriol.* 1966;91(1):123-139. doi: 10.1002/path.1700910117.
- Teasdale F. Idiopathic intrauterine growth retardation: histomorphometry of human placenta. *Placenta.* 1984;5(1):83-92.
- Mayhew TM, Manwani R, Ohadike C, Wijesekara J, Baker PN. The placenta in pre-eclampsia and in intrauterine growth restriction: studies on exchange surface areas, diffusion distances and villous membrane diffusive conductances. *Placenta.* 2007;28(2-3):233-238.
- Visser GH, Ribbert LS, Bekedam DJ. Sequential changes in Doppler waveform, fetal heart rate and movement pattern in IUGR fetuses. In: Van Geijn HP, Copray FJA, eds. *A Critical Appraisal of fetal surveillance.* Amsterdam: Elsevier; 1994.
- Bam JE, Odibo AO. Diagnosis and management of fetal growth restriction. *J Preg.* 2011; 2011:640715. doi:10.1155/2011/640715.
- Biswas Sh, Ghosh SK. Gross morphological changes of placentas associated with intrauterine growth restriction of fetuses: a case control study. *Early Hum Dev.* 2008;84(6):357-362. doi:10.1016/j.earlhumdev.2007.09.017.
- Barut F, Barut A, Gun BD, et al. Intrauterine growth restriction and placental angiogenesis. *Diagnostic Pathol.* 2010;5:24-30.
- Tenny B, Parker F. The placenta in toxemia of pregnancy. *Am J Obstet Gynecol.* 1940;39:1000-1005.
- Salafia CM, Vintzileos AM, Silberman L, Bantham KF, Vogel CA. Placental pathology of intrauterine growth retardation at term. *Am J Perinatal.* 1992;9(3):179-184.
- Sinclair JG. Significance of placental and birth weight ratios. *Anat Rec.* 1948;102:245-258.
- Salafia CM, Minior VK, Pezzullo JC, Popek EJ, Rosenkrantz TS, Vintzileos AM. Intrauterine growth retardation in infants less than thirty two weeks gestation; associated place pathological features. *Am J Obstet Gynecol.* 1995;173(4):1049-1045. doi:10.1016/0002-9378(95)91325-4.
- Davies BR, Casanueva E, Arroyo P. Placentas of small-for-date infants: a small controlled series from Mexico City, Mexico. *Am J Obstet Gynecol.* 1984;149(7):731-736.
- Afshari F, Faraji M, Abbasalizade F. Histochemical changes in placenta of diabetic pregnant women. *Adv Biores.* 2014;5(1):37-41. doi: 10.15515/abr.0976-4585.5.37-41.
- Ghomian N, Amouian S, Tavassoli F, Arbabzadeh T. Comparison of placental morphology and histopathology of intrauterine growth restriction and normal infants. *Iranian J Pathol.* 2014;9(1):9-16.
- Vedmedovska N, Rezeberga D, Teibe U, Melderis I, Donders GG. Placental pathology in fetal growth restriction. *Eur J Obstet Gynecol Reprod Biol.* 2011;155(1):36-40. doi:10.1016/j.ejogrb.2010.11.017.
- Raghunath G, Vijayalakshmi, Shenoy V. Study on morphology and the morphometry of the human placenta and its clinical relevance in a population in Tamilnadu. *J Clin Diagnostic Res.* 2011;5(2):282-286.
- Katzman PJ, Genest DR. Maternal floor infarction and massive perivillous fibrin deposition: histological definitions, association with intrauterine fetal growth restriction, and risk of recurrence. *Pediatr Dev Pathol.* 2002;5(2):159-164.
- Syridou G, Spanakis N, Konstantinidou A, et al. Detection of cytomegalovirus, parvovirus B19 and herpes simplex viruses in cases of intrauterine fetal death: association with pathological findings. *J Med Virol.* 2008;80(10):1776-1782. doi: 10.1002/jmv.21293.
- Varli IH, Kublickas M, Papadogiannakis N, Petersson K. Chorioamnionitis without foetal inflammatory response is associated with stillbirth in early preterm pregnancies. *J Matern Fetal Neonatal Med.* 2013;26(10):953-959. doi:10.3109/14767058.2013.766706.

Copyright © 2016 The Author(s); This is an open-access article distributed under the terms of the Creative Commons Attribution License (<http://creativecommons.org/licenses/by/4.0>), which permits unrestricted use, distribution, and reproduction in any medium, provided the original work is properly cited.