

Necrotizing Enterocolitis: A Narrative Review of Updated Therapeutic and Preventive Interventions

Brittany Michelle Reid,^{1,*} and Alecia Thompson-Branch¹

¹Division of Neonatology, The Children's Hospital at Montefiore, Bronx, USA

*Corresponding author: Brittany Michelle Reid, 1825 Eastchester Road, Bronx, New York, USA. Tel: +1-7189044105, Fax: +1-7189042659, E-mail: brreid@montefiore.org

Received 2016 March 18; Revised 2016 June 04; Accepted 2016 June 11.

Abstract

Context: Necrotizing enterocolitis (NEC) remains one of the most common causes of morbidity and mortality for premature infants in the neonatal intensive care unit (NICU). Many theories concerning its pathophysiology and inciting factors have been suggested but progression in preventing the onset of NEC has been minimal. While this article highlights the pathophysiology, management, and outcomes of NEC, it mainly serves as a narrative review to discuss the emerging methods of treatment and prevention.

Evidence Acquisition: A literature search was done using Medline/Pub Med, Cochrane Database of Systematic Reviews via Ovid, and CINAHL Complete with focus on articles published between 2000 and 2016. Searched terms included the following: necrotizing enterocolitis, pathogenesis, prevention, management, breast milk, formula, probiotics, prebiotics, and treatment.

Results: Intestinal barrier dysfunction, hypoxic ischemic injury, receipt of packed red blood cells, immature intestinal immunity and alterations of the gut microbiome of the premature infant were reviewed factors that have been studied related to the pathophysiology of NEC. The presentation, staging and management remain relatively unchanged in the last few decades, though there have been a few studies evaluating different surgical options, various antibacterial regimen, and recently use of moderate hypothermia and amniotic fluid stem cells to treat NEC. Use of breast milk, use of pre-, pro- and postbiotics show promise in the prevention of NEC.

Conclusions: NEC is a likely multifactorial illness of the gastrointestinal tract affecting mostly premature infants. Recent studies have focused on preventative strategies, with promise in pre-, pro- and postbiotics; however continued research is imperative.

Keywords: Necrotizing Enterocolitis, Prevention, Treatment, Narrative Review

1. Context

Although it has been nearly two centuries since the first description of necrotizing enterocolitis (NEC) by Charles Billard, NEC still exists as a major cause of morbidity and mortality for premature infants in neonatal intensive care units (NICUs) (1). In the United States (US) and Canada, it affects approximately 7% of neonates weighing 500-1500 grams, and of that percentage, up to 20-30% die (2). Cases have been noted in term infants; however, they usually have additional factors, such as congenital heart disease or gastroschisis, which make them more vulnerable than their healthy term counterparts. Moreover, NEC is a very costly disease. In the US alone, NEC accounts for about \$5 billion per year for hospitalizations with the average length of stay (LOS) being 22 days longer for medically-managed NEC and 60 days longer for surgically-managed NEC when compared to other preterm infants (3).

In efforts to de-mystify this disease, numerous research studies, both in human and animal models, have been performed. There are many theories regarding its pathophysiology, and like many conditions in medicine, NEC is per-

ceived to be multi-factorial in nature. Although preventative and therapeutic strategies have been tested and implemented, we unfortunately have made little progress towards eradication. Some barriers in this quest for elimination are that NEC has more than one form of presentation and that the definition of stage I, or the mildest form of NEC, is poorly delineated. Some examples of these "NEC impersonators" can be seen in Box 1. We will discuss novel treatments and modes of prevention based on current theories related to NEC pathophysiology and staging.

2. Evidence Acquisition

Literature search was performed using multiple medical databases, particularly Medline/PubMed, Cochrane Database of Systematic Reviews via Ovid, and CINAHL Complete. We focused on articles published between January 2000 and December 2016. PubMed MESH terms included necrotizing enterocolitis, NEC, breast milk, formula, pathogenesis, prevention, management, and treatment of necrotizing enterocolitis. For Ovid/ Cochrane, the

Box 1. Imitators of Necrotizing Enterocolitis

Imitators
1. Spontaneous or isolated intestinal perforations
2. Viral Colitis
3. Misinterpretation of stool gas
4. Variants of food protein-induced enterocolitis syndrome
5. Ischemic bowel disease from another secondary case (e.g. congenital cardiac anomalies)
6. Congenital bowel anomalies

search was limited to full systematic reviews, recently updated reviews, and new reviews. Keywords were mainly phrases such as “necrotizing enterocolitis and treatment” and “necrotizing enterocolitis and prevention.” In CINAHL Complete, combinations of terms were grouped together with “necrotizing enterocolitis” being the primary search word. Other search terms consisted of probiotics, prebiotics, surgery, management, prevention, antibiotics, and enteral feeding.

3. Results

3.1. Pathophysiology

3.1.1. Intestinal Epithelium and Barrier Dysfunction

The intestinal lining normally consists of epithelial cells connected by a system of both intracellular and membrane-spanning proteins that selectively allow solutes/nutrients to pass across while maintaining a protective barrier against harmful organisms (4-7). However, the intestinal lining of the premature infant is frequently under-developed, and as a result, subject to disruption of the intestinal barrier. NEC is then more likely to arise as injury occurs due to effects of pro-inflammatory cytokines and impedance of normal epithelial repair processes.

3.1.2. Hypoxic-Ischemic Injury

Hypoxic-ischemic injury that occurs outside of the immediate perinatal window is a well-studied theory regarding NEC pathogenesis. Conditions, such as congenital heart disease, hemo-dynamically significant patent ductus arteriosus (PDA), and polycythemia, can precipitate a “steal phenomena” where blood is shunted away from less vital organs (e.g.- the gut) and make infants more vulnerable to developing NEC. When the under-perfused gut is then re-perfused, an inflammatory state ensues and injury to the epithelial barrier occurs.

Packed red blood cell (PRBC) transfusion remains a controversial factor in intestinal reperfusion injury and

the subsequent occurrence of NEC. A review of several studies conducted from 2006-2012 showed several common conclusions showing an association between PRBC transfusion and NEC; however, there are other studies suggesting that PRBC transfusion has a protective benefit against NEC (8, 9). As a result, no direct causality has been substantiated.

3.1.3. Toll-Like Receptors and Immature Intestinal Immunity

Toll-like receptors (TLRs), TLR4 in particular, have been shown in primarily animal models to play an important role in NEC. When potentially pathologic flora colonize the premature intestine, TLR 4 is activated by lipopolysaccharides (LPS) and influenced by other innate immune elements which hinder mechanisms for intestinal epithelium repair. In utero TLR4 expression is high, and naturally falls by the time the neonate reaches term gestation. Therefore, preterm babies maintain an elevated level of TLR4 expression potentially making this population more vulnerable to getting NEC (7). With further research, some studies predict that hindrance of TLR4 and other crucial pro-inflammatory proteins may be an avenue of NEC prevention in the future (10).

Aside from TLRs, platelet activating factor, tumor necrosis factor- α , nitric oxide (NO), LPS, several interleukins (ILs), and thromboxanes also contribute to the pro-inflammatory environment leading to NEC (4). Although the exact role of each of these entities is not well delineated, it is generally agreed that the excessive inflammatory response generated from these factors outweighs the effects from anti-inflammatory mediators and that is one of the main occurrences preceding the development of NEC.

3.1.4. Gut Microbiome

Many perinatal and postnatal exposures contribute to a lack of microbial diversity and increased risk of pathogenic colonization (11). Research comparing preterm infants to healthy, breast-fed term controls has shown differences in the class and quantity of bacteria. Additionally, Butel et al. and LaRosa et al. suggest that there may be gestational thresholds for colonization (12, 13). A range from 33 - 36 weeks seems to be a major landmark for colonization with Bifidobacterium species and anaerobic species. More prospective studies investigating the preterm intestinal microbiota are needed to confirm these observations.

Although infection and bacterial exposures are often a perceived cause for NEC, no single type of bacteria has been identified as a direct causative factor. Various studies have implicated the presence of or alterations in different species, but it is most likely overall disruption of normal

bacterial homeostasis and translocation of these bacteria that serve as an inciting factor for NEC.

3.2. Presentation and Staging

3.2.1. Clinical Presentation

It is well known that the clinical symptoms of NEC are often non-specific and its presentation may occur acutely or gradually over time. Neonates may experience abdominal distention with or without overlying skin changes, feeding intolerance/emesis, decreased or absent bowel sounds, increased pre-feeding gastric residuals, and blood in the stool. Other more systemic symptoms include hypotension, poor perfusion, increased bradycardic or apneic events, worsening respiratory status, glucose instability, abnormal heart rate, and temperature instability (1, 2, 14).

The presentation of these symptoms may also vary depending on the gestational age of the infant. Late preterm or term infants are more likely to exhibit abdominal tenderness and guarding, which are more localized symptoms. Very premature infants, on the other hand, often demonstrate the more non-specific symptoms mentioned above. Since full term neonates account for approximately 10% of NEC cases, it is important to take note of these differences in order to take the appropriate interventions when clinical changes occur.

3.2.2. Laboratory and Radiographic Abnormalities

Common laboratory abnormalities that are observed can be helpful, but are not specific to NEC (Table 1). Although a relatively small amount of NEC cases will have concurrent bacteremia, Sharma and Hudak in 2014 quoted rates of concurrent bacteremia/sepsis as high as 40% - 60% (1). Research has been done to seek out biomarkers to assist with clinical diagnosis of NEC, but there has yet to be any which are consistently found. Pneumatosis and portal venous gas remain the pathognomonic radiographic signs of NEC, and are often what NICU physicians aim to assess via abdominal X-rays. However, it can be difficult to distinguish pneumatosis from air within intraluminal fecal material. Other radiographic signs are listed in Table 1. Serial X-rays are needed to monitor progression. Ultrasound is another avenue to evaluate for NEC, especially if X-ray findings are inconclusive. Currently, CT and MRI are not modalities recommended for the evaluation of NEC (15).

3.2.3. Staging of NEC

Staging of NEC has not significantly changed over the past several years; however, the concept of "medical NEC" has been a hot topic with regards to having a clear definition. The Modified Bell's Staging from 1978 is still the current guidelines for NEC categorization (Table 2).

Table 1. Laboratory Markers and Radiographic Signs of NEC

Common Laboratory Abnormalities in NEC (1,11)	Common Radiographic Findings in NEC (1,2,11)
Hyponatremia (< 130)	Pneumatosis or portal venous gas
Metabolic acidosis (bicarbonate < 20 or base deficit < -2)	Pneumoperitoneum or free air
Thrombocytopenia (< 150,000) or an acute decline in platelet counts over a short time period	Bowel wall thickening with or without paucity of gas
Neutropenia (ANC < 1500)	Dilated and/or fixed bowel loops
Elevated I/T ratio (> 0.2)	

3.3. Management and Treatment

3.3.1. Medical Management

The mainstay for management of NEC remains discontinuation of enteral feeds, initiation of broad-spectrum antibiotics, bowel decompression, and supportive therapies for hydration, nutrition, perfusion, and electrolyte abnormalities (1, 3, 17). Escalation of respiratory support may also be needed for infants experiencing respiratory distress or failure. The choice of broad-spectrum antibiotics may vary between institutions, and the optimal antimicrobial regimen is still highly debated today. Generally, a regimen targeting Gram-positive bacteria and gut flora (e.g. - Gram-negatives and anaerobes) plus or minus the administration of an anti-fungal agent is accepted. Autmizguine et al. (18) showed that administration of an anaerobic antimicrobial medication resulted in increased incidence of stricture formation, possibly due to the reduced mortality when compared to the control group. There was no difference in death between the exposed and non-exposed groups. Reassessment with repeated radiologic studies and abdominal girth measurements is also helpful in determining progression versus improvement. Regardless of antibiotic choice, laboratory work-up (e.g. CBC, blood culture, urine culture, markers of inflammation, basic metabolic profile, etc.) should be done prior to initiation of antimicrobial therapy in order to evaluate for concurrent sepsis and metabolic derangements. Early consultation with pediatric surgery specialists is highly recommended. NEC can rapidly evolve and having surgical input early in the course of illness is critical.

Experimental therapies have begun to emerge from animal studies. Moderately-controlled hypothermia, in particular, has been tested in animals and undergone safety and feasibility trials in humans with great promise. Hypothermic therapy resulted in prolonged survival, reduced neutrophil infiltration, prevention of liver energy failure, and attenuation of pro-inflammatory mechanisms that cause local and systemic damage (19). Stem cell ther-

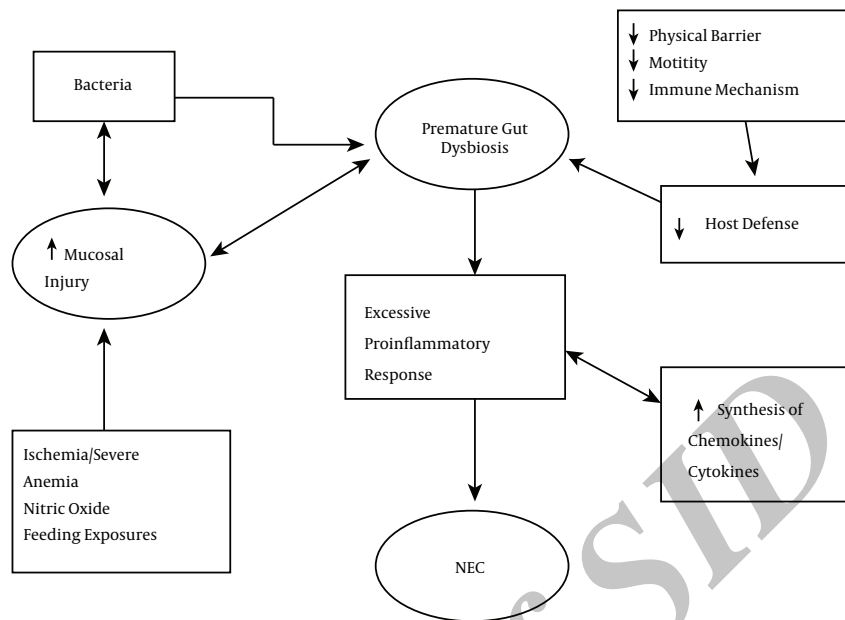


Figure 1. Summary of NEC Pathogenesis

Table 2. Modified Bell Staging Criteria for NEC^a

Stage	Systemic Signs	Intestinal Signs	Radiographic Signs
I: Suspected NEC	Temperature Instability, apnea, and bradycardia	Elevated gastric residuals, mild abdominal distension, occult blood in stool	Normal or mild ileus
IIA: Mild NEC	Similar to Stage I	Prominent abdominal distension ± tenderness, absent bowel sounds, grossly bloody stools	Ileus, dilated bowel loops with focal pneumatosis
IIB: Moderate NEC	Mild acidosis and thrombocytopenia	Abdominal wall edema and tenderness ± palpable mass	Extensive pneumatosis, early ascites ± PVG
IIIA: Advanced NEC	Respiratory and Metabolic acidosis, Mechanical ventilation, hypotension, oliguria, DIC	Worsening wall edema and erythema with induration	Prominent ascites, persistent bowel loop, no free air
IIIB: Advanced NEC	Vital sign and laboratory evidence of deterioration, shock	Evidence of perforation	Pneumoperitoneum

^aBell MJ, Ternberg JL, Feigin RD, Keating JP, Marshall R, Barton L, et al. Neonatal necrotizing enterocolitis. Therapeutic decisions based upon clinical staging. *Ann Surg.* 1978;187(1):1-7 (16).

apy, which is used for refractory inflammatory bowel disease, has also been proposed as a treatment for NEC. In rat models, intraperitoneal injection of amniotic fluid stem cells demonstrated a reduction in NEC, increased intestinal function, and improved survival. The protective effect from these stem cells is believed to be from migration of COX-2 producing cells and secretion of factors that stimulate bowel regeneration (19). Although more research must be done, advances such as these give hope for other novel therapies in the future.

3.3.2. Surgical Management

Signs that surgical intervention is required can include any of the following: abdominal wall cellulitis, presence of free air, concern for intestinal necrosis, or deterioration/lack of response to medical treatment. The decision to undergo primary peritoneal drainage (PPD) or laparotomy is another disputed subject. In some instances, PPD acts a temporizing measure in very labile infants or in infants weighing ≤ 1000 g until laparotomy can be performed. Unfortunately, very few randomized control trials (RCTs) have been done and the ones that have been completed

lack sufficient numbers and do not clearly delineate between isolated intestinal perforation (IIP) and NEC. This is important because infants with IIP have a less severe mortality and morbidity risk and often do better following PPD (1).

For those infants who have laparotomies, the main focus is to effectively debride and excise necrotic bowel, while maintaining as much healthy bowel as possible. Occasionally, infants can have an immediate reanastomosis during the initial procedure. However, most infants require the creation of an enterostomy with mucous fistula until the patient is stable and ready for reanastomosis. An alternative procedure using a single stoma and the Hartmann's pouch is also available.

3.4. Prevention

3.4.1. Formula vs Breast Milk

There are many theories and studies that have been done with regards to feeding techniques and their effects on preventing NEC. Although there is no single consensus, neonatal intensivists agree that giving breast milk (maternal or donor) is the most effective strategy of NEC prevention. Some of the perceived protective factors are L-arginine, nitrate/nitrite, L-glutamine, lactoferrin, and oligosaccharides. A 2008 Cochrane review evaluated the effects of formula feeding versus use of donor breast milk in premature or low birth weight (LBW) infants (20). Eight studies were analyzed for impact on growth and development, with secondary outcomes of neonatal death, development of NEC, incidence of infection, feeding intolerance, and time to achievement of full enteral feeds. In total, over 1000 infants were included and most were less than 32 weeks or less than 1800 grams. This meta-analysis concluded that formula feeding increases short-term growth rates, but is associated with a greater risk (RR 2.5) of developing NEC when compared to infants who received donor milk. Another meta-analysis (21) evaluated 7 studies from the 1970s-1980s and found similar findings with donor milk having a lower risk of NEC (RR 0.21). However, these studies do not address the effect of fortification of donor breast milk and its potential effects.

There are no randomized control trials that compare the effects of non-donor maternal milk and formula on the incidence of NEC and mortality. A 2007 prospective study (22) investigated early human milk (HM) feedings versus formula in VLBW infants. Two hundred and twenty-two neonates were included in the analysis, and they grouped study subjects according to the amount of HM feedings in the first 14 days of life (e.g. $< 50\%$ = low human milk or $\geq 50\%$ = high human milk). They found that enteral feeding containing at least 50% HM in the first 14 days of life correlated with a 6-fold decrease in the odds of developing

NEC. Unfortunately, there are often challenges in providing human milk (maternal or donor) to premature infants, such as poor maternal supply and lack of access to or ability to afford donor milk. Additionally, despite the benefits of human milk, adequate growth for preterm infants on human milk alone is extremely difficult to achieve. Therefore, there often is a need for fortification.

3.4.2. Enteral Feeding Techniques

Despite the variety of fortification methods and formula preparations available, there remains controversy in what type of feeding protocol is best to implement for premature newborns in order to reduce the incidence of NEC. How quickly feeds can be safely advanced, what is the optimal rate of delivery for enteral feeds, and what method is best for fortification are a few of the underlying questions in the journey to form a universal guideline or policy. Starting with trophic feeds between 10 - 20 mL/kg/day is generally an accepted practice, and administering that volume via bolus feeds rather than continuous feeds is preferred due to its more physiologic nature. A randomized control trial (23) examined a cohort of preterm infants and divided them into a "minimal feeding group" (maintained on 20mL/kg/d for first 10 days) and an "advancing feeding group" (started on 20mL/kg/d feeds and advanced by 20mL/kg/d on a daily basis). They determined that the advancing group had a higher risk of NEC and concluded that a slow rate of advancement should be considered in premature newborns. However, the minimal feeding group also had prolonged parenteral nutrition and central line placement, which carries other risks unrelated to NEC. In a 2013 Cochrane review, Morgan et al determined that there is insufficient evidence showing that early trophic feedings compared to enteral fasting or delayed enteral feeding improves feeding tolerance or prevents NEC (24). Other studies have demonstrated similar findings. Furthermore, additives in human milk continue to be a debated topic in neonatology (25, 26). There is no primary literature that proves any particular mode of fortification has a direct effect for promoting NEC. Some small studies suggest that acidified liquid human milk fortifier (HMF) versus powdered HMF may lead to increased cases of NEC (27). More research needs to be done to provide more defined guidelines for enteral feeding practices and preventing the development of NEC.

3.4.3. Prebiotics, Probiotics, and Postbiotics

Prebiotics are supplements or foods that contain a non-digestible ingredient that selectively stimulates the growth of beneficial indigenous bacteria. The most common prebiotics are oligosaccharides, which are known to help with host defense mechanisms. Many studies have

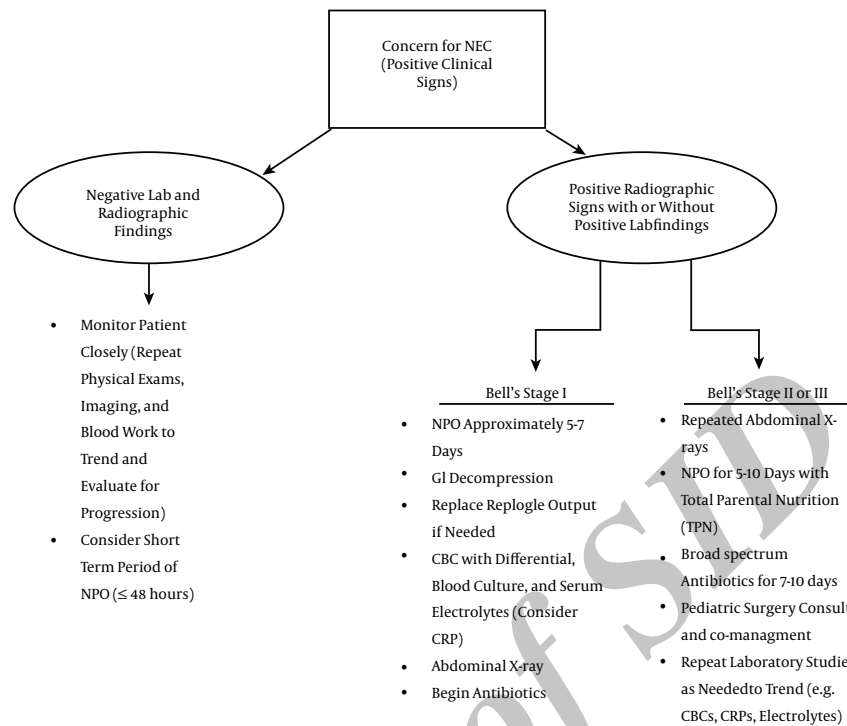


Figure 2. Clinical Algorithm for NEC

shown that prebiotic administration increases Bifidobacteria, an organism that helps intestinal microbial homeostasis and decreases the pathogenic bacteria that can potentially increase the risk for NEC (19, 28). Other protective factors against NEC include improved intestinal motility and prevention of bacterial stasis. However, there is little data that is available on prebiotic administration and its effect on NEC incidence.

Probiotics, on the other hand, act to alter the microflora by boosting the presence of non-pathogenic bacteria. There are multiple strains available with Lactobacillus and Bifidobacteria being the most common and most studied. Some research suggests that daily probiotic administration can decrease the incidence of NEC stage 2 or greater without increasing the incidence of sepsis, particularly in VLBW infants (29-32). The ProPre-Save Study analyzed 400 VLBW neonates who were assigned to 1 of 4 groups: Probiotic, prebiotic, synbiotic (combination of prebiotics and probiotics), or placebo (33). In addition to demonstrating less feeding intolerance and better weight gain in the probiotic and prebiotic groups, this study found that the rate of Bell stage ≥ 2 NEC was lower in the probiotic and synbiotic groups when compared to the placebo and prebiotic groups. Despite these findings, there remains a theoretical concern of inducing sepsis and NEC, particularly since

the optimal type, dose, and duration of probiotic therapy is still uncertain.

Postbiotics are a newer and largely unexplored therapeutic option in NEC prevention. Using the bacterial metabolites derived from probiotic microorganisms is hypothesized to diminish the risk of giving live organisms, while still providing the beneficial effects of probiotics against NEC (34). Several types of metabolites and heat-killed organisms are currently being investigated. Thus far, research has been limited to animal models and their effects in humans are uncertain.

3.4.4. Other Methods of Prevention

There are a variety of other preventative methods that continue to be studied, but in theory would be beneficial. Antenatal glucocorticoids can potentially decrease colonization, reduce bacterial translocation, and stimulate the activity of beneficial enzymes (e.g. - lactase, maltase, sucrase, etc.). These effects overall impact the maturity of premature vasculature and the intestinal barrier. Several randomized control trials have reported a reduction in NEC incidence following administration of antenatal glucocorticoids; however the long-term outcomes must still be investigated (31). Lactoferrin has also been shown to reduce inflammatory injury in small studies using animal models

(35). Other options include erythropoietin (EPO) and epidermal growth factor (EGF), which are components found in human milk and amniotic fluid that could have protective effects against NEC (36). Unfortunately, the effects of EGF have mainly been observed in animal models, and due to its large expense and possible side effects, it is not a viable option for NEC prevention at this time.

3.5. Outcomes

Patient outcomes following NEC are greatly impacted by early recognition of the condition and whether it requires medical or surgical management. Outcomes vary from localized complications in the gastrointestinal system to infant mortality. In 10% - 35% of all NEC cases, intestinal strictures, most commonly near the watershed regions of the large intestine, develop regardless of whether the patient was treated via medical or surgical means. Neurodevelopmental deficits are also very prevalent (37, 38) and should be discussed with parents when reviewing the long-term prognosis of their child. Other conditions associated with morbidity are listed in Box 2. Overall, the majority of literature shows evidence that need for surgery correlates to a greater morbidity and mortality risk (39). Some studies suggest that GA, BW, and clinical course prior to NEC diagnosis are also important factors when considering prognosis and long-term outcomes (40).

Box 2. Patient Outcomes Following NEC

Patient Outcomes
Intestinal strictures
Bowel resection and/or Short Bowel Syndrome
Intestinal failure secondary to short bowel syndrome
Neurodevelopmental deficits
Visual and hearing impairments
Cognitive impairment
Psychomotor impairments
Cerebral palsy
Feeding aversions (dependent on length of NPO status)
Death

4. Conclusions

NEC is a potentially devastating gastrointestinal disease of mainly premature neonates that is caused by multiple factors. Although studies are still investigating the ideal modes for management, more recent research is exploring preventative strategies. Methods targeting enteral

feeding techniques, anti-inflammatory therapies, and alteration of the microbiome via pre- and probiotics appear to be the most promising at this time. More research is still needed to determine the overall risks of these interventions. However, there is emerging literature in animal models and early human trials that may lead to ways of directly inhibiting the pro-inflammatory process or assessing neonates at higher risk for NEC in the future. Continued research and discussion is imperative in the evolving topic of NEC risk assessment and prevention.

Footnote

Financial Disclosure: There are no financial disclosures to report.

References

- Sharma R, Hudak ML. A clinical perspective of necrotizing enterocolitis: past, present, and future. *Clin Perinatol.* 2013;**40**(1):27-51. doi: [10.1016/j.clp.2012.12.012](https://doi.org/10.1016/j.clp.2012.12.012). [PubMed: 23415262].
- Neu J. Necrotizing enterocolitis: the mystery goes on. *Neonatology.* 2014;**106**(4):289-95. doi: [10.1159/000365130](https://doi.org/10.1159/000365130). [PubMed: 25171544].
- Gephart SM, McGrath JM, Effken JA, Halpern MD. Necrotizing enterocolitis risk: state of the science. *Adv Neonatal Care.* 2012;**12**(2):77-87. doi: [10.1097/ANC.0b013e31824cee94](https://doi.org/10.1097/ANC.0b013e31824cee94). [PubMed: 22469959].
- Chen AC, Chung MY, Chang JH, Lin HC. Pathogenesis implication for necrotizing enterocolitis prevention in preterm very-low-birth-weight infants. *J Pediatr Gastroenterol Nutr.* 2014;**58**(1):7-11. doi: [10.1097/MPG.0b013e3182a7dc74](https://doi.org/10.1097/MPG.0b013e3182a7dc74). [PubMed: 24378520].
- Claud EC, Walker WA. Hypothesis: inappropriate colonization of the premature intestine can cause neonatal necrotizing enterocolitis. *FASEB J.* 2001;**15**(8):1398-403. [PubMed: 11387237].
- Claud EC. Neonatal Necrotizing Enterocolitis -Inflammation and Intestinal Immaturity. *Antiinflamm Antiallergy Agents Med Chem.* 2009;**8**(3):248-59. doi: [10.2174/187152309789152020](https://doi.org/10.2174/187152309789152020). [PubMed: 20498729].
- Tanner SM, Berryhill TF, Ellenburg JL, Jilling T, Cleveland DS, Lorenz RG, et al. Pathogenesis of necrotizing enterocolitis: modeling the innate immune response. *Am J Pathol.* 2015;**185**(1):4-16. doi: [10.1016/j.ajpath.2014.08.028](https://doi.org/10.1016/j.ajpath.2014.08.028). [PubMed: 25447054].
- Amin SC, Remon JI, Subbarao GC, Maheshwari A. Association between red cell transfusions and necrotizing enterocolitis. *J Matern Fetal Neonatal Med.* 2012;**25**(Suppl 5):85-9. doi: [10.3109/14767058.2012.715465](https://doi.org/10.3109/14767058.2012.715465). [PubMed: 23025777].
- Gephart SM. Transfusion-associated necrotizing enterocolitis: evidence and uncertainty. *Adv Neonatal Care.* 2012;**12**(4):232-6. doi: [10.1097/ANC.0b013e31825e20ee](https://doi.org/10.1097/ANC.0b013e31825e20ee). [PubMed: 22864004].
- Afrazi A, Sodhi CP, Good M, Jia H, Siggers R, Yazji I, et al. Intracellular heat shock protein-70 negatively regulates TLR4 signaling in the newborn intestinal epithelium. *J Immunol.* 2012;**188**(9):4543-57. doi: [10.4049/jimmunol.1103114](https://doi.org/10.4049/jimmunol.1103114). [PubMed: 22461698].
- Gritz EC, Bhandari V. The human neonatal gut microbiome: a brief review. *Front Pediatr.* 2015;**3**:17. doi: [10.3389/fped.2015.00017](https://doi.org/10.3389/fped.2015.00017). [PubMed: 25798435].
- Clark RH, Gordon P, Walker WM, Laughon M, Smith PB, Spitzer AR. Characteristics of patients who die of necrotizing enterocolitis. *J Perinatol.* 2012;**32**(3):199-204. doi: [10.1038/jp.2011.65](https://doi.org/10.1038/jp.2011.65). [PubMed: 21593813].

13. La Rosa PS, Warner BB, Zhou Y, Weinstock GM, Sodergren E, Hall-Moore CM, et al. Patterned progression of bacterial populations in the premature infant gut. *Proc Natl Acad Sci U S A*. 2014;**111**(34):12522-7. doi: [10.1073/pnas.1409497111](https://doi.org/10.1073/pnas.1409497111). [PubMed: [25114261](https://pubmed.ncbi.nlm.nih.gov/25114261/)].
14. Stone ML, Tatum PM, Weitkamp JH, Mukherjee AB, Attridge J, McGahren ED, et al. Abnormal heart rate characteristics before clinical diagnosis of necrotizing enterocolitis. *J Perinatol*. 2013;**33**(11):847-50. doi: [10.1038/jp.2013.63](https://doi.org/10.1038/jp.2013.63). [PubMed: [23722974](https://pubmed.ncbi.nlm.nih.gov/23722974/)].
15. Epelman M, Daneman A, Navarro OM, Morag I, Moore AM, Kim JH, et al. Necrotizing enterocolitis: review of state-of-the-art imaging findings with pathologic correlation. *Radiographics*. 2007;**27**(2):285-305. doi: [10.1148/rg.272055098](https://doi.org/10.1148/rg.272055098). [PubMed: [17374854](https://pubmed.ncbi.nlm.nih.gov/17374854/)].
16. Bell MJ, Ternberg JL, Feigin RD, Keating JP, Marshall R, Barton L, et al. Neonatal necrotizing enterocolitis. Therapeutic decisions based upon clinical staging. *Ann Surg*. 1978;**187**(1):1-7. [PubMed: [413500](https://pubmed.ncbi.nlm.nih.gov/413500/)].
17. Dimmitt RA, Moss RL. Clinical management of necrotizing enterocolitis. *NeoReviews*. 2001;**2**(5):110-7. doi: [10.1542/neo.2-5-e110](https://doi.org/10.1542/neo.2-5-e110).
18. Autmizguine J, Hornik CP, Benjamin DJ, Laughon MM, Clark RH, Cotten CM, et al. Anaerobic antimicrobial therapy after necrotizing enterocolitis in VLBW infants. *Pediatrics*. 2015;**135**(1):117-25. doi: [10.1542/peds.2014-2141](https://doi.org/10.1542/peds.2014-2141). [PubMed: [25511117](https://pubmed.ncbi.nlm.nih.gov/25511117/)].
19. Zani A, Pierro A. Necrotizing enterocolitis: controversies and challenges. *Fl000Res*. 2015;**4** doi: [10.12688/f1000research.6888.1](https://doi.org/10.12688/f1000research.6888.1). [PubMed: [26918125](https://pubmed.ncbi.nlm.nih.gov/26918125/)].
20. Henderson G, Anthony MY, McGuire W. Formula milk versus maternal breast milk for feeding preterm or low birth weight infants. *Cochrane Database Syst Rev*. 2007(4):2972. doi: [10.1002/14651858.CD002972.pub2](https://doi.org/10.1002/14651858.CD002972.pub2). [PubMed: [17943777](https://pubmed.ncbi.nlm.nih.gov/17943777/)].
21. Boyd CA, Quigley MA, Brocklehurst P. Donor breast milk versus infant formula for preterm infants: systematic review and meta-analysis. *Arch Dis Child Fetal Neonatal Ed*. 2007;**92**(3):F169-75. doi: [10.1136/adc.2005.089490](https://doi.org/10.1136/adc.2005.089490). [PubMed: [16556615](https://pubmed.ncbi.nlm.nih.gov/16556615/)].
22. Sisk PM, Lovelady CA, Dillard RG, Gruber KJ, O'Shea TM. Early human milk feeding is associated with a lower risk of necrotizing enterocolitis in very low birth weight infants. *J Perinatol*. 2007;**27**(7):428-33. doi: [10.1038/sj.jp.7211758](https://doi.org/10.1038/sj.jp.7211758). [PubMed: [17443195](https://pubmed.ncbi.nlm.nih.gov/17443195/)].
23. Berseth CL, Bisquera JA, Paje VU. Prolonging small feeding volumes early in life decreases the incidence of necrotizing enterocolitis in very low birth weight infants. *Pediatrics*. 2003;**111**(3):529-34. [PubMed: [12612232](https://pubmed.ncbi.nlm.nih.gov/12612232/)].
24. Morgan J, Bombell S, McGuire W. Early trophic feeding versus enteral fasting for very preterm or very low birth weight infants. *Cochrane Database Syst Rev*. 2013(3):504. doi: [10.1002/14651858.CD000504.pub4](https://doi.org/10.1002/14651858.CD000504.pub4). [PubMed: [23543508](https://pubmed.ncbi.nlm.nih.gov/23543508/)].
25. Maas C, Mitt S, Full A, Arand J, Bernhard W, Poets CF, et al. A historic cohort study on accelerated advancement of enteral feeding volumes in very premature infants. *Neonatology*. 2013;**103**(1):67-73. doi: [10.1159/000342223](https://doi.org/10.1159/000342223). [PubMed: [23095283](https://pubmed.ncbi.nlm.nih.gov/23095283/)].
26. Morgan J, Young L, McGuire W. Slow advancement of enteral feed volumes to prevent necrotising enterocolitis in very low birth weight infants. *Cochrane Database Syst Rev*. 2011(3):1241. doi: [10.1002/14651858.CD001241.pub3](https://doi.org/10.1002/14651858.CD001241.pub3). [PubMed: [21412870](https://pubmed.ncbi.nlm.nih.gov/21412870/)].
27. Thoene M, Hanson C, Lyden E, Dugick L, Ruybal L, Anderson-Berry A. Comparison of the effect of two human milk fortifiers on clinical outcomes in premature infants. *Nutrients*. 2014;**6**(1):261-75. doi: [10.3390/nu6010261](https://doi.org/10.3390/nu6010261). [PubMed: [24394538](https://pubmed.ncbi.nlm.nih.gov/24394538/)].
28. Knol J, Boehm G, Lidestri M, Negretti F, Jelinek J, Agosti M, et al. Increase of faecal bifidobacteria due to dietary oligosaccharides induces a reduction of clinically relevant pathogen germs in the faeces of formula-fed preterm infants. *Acta Paediatr Suppl*. 2005;**94**(449):31-3. doi: [10.1080/08035320510043529](https://doi.org/10.1080/08035320510043529). [PubMed: [16214763](https://pubmed.ncbi.nlm.nih.gov/16214763/)].
29. Deshpande G, Rao S, Patole S. Probiotics for prevention of necrotizing enterocolitis in preterm neonates with very low birth-weight: a systematic review of randomised controlled trials. *Lancet*. 2007;**369**(9573):1614-20. doi: [10.1016/S0140-6736\(07\)60748-X](https://doi.org/10.1016/S0140-6736(07)60748-X). [PubMed: [17499603](https://pubmed.ncbi.nlm.nih.gov/17499603/)].
30. Hoyos AB. Reduced incidence of necrotizing enterocolitis associated with enteral administration of lactobacillus acidophilus and bifidobacterium infantis to neonates in an intensive care unit. *J Infect Dis*. 1999;**3**(4):197-202. doi: [10.1016/s1201-9712\(99\)90024-3](https://doi.org/10.1016/s1201-9712(99)90024-3).
31. Lin HY, Chang JH, Chung MY, Lin HC. Prevention of necrotizing enterocolitis in preterm very low birth weight infants: is it feasible?. *J Formos Med Assoc*. 2014;**113**(8):490-7. doi: [10.1016/j.jfma.2013.03.010](https://doi.org/10.1016/j.jfma.2013.03.010). [PubMed: [23701837](https://pubmed.ncbi.nlm.nih.gov/23701837/)].
32. Lin HC, Su BH, Chen AC, Lin TW, Tsai CH, Yeh TF, et al. Oral probiotics reduce the incidence and severity of necrotizing enterocolitis in very low birth weight infants. *Pediatrics*. 2005;**115**(1):1-4. doi: [10.1542/peds.2004-1463](https://doi.org/10.1542/peds.2004-1463). [PubMed: [15629973](https://pubmed.ncbi.nlm.nih.gov/15629973/)].
33. Dilli D, Aydin B, Fettah ND, Ozyazici E, Beken S, Zenciroglu A, et al. The pro-pre-save study: effects of probiotics and prebiotics alone or combined on necrotizing enterocolitis in very low birth weight infants. *J Pediatr*. 2015;**166**(3):545-51. doi: [10.1016/j.jpeds.2014.12.004](https://doi.org/10.1016/j.jpeds.2014.12.004). [PubMed: [25596096](https://pubmed.ncbi.nlm.nih.gov/25596096/)].
34. Patel RM, Denning PW. Therapeutic use of prebiotics, probiotics, and postbiotics to prevent necrotizing enterocolitis: what is the current evidence?. *Clin Perinatol*. 2013;**40**(1):11-25. doi: [10.1016/j.clp.2012.12.002](https://doi.org/10.1016/j.clp.2012.12.002). [PubMed: [23415261](https://pubmed.ncbi.nlm.nih.gov/23415261/)].
35. Manzoni P, Meyer M, Stolfi I, Rinaldi M, Cattani S, Pugni L, et al. Bovine lactoferrin supplementation for prevention of necrotizing enterocolitis in very-low-birth-weight neonates: a randomized clinical trial. *Early Hum Dev*. 2014;**90** Suppl 1:60-5. doi: [10.1016/S0378-3782\(14\)70020-9](https://doi.org/10.1016/S0378-3782(14)70020-9). [PubMed: [24709463](https://pubmed.ncbi.nlm.nih.gov/24709463/)].
36. Ledbetter DJ, Juul SE. Erythropoietin and the incidence of necrotizing enterocolitis in infants with very low birth weight. *J Pediatr Surg*. 2000;**35**(2):178-81. [PubMed: [10693662](https://pubmed.ncbi.nlm.nih.gov/10693662/)].
37. Rees CM, Pierro A, Eaton S. Neurodevelopmental outcomes of neonates with medically and surgically treated necrotizing enterocolitis. *Arch Dis Child Fetal Neonatal Ed*. 2007;**92**(3):F193-8. doi: [10.1136/adc.2006.099929](https://doi.org/10.1136/adc.2006.099929). [PubMed: [16984980](https://pubmed.ncbi.nlm.nih.gov/16984980/)].
38. Wadhawan R, Oh W, Hintz SR, Blakely ML, Das A, Bell EF, et al. Neurodevelopmental outcomes of extremely low birth weight infants with spontaneous intestinal perforation or surgical necrotizing enterocolitis. *J Perinatol*. 2014;**34**(1):64-70. doi: [10.1038/jp.2013.128](https://doi.org/10.1038/jp.2013.128). [PubMed: [24135709](https://pubmed.ncbi.nlm.nih.gov/24135709/)].
39. Balanescu RN, Topor L, Dragan GC. Clinical and surgical aspects in necrotizing enterocolitis. *Chirurgia (Bucur)*. 2013;**108**(2):184-8. [PubMed: [23618567](https://pubmed.ncbi.nlm.nih.gov/23618567/)].
40. Duro D, Kalish LA, Johnston P, Jaksic T, McCarthy M, Martin C, et al. Risk factors for intestinal failure in infants with necrotizing enterocolitis: a Glaser Pediatric Research Network study. *J Pediatr*. 2010;**157**(2):203-8. doi: [10.1016/j.jpeds.2010.02.023](https://doi.org/10.1016/j.jpeds.2010.02.023). [PubMed: [20447649](https://pubmed.ncbi.nlm.nih.gov/20447649/)].