

Obstructive Renal Failure Caused by Bilateral Renal Candidiasis and Hypoplastic Renal Pelvises in a Preterm Infant: Case Presentation and Review of the Literature

Farhad Abolhassan Choobdar,¹ Elham Zarei,^{2,*} Mohammad Reza Navaeifar,³ Ali Manafi Anari,⁴ and

Behzad Haghighi Aski⁴

¹Department of Neonatology, Ali Asghar Children Hospital, Iran University of Medical Sciences, Tehran, Iran

²Department of Radiology, Ali Asghar Children Hospital, Iran University of Medical Sciences, Tehran, Iran

³Infectious Diseases Research Center with Focus on Nosocomial Infection, Faculty of Medicine, Mazandaran University of Medical Sciences, Sari, Iran

⁴Department of Pediatric, Division of Pediatric Intensive Care, Faculty of Medicine, Iran University of Medical Sciences, Tehran, Iran

*Corresponding author: Elham Zarei, MD, Assistant Professor, Radiologist, Department of Radiology, Iran University of Medical Sciences, Ali Asghar Children Hospital, Vahid Dastgerdi Street, Shariati Street, Tehran, Iran. Tel: +98-2122222041-4, E-mail: dr.elhamzare@gmail.com

Received 2016 October 07; Revised 2016 December 19; Accepted 2016 December 26.

Abstract

Introduction: *Candida* is one of the common causes of infections in late sepsis of very low birth weight neonates. The outcome ranges from a mild focal disease to a fatal septicemia and multi-organ dysfunction.

Case Presentation: Acute renal failure was found in a seven-week-old preterm infant due to bilateral renal fungal balls and hypoplastic renal pelvises. He had previously been treated with courses of broad-spectrum antibiotics for respiratory distress and sepsis during the first weeks of life. The infant did not respond to standard antifungal therapy and needed surgical removal of fungal balls from his kidneys, open nephrostomy tube placement and pyeloplasty.

Conclusions: Obstructive uropathy by fungal balls is rare and acute renal failure as a result of bilateral obstructive uropathy due to fungal balls requires early detection and prompt treatment to salvage the kidney function.

Keywords: Mycoses, Infant, Premature, Renal Failure, Kidney

1. Introduction

Congenital anomalies of the kidney and urinary tract are a group of diseases with different anatomical malformations that cause kidney and urinary tract anomalies. These conditions are found in 0.5% of all pregnancies (1).

One of the common causes of infections in late sepsis of very low birth weight neonates is Candidal infection (2, 3). Incidence of fungal infections is increasing in neonates (4). The infections can cause a range of diseases from mild focal disease to fatal septicemia and multi organ dysfunction. In the urinary tract, *Candida* may be present within a range, from isolated candiduria to severe disease, with formation of fungous ball and obstructive uropathy. It is important to assess the patient for candidemia when a Candidal urinary tract infection (UTI) is diagnosed in neonates.

2. Case Presentation

A 40-day-old preterm male infant referred to our hospital due to poor weight gain. He was born on the 29th week of gestation, by caesarian section, because of cervix insufficiency and weighed 1200 grams at birth. He had a

history of neonatal intensive care unit (NICU) admission at another center due to respiratory distress and sepsis in the first 4 weeks of life.

The infant weighed 1250 grams and was in a relatively good condition when discharged from the previous hospital. He received cefotaxime and amikacin for about two weeks during his previous admission.

Primary screen laboratory data was negative for sepsis and he was observed for further change while the standard premature feeding continued without any intravenous catheter. His weight gain was appropriate in the next 7 days of admission yet he developed apnea episodes on the 9th day of admission.

Blood and cerebrospinal fluid (CSF) cultures were negative, and CSF analysis and chest radiogram were normal. Remarkable laboratory findings included elevated levels of C-reactive protein, leukocytosis, and candiduria. Serum creatinine also increased from 0.6 to 1.2 mg/dL in the next five days. *Candida albicans* was isolated from urine that was aspirated from the bladder by supra-pubic sampling.

After urine analysis showed candiduria, amphotericin B was administered. On ultrasound, non-shadowing echogenic materials, that filled the pyelocalyceal systems

bilaterally, were observed.

During the next week, patient's renal function deteriorated gradually and serum creatinine elevated to 3.2 mg/dL. On follow-up dilation of calyces on both sides without obvious dilation of renal pelvises and increased renal parenchymal echogenicity were seen in follow up ultrasound (Figure 1). This was a confusing situation and dilation of pelvises in presence of dilated calyces was anticipated. The infant became oliguric at this point.

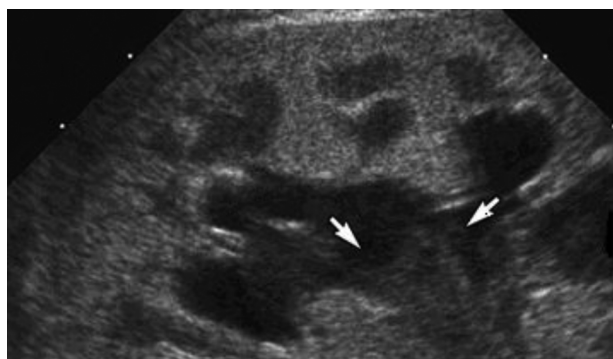


Figure 1. Ultrasound Showed Dilation of Calyces Without Obvious Dilation of Renal Pelvises

No response was noted clinically, ultrasonographically and according to laboratory data after 2 weeks of antifungal (Amphotericin B) treatment, necessitating initiation of an adjunct antifungal agent.

Ultrasound-guided percutaneous nephrostomy insertion failed due to small renal pelvises. Hence, an open surgical approach was employed. Bilateral pyelotomy was done and soft friable masses were found in renal pelvises extending to the calyces.

Pelvises were bilaterally hypoplastic and pyeloplasty was done to correct the bilateral intra-renal hypoplastic pelvises, and nephrostomy tubes were placed for further irrigation and further nephrostography.

It was not possible to find a suitable name for this case's kidney anomaly with normal looking kidneys and hypoplastic pelvises therefore we assumed it as a congenital kidney hypoplasia and named it "hypoplastic renal pelvises".

After the nephrostomy, serum creatinine gradually decreased but the next two urine cultures were positive; therefore flucytosine was added to the previous antifungal regimen.

Although the initial post-operative ultrasound showed echogenic material in the non-dilated pyelocalyceal systems of both kidneys, the creatinine, C-reactive protein, and urine output had all returned to normal ranges.

Bilateral nephrostography showed good drainage with some filling defects in both pelvises and urinary bladder (Figure 2).

Ten days later, nephrostomy catheters were removed and finally, the infant was discharged in good condition and on oral fluconazole. He is currently a 14 months old with normal kidney function tests and his growth and development are acceptable for a preterm born baby.

3. Discussion

3.1. Congenital Anomalies of the Kidney and Urinary Tract

A group of diseases with a different anatomical spectrum cause kidney and urinary tract anomalies. These conditions may be found in 0.5% of all pregnancies (1).

Ureteropelvic junction stenosis or atresia, multi-cystic dysplastic kidneys, hypoplastic kidneys, vesicoureteral reflux, non-obstructed, non-refluxing primary mega-ureter, and bladder outlet obstruction are classic types of common congenital anomalies. In prenatal evaluations, some of these anomalies are reported more in males. By contrast, there is a female predominance in older children (5).

Some of these anomalies require surgical intervention or lead to renal impairment, and further renal replacement therapy or transplant may be needed. Genetic basis of kidney and urinary tract anomalies is widely accepted, yet these genetic aspects have not been fully diagnosed to date (6).

3.2. Urinary Tract Infection with *Candida*

Candida is one of the common causes of infections in late sepsis of very low birth weight neonates (2, 3). *Candida albicans* is the most common Candidal infection at neonatal intensive care units (NICUs) (3) and incidence of fungal infections is increasing in neonates (4). This infection can cause a range of complications from mild focal disease to a fatal septicemia and multi organ dysfunction. In the urinary tract, *Candida* may be present within a range from isolated candiduria to severe disease, with formation of fungous ball and obstructive uropathy. When a Candidal urinary tract infection (UTI) is diagnosed in a neonate, it is important to assess the patient for candidemia. Phillips and Karlowicz found candidemia in 13 of 25 Candidal UTIs in neonates and Bryant *et al.* reported this condition in 12 of 36 cases (7, 8). Renal involvement in neonatal candidemia varies from 5% to 33% (9-11).

3.3. Risk Factors

Premature infants are at risk of fungal infection because of several factors including: increased *Candida* colonization by vertical or horizontal transmission, neona-

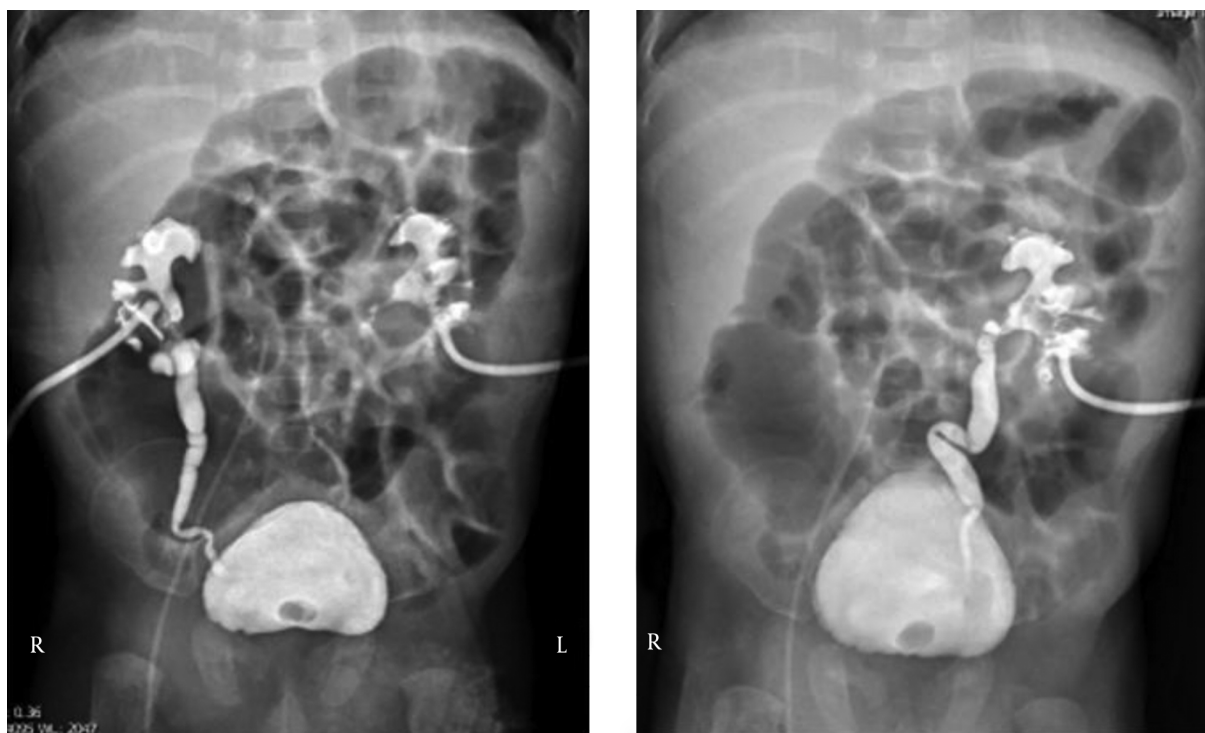


Figure 2. Post-Operative Nephrostography

tal and immaturity immunodeficiency, disruption of natural barrier by catheters or endotracheal tube, use of broad spectrum antibiotics, parenteral nutrition, use of H2-receptor antagonists, corticosteroid, congenital urinary tract abnormalities, indwelling bladder catheter, obstruction, urinary stasis and hyperglycemia (11-16).

3.4. Clinical Manifestations of Candidal UTI

While a bag specimen for urine culture in neonate is not reliable, the growth of more than 103 colony forming units/mL (CFU/ML) in a urine culture gathered by suprapubic aspiration or greater than 10^4 CFU/mL in a catheter collected sample, there is Candidal UTI (7, 16, 17).

Ultrasonography can find renal parenchymal involvement, mycetoma, fungal masses or obstructive effect of fungal mass in the urinary tract. Computed tomography and magnetic resonance imaging may be superior to ultrasonography for detecting the fungus ball, but these easily available imaging instruments are not portable (18). Thus ultrasound may remain the imaging method of choice for evaluating fungal UTI of neonates at the NICU and for follow up after treatment (8).

In addition to nonspecific symptoms and signs that could be found in any neonatal infection, fungal UTI can be

presented by renal failure, anuria, oliguria, hypertension and flank mass (19-23).

3.5. Management

To eradicate the fungal UTI, it is necessary to:

1. Remove any inserted catheter if possible (24).
2. Use systemic antifungal therapy.
3. Resect infected tissue, if systemic therapy is not successful (16).
4. Resect fungous ball, if it causes urinary obstruction.
5. Some authors recommend irrigation of urinary tract when a nephrostomy tube is in place (16, 25).

Amphotericin B deoxycholate at a daily dose of 1 mg/kg/day for 3 weeks is effective on most *Candida* species and is tolerated by neonates (26-28). If localized defect is present and surgical removal could not remove it completely, anti-fungal therapy may have to be continued for 4 to 12 weeks and follow up must be made by blood and urine cultures and suitable imaging (28, 29). Ultrasonography is useful for follow up as a safe and available imaging, yet Berman et al. and Benjamin et al. reported that fungous ball may persist while alive organisms are not present, thus the remaining of non-shadowing renal echogenicities in ultrasound is not solely an indication to continue therapy (11, 30).

Dose interval adjustment must be done in renal failure when serum creatinine is above 1.5 mg/dL or serum creatinine rises more than 0.3 mg/dL per day (31). Another option in renal failure is liposomal amphotericin B, but penetration of lipid form in renal tube is less and its efficacy on Candidal UTI is questionable (32). Although, fluconazole could be added to amphotericin B in case of renal failure or resistant organisms, it should be chosen as initial therapy for susceptible organisms (33-36). When non-albicans *Candida* is probable, fluconazole is not as effective as amphotericin B (37).

As another adjunctive therapy, a nucleoside analogues, flucytosine, can be used in combination with amphotericin B (8). Flucytosine is used in combination with amphotericin B in some neonatal Candidal renal infections, although this combination may have a greater potential of adverse effects especially in decreased renal function (8, 31). Flucytosine is not a drug for monotherapy of neonatal fungal disease.

Echinocandins such as micafungin, caspofungin and anidulafungin are used in fungal infections. Some authors have recommend micafungin and caspofungin instead of amphotericin B in case of resistance, intolerance or toxicity, although these medications need more clinical trials before wide administration (38, 39).

In spite of the fact that systemic antifungal therapy is the standard therapy for fungal UTI, surgical intervention must be used when obstruction or abscess is present or infected tissue is not treated despite appropriate treatment. These interventions may include nephrostomy tube insertion with or without irrigation, removal of fungous ball, resection of affected tissue, drainage of abscess and correction of anatomic problems (16).

Candida albicans is the most common cause of fungal urinary tract infection. Although invasive candidiasis is uncommon in term infants, yet is more frequent in premature cases, and the presence of positive urine culture in this high-risk group should be considered significant (16, 40-42).

Invasive renal candidiasis and fungal balls are uncommon and the most important predisposing factors include low urinary pH, urinary stasis due to poor urine output, congenital renal anomalies and administration of frequent courses of broad-spectrum antibiotics (40, 41).

Obstructive uropathy by fungal balls is rare and acute renal failure as a result of bilateral obstructive uropathy due to fungal balls has been reported (40, 43, 44). This requires early detection and prompt treatment to salvage kidney function (45).

As shown in our case, ultrasound is a useful modality for diagnosis of fungal balls but other interventions such as open surgery may be needed for diagnosis of some con-

genital anomalies (8).

In the presence of positive urine culture for *Candida* and in the absence of hematuria or pyuria, the non-shadowing echogenic material in pyelocalyceal system may be in favor of renal candidiasis (40, 41).

4. Conclusion

Although Candidal UTI is fairly common in the current NICU settings, invasive renal candidiasis and fungal balls are uncommon and the most important predisposing factors include low urinary pH, urinary stasis due to poor urine output, congenital renal anomalies and administration of frequent courses of broad-spectrum antibiotics. Ultrasound is a useful modality for diagnosis of fungal balls and some kidney anomalies. In some cases, surgical intervention may be needed for diagnosis or treatment of some renal congenital anomalies.

Footnotes

Financial Disclosure: None.

Funding/Support: None.

References

1. Scott JE, Renwick M. Antenatal diagnosis of congenital abnormalities in the urinary tract. Results from the Northern Region Fetal Abnormality Survey. *Br J Urol.* 1988;**62**(4):295-300. [PubMed: 3191352].
2. Sobel JD, Fisher JF, Kauffman CA, Newman CA. Candida urinary tract infections-epidemiology. *Clin Infect Dis.* 2011;**52** Suppl 6:S433-6. doi: 10.1093/cid/cir109. [PubMed: 21498836].
3. Fridkin SK, Kaufman D, Edwards JR, Shetty S, Horan T. Changing incidence of Candida bloodstream infections among NICU patients in the United States: 1995-2004. *Pediatrics.* 2006;**117**(5):1680-7. doi: 10.1542/peds.2005-1996. [PubMed: 16651324].
4. Maldonado Y. Pneumocystis and other less common fungal infections. In: Infectious diseases of the fetus and newborn infant. Philadelphia, PA, USA: Elsevier Saunders; 2010. p. 1078.
5. Ring E, Petritsch P, Riccabona M, Haim-Kuttig M, Vilits P, Rauchenwald M, et al. Primary vesicoureteral reflux in infants with a dilated fetal urinary tract. *Eur J Pediatr.* 1993;**152**(6):523-5. [PubMed: 8335023].
6. Pope JCt, Brock JW 3rd, Adams MC, Stephens FD, Ichikawa I. How they begin and how they end: classic and new theories for the development and deterioration of congenital anomalies of the kidney and urinary tract, CAKUT. *J Am Soc Nephrol.* 1999;**10**(9):2018-28. [PubMed: 10477156].
7. Phillips JR, Karlowicz MG. Prevalence of Candida species in hospital-acquired urinary tract infections in a neonatal intensive care unit. *The Pediatric Infectious Disease Journal.* 1997;**16**(2):190-4. doi: 10.1097/00006454-199702000-00005.
8. Bryant K, Maxfield C, Rabalais G. Renal candidiasis in neonates with candiduria. *Pediatr Infect Dis J.* 1999;**18**(11):959-63. [PubMed: 10571429].
9. Faix RG. Invasive neonatal candidiasis: comparison of albicans and parapsilosis infection. *Pediatr Infect Dis J.* 1992;**11**(2):88-93. [PubMed: 1741204].

10. Noyola DE, Fernandez M, Moylett EH, Baker CJ. Ophthalmologic, visceral, and cardiac involvement in neonates with candidemia. *Clin Infect Dis*. 2001;**32**(7):1018–23. doi: [10.1086/319601](#). [PubMed: [11264029](#)].
11. Benjamin DK Jr, Fisher RG, McKinney RE Jr, Benjamin DK. Candidal mycetoma in the neonatal kidney. *Pediatrics*. 1999;**104**(5 Pt 1):1126–9. [PubMed: [10545558](#)].
12. Clerihew L, Lamagni TL, Brocklehurst P, McGuire W. Candida parapsilosis infection in very low birthweight infants. *Arch Dis Child Fetal Neonatal Ed*. 2007;**92**(2):127–9. doi: [10.1136/fnn.2006.097758](#). [PubMed: [17337658](#)].
13. Botas CM, Kurlat I, Young SM, Sola A. Disseminated candidal infections and intravenous hydrocortisone in preterm infants. *Pediatrics*. 1995;**95**(6):883–7. [PubMed: [7761215](#)].
14. Hitchcock RJ, Pallett A, Hall MA, Malone PS. Urinary tract candidiasis in neonates and infants. *Br J Urol*. 1995;**76**(2):252–6. [PubMed: [7663922](#)].
15. Gubbins PO, McConnell SA, Penzak SR. Current management of funguria. *Am J Health Syst Pharm*. 1999;**56**(19):1929–35. [PubMed: [10554910](#)].
16. Karlowicz MG. Candidal renal and urinary tract infection in neonates. *Semin Perinatol*. 2003;**27**(5):393–400. doi: [10.1016/s0146-0005\(03\)00063-6](#).
17. Al-Orifi F, McGillivray D, Tange S, Kramer MS. Urine culture from bag specimens in young children: are the risks too high?. *J Pediatr*. 2000;**137**(2):221–6. doi: [10.1067/mpd.2000.107466](#). [PubMed: [10931415](#)].
18. Erden A, Fitoz S, Karagulle T, Tukul S, Akyar S. Radiological findings in the diagnosis of genitourinary candidiasis. *Pediatr Radiol*. 2000;**30**(12):875–7. doi: [10.1007/s002470000351](#). [PubMed: [11149100](#)].
19. Makhoul IR, Kassis I, Smolkin T, Tamir A, Sujov P. Review of 49 neonates with acquired fungal sepsis: further characterization. *Pediatrics*. 2001;**107**(1):61–6. doi: [10.1542/peds.107.1.61](#). [PubMed: [11134435](#)].
20. McDonnell M, Lam AH, Isaacs D. Nonsurgical management of neonatal obstructive uropathy due to *Candida albicans*. *Clin Infect Dis*. 1995;**21**(5):1349–50. doi: [10.1093/clinids/21.5.1349](#). [PubMed: [8589183](#)].
21. Eckstein CW, Kass EJ. Anuria in a newborn secondary to bilateral ureteropelvic fungus balls. *J Urol*. 1982;**127**(1):109–10. [PubMed: [7057477](#)].
22. Yusuf Khan M. Anuria from candida pyelonephritis and obstructing fungal balls. *Urology*. 1983;**21**(4):421–3. doi: [10.1016/0090-4295\(83\)90171-1](#).
23. Sirinelli D, Biriotti V, Schmit P, Lupold M, Bensman A. Urinoma and arterial hypertension complicating neonatal renal candidiasis. *Pediatr Radiol*. 1987;**17**(2):156–8. [PubMed: [3550669](#)].
24. Harris MC, Pereira GR, Myers MD, Cardin AJ, Razdan B, Pleasure J, et al. Candidal arthritis in infants previously treated for systemic candidiasis during the newborn period: report of three cases. *Pediatr Emerg Care*. 2000;**16**(4):249–51. doi: [10.1097/00006565-200008000-00008](#). [PubMed: [10966343](#)].
25. Baetz-Greenwalt B, Debaz B, Kumar ML. Bladder fungus ball: a reversible cause of neonatal obstructive uropathy. *Pediatrics*. 1988;**81**(6):826–9. [PubMed: [3285313](#)].
26. Baley JE, Meyers C, Kliegman RM, Jacobs ML, Blumer JL. Pharmacokinetics, outcome of treatment, and toxic effects of amphotericin B and 5-fluorocytosine in neonates. *J Pediatr*. 1990;**116**(5):791–7. doi: [10.1016/s0022-3476\(05\)82674-5](#).
27. Butler KM, Rench MA, Baker CJ. Amphotericin B as a single agent in the treatment of systemic candidiasis in neonates. *Pediatr Infect Dis J*. 1990;**9**(1):51–6. doi: [10.1097/00006454-199001000-00012](#). [PubMed: [2300413](#)].
28. Pappas PG, Kauffman CA, Andes D, Benjamin DK Jr, Calandra TF, Edwards JE Jr, et al. Clinical practice guidelines for the management of candidiasis: 2009 update by the infectious diseases society of America. *Clin Infect Dis*. 2009;**48**(5):503–35. doi: [10.1086/596757](#). [PubMed: [19191635](#)].
29. American Academy of Pediatrics. Candidiasis in: 2012 report of the committee on infectious diseases. USA: Elk Grove Village; 2012. p. 265–9.
30. Berman LH, Stringer DA, St Onge O, Daneman A, Whyte H. An assessment of sonography in the diagnosis and management of neonatal renal candidiasis. *Clin Radiol*. 1989;**40**(6):577–81. doi: [10.1016/s0009-9260\(89\)80307-1](#).
31. Butler KM, Baker CJ. Candida: An increasingly important pathogen in the nursery. *Pediatr Clin North Am*. 1988;**35**(3):543–63. doi: [10.1016/s0031-3955\(16\)36471-9](#).
32. Wong-Beringer A, Jacobs RA, Guglielmo BJ. Lipid formulations of amphotericin B: clinical efficacy and toxicities. *Clin Infect Dis*. 1998;**27**(3):603–18. doi: [10.1086/514704](#). [PubMed: [9770163](#)].
33. Robinson LG, Jain L, Kourtis AP. Persistent candidemia in a premature infant treated with fluconazole. *Pediatr Infect Dis J*. 1999;**18**(8):735–7. doi: [10.1097/00006454-199908000-00021](#). [PubMed: [10462351](#)].
34. Weintrub PS, Chapman A, Piecuch R. Renal fungus ball in a premature infant successfully treated with fluconazole. *Pediatr Infect Dis J*. 1994;**13**(12):1152–4. doi: [10.1097/00006454-199412000-00019](#). [PubMed: [7892091](#)].
35. Bibiloni N, Spizzirri F, Zalba J. Successful conservative treatment of severe renal candidiasis with fungus balls. *Pediatr Nephrol*. 2001;**16**(4):394–5. [PubMed: [11354788](#)].
36. Sugar AM, Hitchcock CA, Troke PF, Picard M. Combination therapy of murine invasive candidiasis with fluconazole and amphotericin B. *Antimicrob Agents Chemother*. 1995;**39**(3):598–601. doi: [10.1128/AAC.39.3.598](#). [PubMed: [7793858](#)].
37. Kicklighter SD, Springer SC, Cox T, Hulsey TC, Turner RB. Fluconazole for prophylaxis against candidal rectal colonization in the very low birth weight infant. *Pediatrics*. 2001;**107**(2):293–8. doi: [10.1542/peds.107.2.293](#). [PubMed: [11158461](#)].
38. Mohamed WA, Ismail M. A randomized, double-blind, prospective study of caspofungin vs. amphotericin B for the treatment of invasive candidiasis in newborn infants. *J Trop Pediatr*. 2012;**58**(1):25–30. doi: [10.1093/tropej/fmr025](#). [PubMed: [21355042](#)].
39. Natarajan G, Lulic-Botica M, Rongkavilit C, Pappas A, Bedard M. Experience with caspofungin in the treatment of persistent fungemia in neonates. *J Perinatol*. 2005;**25**(12):770–7. doi: [10.1038/sj.jp.7211380](#). [PubMed: [16222348](#)].
40. Mercado-Deane MG, Beeson JE, John SD. US of renal insufficiency in neonates. *Radiographics*. 2002;**22**(6):1429–38. doi: [10.1148/rg.226025047](#). [PubMed: [12432113](#)].
41. Raghunath BV, Gowrishankar BC, Narendrababu M, Ramesh S. Successful management of a renal fungal ball in a preterm neonate: A case report and review of literature. *J Indian Assoc Pediatr Surg*. 2013;**18**(3):121–3. doi: [10.4103/0971-9261.116047](#). [PubMed: [24019645](#)].
42. Yeo KT, Priyadarshi A, Bolisetty S. Streptokinase therapy in the treatment of neonatal obstructive renal candidiasis. *BMJ Case Rep*. 2013;**2013** doi: [10.1136/bcr-2013-201679](#). [PubMed: [24302664](#)].
43. Hari P, Srivastava A, Gupta AK, Srivastava RN. Neonatal renal failure due to obstructive candidal bezoars. *Pediatr Nephrol*. 1997;**11**(4):497–8. doi: [10.1007/s004670050326](#). [PubMed: [9260255](#)].
44. Shimada S, Nakagawa H, Shintaku I, Saito S, Arai Y. Acute renal failure as a result of bilateral ureteral obstruction by *Candida albicans* fungus balls. *Int J Urol*. 2006;**13**(8):1121–2. doi: [10.1111/j.1442-2042.2006.01509.x](#). [PubMed: [16903942](#)].
45. Bianchi D, Vespasiani G, Bove P. Acute kidney injury due to bilateral ureteral obstruction in children. *World J Nephrol*. 2014;**3**(4):182–92. doi: [10.5527/wjn.v3.i4.182](#). [PubMed: [25374811](#)].