



Scheuermann's Disease: New Impressions of Clinical and Radiological Evaluation and Treatment Approaches; A Narrative Review

Kaveh Haddadi,^{1*} Abhijeet Kadam,² Chadi Tannoury,³ and Tony Tannoury²

¹Department of Neurosurgery, Spine Fellowship Scholar of Boston University Medical Center, Orthopedic Research Center, Mazandaran University of Medical Sciences, Sari, IR Iran

²Department of Orthopedics (Spine Surgery), Boston University Medical Center, Boston, MA-02118, United States of America

³Department of Orthopedics (Spine Surgery), Director of Spine Research, Director of Orthopedic Ambulatory Clinic, Co-Director of Spine Fellowship Program, Boston, MA 02118, United States of America

*Corresponding author: Kaveh Haddadi, Associated of Professor of Neurosurgery, Department of Neurosurgery, Spine Fellowship Scholar of Boston University Medical Center, Orthopedic Research Center, Mazandaran University of Medical Sciences, Sari, IR Iran. Tel: +98-1133377169, E-mail: kh568hd@yahoo.com

Received 2017 April 25; Revised 2017 October 11; Accepted 2017 November 11.

Abstract

Context: Scheuermann's disease (kyphosis) is an essential kyphosis of the thoracic spinal column, and it is the most public source of kyphosis in adolescents. It has been shown that the imaging characteristics of the disease are sequential 3 vertebrae by minimum 5 degrees of wedging of anterior part of vertebral body. Frequently, the disease is presented at 8 to 12 years of age. Kyphosis is regularly managed with conservative methods. The purpose of this review was to discuss challenging issues in evaluation and treatment of this disease in the mentioned age group.

Evidence Acquisition: Medline, Google scholar, PubMed and Ovid were searched and a total of 44 articles were found to be involved in the pediatric evaluation of this disease.

Results: The precise basis of Scheuermann's kyphosis remnants is unidentified. Diagnosis is made by careful clinical examination and radiologic evaluations. In neurologic defects, MRI must be taken. Conservative managing plans for SK involve observation, physical therapy, and bracing. Some writers recommended evading the operation till skeletal maturity is completed. Surgery is commonly suggested for patients with deformity progress, permanent pain, neurological discrepancy, pulmonary insufficiency, or cosmetic complain. Thoracic kyphosis with curving of smaller than 75 degrees seldom requires surgery. Posterior only or combined with anterior methods are the surgery options based on severity of disease.

Conclusions: Today, new and more modern braces have been designed to increase global advantages of bracing in Scheuermann's disease. Patients with more than 75 degrees of curving, kyphotic progress, intolerable cosmetic features, or neurological discrepancy might be supposed for operation. New surgical procedures permit improved correction of the deformity via posterior surgery with lesser complication rates. Concurrent shortening of the posterior spinal column crossways the apical levels, combined by monitoring of spinal cord, decreases the danger of neurological deficits. Though patients state great satisfaction rates through surgery, both proximal and distal junctional complications can remain. New systems with dynamic instrumentation and improving surgical methods with biologic handling are almost convinced to become typical treatment possibilities.

Keywords: Scheuermann's Disease, Spine, Diagnosis, Treatment

1. Context

Scheuermann's disease (kyphosis) primary pronounced in 1920, as an essential kyphosis of the thoracic spinal column, is the most public source of kyphosis in adolescents (1). Dissimilar postural kyphosis and kyphosis in Scheuermann is inflexible and is not revised through extension (2, 3). Scheuermann's Kyphosis (SK) is a kind of osteochondrosis that is a domestic of orthopedic disorders, including Perthes disease of the pelvic area (4, 5). There seems to be an initial phenomenon overlap with normal spinal growth or it might be secondary to an un-

balanced axial load on the kyphotic thoracic sections of an undeveloped spinal column (3). It has been shown that the imaging characteristics of the disease include sequential three vertebrae by minimum five degrees of wedging of the anterior part of vertebral body. Other authors have informed that only one wedged vertebra by more than 45 degrees of thoracic kyphosis, indiscretions of vertebral end plate, and reduction of disk space are needed for diagnosis (6-8). Furthermore, SK is an infrequent illness and is regularly managed with conservative methods. Frequently, the disease is presented at 8 to 12 years of age,

nonetheless, extra severe types are apparent at about 12 to 16 years of age (9). Even though some patients have pain, they frequently refer with their main concern being the cosmetic abnormality (10, 11). In a large assessment of lateral radiographs, 4% of patients encountered the diagnostic standards for SK (12). In supplementary studies, the incidence ranged from 0.4% to 10% (3, 6, 12). There is inconsistent information regarding whether the SK is more public in males or females (4, 6, 8, 13, 14).

Regardless of variable ideas on the natural history of Scheuermann's kyphosis, there seems to be a subclass of adolescents, who progress to refractory pain and a subset of them, who have progressive curves, finally develop painful deformities in maturity that influences management decisions earlier in life. The psychosocial consequences of the deformity must also be considered. Cardiopulmonary and neurologic risks are remarkably challenging; when encountered, they need to be addressed on a specific basis. Therefore, early diagnosis and management of this disease may be critical for further evaluation and follow up of the patients (10, 11, 13).

In contrast to various physical illnesses like trauma, spine diseases, behavioral disorder and hydrocephalous (15-18), the prevalence of SK is infrequent, yet there are no specific recommendations about the best treatment option for this condition in adolescent patients. Therefore, the current study was designed with the purpose of review of the literature on the occurrence and challenging issues in evaluation and treatment of this disease in the mentioned age group.

2. Evidence Acquisition

Primarily Medline, Scopus, Embase via Google scholar, PubMed and Ovid were searched using the following keywords: pediatric, adolescent, Scheuermann's disease, kyphosis, spine, thoracic, spinal cord, thoracolumbar, treatment, surgery, and spinal fusion. The criteria involved articles from journals on epidemiology, anatomy, classification, management and outcome of Scheuermann's disease in pediatric patients (age < 18 years). Exclusion criteria were: 1) articles available in any language other than English, 2) patients older than 18 years at the time of study, and 3) articles published before 2000. Significant training and publications in this field was very low. Overall, 66 article from 1970 to 2016 were studied. A total of 44 articles were involved in the pediatric evaluation. This review only included studies published after 2000 for SK epidemiology, classification, and management

3. Results

3.1. Etiology

The precise basis of Scheuermann's kyphosis remains unidentified. Numerous philosophies have been proposed, including counting avascular necrosis, osteochondrosis (1, 3, 9), apophyseal ring ossification (13), and cartilaginous end plate flagging (2, 19, 20). Pathologic examinations revealed irregular growth of vertebral cartilage and plates, through unbalanced chondrocytes and bone growing in involved zones, without bone necrosis (19). Schmorl's nodes are frequently noticeable, involving representative herniation of the disk amongst anomalous end plates into the vertebral bone (19), however, are not essential for judgement. A number of twin studies have suggested a hereditary factor to Scheuermann's kyphosis (21-24) and propose that genetics is involved in the development of the disease (21). However, the exact genes continue to be unidentified.

3.2. Histopathological Studies

Studies of collagen existing in the vertebral end plates of children with Scheuermann's disease have revealed a change in endochondral ossification comparable to that detected in Blount's disease. An initial phenomenon overlaps with normal spinal growth or might be secondary to an unbalanced axial load on the kyphotic thoracic sections of an undeveloped spinal column (3).

3.3. Evaluation

3.3.1. Clinical Evaluation

This basically involves history and physical examination. The examination must concentrate on the occurrence of neurological discrepancies, particularly deficits in the lower limbs, even though these discoveries are infrequent. Some studies have reported that only about 9% of pre-operative neurological deficits have a final good prognosis after surgery (25). Physical examinations should likewise comprise of check of standup posture and that the kyphosis is improved by extension throughout upright standing. Contractures of Hamstring muscles exist in about 41% of patients with SK, pre-operatively, and the surgeon might profit from measuring muscle tendency and tone (25, 26).

3.3.2. Imaging Evaluation

Radiographs in all neutral and dynamic directions help in the valuation of flexibility of the deformity. A 36-inch standing AP and lateral imaging would be performed to measure the grade of deformity. Hyperextension images of above a bolster on the apex of the kyphosis are essential for evaluating the degree of curve flexibility (27, 28). Computerized Tomography scan is useful in

bony structures diagnosis and measurement of spine angles and pedicle dimensions before surgery (29, 30). Some studies showed the severity of thoracic kyphosis is not essentially associated with neurological utility (31). The occurrence of any neurologic discrepancy must be examined by Magnetic Resonance Imaging (MRI) of the entire spine (Figure 1) (9). Variable diagnostic principles are present for SK (9, 20, 32). The best established standard is the radiographic explanation of 3 sequential levels through at least five degrees of kyphotic wedging in separate vertebrae (27). Scheuermann's kyphosis through participation of the thoracolumbar junction or of the lumbar spinal column has likewise been pronounced (23, 28, 33). The mixture of wedging of anterior body of five degrees or more of at least three sequential vertebrae, Schmorl's nodes, and end plate abnormalities have been categorized for thoracolumbar Scheuermann's disease (11, 33). The combination of one or two vertebral wedging, Schmorl's nodes, and disk space tapering was distinct as unusual thoracolumbar SK. All of these lower spine kyphosis have been presented by back pain (100%) (11, 20, 33).

3.4. Differential Diagnosis

Round back postural kyphosis, is not an illness state, however, there is a flexible thoracic kyphosis produced by stooping, or bad posture. Postural kyphosis is revised by upright standing, and no need for surgical treatment. Pre-Scheuermann's disease is a projected midway condition, in which thoracic kyphosis is noticeable, however, the typical radiologic results of wedging of anterior body or Schmorl's nodes are absent (3, 4).

Other differential diagnosis of SK are situations, such as congenital kyphosis, ankylosing spondylitis, spondylodiscitis, sequelae from previous fractures, post-laminectomy kyphosis, and tumors (11, 33).

3.5. Treatment

3.5.1. Nonsurgical Management

Conservative managing plans for SK involve observation, physical therapy, and bracing. Some writers have recommended evading operations until skeletal maturity is complete (28). Overall, adolescents by Scheuermann's kyphosis must evade actions that include boring, and continuous strain forces on the spine. In unimportant cases, repeated observation might be sufficient (28, 29).

3.5.2. Physiotherapy

Teenagers with undeveloped skeletons and a minor rise in regular kyphosis, maximum of up to 60 degrees and without sign of deterioration of the deformity, only

need steady clinical and radiological observation till skeletal maturity (3, 5). Physical therapy training is able to aid throughout the early growth phases of flexion contracture in hip and augmented lumbar lordosis related to thoracic kyphosis (3). This exercise can occasionally crop an obvious upgrading in the symptoms, however, it will not be effective on the degree of the deformity (34-36).

Physical therapy must be administered for all patients with symptoms, regardless of the management being non-surgical or surgical. Rigorous rehabilitation plans are a therapy for pain relief and enhancement of musculoskeletal task and upgrade of specialized respiratory capability in patients by restrictive lung disorders due to kyphosis is required (5, 34). Communal rehabilitation methods and maneuvers target to recover postural switch, reinforce the trunk, and stretch muscles and tendons (35, 36).

3.5.3. Bracing

In conditions, where close observation and physical therapy are not sufficient in stopping the enduring development of kyphosis or while pain is not satisfactorily controlled, brace usage is a further treatment option. Rigid bracing is the main tool of non-surgical management for mild to moderate types of SK (37). The general aims of bracing are to avoid additional wedging of anterior vertebral body and precise deformity. The indications for brace are headstrong pain, cosmetic complain, and kyphosis of thoracic region by curvature of 45 to 65 degrees (37, 38). Some writers have recommended that severe kyphosis (curving above 70 degrees) is able to be treated by bracing if management is applied before skeletal maturity (39, 40). Of the numerous accessible braces, the Milwaukee brace seems be the best. Reliable studies have shown that Milwaukee brace leads to improvement of kyphosis in 69% of those, who wore a brace in the long-term, while in 22% worsening was indicated, and in 9%, there was no change (5). In this brace, one anterior bar and two posterior bars are devoted to a sacrum and lengthen superiorly to attribute to a cervical ring (39). Another is the Boston brace, usually recognized as Thoraco-Lumbosacral Orthosis (TLSO). This brace is positioned around the patient's trunk, however, does not have a cervical ring. The Boston orthosis cannot be appropriate for upper points of thoracic kyphosis (37, 40). Below, new designs of more modern braces have been listed to increase global advantages of bracing in SK (38, 40, 41).

3.5.3.1. Newly Anti-Kyphosis

This orthosis is really a posture guide support, built on biofeedback opinion. The shoulder bands of the orthosis comprise of vibrating components, which are devoted to the central part with cables. The extension of the shoulders jerk the cable and active the vibration unit (Figure 2).

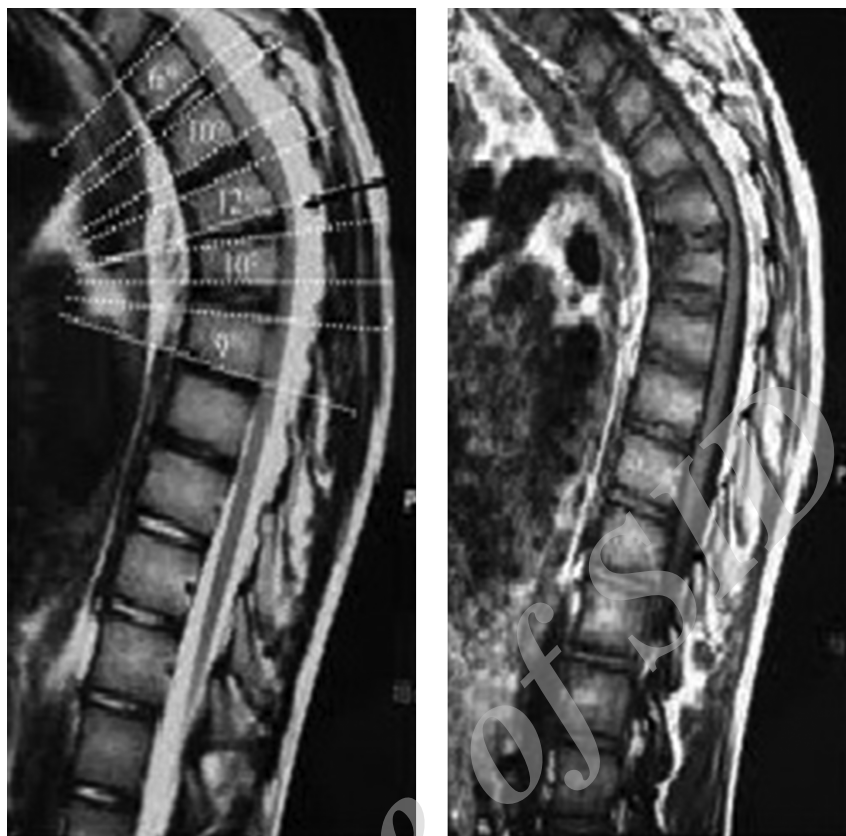


Figure 1. Sagittal magnetic resonance imaging of a 14-year-old female with typical Scheuermann's disease

3.5.3.2. Gschwend Orthosis

This brace has also been used for kyphosis. A long-lasting correction of kyphosis has been described by means of this brace. In contrast with Milwaukee brace, this brace remains the treatment of choice.

3.5.3.3. Osteomed Orthotic Device

This brace is used specially for osteoporosis. It looks like contact orthosis, with no rigid structure. There are some air hollow pads close to the back segment of the device, which can be filled up to 75% of their volume.

3.5.3.4. Sforzesco Brace

This was established in order to ignore the casting process used for spinal orthoses. The correction attained following the use of this brace is based on Sport perception of correction. The other orthoses, such as Sibilla and Lapadula, were established on a similar idea.

3.5.3.5. Physio-Logic Brace

This orthosis aims to reinstate lumbar lordosis through an apex at L2 (38, 40, 41).

3.5.3.6. Best Manner of Bracing

There are abundant references on the rate and period of management through a brace. It has been suggested that supports are used 16 to 23 hours a day depending on the particular brace, the rigidity of the spine, and the degree of kyphosis (41-44). In general, once an orthosis is used for improvement of kyphosis, the brace must be used till the spine is within the range of maturity or for minimum for 18 months. Afterward, the patient is able to be slowly "deterred" off the brace, ending in an additional 18 months (44, 45). In unusual circumstances of inflexible kyphosis, a plastered brace container is used for 2 or 3 months. The prognosticators of promising answers to bracing comprise of flexible deformity, kyphosis by curving of fewer than 65 degrees, and skeletal childishness (34, 40, 46).

3.5.4. Surgical Approach

Surgery is commonly suggested for patients by deformity progress, permanent pain, neurological discrepancy, pulmonary insufficiency, or for cosmetic complain



Figure 2. Standard anti-kyphosis TLSO brace used for treatment of SK

(5). Flexible malformations are usually managed by Ponte osteotomies and fixation from a single posterior approach, while for plain, immobile deformities, release from the anterior might be obligatory before the posterior step (5, 10, 47). Like other deformity operations, intra-operative nerve monitoring is suggested to attentive the surgeon while any spine handlings reason fluctuations in motor evoked potentials or somatosensory evoked potentials. Posterior kyphosis surgery contains shortening of the posterior column. Extreme stretch of the spinal cord or nerve roots might be a clue for alterations in these potentials, and the surgeon is able to reflect discharging some of the corrections since this occurs (10, 48).

3.5.4.1. Posterior Approach

Fixation of pedicular screw with Ponte osteotomies for release of posterior elements wont be the center of contemporary treatment (28). By a mixture of compression on the kyphotic parts and in sequence above multi-segmental Ponte osteotomies, great grades of deformity correction can be attained (28). The Ponte osteotomies permit for kyphosis improvement from only the posterior method (28, 29). This type of osteotomy includes subtraction of the spinous process, inferior facets, inferior lamina, and a slice of the superior facets of the lower level. Caution must be taken to eliminate any osseous barbs and original ligament of flavum that can buckle into the spinal cord once the deformity is adjusted (25, 46, 47, 49). Most physicians

today custom pedicle screws at many levels. The amount of instrumented points is found on the local spinal stability, however, they must extent from minimum the superior sagittal Cobb level proximal to the first lordotic disk in distal region (49-52). Over-correction rises the risk of junctional kyphosis distal or proximal to end of hardware (6); however, adjusting to fewer than 50% of the initial kyphosis is believed to diminish the danger of junctional kyphosis (50, 52).

New systems with dynamic instrumentation and improving surgical methods with biologic handling are almost convinced to become typical treatment possibilities (53).

3.5.4.2. Anterior Combined Posterior Approach

The usage of anterior methods for SK improvement begun in the 1970s. Bradford et al. joined anterior and posterior fusions for enhanced preservation of correction and pain release (48). Detailed principles assumed immobile kyphosis by curving larger than 80 degrees or proven pseud arthrosis (28, 53). Some writers have supported a combined anterior and posterior approach for a rigid curvature that does not improve to fewer than 50 degrees through extension (52, 53). The anterior release is conventionally done via an ordinary open thoracotomy. The disk is recognized and removed, and the anterior longitudinal ligament, divided though the anterior visceral constructions, is endangered. Bone grafts, such as rib auto-graft,

are crammed into the disc spaces (54). The apex kyphosis is usually released, and this issue is able to be achieved in excess of 3 to 5 sections. Thoracoscopy allows the surgeon to attain an anterior relief in a minimally invasive method. After careful anesthetic groundwork with ventilation through one lung, the thoracoscopic process is done (53, 55). Three ports are located for entree: one for the camera and two for any thoracoscopic tools desirable for the entire process (55).

3.6. Outcome

3.6.1. Nonsurgical Conservative Measures

Scheuermann's disease is often treated non-surgically. Concentrated rehabilitation has shown at least 16% decrease in pain and also delivers mild profits in avoiding advance deformity (28, 29). Bracing is the real management for SK, nonetheless, the distress is that its consequences might not be long-lasting deprived of continuing bracing. After about two or three years of bracing, the Milwaukee brace was capable of decreasing kyphosis by 35% to 50% (30, 39, 49). There is data that even at 1.5 years of observation, nearly all patients, who experience bracing take substantial damage of previous correction (56). In addition, patients frequently encounter inessential physical and public problems though experiencing use of bracing. Patients report problems in standing up and sleeping (35, 56). Some of them have major anxiety disturbances in relations through their aristocracies (56). There is a proposition that patients, who experience lengthy times of bracing, are at increased danger of emerging back pain (41). Watchful thought and sympathy concerning these subjects must be assumed throughout the period of bracing (35, 57).

3.6.2. Surgery

The operative management of SK is actual, and substantial kyphosis correction can be attained by instrumentation and fusion. Use of only Posterior methods have been shown to give 27 to 46 degrees of deformity correction (28, 48). The usefulness of an additional anterior approach for the rigid spine for correction of remnants, is an option in the surgical management of SK, nonetheless, posterior-only methods are usually used (50, 51).

The anterior approach basically places patients at danger for pneumothorax, pleural effusion, hemothorax, and catastrophic great vessels injury (52, 53). However, video-assisted thoracoscopic surgery for anterior spinal release decreased the overall thoracoscopic complications (50-52). The most communal peri-operative operating hitches related to the surgical procedure include neurological discrepancies like paraplegia, wound infections, and respiratory problems, particularly in cases with thoracotomy

process (28, 54, 55), in longstanding complications, pseudarthrosis by recurring deformity, hardware failure, and proximal and distal junctional kyphosis are the most common (42, 53, 57, 58). Surgical reconsideration is obligatory in about 17% of patients (28, 59). The long standing medical consequences after the operation for the correction of Scheuermann's disease are medium, however hopeful. In one study, at average of 75 months of observation, 18% of patients stated deteriorating back pain, 36% did not inform any change in pain, and 45% described relief of pain (12). In patients, who experienced operating correction of SK, 45% stated enhanced self-image, 41% described no change, and 14% described deteriorated self-image (42, 54). However, patients, who experienced surgery showed high general satisfaction rates, up to 96% (Figures 3, 4) (52, 58, 59).

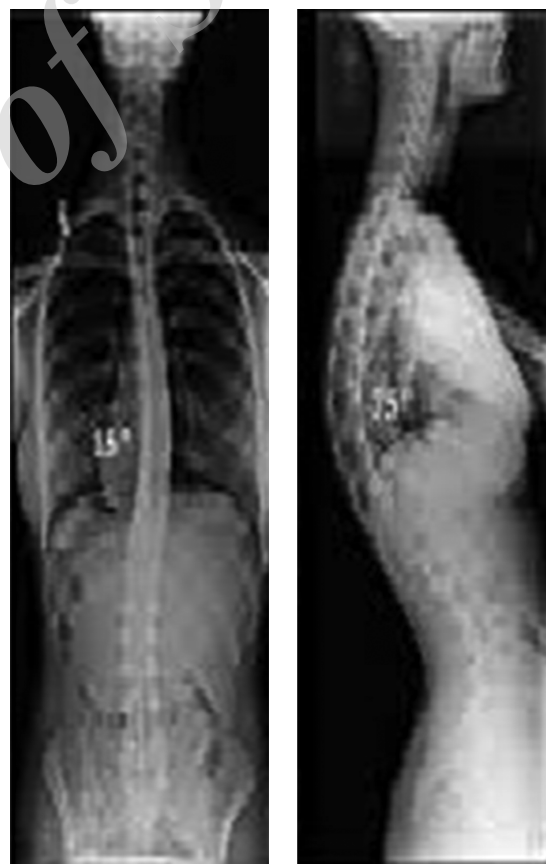


Figure 3. X-ray of a 15-year-old male with SK and Thoracic kyphosis up to 75 degrees, needing surgery

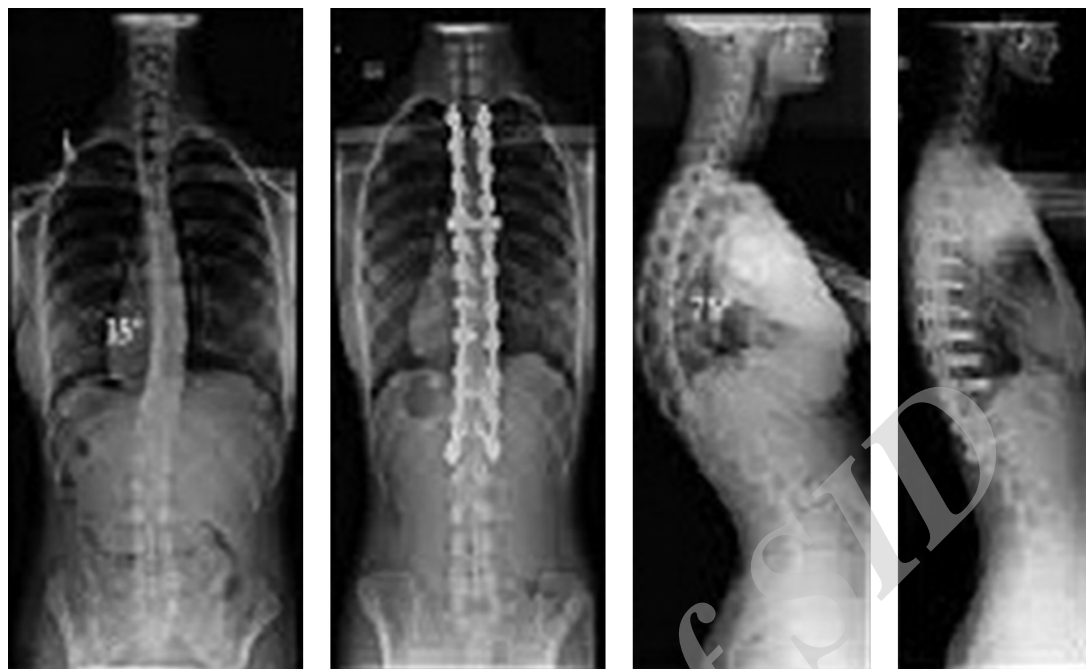

Figure 4. Comparative pre and post operation X-ray of the same patient with significant kyphosis correction

4. Conclusion

Today, new and more modern braces have been designed to increase global advantages of bracing in Scheuermann's disease. Patients with more than 75 degrees of curving, kyphotic progress, intolerable cosmetic features, or neurological discrepancy might be supposed for operation. New surgical procedures permit improved correction of the deformity via posterior surgery with lesser complication rates. Concurrent shortening of the posterior spinal column crossways the apical levels, and combined by monitoring of spinal cord, decreases the danger of neurological deficits.

Though patients state great pleasure rates through surgery, both proximal and distal junctional complications can remain to outbreak in patients in the long-term.

New systems with dynamic instrumentation and improvement in surgical methods with biologic handling are almost convinced to become typical treatment possibilities.

References

1. Scheuermann HW. Kyfosis dorsalis juvenilis. *Ugeskr Laeger*. 1920;**82**:385-93.
2. Summers BN, Singh JP, Manns RA. The radiological reporting of Scheuermann's disease: an unnecessary source of confusion amongst clinicians and patients. *Br J Radiol*. 2008;**81**.
3. Tsirikos AI. Scheuermann's kyphosis: an update. *J Surg Orthop Adv*. 2009;**18**:122-8.
4. Wood KB, Melikian R, Villamil F. Adult Scheuermann kyphosis: evaluation, management, and new developments. *J Am Acad Orthop Surg*. 2012;**20**:113-21.
5. Papagelopoulos PJ, Mavrogenis AF, Savvidou OD, Mitsiokapa EA, Themistocleous G, Soucacos P. Current concepts in Scheuermann's kyphosis. *Orthopedic*. 2008;**31**:52-8.
6. Bradford DS. Vertebral osteochondrosis (Scheuermann's kyphosis). *Clin Orthop Relat Res*. 1981;(158):83-90. [PubMed: 7273530].
7. Sorensen RH, Cheu SH. Accidental Cutaneous Coccidioidal Infection in an Immune Person. A Case of an Exogenous Reinfection. *Calif Med*. 1964;**100**:44-7. [PubMed: 14104142].
8. Berven S, Talu U, Lowe TG. *Scheuermann kyphosis*. In: Mummaneni PV, Lenke LG, Haid RW, eds. *Spinal Deformity: A Guide to Surgical Planning and Management*. St. Louis: Quality Medical Publishing; 2008. p. 495-509.
9. Shah SA, Shafa E. *Scheuermann kyphosis*. In: Heary RF, Albert TJ, eds. *Spinal Deformities: The Essentials*. 2nd ed. New York: Thieme; 2014. p. 163-74.
10. Lowe TG. Scheuermann's kyphosis. *Neurosurg Clin N Am*. 2007;**18**(2):305-15. doi: 10.1016/j.nec.2007.02.011. [PubMed: 17556132].
11. Lonner BS, Newton P, Betz R, Scharf C, O'Brien M, Sponseller P. Operative management of Scheuermann's kyphosis in 78 patients: radiographic outcomes, complications and technique. *Spine*. 2007;**32**:2644-52.
12. Makurthou AA, Oei L, El Saddy S, Breda SJ, Castano-Betancourt MC, Hofman A, et al. Scheuermann disease: evaluation of radiological criteria and population prevalence. *Spine (Phila Pa 1976)*. 2013;**38**(19):1690-4. doi: 10.1097/BRS.0b013e31829ee8b7. [PubMed: 24509552].
13. Poolman RW, Been HD, Ubags LH. Clinical outcome and radiographic results after operative treatment of Scheuermann's disease. *Eur Spine J*. 2002;**11**(6):561-9. doi: 10.1007/s00586-002-0418-6. [PubMed: 12522714].

14. Montgomery SP, Erwin WE. Scheuermann's kyphosis long-term results of Milwaukee braces treatment. *Spine*. 1981;**6**:5-8.
15. Haddadi K, Yousefzadeh F. Epidemiology of Traumatic Spinal Injury in North of Iran: A Cross-sectional Study. *IrfNS*. 2015;**1**(4):11-4. Persian.
16. Haddadi K. Pediatric Lumbar Disc Herniation: A Review of Manifestations, Diagnosis and Management. *J Pediatr Rev*. 2016;**4**(1):e4725. Persian.
17. Haddadi K. Outlines and Outcomes of Instrumented Posterior Fusion in the Pediatric Cervical Spine: A Review Article. *J Pediatr Rev*. 2016;**4**(1):e4765. Persian.
18. Haddadi K. Pediatric Endoscopic Third Ventriculostomy: A Narrative Review of Current Indications, Techniques and Complications. *J Pediatr Rev*. 2016;**4**(2):e5074. Persian.
19. Ippolito E, Ponseti IV. Juvenile kyphosis: histological and histochemical studies. *J Bone Joint Surg Am*. 1981;**63**(2):175-82. [PubMed: 7462274].
20. Lowe TG, Line BG. Evidence based medicine: analysis of Scheuermann kyphosis. *Spine (Phila Pa 1976)*. 2007;**32**(19 Suppl):S115-9. doi: 10.1097/BRS.0b013e3181354501. [PubMed: 17728677].
21. Damborg F, Engell V, Andersen M, Kyvik KO, Thomsen K. Prevalence, concordance, and heritability of Scheuermann kyphosis based on a study of twins. *J Bone Joint Surg Am*. 2006;**88**(10):2133-6. doi: 10.2106/JBJS.E.01302. [PubMed: 17015588].
22. Graat HC, van Rhijn LW, Schrande-Stumpel CT, van Ooij A. Classical Scheuermann disease in male monozygotic twins: further support for the genetic etiology hypothesis. *Spine (Phila Pa 1976)*. 2002;**27**(22):E485-7. doi: 10.1097/01.BRS.0000031070.91294.E1. [PubMed: 12436008].
23. Gustavel M, Beals RK. Scheuermann's disease of the lumbar spine in identical twins. *AJR Am J Roentgenol*. 2002;**179**(4):1078-9. doi: 10.2214/ajr.179.4.1791078. [PubMed: 12239077].
24. van Linthoudt D, Revel M. Similar radiologic lesions of localized Scheuermann's disease of the lumbar spine in twin sisters. *Spine (Phila Pa 1976)*. 1994;**19**(8):987-9. [PubMed: 8009360].
25. Cho W, Lenke LG, Bridwell KH, Hu G, Buchowski JM, Dorward IG, et al. The prevalence of abnormal preoperative neurological examination in Scheuermann kyphosis: correlation with X-ray, magnetic resonance imaging, and surgical outcome. *Spine (Phila Pa 1976)*. 2014;**39**(21):1771-6. doi: 10.1097/BRS.0000000000000519. [PubMed: 25029218].
26. Speck GR, Chopin DC. The surgical treatment of Scheuermann's kyphosis. *J Bone Joint Surg Br*. 1986;**68**(2):189-93. [PubMed: 3958000].
27. Summers BN, Singh JP, Manns RA. The radiological reporting of lumbar Scheuermann's disease: an unnecessary source of confusion amongst clinicians and patients. *Br J Radiol*. 2008;**81**(965):383-5. doi: 10.1259/bjr/69495299. [PubMed: 18440942].
28. Ponte A. Posterior column shortening for Scheuermann's kyphosis: an innovative one-stage technique. In: *Hafer TR, Merola AA, eds. Surgical Techniques for the Spine*. New York: Thieme; 2003. p. 107-9.
29. Ghasemi A, Haddadi K, Khoshakhlagh M, Ganjeh HR. The Relation Between Sacral Angle and Vertical Angle of Sacral Curvature and Lumbar Disc Degeneration: A Case-Control Study. *Medicine (Baltimore)*. 2016;**95**(6). e2746. doi: 10.1097/MD.0000000000002746. [PubMed: 26871821].
30. Iotfinia I, Haddadi K, Sayyahmelli S. Computed tomographic evaluation of pedicle dimension and lumbar spinal canal. *Neurosurg Quarterl*. 2010;**20**(3):194-8. Persian.
31. Palazzo C, Sailhan F, Revel M. Scheuermann's disease: an update. *Joint Bone Spine*. 2014;**81**(3):209-14. doi: 10.1016/j.jbspin.2013.11.012. [PubMed: 24468666].
32. Ghasemi A, Haddadi K, Shad AA. Comparison of Diagnostic Accuracy of MRI with and Without Contrast in Diagnosis of Traumatic Spinal Cord Injuries. *Medicine (Baltimore)*. 2015;**94**(43). e1942. doi: 10.1097/MD.0000000000001942. [PubMed: 26512624].
33. Jansen RC, van Rhijn LW, van Ooij A. Predictable correction of the unfused lumbar lordosis after thoracic correction and fusion in Scheuermann kyphosis. *Spine*. 2006;**31**:1227-31.
34. Soo CL, Noble PC, Esses SI. Scheuermann kyphosis: long-term follow-up. *Spine J*. 2002;**2**:49-56.
35. Weiss HR, Dieckmann J, Gerner HJ. Effect of intensive rehabilitation on pain in patients with Scheuermann's disease. *Stud Health Technol Inform*. 2002:254-7.
36. Platero D, Luna JD, Pedraza V. Juvenile kyphosis: effects of different variables on conservative treatment outcome. *Acta Orthop Belg*. 1997;**63**:194-201.
37. Pizzutillo PD. Nonsurgical treatment of kyphosis. *Intercours Lect*. 2004;**53**:485-91.
38. Weiss HR, Turnbull D, Bohr S. Brace treatment for patients with Scheuermann's disease - a review of the literature and first experiences with a new brace design. *Scoliosis*. 2009;**4**:22. doi: 10.1186/1748-7161-4-22. [PubMed: 19788753].
39. de Mauroy J, Weiss H, Aulisa A, Aulisa L, Brox J, Durmala J, et al. 7th SOSORT consensus paper: conservative treatment of idiopathic Scheuermann's kyphosis. *Scoliosis*. 2010;**5**:9. doi: 10.1186/1748-7161-5-9. [PubMed: 20509962].
40. Lowe TG, Kasten MD. An analysis of sagittal curves and balance after Cotrel-Dubousset instrumentation for kyphosis secondary to Scheuermann's disease. A review of 32 patients. *Spine (Phila Pa 1976)*. 1994;**19**(15):1680-5. [PubMed: 7973960].
41. Karimi MT. Effect of Brace on Kyphosis Curve Management: A Review of Literature. *Health Rehabil*. 2016;**1**(1):1-4. Persian.
42. Korovessis P, Zacharatos S, Koureas G, Megas P. Comparative multifactorial analysis of the effects of idiopathic adolescent scoliosis and Scheuermann kyphosis on the self-perceived health status of adolescents treated with brace. *Eur Spine J*. 2007;**16**(4):537-46. doi: 10.1007/s00586-006-0214-9. [PubMed: 16953447].
43. Zaina F, Atanasio S, Ferraro C, Fusco C, Negrini A, Romano M, et al. Review of rehabilitation and orthopedic conservative approach to sagittal plane diseases during growth: hyperkyphosis, junctional kyphosis, and Scheuermann disease. *Eur J Phys Rehabil Med*. 2009;**45**(4):595-603. [PubMed: 20032919].
44. Tsirikos AI, Jain AK. Scheuermann's kyphosis; current controversies. *J Bone Joint Surg Br*. 2011;**93**(7):857-64. doi: 10.1302/0301-620X.93B7.26129. [PubMed: 21705553].
45. Riddle EC, Bowen JR, Shah SA, Moran EF, Lawall HJ. The duPont kyphosis brace for the treatment of adolescent Scheuermann kyphosis. *J South Orthop Assoc*. 2003;**12**(3):135-40. [PubMed: 14577720].
46. Weiss HR. Ein neuer Zuschnitt in der Korsettversorgung der thorakalen Kyphose. A new model in bracing of the thoracic kyphosis. *MOT*. 2005;**125**:65-71.
47. Geck MJ, Macagno A, Ponte A, Shufflebarger HL. The Ponte procedure: posterior only treatment of Scheuermann's kyphosis using segmental posterior shortening and pedicle screw instrumentation. *J Spinal Disord Tech*. 2007;**20**(8):586-93. doi: 10.1097/BSD.0b013e31803d3b16. [PubMed: 18046172].
48. Bradford DS, Moe JH, Montalvo FJ, Winter RB. Scheuermann's kyphosis. Results of surgical treatment by posterior spine arthrodesis in twenty-two patients. *J Bone Joint Surg Am*. 1975;**57**(4):439-48. [PubMed: 1141252].
49. Coe JD, Smith JS, Berven S, Arlet V, Donaldson W, Hanson D. Complications of spinal fusion for Scheuermann kyphosis: a report of the scoliosis research society morbidity and mortality committee. *Spine*. 2010;**35**:99-103.
50. Lonner BS, Newton P, Betz R, Scharf C, O'Brien M, Sponseller P, et al. Operative management of Scheuermann's kyphosis in 78 patients: radiographic outcomes, complications, and technique. *Spine (Phila Pa 1976)*. 2007;**32**(24):2644-52. doi: 10.1097/BRS.0b013e31815a5238. [PubMed: 18007239].
51. Pompeo E. Minimalistic thoracoscopic anterior spinal release in Scheuermann kyphosis. *J Thorac Cardiovasc Surg*. 2013;**146**(2):490-1. doi: 10.1016/j.jtcvs.2013.04.009. [PubMed: 23692993].
52. Johnston CE, Elerson E, Dagher G. Correction of adolescent hyper-

- kyphosis with posterior-only threaded rod compression instrumentation: is anterior spinal fusion still necessary? *Spine*. 2005;**30**:12.
53. Tome-Bermejo F, Tsirikos AI. Current concepts on Scheuermann kyphosis: clinical presentation, diagnosis and controversies around treatment. *Rev Esp Cir Ortop Traumatol*. 2012;**56**(6):491-505. doi: [10.1016/j.recot.2012.07.002](https://doi.org/10.1016/j.recot.2012.07.002). [PubMed: [23594948](https://pubmed.ncbi.nlm.nih.gov/23594948/)].
 54. Arlet V, Schlenzka D. Scheuermann's kyphosis: surgical management. *Eur Spine J*. 2005;**14**(9):817-27. doi: [10.1007/s00586-004-0750-0](https://doi.org/10.1007/s00586-004-0750-0). [PubMed: [15830215](https://pubmed.ncbi.nlm.nih.gov/15830215/)].
 55. Herrera-Soto JA, Parikh SN, Al-Sayyad MJ, Crawford AH. Experience with combined video-assisted thoracoscopic surgery (VATS) anterior spinal release and posterior spinal fusion in Scheuermann's kyphosis. *Spine (Phila Pa 1976)*. 2005;**30**(19):2176-81. [PubMed: [16205343](https://pubmed.ncbi.nlm.nih.gov/16205343/)].
 56. Lee SS, Lenke L. G , Kuklo TR. Comparison of Scheuermann kyphosis correction by posterior-only thoracic pedicle screw fixation versus combined anterior/posterior fusion. *Spine*. 2006;**31**:2316-21.
 57. Weiss HR, Dieckmann J, Gerner HJ. Outcome of in-patient rehabilitation in patients with M. Scheuermann evaluated by surface topography. *Stud Health Technol Inform*. 2002;**88**:246-9. [PubMed: [15456043](https://pubmed.ncbi.nlm.nih.gov/15456043/)].
 58. Koller H, Juliane Z, Umstaetter M, Meier O, Schmidt R, Hitzl W. Surgical treatment of Scheuermann's kyphosis using a combined antero-posterior strategy and pedicle screw constructs: efficacy, radiographic and clinical outcomes in 111 cases. *Eur Spine J*. 2014;**23**(1):180-91. doi: [10.1007/s00586-013-2894-2](https://doi.org/10.1007/s00586-013-2894-2). [PubMed: [23893052](https://pubmed.ncbi.nlm.nih.gov/23893052/)].
 59. Sturm PF, Dobson JC, Armstrong GW. The surgical management of Scheuermann's disease. *Spine (Phila Pa 1976)*. 1993;**18**(6):685-91. [PubMed: [8516695](https://pubmed.ncbi.nlm.nih.gov/8516695/)].

Archive of SID