

Accepted Manuscript

Netherton Syndrome: A Case Report & literature review

Running title: Netherton Syndrome

**Fereshteh Salari¹, Leila Bani Adam¹, Saba Arshi¹, Mohammad Hassan Bemanian¹,
Morteza Fallahpour¹, Mohammad Nabavi^{1*}**

¹Department of Allergy and Clinical Immunology, Hazrat Rasoul Hospital, Iran University of Medical Science, Tehran, Iran

***Corresponding author:** Mohammad Nabavi, MD, Allergist and Clinical Immunologist

Postal Address: Hazrat Rasoul Hospital, Niayesh Street, Tehran

Tel & fax: 00982164352383

Email: mnabavi44@yahoo.com

ORCID IDs of all Authors (If any):

Dr. Fereshteh Salari: ORCID: 0000-0002-2158-6560

Dr. Leila Bani Adam: ORCID: 0000-0003-2803-9428

Dr. Saba Arshi: ORCID: 0000-0002-7277-3243

Dr. Mohammad Hassan Bemanian: ORCID: 0000-0003-0998-4651

Dr. Morteza Fallahpour: ORCID: 0000-0002-5148-8312

Dr. Mohammad Nabavi: ORCID: 0000-0001-6558-0390

To appear in: Journal of Pediatrics Review

Received: 2018/11/13

Revised: 2019/02/6

Accepted date: 2019/02/13

This is a “Just Accepted” manuscript, which has been examined by the peer review process and has been accepted for publication. A “Just Accepted” manuscript is published online shortly after its acceptance, which is prior to technical editing and formatting and author proofing. Journal of Pediatrics Review provides “Just Accepted” as an optional and free service which allows authors to make their results available to the research community as soon as possible after acceptance. After a manuscript has been technically edited and formatted, it will be removed from the “Just Accepted” web site and published as a published article. Please note that technical editing may introduce minor changes to the manuscript text and/or graphics which may affect the content, and all legal disclaimers that apply to the journal pertain.

Please cite this article as:

Fereshteh Salari¹, Leila Bani Adam¹, Saba Arshi¹, Mohammad Hassan Bemanian¹, Morteza Fallahpour ¹, Mohammad Nabavi^{1*}. Netherton Syndrome: A Case Report & literature review. J. Pediatr. Rev. Forthcoming 2020 Oct 31.

Abstract

Introduction: Netherton Syndrome (NS) is a rare hereditary autosomal recessive disorder with ichthyosiform cutaneous lesions, specific hair shaft defect and atopic diathesis. The incidence of Netherton syndrome is estimated to be approximately 1 in 200,000. The objective of this case report is to illustrate the Netherton Syndrome in a patient with severe eczema atopic dermatitis-like eruption.

Case presentation: A 41-month old boy referred to the clinic of Allergy and Immunology, Hazrat Rasoul Hospital with generalized erythema and scaling cutaneous lesions. The patient underwent clinical examinations and laboratory analysis. Laboratory data revealed only an elevated IgE level, leukocyte count was 7800/ μ l with 10% eosinophil, and his hair shaft indicated classic trichorrhexis invaginata (Bamboo hair). Based on the clinical and laboratory findings, N.S was diagnosed. A brief review was also done related to this case.

Conclusion: The case was reported because of the severity of the disorder and other differential diagnoses in severe and refractory atopic dermatitis-like eruptions. The importance of the case is related to other differential diagnoses, especially with early onset disorders at neonatal age.

Keywords: Netherton syndrome, congenital ichthyosis, trichorrhexis invaginata

Introduction

Netherton Syndrome (NS) is a scarce autosomal recessive disorder characterized by congenital ichthyosiform erythroderma, an atopic diathesis, and hair-shaft abnormality known as trichorrhexis invaginata (1). The incidence of Netherton syndrome is estimated to be approximately 1 in 200,000 (2). It is also the cause of up to 18% of congenital erythrodermas (3). This syndrome is associated with a type of mutation in the SPINK5 gene which codes a serine protease inhibitor named as LEKTI (Lymphoepithelial Kazal Type-related Inhibitor) (1). Triad of trichorrhexis invaginata, Ichthyosis linearis circumflexa (ILC), and an atopic diathesis usually are seen (4). Trichorrhexis invaginata is a necessary finding in the diagnosis of Netherton syndrome (5, 6).

Atopic diathesis can include eczema-like eruptions, atopic dermatitis, asthma, pruritus, allergic rhinitis, angioedema, urticaria, elevated serum IgE, and/or hypereosinophilia (4). Many treatments have been attempted in patients, including topical corticosteroids, low-dose oral corticosteroids, tretinoin, topical emollients and psoralen ultraviolet A therapy (1). The objective of this case report is to illustrate the Netherton Syndrome in a patient with severe eczema atopic dermatitis-like eruption. In addition, a short review was done related to this case.

Case Presentation

A 41-month old boy referred to the clinic of Allergy and Immunology with generalized erythema since the first day of his life.

Dermatological examination revealed thinning and sparseness of the hair and eyebrow with excessive scalp scaling, erythema, and patchy scaling in the perioral area and face and generalized ichthyosiform xerosis (Fig.1). In the extremities, especially in the antecubital (Fig.2a) and popliteal area (Fig.2b), there were diffuse polycyclic erythematous patches surrounded by a double edged

scales characteristic of ILC. Erythema and desquamation were also dominant in other parts of the body, including back and posterior auricular area.

He was born after a normal pregnancy course without any perinatal complications. Immediately post-partum generalized erythema appeared with associated ichthyosis. After a few months, erythematous rash changed and transformed into desquamated patches and plaques during infancy. He had recurrent skin infections and worsening of his cutaneous lesions with some contact allergens as well as food allergens. Signs and symptoms of gastroesophageal reflux and allergic rhinosinusitis without any evidence of asthma appeared soon in his life. The patient is mentally normal with normal development and growth. He was in the 50th percentile for weight and height. There was a history of parental consanguinity and his mother had atopic dermatitis.

Laboratory data revealed only an elevated IgE level (1280 IU/ml) and the other immunologic tests didn't show significant results. There was a leukocyte count of 7800/ μ l with 10% eosinophil. Skin prick test showed sensitization against some foods, including nuts, milk, wheat and tomato.

Light microscopy of his hair shaft indicated classic trichorrhexis invaginata (Bamboo hair) (Fig.3a) and pili torti (Fig.3b). Diagnosis of Netherton Syndrome was based on clinical as well as histological findings, including ILC and trichorrhexis invaginata. Cutaneous lesions are under relatively controlled state using topical medications such as moisturizers, topical corticosteroid ointments, and keratolytic agents.

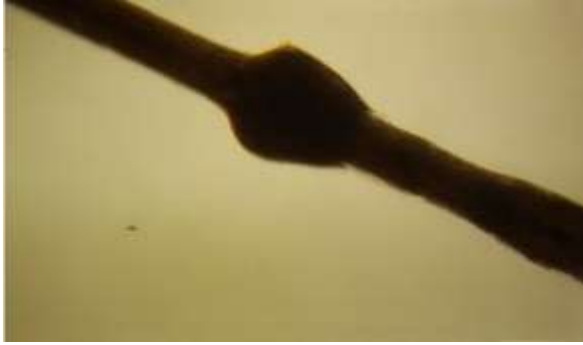

Fig.1-Thinning and sparseness of the hair and eyebrows

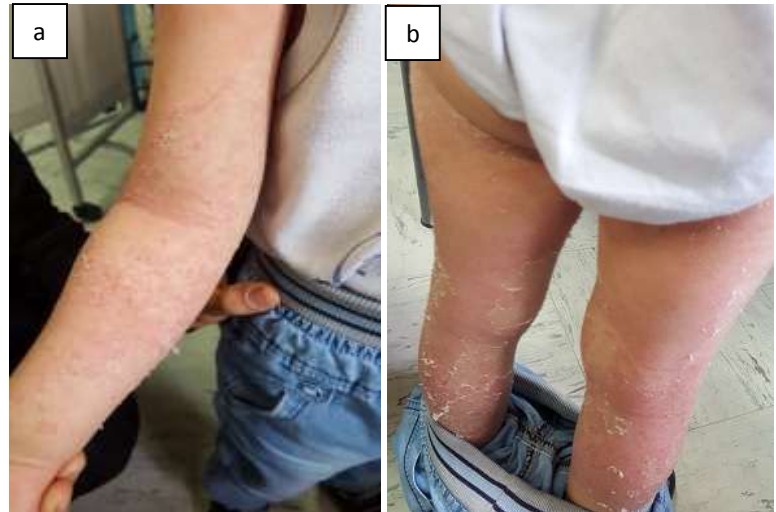

Fig.2- Ichthyosis linearis circumflexa (ILC) on antecubital (2a) and popliteal area (2b)

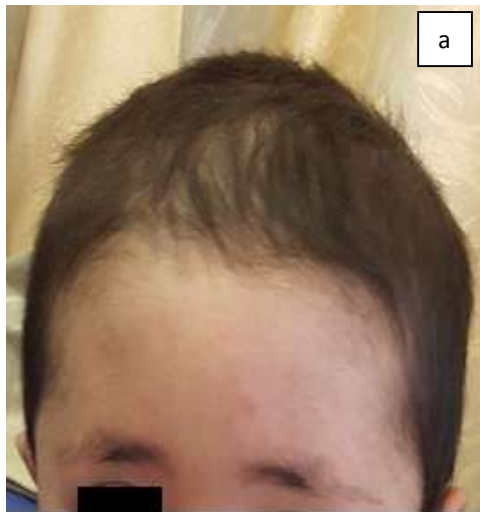


Fig.3a- trichorrhexis invaginata (Bamboo hair) and **3b-**Pili torti

Discussion and review of the literature

Netherton Syndrome is a rare autosomal recessive disorder characterized by triad of congenital ichthyosiform erythroderma with a typical form referred to as Ichthyosis Linearis Circumflexa (ILC); hair shaft defect diagnosed with either trichorrhexis invaginata or bamboo hair; and atopic diathesis (4, 5). In 1937, Touraine and Solente first noted the association between hair-shaft defects (bamboo node) and ichthyosiform erythroderma. Còmel first claimed the term ichthyosis linearis circumflexa in 1949 and finally in 1958, Netherton reported a young girl with generalized scaly dermatitis and fragile nodular hair-shaft deformities, named as trichorrhexis nodosa (7). The frequency of trichorrhexis invaginata is unknown. Nearly, 200 cases have been reported worldwide (7). The Netherton syndrome (Mendelian Inheritance in Man [MIM] #256500) is an autosomal recessive disease as a result of mutations of both copies of the SPINK5 gene (localized to band 5q31-32) (8). Each SPINK5 mutation results in a LEKTI protein with different length, resulting in genotype/phenotype associations in cutaneous severity and vulnerability to atopic dermatitis (9). Clinically, Netherton syndrome is recognized by the triad of trichorrhexis invaginata (“bamboo hair” or “ball and socket” hair shaft deformity), congenital ichthyosiform erythroderma/ichthyosis linearis circumflexa, and an atopic diathesis. Atopic manifestations include atopic dermatitis, asthma, allergic rhinitis, urticaria, angioedema, anaphylactic reactions to food, blood hypereosinophilia, and elevated serum IgE. Recurrent infections, especially bacterial infections of the skin, are common and occur in at least 30% of affected patients (10) such as this case. At 2013 Boskabadi et al was reported a 63-day-old boy with diagnosis of Nethertone syndrome with severe failure to thrive and diarrhea and generalized erythroderma and scaling that shown children with ichthyosiform dermatosis, diarrhea and growth failure may have an underlying disease such as NS (11). In the current case, although the child had erythroderma and desquamation

immediately after birth, the diagnosis of Netherton was missed because we found no family history of the syndrome and the hair was not influenced in the early infancy period and the fact that hair may also be sparse in the healthy infants in the early infancy and also ILC commonly doesn't occur before the age of 2 and it may be misdiagnosed as allergic diseases such as atopic dermatitis or other skin disorders. As well, the nature and severity of the skin lesions are variable between and within patients, rendering the diagnosis difficult.

Typically, the diagnosis is delayed until the appearance of trichorrhexis invaginata which is pathognomonic. Therefore, hair examination should be carried out early so that the diagnosis would not have been missed or delayed diagnosis in atypical cases can be confirmed, if necessary, by identification of a germline *SPINK5* mutation by DNA sequencing. However, in our case because of the high cost of performing his parents refused for genetic testing, but with typical clinical triad it wasn't necessary for diagnosis. A similar case of Netherton syndrome was reported by Saleem et al at 2018 in a two-year-old boy with intractable skin manifestations, multiple food allergies, initially treated as atopic dermatitis too (12).

Currently, there is no known cure or satisfactory treatment for Netherton syndrome. Treatment modalities such as topical corticosteroids, topical calcineurin inhibitors, topical retinoids, narrowband ultraviolet B phototherapy, psoralen and ultraviolet irradiation, and oral acitretin have been used with varying success as we did. Intravenous immunoglobulin and anti-TNF- α are therapeutic options for severe illness (13, 14). Our reported case demonstrated in consistent with other similar cases, the importance of attention to other differential diagnoses in severe and refractory eruptions, especially with early onset disorders at neonatal age. Table 1 is indicated a summary of data derived from the literature review.

Author	Year	Gender and age	clinical findings
Sun et al	2006	2-year-old girl	generalized erythema, pruritus, and scaling skin, shaft abnormalities (trichorrhexis invaginata), and an atopic diathesis
Boskabadi et al.	2013	63-day-old boy	hair shaft anomaly, active colitis compatible with dermatopathic enteropathy, triad of congenital erythroderma, bamboo-like growths in the hair shaft and failure to thrive due to prolonged diarrhea
Roda et al.	2017	19-year-old female	erythematous plaques with a double-edged scale, Hair shaft abnormalities (trichorrhexis invaginata), elevation of IgE.
Saleem et al.	2018	two-year-old boy	triad of congenital ichthyosiform erythroderma (CIE) or ichthyosis linearis circumflexa (ILC), hair shaft abnormalities, and atopic diathesis (elevated serum IgE)
Leung et al.	2018	8-year-old boy	severe atopic dermatitis, migratory serpiginous pruritic scaly patches and sparse hair, double-edged peripheral scaling typical of ichthyosis linearis circumflexa, trichorrhexis invaginata (bamboo hair)

Acknowledgments

The authors would like to express their sincere appreciation to the patient and his parents.

Conflict of interest

The authors declare no financial conflict of interest to in this study.

References

1. Sun JD, Linden KG. Netherton syndrome: a case report and review of the literature. *Int J Dermatol.* 2006;45(6):693-7.
2. Selma E, Metin A, Demirseren DD, Yorulmaz A, Onursever A, Kaftan B. Two siblings with Netherton syndrome. *Turk J Med Sci.* 40(5):819-23.
3. Bitoun E, Chavanas S, Irvine AD, Lonie L, Bodemer C, Paradisi M, et al. Netherton syndrome: disease expression and spectrum of SPINK5 mutations in 21 families. *J Invest Dermatol.* 2002;118(2):352-61.
4. Greene SL, Muller SA. Netherton's syndrome: report of a case and review of the literature. *J Am Acad Dermatol.* 1985;13(2):329-37.
5. Altman J, Stroud J. Netherton's syndrome and ichthyosis linearis circumflexa. *Arch Dermatol.* 1969;100(5):550-8.
6. Dawber R. Clinical aspects of hair disorders. *Dermatol Clin.* 1996;14:753-72.
7. McGevna LF. Trichorrhexis Invaginata (Netherton Syndrome or Bamboo Hair). <https://emedicinemedscape.com>. 2017.
8. Wang S, Olt S, Schoefmann N, Stuetz A, Winiski A, Wolff-Winiski B. SPINK5 knockdown in organotypic human skin culture as a model system for Netherton syndrome: effect of genetic inhibition of serine proteases kallikrein 5 and kallikrein 7. *Exp Dermatol.* 2014;23(7):524-6.
9. Namkung JH, Lee JE, Kim E, Byun JY, Kim S, Shin ES, et al. Hint for association of single nucleotide polymorphisms and haplotype in SPINK5 gene with atopic dermatitis in Koreans. *Exp Dermatol.* 2010;19(12):1048-53.
10. Leung AK, Barankin B, Leong K. An 8-Year-Old Child with Delayed Diagnosis of Netherton Syndrome. *Case Rep Pediatr.* 2018;2018 :9434916.
11. Boskabadi H, Maamouri G, Mafinejad S. Netherton syndrome, a case report and review of literature. *Iran J Pediatr.* 2013;23(5):611-2.
12. Saleem HMK, Shahid MF, Shahbaz A, Sohail A, Shahid MA, Sachmechi I. Netherton Syndrome: A Case Report and Review of Literature. *Cureus.* 2018;10(7).
13. Small AM, Cordoro KM. Netherton syndrome mimicking pustular psoriasis: clinical implications and response to intravenous immunoglobulin. *Pediatr Dermatol.* 2016;33(3):e222-e3.
14. Roda Â, Mendonça-Sanches M, Travassos AR, Soares-de-Almeida L, Metze D. Infliximab therapy for Netherton syndrome: A case report. *JAAD case reports.* 2017;3(6):550-2.