

## Leiomyosarcoma with Unusual Macroscopic Features: A Case Report

Sima Kadkhodayan (MD)<sup>1</sup>, Zohreh Yousefi (MD)<sup>2</sup>, Malihe Hasanzadeh (MD)<sup>1\*</sup>, Noorieh Sharifi Sistani (MD)<sup>3</sup>, Fatemeh Homaei (MD)<sup>4</sup>

<sup>1</sup> Associate Professor, Department of Obstetrics and Gynecology, Ghaem Hospital, School of Medicine, Mashhad University of Medical Sciences, Mashhad, Iran

<sup>2</sup> Professor, Department of Obstetrics and Gynecology, Ghaem Hospital, School of Medicine, Mashhad University of Medical Sciences, Mashhad, Iran

<sup>3</sup> Professor, Department of Pathology, Ghaem Hospital, School of Medicine, Mashhad University of Medical Sciences, Mashhad, Iran

<sup>4</sup> Associate Professor, Department of Radiation Oncology, Ghaem Hospital, School of Medicine, Mashhad University of Medical Sciences, Mashhad, Iran

ARTICLE INFO	ABSTRACT
<i>Article type:</i> Case report	Uterine sarcoma is a rare tumor of mesodermal origin, accounting for 2-6% of uterine malignancies. Leiomyosarcoma (LMS) has been reported in only 1% of all uterine malignancies and is regarded as the most common primary uterine sarcoma. Herein, we present a case of LMS with unusual macroscopic features. The patient was a 61-years-old woman with LMS, which consisted of a large cystic mass (88×136 mm), containing six liters of brownish fluid on the right side of the pelvis and abdomen. The fundus of the uterus was ruptured by the solid part of the tumor. For treatment, total hysterectomy, salpingo-oophorectomy and the optimal resection of tumor were carried out. Overall, the distinctive biological behavior and poor overall survival of uterine sarcoma challenge the post-operative management of this tumor. According to the one-year follow-up, the patient was disease-free. Unfortunately, no further data is available beyond this period.
<i>Article History:</i> Received: 7-Jan-2015 Accepted: 20-Apr-2015	
<i>Key words:</i> Cystic Change Leiomyosarcoma Pelvic Neoplasm Lipid	

► Please cite this paper as:  
Kadkhodayan S, Yousefi Z, Hasanzadeh M, Sharifi Sistani N, Homaei F. Leiomyosarcoma with Unusual Macroscopic Features: A Case Report. Journal of Midwifery and Reproductive Health. 2015; 3(3):433-436.

### Introduction

Uterine sarcoma is regarded as the most malignant uterine tumor (1, 2). The three most common histologic variants include endometrial stromal sarcoma, leiomyosarcoma (LMS) and carcinosarcoma (malignant mixed müllerian tumor) (3). However, LMS is the most common variant and is more common in younger individuals (43-53 years) (4).

The incidence of sarcomatous change in benign uterine leiomyoma is reported to range between 0.13% and 0.8% (4). A mitotic index of > 10 is indicative of severe cytologic atypia, coagulation and tumor necrosis. Also, the prognosis is poor when the tumor is disseminated out of the uterus (5). The tumor normally spreads to the myometrium, pelvic blood, lymphatic vessels, contiguous pelvic structures, the abdomen and distantly most often to the lungs (5).

### Case report

A 61-year-old nulliparous woman with a large pelvic mass was referred to Ghaem Hospital, affiliated to Mashhad University of Medical Sciences. She had experienced a dull pain in the lower abdomen over the last two months. On abdominal examination, a large mass was indicated in the middle and right side of the abdomen. It was a fixed, solid, cystic mass with no ascites; the borders were not manually palpable.

According to vaginal examinations, the mass had occupied the whole pelvis, extending to the upper abdomen; also, the uterus was undistinguishable. Ultrasonography showed a heterogeneous mass (118×132×103 mm) on the fundus, suggesting uterine leiomyoma with solid (79×75 mm) and cystic components (88×136 mm).

The computed tomography (CT) scan revealed a large heterogeneous mass (230×120×140 mm), containing solid and cystic components in the pelvis and the abdomen. The

\* Corresponding author: Malihe Hasanzadeh, Department of Obstetrics and Gynecology, Ghaem Hospital, School of Medicine, Mashhad University of Medical Sciences, Mashhad, Iran. Email: HasanzadeMofradM@mums.ac.ir

mass probably originated from the uterine or the ovaries, with no lymphadenopathy or ascites (Figure 1). The tumor marker results were as follows: cancer antigen 125 (CA-125) = 56.9, carcinoembryonic antigen (CEA) = 2.1 and serum lactate dehydrogenase (LDH) = 670.

Intra-operatively, a large, lobulated, solid, cystic mass was detected, which occupied the pelvis and the abdomen and extended to the upper umbilicus with adhesions to the abdominal wall, fascia, bowel and peritoneum. The cystic component had a very thin wall and was extending to the upper abdomen on the right side.

The thin wall of the cystic component was ruptured and six liters of brownish fluid was evacuated. The fundus of the uterus was completely ruptured by the necrotic tumor (Figure 2). The ovaries and fallopian tubes were apparently normal and instant pathologic report

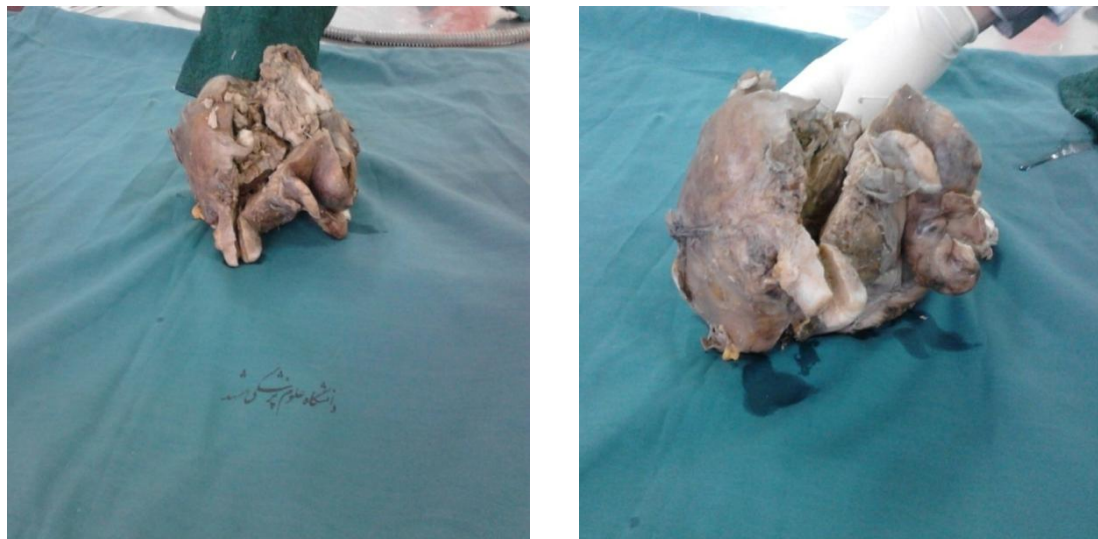indicated LMS.

For treatment, total hysterectomy, salpingo-oophorectomy and the optimal resection of tumoral parts were carried out. Pathologic response indicated high-grade LMS of the uterus, which extended to all layers of the uterine wall and consisted of smooth muscle bundles with extensive necrosis.

LMS is composed of malignant uterine smooth muscle cells. It also involves the omentum, bowel and peritoneum. The cells are elongated with tapered ends. At a microscopic level, LMS may histologically resemble normal uterine musculature. The less differentiated the sarcoma is, the less it resembles a leiomyoma. As the cellularity increases, nuclear atypia increases, cytoplasm becomes more eosinophilic and the number of giant cells rises.




Figure 1. CT scan showed a large heterogeneous mass in the pelvis and the abdomen



**Figure 2.** The macroscopic appearance of the tumor indicated a multilocular cystic tumor with solid components

On the first and eighth days, chemotherapy with gemcitabine (900 mg/m<sup>2</sup>) was performed. Chemotherapy continued with docetaxel (100 mg/m<sup>2</sup>) on the eighth day and every 21 days after the operation for six cycles. According to the one-year follow-up, the patient was disease-free. Unfortunately, no further information is at hand beyond this period.

### Discussion

LMS is a rare uterine neoplasm with a poor prognosis (6). The usual appearance of LMS is a soft, fleshy, ill-defined mass with hemorrhage and necrosis in the macroscopic tumor section (6). In the present case, LMS was predominantly a large cystic mass. It should be mentioned that the symptoms including vaginal bleeding, pelvic pain/pressure and abdomino-pelvic mass do not normally last long (mean duration = 6 months) (7).

The present case had experienced dull pain over the last two months, without any other symptoms. According to sonography and CT scan, the origin of the mass was not exactly determined, although the uterine or the ovaries (or both) were suspected.

Although ultrasonography is the most common imaging modality in gynecology, different new modalities have been introduced for improving the preoperative diagnosis of pelvic masses, especially pelvic sarcoma. Generally, CT scan, magnetic resonance imaging

(MRI), 2-Deoxy-2-[18F] fluoro-D-glucose positron emission tomography (PET) and fluorodeoxyglucose PET are the most important modalities (8-10).

LMS tends to involve cystic changes and be more heterogeneous than most leiomyomas (11). However, in this case report, an unusually large cyst was found. In fact, LMS could be included in the differential diagnosis of large pelvic cystic tumors. Considering this unusual appearance, the present case was reported.

Elevated serum LDH has been suggested as a marker of LMS, although it has not been independently confirmed (12); in the present case, serum LDH titer was high (670 U/L). The distinctive biological behavior and poor overall survival of uterine sarcoma challenge the post-operative management of this tumor. However, chemotherapy regimen has been suggested to be useful (13, 14). In this patient, gemcitabine, along with docetaxel, was prescribed for chemotherapy. Several studies have confirmed that radiotherapy does not increase the quality of life and survival in LMS patients (15, 16).

### Conflict of interest

The authors declare no conflict of interest.

### References

1. D'Angelo E, Prat J. Uterine sarcomas: a review. *Gynecologic Oncology*. 2010; 116(1):131-139.
2. Di Luigi G, D'Alfonso A, Patacchiola F, Di Stefano

- L, Palermo P, Carta G. Leiomyosarcoma: a rare malignant transformation of a uterine leiomyoma. *European Journal of Gynaecological Oncology*. 2015; 36(1):84-87.
3. Kaur K, Kaur P, Kaur A, Singla A. Uterine leiomyosarcoma: A case report. *Journal of Mid-life Health*. 2014; 5(4):202-204.
  4. Dinh TA, Oliva EA, Fuller AF Jr, Lee H, Goodman A. The treatment of uterine leiomyosarcoma. Results from a 10-year experience (1990-1999) at the Massachusetts General Hospital. *Gynecologic Oncology*. 2004; 92(2):648-652.
  5. Bell SW, Kempson RL, Hendrickson MR. Problematic uterine smooth muscle neoplasms. A clinicopathologic study of 213 cases. *The American Journal of Surgical Pathology*. 1994; 18(6):535-558.
  6. Rosai J. *Rosai and Ackerman's surgical Pathology*. 9th ed. New York. Female Reproductive System; 2011.
  7. Berek JS. *Berek & Novak's Gynecology*. 14th ed. Lippincott Williams & Wilkins; 2007.
  8. Wu TI, Yen TC, Lai CH. Clinical presentation and diagnosis of uterine sarcoma, including imaging. *Best Practice & Research Clinical Obstetrics & Gynaecology*. 2011; 25(6):681-689.
  9. Qiu LL, Yu RS, Chen Y, Zhang Q. Sarcomas of abdominal organs: computed tomography and magnetic resonance imaging findings. *Seminars in Ultrasound, CT, and MR*. 2011; 32(5):405-421.
  10. Zhang HJ, Zhan FH, Li YJ, Sun HR, Bai RJ, Gao S. Fluorodeoxyglucose positron emission tomography/computed tomography and magnetic resonance imaging of uterine leiomyosarcomas: 2 cases report. *Chinese Medical Journal*. 2011; 124(14):2237-2240.
  11. Ishizuka B, Fujiwaki S. Sonography of the endometrium. Hong Kong. In: Anderson JC. *Gynecologic Imaging*. Churchill Livingstone; 1999.
  12. Giuntoli RL 2nd, Metzinger DS, DiMarco CS, Cha SS, Sloan JA, Keeney GL, et al. Retrospective review of 208 patients with leiomyosarcoma of the uterus: prognostic indicators, surgical management, and adjuvant therapy. *Gynecologic Oncology*. 2003; 89(3):460-469.
  13. Sutton G, Brunetto VL, Kilgore L, Soper JT, McGehee R, Olt G, et al. A phase III trial of ifosfamide with or without cisplatin in carcinosarcoma of the uterus: A Gynecologic Oncology Group Study. *Gynecologic Oncology*. 2000; 79(2):147-153.
  14. Homesley HD, Filiaci V, Markman M, Bitterman P, Eaton L, Kilgore LC, et al. Phase III trial of ifosfamide with or without paclitaxel in advanced uterine carcinosarcoma: a Gynecologic Oncology Group Study. *Journal of Clinical Oncology*. 2007; 25(5):526-531.
  15. Foley OW, Rauh-Hain JA, Clemmer J, Clark RM, Hall T, Diver EJ, et al. Trends in the treatment of uterine leiomyosarcoma in the Medicare population. *International Journal of Gynecological Cancer*. 2015; 25(3):453-458.
  16. Reed NS, Mangioni C, Malmström H, Scarfone G, Poveda A, Pecorelli S, et al. Phase III randomised study to evaluate the role of adjuvant pelvic radiotherapy in the treatment of uterine sarcomas stages I and II: an European Organisation for Research and Treatment of Cancer Gynaecological Cancer Group Study (protocol 55874). *European Journal of Cancer*. 2008; 44(6):808-818.