



Research Article

# Preliminary Nutrient Determination and Regeneration of Pancreatic Islet Cells by Extracts of *Spondias mombin* Leaves in Streptozotocin-Induced Diabetic Rats

Nkeiruka Eluehike<sup>1\*</sup>, Iyere Osolase Onoagbe<sup>2</sup>

<sup>1</sup>Department of Medical Biochemistry, School of Basic Medical Sciences, University of Benin, Benin City, Nigeria.

<sup>2</sup>Department of Biochemistry, Faculty of Life Sciences, University of Benin, Benin City, Nigeria.

\*Corresponding author:

Nkeiruka Eluehike,  
Department of Medical  
Biochemistry, School of Basic  
Medical Sciences, University of  
Benin, Benin City, Nigeria.  
Tel: +2348061344256,  
Email:nkeiruka.ezeugwu@  
uniben.edu

Received: 20 March 2020

Accepted: 19 June 2020

ePublished: 29 June 2020

## Abstract

**Background:** There is a growing trend towards the use of medicinal plant that can prevent degeneration of pancreatic cells and regenerate islet cells in diabetes treatment

**Objectives:** The possible effects of the extracts of *Spondias mombin* leaves on the regeneration of pancreatic beta cells in streptozotocin (STZ)-induced diabetic rats were determined in this study.

**Methods:** Twenty-five male Wistar rats were randomly divided into 5 groups (A-E) including normal and diabetic rats. Aqueous and ethanol extracts of *S. mombin* were administered orally to diabetic rats in groups D and E for 12 weeks. Blood samples were collected for serum insulin and C-peptide assays. The pancreases were also collected for histopathological examination. Additionally, mineral and vitamin contents of the leaves were determined using standard procedures.

**Results:** The highest vitamin content was vitamin C in the leaves, while the highest mineral content was calcium. Treatment with extracts of *Spondias mombin* attenuated the STZ-induced hypoinsulinemia, which was evident from the increased serum insulin and c-peptide levels in the extract treated groups. Histopathological examination of the pancreas revealed an increase in the number and size of the pancreatic beta cells in the extracts treated groups in comparison to the shrunken and diminished islet cells observed in the untreated animals.

**Conclusion:** Extracts of *S. mombin* leaves are capable of regenerating pancreatic  $\beta$ -cells which were destroyed by streptozotocin induction.

**Keywords:** Pancreatic  $\beta$ -cells, *S. mombin*, insulin, C-peptide, Diabetes



## Introduction

Diabetes mellitus (DM) is a metabolic disorder marked by chronic high blood glucose, which results in an array of secondary complications of the heart, kidney, and eyes (1). DM is the predominant cause of death around the world affecting both developing and developed countries. DM is, therefore, a serious health challenge placing a heavy burden on the economy. The global prevalence of DM has shown an alarming projection in recent times and according to the World Health Organization (WHO), diabetes will be seen as the seventh leading cause of mortality by the year 2030 (2). Taking into account the pathology of diabetes, the prevention of beta cell from degenerating and enhancement of the endogenous regeneration of islets will be a crucial strategy in the management of diabetes. Despite the availability of therapy for diabetes management, there is a growing interest in using anti-diabetic compounds from natural sources because of the unwanted adverse effects of the available drugs (3).

A wide range of studies are available on the advantageous

effects of using phytotherapy for the management of diabetes (4). The mechanism of action of phytochemicals and active isolate(s) from plants is by decreasing intestinal absorption of glucose, inhibiting hepatic gluconeogenesis, enhancing uptake of glucose by tissues, stimulation of insulin release by the pancreas, and/or regenerating pancreatic tissues (5-7)

*Spondias mombin* is a fructiferous plant belonging to a large family referred to as Anacardiaceae. All parts of the plant have been used in the management of various disease conditions. These conditions include cardiovascular diseases, dysentery, hemorrhoids, and diarrhea (8). Hosseini et al (9) in their reports on the "pancreatic beta cell protection/regeneration with phytotherapy" recorded an increase in the number, percentage, and volume density of beta cells in islets of the treated diabetic animals. We, therefore, aimed to determine the improvement of insulin secretion and effects of leaf extracts (aqueous and ethanol) of *S. mombin* on pancreatic islet cell regeneration in streptozotocin-induced diabetic rats.

Archive of SID

Materials and Methods

Plant Material

Fresh leaves of *S. mombin* were obtained from fields around the campus of the University of Benin in Edo State, Nigeria. Identification and authentication were done in the Department of Plant Biology and Biotechnology, University of Benin, Benin City. Voucher specimens were deposited in the Herbarium with voucher number UBH<sub>3</sub>345.

Preparation of Plant Extract

The leaves were allowed to dry for few days. Then, they were pulverized with a mechanical grinder.

Afterwards, 1000 g of the pulverized sample was macerated in distilled water (3 L) for 48 hours, and 1000 g of the leaves were also macerated in ethanol (4 L). The crude extracts obtained were lyophilized. The freeze-dried extracts were kept in the freezer until use.

The mineral content of the powdered leave sample was investigated using the atomic absorption spectrometer (Shimadzu).

Vitamin Determination

The composition of the vitamins of the powdered leave sample was determined using a high-performance liquid chromatographic technique. Samples were separated using Acclaim PA column (3 μm, 120 A, 3.0 ×150 mm) for fat-soluble vitamins and Acclaim C18 column (3 μm, 120 A, 3.0 ×150 mm) for water-soluble vitamins.

Induction of Diabetes

Streptozotocin dissolved in carbonate buffer (0.1 M) with a pH value of 4.5 was administered by intra-peritoneal injection at a dose of 65 mg/kg of body weight after a 12-hour fasting period. Diabetes was confirmed on day 7 by determining fasting blood sugar (FBS) using Accu-Chek glucometer. Only rats with FBS ≥ 250 mg/dL were used for this study

Feeding Pattern

A total of 25 male albino Wistar rats obtained from the animal house of the Department of Anatomy, University of Benin, Benin City, were used for this study. They were kept in galvanized cages and allowed to acclimatize for 2 weeks before extract administration under 12 hours light/dark cycle. The room temperature was 22°C to 25°C and the animals had free access to food and water.

The rats were randomly divided into 5 groups (A-E) of 5 rats each.

- Group A: normal control
- Group B: diabetic control (untreated diabetic rats)
- Group C: positive control (diabetic rats treated with 5 mg/kg of body weight of glibenclamide as the standard drug)

- Group D: diabetic rats treated with 200 mg/kg of body weight of aqueous extract
- Group E: diabetic rats treated with 200 mg/kg of body weight of ethanol extract.

Extracts were given orally using an orogastric tube daily for twelve weeks. At the end of the 12th week, the animals were anesthetized with chloroform and the blood samples were taken by cardiac puncture into plain sample tubes. Serum samples used for the biochemical assays were obtained after centrifuging the blood sample at 3000 g for 10 minutes. The sera obtained were used for insulin and C-peptide assays using insulin and C-peptide ELISA kits, respectively.

Histological Evaluation

The excised pancreases were rinsed with normal saline and fixed for two days in 10 % buffered neutral formalin. The sections were 5 μm thick. They were paraffin-embedded and stained with hematoxylin and eosin. The sections of the pancreases were prepared and examined under Leica DM750 research microscope. Digital photomicrographs of the tissue sections were taken at ×40 and ×100 magnifications.

Statistical Analysis

Results were represented as mean ± SEM. The results were computed statistically using GraphPad Prism 5. The level of significance was determined at P<0.05 using analysis of variance.

Results

Table 1 shows the mineral composition of the pulverized leaves of *S. mombin*. Calcium was the highest mineral content, followed closely by phosphorus, sodium, and potassium with the lowest mineral content being copper while cadmium was not detected.

Table 2 shows the vitamin composition of the pulverized leaves of *S. mombin*. Of the vitamins identified, vitamin C gave the highest content

Figure 1 shows the chromatogram of vitamin composition

Table 1. Mineral Content of the Dry Powdered Plant Sample

Parameter	Composition (mg/100 g)
Sodium	31.74
Potassium	15.96
Calcium	50.58
Magnesium	12.97
Phosphorus	42.63
Iron	5.98
Zinc	9.74
Copper	<0.01
Chromium	ND

ND: Not Detected.

Values represent the mineral composition of the powdered leave samples of *S. mombin* which were obtained from a single determination.

Table 2. Vitamins Composition of *Spondias Mombin* Leaves

Retention Time (min)	Area	Amount (mg/100 g)	Name of Vitamin
12.737	66.36932	0.705396	Vitamin B3
13.882	31.50593	0.184030	Vitamin B6
16.037	105.8693	16.33779	Vitamin C
17.092	132.86963	0.107585	Vitamin A
17.666	46.3825	0.0137827	Vitamin B1
18.764	74.83737	0.0031613	Vitamin B2
19.101	128.87108	0.0206247	Vitamin D
19.519	195.34097	0.662654	Vitamin E
20.537	65.37851	0.0405775	Vitamin B9
21.501	97.67581	0.168593	Vitamin K
22.603	106.72191	0.114862	Vitamin B5
22.706	53.67599	0.00662043	Vitamin B 12

Values represents the vitamins composition of powdered leaves samples which were obtained from a single determination

of pulverized leaves of *Spondias mombin*. Figure 2 shows the result of serum insulin and C-peptide assay. A significant decrease in serum insulin and C-peptide levels was seen in the diabetic control rats when compared to the normal control group.

Histological studies revealed that the normal pancreases were characterized by well-defined acinar cells, islet of Langerhans, interlobular ducts and interlobular arteries in comparison to the diabetic control pancreases which had hypoplastic islets, distorted vascular cells and ducts filled with proteinaceous plugs. The pancreases of the positive control, ethanol extract treated and aqueous extract treated diabetic rats showed luxuriant islets and normal interlobular arteries and ducts. In addition, the number and sizes of the islet cells markedly increased in the treated rats when compared with the untreated animals (Supplementary file 1).

## Discussion

Beta cell degeneration caused by streptozotocin resulted in a reduction in serum insulin and C-peptide levels (Figure 2). The measurement of C-peptide and insulin concentration has been reported to be an important marker of insulin secretion (10). As the estimation of serum insulin without assaying C-peptide may not be ideal because insulin goes through first-pass clearance by the liver once secreted by the pancreas. The increase of serum insulin and C-peptide concentration observed in the treated diabetic rats may have been due to the up-regulation of insulin synthesis by the pancreatic  $\beta$ -cells or regeneration of the islet cells as confirmed by the histological studies. The high concentration of serum insulin seen in the diabetic treated rats suggests that *S. mombin* can be used as an anti-diabetic agent that enhances the secretion of insulin. We recorded 68.1%, 47.58%, and 50.99% increase in serum insulin concentration of the glibenclamide, aqueous, and ethanol-treated diabetic rats, respectively, when compared with the diabetic control. On the other hand, 71.13%, 54%, and 45.24% increase in serum C-peptide concentration were

reported for glibenclamide, aqueous, and ethanol-treated diabetic rats, respectively. This, therefore, shows that the ethanol extract better increased serum insulin concentration, while aqueous extract better increased serum C-peptide level.

It is proposed that the increased insulin levels noted in the present study could be due to the ability of the phytochemicals, amino acid contents, minerals, and vitamins in *S. mombin* to stimulate insulin release, inhibit insulin breakdown and/or rejuvenate  $\beta$ - cells that were destroyed by streptozotocin in the diabetic state. Studies have shown that the anti-diabetic effects of many phytochemicals from plant materials have been attributed to their antioxidant properties (11). In our previous study, we have established that the rich polyphenols present in the extracts of *S. mombin* have antioxidant effects (12).

C-peptide is an important marker for assessing pancreatic beta cell function. It has a long half-life and is not subject to hepatic clearance. Some researchers prefer c-peptide concentration to insulin in recognizing any variation in beta cell secretion of insulin. Our results indicated that there was a remarkable reduction in C-peptide level in STZ induced diabetic rats. Cong and Chen (13) and Amin et al (14) reported the same findings.

Regeneration of  $\beta$ -cells has also been reported by several authors following treatment of STZ-induced diabetic

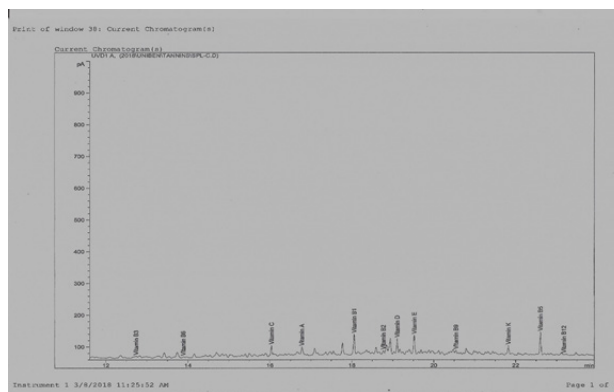


Figure 1. Chromatogram of Vitamin Composition of Pulverized Leaves of *Spondias Mombin*.

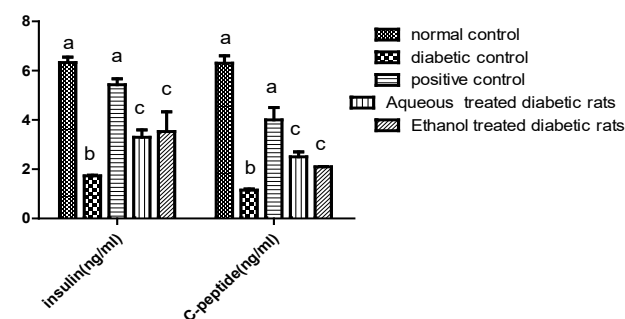


Figure 2. Effects of Aqueous and Ethanol Extracts of *Spondias Mombin* Leaves on Serum Insulin and C-peptide Levels of Diabetic Rats Treated for 12 Weeks.

Values represent serum insulin and C-peptide level of rats treated with aqueous and ethanol extracts for 12 weeks which are expressed as mean  $\pm$  SEM and were obtained from 3-5 determinations.

Archive of SID

animals with medicinal plants (15-17). Other reports have established that diabetes induction in animals can lead to 50% reduction in pancreatic  $\beta$ -cells (18,19). The increase in the number and size of the pancreatic  $\beta$ -cells observed in the aqueous and ethanol extract treated animals in this study can be regarded as the  $\beta$ -cells regenerative effects of *S. mombin*. Our result also showed evidence of beta cell recovery in the glibenclamide treated group when compared with the untreated animals. Onakpa and Asuzu (20), and Alese et al (21) reported similar findings. Glibenclamide has been used as an antidiabetic drug to compare the efficacy of various hypoglycemic medicinal compounds (22)

Certain minerals and vitamins play a vital function in controlling diabetes. They may have directly or indirectly led to the improvement of insulin secretion and regeneration of the pancreatic beta cells observed in this study. Of the minerals identified in *Spondias mombin* (Table 1), magnesium and zinc play important roles in diabetic individuals. Magnesium plays a role in the metabolism of glucose. Certain conditions such as insulin resistance and carbohydrate intolerance occur often as a result of low magnesium in the body (23). Owing to the role of magnesium in controlling diabetes, decreased magnesium levels in the blood can be compelling.

Zinc is an important mineral useful to diabetics. In humans and animals, diabetes causes alterations in vital micronutrients including zinc (24). Zinc is required for the production and storage of insulin. It plays a role in preserving the structure of insulin (25).

Vitamins C and E are important antioxidants which help protect the cell from oxidative damage (26). A crucial link exists between the level of vitamin C in the body and the development of diabetes (27).

Niacin (vitamin B3) is a co-enzyme needed in reduction and oxidation reactions. Niacin plays a vital role in protecting the cardiovascular system in diabetics. Niacin has been shown to protect the pancreas, by maintaining intracellular levels of  $NAD^+$ , leading to the prevention of autoimmune destruction of beta cells. It also mops up nitric oxide radicals in the pancreas. This in turn protects the pancreas from oxidative damage.

It was shown that the presence of vitamin E in *S. mombin* may be helpful in eliminating byproducts of lipid peroxidation. A decreased incidence of diabetes has been reported in people with high vitamin E (28) and researches have shown that diabetic patients have decreased antioxidants in the body (29). Therefore, the presence of vitamin E in *S. mombin* will be useful to individuals with diabetes.

Morphometric analysis of the sections of the pancreas showed a remarkable increase in the surface area of islets of the treated diabetic rats ( $4904.00 \pm 4.00$  pixel,  $3307.00 \pm 2.00$  pixel, and  $3293.00 \pm 318.00$  pixel for the glibenclamide, aqueous, and ethanol treated diabetic groups, respectively) compared to the untreated group ( $1324.50 \pm 2.50$  pixel).

The diameter of islet also increased in the treated diabetic animals ( $21.86 \pm 0.10$ ,  $20.47 \pm 0.23 \mu\text{m}^3$ , and  $20.45 \pm 0.33 \mu\text{m}^3$  for the glibenclamide, aqueous, and ethanol treated diabetic groups, respectively) when compared to the untreated rats ( $17.53 \pm 0.59 \mu\text{m}^3$ ) (Tables 3 and 4) (Figures 3 and 4).

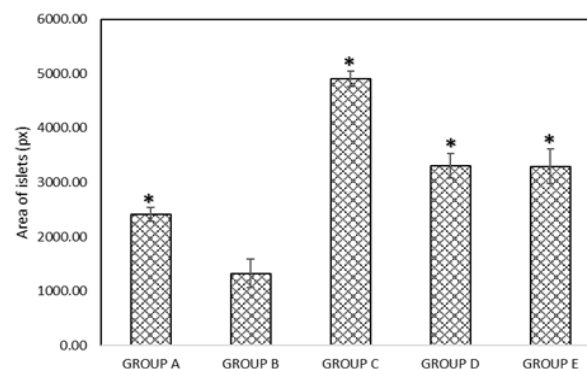
**Table 3.** Effects of aqueous and ethanol extract of *Spondias Mombin* Leaves on Serum Insulin and C-peptide Levels of Diabetic Rats Treated for 12 Weeks.

	Insulin(ng/mL)	C-peptide(ng/mL)
Normal control	6.330±0.22	6.30±0.30
Diabetic control	1.73±0.03	1.15±0.05
Positive control	5.43±0.24	4.0±0.50
Aqueous extract treated rats	3.30±0.30	2.50±0.20
Ethanol extract treated rats	3.53±0.80	2.10±0.01

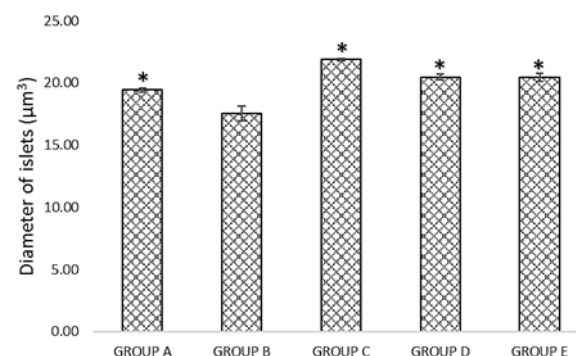
C-peptide Levels of Diabetic Rats Treated for 12 Weeks. Values represent serum insulin and C-peptide level of rats treated with aqueous and ethanol extracts for 12 weeks which are expressed as mean  $\pm$  SEM and were obtained from 3-5 determinations

**Table 4.** surface area and diameter of pancreatic islet cell

	Area (Pixels)	Diameter( $\mu\text{m}^3$ )
Normal control	2409.00±128.00	19.42±0.17
Diabetic control	1324.50±262.50	17.53±0.59
Positive control	4904.00±140.00	21.86±0.10
Aqueous extract treated rats	3307.00±225.00	20.47±0.23
Ethanol extract treated rats	3293.00±318.00	20.45±0.33



**Figure 3.** Surface Area of Islet Cells. \*Significantly different from Group B



**Figure 4.** Diameter of Islet Cell. \*Significantly different from Group B.

## Archive of SID

### Conclusion

The improvement in insulin concentration and pancreatic  $\beta$ -cells regeneration observed in this study may not be unconnected to the presence of important minerals and vitamins detected in the leaves of *Spondias mombin*.

### Authors' Contributions

IOO designed the experiment and supervised the work. NE performed the experimental work and wrote the manuscript.

### Conflict of Interest Disclosures

None.

### Ethical Issues

Treatment of the animals conformed to the guidelines of the Principles of Laboratory Animal Care (NIH Publication 85-23, revised 1985).

### Acknowledgements

The authors acknowledge Dr. Eze at the Department of Anatomy, University of Benin for the histopathological studies. The authors are also grateful to the Natural Product Research and Disease Control Laboratory (NPRDC), Department of Biochemistry, University of Benin for providing the facilities used in carrying out this research work.

### Supplementary Files

Supplementary file 1 contains Figure S1.

### References

- Thornalley PJ, McLellan AC, Lo TW, Benn J, Sönksen PH. Negative association between erythrocyte reduced glutathione concentration and diabetic complications. *Clin Sci (Lond)*. 1996;91(5):575-82. doi: [10.1042/cs0910575](https://doi.org/10.1042/cs0910575).
- World Health Organization (WHO). Diabetes. Fact Sheet No. 312. Geneva: WHO; 2015. Available from: <http://www.who.int/mediacentre/factsheets/fs312/en/>. Accessed Jan 2014.
- Zhou JY, Zhou SW, Zeng SY, Zhou JY, Jiang MJ, He Y. Hypoglycemic and hypolipidemic effects of ethanolic extract of *Mirabilis jalapa* L. root on normal and diabetic mice. *Evid Based Complement Alternat Med*. 2012;2012:257374. doi: [10.1155/2012/257374](https://doi.org/10.1155/2012/257374).
- Ghorbani A. Phytotherapy for diabetic dyslipidemia: evidence from clinical trials. *Clin Lipidol*. 2013;8(3):311-9. doi: [10.2217/clp.13.26](https://doi.org/10.2217/clp.13.26).
- Asgary S, Parkhideh S, Solhpour A, Madani H, Mahzouni P, Rahimi P. Effect of ethanolic extract of *Juglans regia* L. on blood sugar in diabetes-induced rats. *J Med Food*. 2008;11(3):533-8. doi: [10.1089/jmf.2007.0611](https://doi.org/10.1089/jmf.2007.0611).
- Kamyab H, Hejrati S, Khanavi M, Malihi F, Mohammadirad A, Baeeri M, et al. Hepatic mechanisms of the Walnut antidiabetic effect in mice. *Cent Eur J Biol*. 2010;5(3):304-9. doi: [10.2478/s11535-010-0019-z](https://doi.org/10.2478/s11535-010-0019-z).
- Jelodar GA, Maleki M, Motadayen MH, Sirus S. Effect of fenugreek, onion and garlic on blood glucose and histopathology of pancreas of alloxan-induced diabetic rats. *Indian J Med Sci*. 2005;59(2):64-9. doi: [10.4103/0019-5359.13905](https://doi.org/10.4103/0019-5359.13905).
- León de Pinto G, Martínez M, Beltrán O, Rincón F, Manuel Igartuburu J, Rodríguez Luis F. Structural investigation of the polysaccharide of *Spondias mombin* gum. *Carbohydr Polym*. 2000;43(2):105-12. doi: [10.1016/s0144-8617\(99\)00197-6](https://doi.org/10.1016/s0144-8617(99)00197-6).
- Hosseini A, Shafiee-Nick R, Ghorbani A. Pancreatic beta cell protection/regeneration with phytotherapy. *Braz J Pharm Sci*. 2015;51(1):1-16. doi: [10.1590/s1984-82502015000100001](https://doi.org/10.1590/s1984-82502015000100001).
- Juárez-Rojop IE, Díaz-Zagoya JC, Ble-Castillo JL, Miranda-Osorio PH, Castell-Rodríguez AE, Tovilla-Zárate CA, et al. Hypoglycemic effect of *Carica papaya* leaves in streptozotocin-induced diabetic rats. *BMC Complement Altern Med*. 2012;12:236. doi: [10.1186/1472-6882-12-236](https://doi.org/10.1186/1472-6882-12-236).
- Kaleem M, Asif M, Ahmed QU, Bano B. Antidiabetic and antioxidant activity of *Annona squamosa* extract in streptozotocin-induced diabetic rats. *Singapore Med J*. 2006;47(8):670-5.
- Ezeugwu N, Onoagbe IO. Amino acid contents of *Spondias mombin* leaves and in vitro antioxidant capacity of aqueous and ethanol extract of *Spondias mombin* leaves. *JOPAT*. 2018;17(2):221-36.
- Cong L, Chen J. [Effect of exercise on leptin in streptozotocin-induced diabetic rats]. *Wei Sheng Yan Jiu*. 2001;30(3):158-9, 62.
- Amin KA, Awad EM, Nagy MA. Effects of panax quinquefolium on streptozotocin-induced diabetic rats: role of C-peptide, nitric oxide and oxidative stress. *Int J Clin Exp Med*. 2011;4(2):136-47.
- Xiu LM, Miura AB, Yamamoto K, Kobayashi T, Song QH, Kitamura H, et al. Pancreatic islet regeneration by ephedrine in mice with streptozotocin-induced diabetes. *Am J Chin Med*. 2001;29(3-4):493-500. doi: [10.1142/s0192415x01000514](https://doi.org/10.1142/s0192415x01000514).
- Sivaraj A, Devi K, Palani S, Kumar PV, Kumar BS, David E. Anti-hyperglycemic and anti-hyperlipidemic effect of combined plant extract of *Cassia auriculata* and *Aegle marmelos* in streptozotocin (STZ) induced diabetic albino rats. *Int J PharmTech Res*. 2009;1(4):1010-6.
- Mujić A, Grdović N, Mujić I, Mihailović M, Živković J, Poznanović G, et al. Antioxidative effects of phenolic extracts from chestnut leaves, catkins and spiny burs in streptozotocin-treated rat pancreatic  $\beta$ -cells. *Food Chem*. 2011;125(3):841-9. doi: [10.1016/j.foodchem.2010.08.068](https://doi.org/10.1016/j.foodchem.2010.08.068).
- Wang L, Zhang XT, Zhang HY, Yao HY, Zhang H. Effect of *Vaccinium bracteatum* Thunb. leaves extract on blood glucose and plasma lipid levels in streptozotocin-induced diabetic mice. *J Ethnopharmacol*. 2010;130(3):465-9. doi: [10.1016/j.jep.2010.05.031](https://doi.org/10.1016/j.jep.2010.05.031).
- Lee SH, Park MH, Heo SJ, Kang SM, Ko SC, Han JS, et al. Dieckol isolated from *Ecklonia cava* inhibits alpha-glucosidase and alpha-amylase in vitro and alleviates postprandial hyperglycemia in streptozotocin-induced diabetic mice. *Food Chem Toxicol*. 2010;48(10):2633-7. doi: [10.1016/j.fct.2010.06.032](https://doi.org/10.1016/j.fct.2010.06.032).
- Monday OM, Uzoma AI. Histological changes and antidiabetic activities of *Icacina trichantha* tuber extract in beta-cells of alloxan induced diabetic rats. *Asian Pac J Trop Biomed*. 2013;3(8):628-33. doi: [10.1016/s2221-1691\(13\)60127-6](https://doi.org/10.1016/s2221-1691(13)60127-6).
- Alese MO, Adewale SO, Ijomore MO, Ajayi SA, Omonisi A. Histological studies of pancreatic beta cells of streptozotocin induced diabetic Wistar rats treated with methanolic extract of *Sphenocentrum jollyanum*. *J Pharmaceutical and Scientific Innovation*. 2013;2(2):8-12.
- Andrade Cetto A, Wiedenfeld H, Revilla MC, Sergio IA. Hypoglycemic effect of *Equisetum myriochaetum* aerial parts on streptozotocin diabetic rats. *J Ethnopharmacol*. 2000;72(1-2):129-33. doi: [10.1016/s0378-8741\(00\)00218-x](https://doi.org/10.1016/s0378-8741(00)00218-x).
- Resnick LM, Gupta RK, Bhargava KK, Gruenspan H, Alderman MH, Laragh JH. Cellular ions in hypertension, diabetes, and

- obesity. A nuclear magnetic resonance spectroscopic study. *Hypertension*. 1991;17(6 Pt 2):951-7. doi: [10.1161/01.hyp.17.6.951](https://doi.org/10.1161/01.hyp.17.6.951).
24. Kowluru RA, Kennedy A. Therapeutic potential of antioxidants and diabetic retinopathy. *Expert Opin Investig Drugs*. 2001;10(9):1665-76. doi: [10.1517/13543784.10.9.1665](https://doi.org/10.1517/13543784.10.9.1665).
25. Chausmer AB. Zinc, insulin and diabetes. *J Am Coll Nutr*. 1998;17(2):109-15. doi: [10.1080/07315724.1998.10718735](https://doi.org/10.1080/07315724.1998.10718735).
26. Guyton AC, Hall JE. *Textbook of Medical Physiology*. 11th ed. Philadelphia, India: Elsevier; 2006. p. 113-5.
27. Harding AH, Wareham NJ, Bingham SA, Khaw K, Luben R, Welch A, et al. Plasma vitamin C level, fruit and vegetable consumption, and the risk of new-onset type 2 diabetes mellitus: the European prospective investigation of cancer--Norfolk prospective study. *Arch Intern Med*. 2008;168(14):1493-9. doi: [10.1001/archinte.168.14.1493](https://doi.org/10.1001/archinte.168.14.1493).
28. Salonen JT, Nyyssönen K, Tuomainen TP, Mäenpää PH, Korpela H, Kaplan GA, et al. Increased risk of non-insulin dependent diabetes mellitus at low plasma vitamin E concentrations: a four year follow up study in men. *BMJ*. 1995;311(7013):1124-7. doi: [10.1136/bmj.311.7013.1124](https://doi.org/10.1136/bmj.311.7013.1124).
29. Polidori MC, Mecocci P, Stahl W, Parente B, Cecchetti R, Cherubini A, et al. Plasma levels of lipophilic antioxidants in very old patients with type 2 diabetes. *Diabetes Metab Res Rev*. 2000;16(1):15-9. doi: [10.1002/\(sici\)1520-7560\(200001/02\)16:1<15::aid-dmrr71>3.0.co;2-b](https://doi.org/10.1002/(sici)1520-7560(200001/02)16:1<15::aid-dmrr71>3.0.co;2-b).