

## Original Article

# Occurrence and Distribution of Sarcocystis Parasite Isolated from Sheep in Yazd Province, Iran

Bahador Hajimohammadi<sup>1,2</sup>, Amin Zohourtabar<sup>3</sup>, Ali Fattahi Bafghi\*<sup>4</sup>, Azam Omidpanah<sup>5</sup>, Tayebe Rayati<sup>5</sup>,  
Abolfazl Ghasemi<sup>5</sup>, Alireza Sazmand<sup>6</sup>

<sup>1</sup> Research Center for Molecular Identification of Food Hazards, Shahid Sadoughi University of Medical Sciences, Yazd, Iran

<sup>2</sup> Department of Food Hygiene and Safety, Faculty of Health, Shahid Sadoughi University of Medical Sciences, Yazd, Iran

<sup>3</sup> Graduated from the Department of Food Hygiene and Safety, School of Health, Shahid Sadoughi University of Medical Sciences, Yazd, Iran

<sup>4</sup> Department of Medical Parasitology and Mycology, School of Medicine, Shahid Sadoughi University of Medical Sciences, Yazd, Iran

<sup>5</sup> Graduated from Institute of Applied-Scientific Education of Jihad-e-Agriculture, MolaSadra Center,

University of Applied Science and Technology, Yazd, Iran

<sup>6</sup> Department of Agriculture, Payame Noor University, Iran

**Received:** 2014/4/6

**Accepted:** 2014/11/8

---

### Abstract

**Introduction:** Sarcocystis species are one of the most important meat borne parasites. Sarcocystosis causes several symptoms in human as well as numerous diseases with a high economic impact on livestock. In the current paper at first the results of a pilot study for determination of disease agent in the lambs of Yazd province in central Iran is presented. Then the status of parasite in red meat products in the study region is discussed.

**Materials and Methods:** Muscles of 70 slaughtered sheep from both sexes and different ages were investigated for presence of parasite cysts from September to October 2013. Carcass inspection with naked eye at industrial slaughterhouses of Yazd for macroscopic cysts, and pepsin-digestion method for microscopic cysts was performed on common infected sites of infection.

**Results:** No macroscopic cyst was seen at inspection. However, bradyzoites of parasite were observed in 97.14% of animals' digested muscles. No significant difference between infection and age groups or sex of animals was observed.

**Conclusion:** As humans are considered to be the final and intermediate host of different species of Sarcocystis and since parasite cysts are present at microscopic sizes, transmission of infection from lamb meat should come into consideration.

**Keywords:** Sarcocystis, Meat products, Iran

---

\* **Corresponding author; Tel:** +983518203410 **Email:** afbafghi@ssu.ac.ir

## Introduction

Sarcocystis species are emerging food-borne intracellular protozoan parasites with worldwide distribution. More than 150 species of the parasite have been isolated from various domestic and wild animals. Sarcocystis has an indirect life cycle based on intermediate (prey)-definitive (predator) host relationship. Carnivores are believed to be definitive and reservoir hosts of most species. The parasite produces tissue cysts in cardiac, striated and smooth muscles of intermediate hosts. Humans are known to be definitive host of *S. hominis* of beef origin and *S. suihominis* of pork origin, but can be the intermediate host of a variety of Sarcocystis species [1,2] for instance a recent paper from Malaysia reported an outbreak of symptomatic *S. nesbitti* infection in 89 individuals [3]. Clinical signs and symptoms are either muscular or intestinal. Muscular form pronounces fever, myalgia, myositis and cardiopathy. Intestinal infections with worldwide incidence of 6-10% cause abdominal discomfort, diarrhea, vomiting and dyspnea. As there is no known therapeutic treatment, the disease should be prevented by thorough cooking or freezing to kill bradyzoites, the infective stage of the parasite [4,5]. Some species of Sarcocystis infecting livestock are able to induce fever, anorexia, wasting, decreased milk production, diarrhea, muscle spasms, weakness, pneumonia, hemorrhages, abortion and death in them [6].

There are 4 known species of Sarcocystis to infect sheep as intermediate host. *S. tenella* (*S. ovicanis*) and *S. arieticanis* with macroscopic cysts have dog

origin as definitive host, while *S. gigantea* (*S. ovifelis*) and *S. medusiformis* with microscopic cysts come from cats. *S. tenella* is thought to be the most pathogenic species causing anorexia, fever, decreased weight gain, anemia and death, and has been associated with abortions in ewes. Neurologic signs including encephalomyelitis, muscle weakness, hindlimb paresis and ataxia have been seen in infected sheep. After recovery from the acute illness, some sheep may lose their wool. Acute deaths can also occur without other symptoms. *S. medusiformis* and *S. gigantea* are thought to be nonpathogenic or cause only mild self-limited disease [7, 8, and 9].

Several researches have been conducted on prevalence of Sarcocystis in meat and meat products of cattle, hamburgers and camels in Yazd province in central Iran [10, 11, 12, and 13]. However, as there is no information about incidence of disease in the sheep of this area, this preliminary study aimed to fill this gap in our knowledge on status of disease in the province.

## Materials & Methods

From September to October 2012 totally 70 slaughtered sheep in industrial abattoir of Yazd were randomly chosen. Animals aged from 10 months to 3 years, and were from both sexes. The animals' carcasses were inspected carefully for presence of macroscopic cysts of Sarcocystis. For investigating microscopic cysts, the most favorite edible muscles of limb and intercostal as well as diaphragm as

common sites of infection were chosen. Tissue samples were taken in individual containers, and moved to -20 °C freezer until examination at the end of sampling period.

For detection of *Sarcocystis* bradyzoites in microscopic cysts we used pepsin-digestion method described by Dubey et al. [14] with some modifications. Briefly, approximately 10 g of each muscle tissue was crushed and digested in 50 mL of digestion solution containing 1.3 g pepsin, 3.5 mL HCl, and 2.5 g NaCl in 500 mL distilled water.

After incubation for 30 min at 40 °C, the digested solution was centrifuged at 1500×g for 5 min. The sediments were then smeared on slides, stained by Giemsa and examined at 400× magnification under light microscopy.

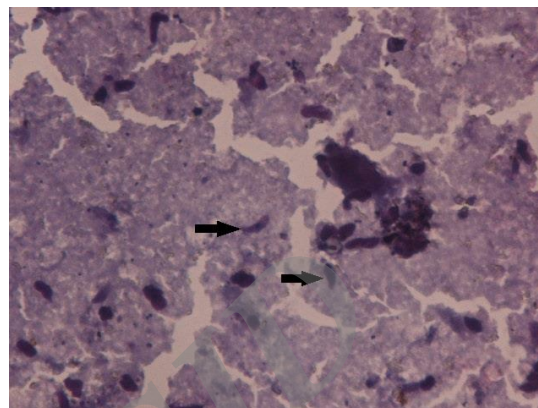
Statistical analysis was performed by SPSS (ver. 16, IBM, New York, USA) using  $\chi^2$  test with 95% confidence interval, and logistic regression test with considering p value less than 0.05 as significant difference.

## Results

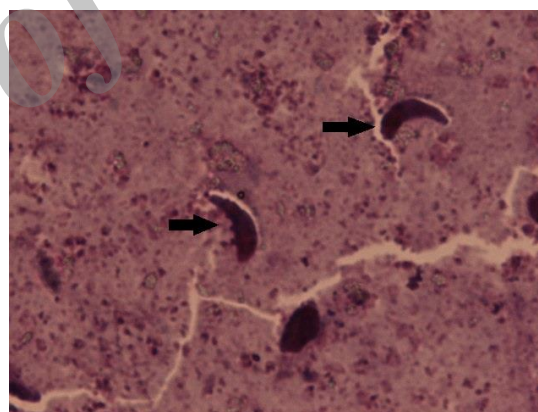
No macroscopic cysts were found during carcass inspection, but bradyzoites of *Sarcocystis* were found in 68 out of 70 examined animals (97.14%) at least in one organ.

All the infected animals harbored merozoites in their diaphragm, but intercostal muscles of 66 (94.28%) and limb muscles of 62 sheep (86.11%) were found to be infected. Banana-shaped bradyzoites in the digested muscle tissues are shown

in Figures 1 and 2 by arrows. Statistical analysis showed no significant difference between infection and age or sex of animals.



**Figure 1:** Banana-shaped bradyzoites microscopic cyst in digested muscle tissues



**Figure 2:** Banana-shaped bradyzoites microscopic cyst in digested muscle tissues

## Discussion

No *Sarcocystis* cysts were detected in any of the slaughtered sheep but this result is based only on macroscopic examinations by meat inspection. This is a common finding and is in accordance with large scale retrospective studies in Iran where in a 5 year

study of abattoir condemnations due to parasitic infections, only 1 carcass among 1,191,871 inspected sheep at the slaughterhouse of Ahwaz in south-west was found to harbor macro cysts of the parasite <sup>[15]</sup>. In another study in north-east region among 275,439 slaughtered sheep inspected during 5 years 0.04% carcass condemnation due to sarcocystosis is reported <sup>[16]</sup>.

Also Oryan et al. <sup>[17]</sup> in their study in Fars province observed *S. gigantea* as the most common species followed by *S. medusiformis*, *S. tenella* and *S. arieticanis*. However, Mirzaei Dehaghi and colleagues <sup>[18]</sup> reported macrocysts in non-edible organs of esophagus and diaphragm of 6% and 2.88% slaughtered sheep in Kerman. In another study in north-west macrocysts were found in investigated organs with average prevalence of 17.56% while all of the investigated samples were positive with pepsin-digestion method <sup>[19]</sup>. These overall findings show dog-sheep cycle to be more important in epidemiology of disease in Iran, and microscopic studies to be preferred to naked eye inspections. Pepsin digestion method as gold standard for diagnosis of *Sarcocystis* has been proven to be more sensitive than muscle squash method <sup>[20]</sup>. In our study bradyzoites of parasite were found in 97.14% of tested animals muscles. This high prevalence of *Sarcocystis* infection in Iranian sheep has been reported in almost all studies, where Dehaghi et al. <sup>[18]</sup> and Arshad et al. <sup>[19]</sup> reported 100% of sheep in Kerman and Tabriz region to be positive for microcysts of parasite. These results

suggest the significant importance of infection prevention in individuals consuming lamb.

Theoretically parasitic infection rate risk increases with increment in age of the animals because of the higher chance of being exposed to parasites. In case of *Sarcocystis* some studies reported higher infection in older animals <sup>[20, 21]</sup>, while some others including the present study found no significant difference in infection of younger and older animals <sup>[18, 21]</sup>.

Despite the high prevalence of animals' meat and meat products in all parts of Iran, to the best of our knowledge, there is no report of human sarcocystosis in the country which is because of the Persian culture as Iranians are used to consuming red meat well-done, and because there are safe water sources and proper hygiene. In contrast, in Southeast Asia human sarcocystosis is prevalent, and there have been several reports of *Sarcocystis* spp. infection in Malaysian people and travelers returning from Malaysia <sup>[3, 22]</sup>.

There are few published reports on *Sarcocystis* in Yazd province. Hamidinejat et al. (2013) investigated *Sarcocystis* in camels' meat using pepsin-digestion method, and found 51.5% of 130 animals to be infected with bradyzoites of parasite in at least one of the most common sites of the infection organs: esophagus, heart, masseter muscle, intercostal muscle and limb muscle. Hajimohammadi et al. (2014) and Eslami et al. (2014) were the first to identify *S. hominis* and *S. hirsuta* using PCR-RFLP in cattle in Iran from Yazd. Afterward they reported *S. cruzi*, *S. hirsuta* and *S.*

hominis with respect to prevalences in 77.9% of 190 raw hamburgers distributed in Yazd city <sup>[12]</sup>. The current pilot study aimed to fill the gap of investigated animal species in the province, and reports that 97.14% of sheep are infected with parasite. However, further studies on identification of sheep *Sarcocystis* species using molecular techniques are necessary although none of *Sarcocystis* spp. in sheep as intermediate host infects humans as definitive host. This necessity is because humans can serve several species as intermediate host, so knowledge of available species in Yazd province can help us for a better understanding of disease in the region.

### Conclusion

Considering the high prevalence of *Sarcocystis* infection in Yazd province meats and meat products, and the absence of observing macrocysts in the region, it is necessary to avoid eating raw or under-cooked meat products. Also freezing meat at -4 and -20 °C for 2 days and 1 day before consumption renders bradyzoites in meat noninfectious. Hence, a training program for

people via media regarding these recommendations is suggested. In animals, chemoprophylaxis using anticoccidial drugs such as amprolium and salinomycin is necessary and should be advised to farmers by the related organizations.

### Conflict of interest

The authors declare that there are no conflicts of interest.

### Acknowledgment

This study was conducted from a research project proposal at Shahid Sadoughi University of Medical Sciences. We thank authorities of Deputy of Research, Shahid Sadoughi University of Medical Sciences, Yazd, Iran for their financial support. Also, we acknowledge Institute of Applied-Scientific Education of Jihad-e-Agriculture, MolaSadrd Center, University of Applied Science and Technology, Yazd, Iran for their support and cooperation. Hence, all the authors contributed equally to this work

### References

1. Nourollahi Fard SR, Asghari M, Nouri F. Survey of *Sarcocystis* infection in slaughtered cattle in Kerman, Iran. *Trop Anim Health Pro.* 2009; 41: 1633–36.
2. Motamedi GR, Dalimi A, Nouri A, Aghaeipour K. Ultrastructural and molecular characterization of *Sarcocystis* isolated from camel (*Camelus dromedarius*) in Iran. 2011; 108: 949–54.
3. Abubakar S, Teoh BT, Sam SS, et al. Outbreak of human infection with *Sarcocystis nesbitti*, Malaysia, 2012. *Emerg Infect Dis.* 2013; 19(12): 1989–91.
4. Fayer R. *Sarcocystis* spp. in Human Infections. *Clinical Microbiology Reviews.* 2004, 17(4): 894–902.
5. Hidron A, Vogenthaler N, Santos-Preciado JI, et al. Cardiac involvement with parasitic infections. *Clin Microbiol Rev.* 2010; 23(2): 324–49.

6. Dubey JP, Lindsay DS. Neosporosis, toxoplasmosis, and sarcocystosis in ruminants. *The Veterinary Clinics of North America. Food Animal Practic.* 2006; 22(3): 645–71.
7. OIE/Center of Food Security and Public Health, Sarcocystosis. CFSPH, Iowa, 2005; 1–6.
8. Satya D. Dubey, Some test functions for the parameters of the weibull distributions, *Naval Research Logistics Quarterly.* 2006; 13(2): 113-28.
9. Lindsay DS. Neosporosis: an emerging protozoal disease of horse. *Equine Veterinary Journal*, 2001, 33: 116-18.
10. Hamidinejat H, Hekmatimoghaddam S, Jafari H, et al. Prevalence and distribution patterns of Sarcocystis in camels (*Camelus dromedarius*) in Yazd province, Iran. *J Parasit Dis.* 2013; 37(2):163–5.
11. Hajimohammadi B, Eslami G, Oryan A, et al. Molecular identification of Sarcocystis hominis in native cattle of central Iran: A case report. *Trop Biomed.* 2014; 31(1):183–6.
12. Hajimohammadi B, Dehghani A, Moghaddam Ahmadi M, et al. Prevalence and species identification of Sarcocystis in raw hamburgers distributed in Yazd , Iran using PCR-RFLP. *J Food Qual Hazards Control.* 2014; 1: 15–20.
13. Eslami G, Zohourtabar A, Mehrizi SR. First molecular identification of Sarcocystis hirsuta in Iranian beef : A case report. *J Food Qual Hazards Control.* 2014; 1: 32–4.
14. Dubey JP, Speer CA, Fayer R. Sarcocystosis of animals and man, 1st edition. CRC Press Inc, 1988, Boca Raton.
15. Borji H, Azizzadeh M, Kamelli MA. Retrospective study of abattoir condemnation due to parasitic infections: economic importance in Ahwaz, southwestern Iran. *The Journal of Parasitology.* 2012; 98(5): 954–7.
16. Borji H, Parandeh S. The abattoir condemnation of meat because of parasitic infection, and its economic importance: results of a retrospective study in north-eastern Iran. *Annals of Tropical Medicine and Parasitology.* 2010; 104(8): 641–7.
17. Oryan A, Moghaddar N, Gaur SNS. The distribution pattern of Sarcocystis species, their transmission and pathogenesis in sheep in Fars Province of Iran. *Vet Res Commun.* 1996; 20(3): 243-53.
18. Dehaghi MM, Fallahi M, Sami M, et al. Survey of Sarcocystis infection in slaughtered sheep in Kerman Abattoir, Kerman, Iran. *Comparative Clinical Pathology.* 2013; 22(3): 343-6.
19. Arshad M, Dalimi A, Ghaffarifar F. Comparative study on Sarcocystis diagnosis in meat of slaughtered sheep in Tabriz. *Pajouhesh and Sazandegi.* 2007; 75: 68–72 [in Persian].
20. Hamidinejat H, Razi Jalali MH, Nabavi L. Survey on Sarcocystis Infection in Slaughtered Cattle in South-West of Iran, Emphasized on Evaluation of Muscle Squash in Comparison with Digestion Method. *J Anim Vet Adv.* 2010; 9(12):1724–6.
21. Oryan A, Ahmadi N, Mousavi SMM. Prevalence, biology, and distribution pattern of Sarcocystis infection in water buffalo (*Bubalus bubalis*) in Iran. *Trop Anim Health Pro.* 2010, 42(7): 1513-18.
22. Esposito DH, Freedman DO, Neumayr A, et al. Ongoing outbreak of an acute muscular Sarcocystis-like illness among travellers returning from Tioman Island, Malaysia. *Eurosurveillance*, 2012, 17(45): 20310.