



Necrolytic Migratory Erythema Associated With Glucagonoma Syndrome

Sara Saniee¹, Yalda Saniee², Armaghan G Zare¹, Ghazaleh Davarnia^{1*}

Abstract

Necrolytic migratory erythema (NME) is a rare cutaneous manifestation that may present as the first sign of glucagonoma syndrome. Glucagonoma syndrome is associated with alpha-cell pancreatic tumor, increased glucagon in blood and skin rash (NME). NME is usually the first and rather exclusive manifestation of this syndrome, but may occur in other diseases, which is called pseudoglucagonoma syndrome. We report a case of NME which is associated with glucagonoma syndrome.

Keywords: NME, Glucagonoma syndrome, Pseudoglucagonoma syndrome

Introduction

Glucagonoma syndrome develops due to a glucagon-secreting pancreatic tumor that causes specific clinical manifestations including necrolytic migratory erythema (NME). NME is often a rather exclusive manifestation of this syndrome that usually develops in the early stages of the disease (1). NME is characterized by irregular and annular cutaneous lesions with advancing border, erosion and crusting. This skin rash has a cyclic nature and lesions exist simultaneously at different stages (2).

Diagnosis of the syndrome is confirmed by NME, increased serum glucagon level and affirmation of pancreatic tumor (3).

In this study, a patient with metastatic pancreatic tumor is introduced where NME was the early manifestation of the disease.

Case Presentation

A 69-year-old female patient was referred to Dermatology Department in June 2016 due to an extensive erosive cutaneous eruption that had been presented for 16 months.

Her lesions initially were diagnosed as pemphigus foliaceus and were treated by prednisolone for 2 months. Due to the lack of response to the treatment, the patient was referred for more evaluation.

In medical history she had a cholecystectomy and cataract surgery. She was receiving aspirin, atenolol and atorvastatin because of hypertension and hyperlipidemia.

The skin eruption started in her lower extremities and lower abdomen and progressed to involve axilla and trunk. This eruption tended to wax and wane.

In addition to cutaneous lesions, the patient complained

of a 10 kg weight loss over the past year.

Physical examination revealed erythematous scaling, erosive and crusted plaques on lower extremities and trunk. Hyperpigmentation and scaling were dominant in old lesions. (Figures 1A and 1B). Other features included angular cheilitis and a mild depapillated red tongue.

Other systemic examinations were normal.

Laboratory testing revealed mild hypochromic anemia (hemoglobin: 11.3 g/dL). Liver function test, electrolytes, blood sugar, hemoglobin A1c (HbA1c), serum zinc level, ferritin, amylase and lipase were all normal.

Histologic analysis of skin eruption demonstrated mild acanthosis, hyperkeratosis, vacuolization of keratinocytes, dyskeratotic keratinocytes and neutrophils. There were clefts in the mid epidermis, perivascular lymphocytic infiltration and scattered necrosis of the epidermis (Figure 2). These findings were compatible with the diagnosis of NME.

Immunohistochemistry on skin lesions for Ki 67 showed high rate in the basal layer of epithelium (Figure 3). Direct immunofluorescence study and anti-desmoglein 1 and, 3

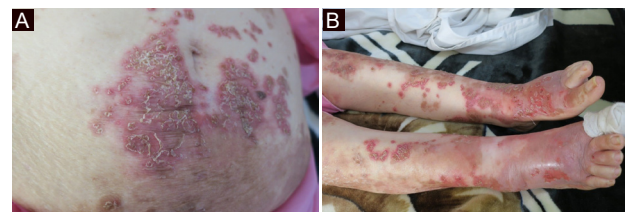


Figure 1. (A) Necrolytic migratory erythema with typical scaling erythema and hyperpigmentation. (B) Erosive scaling and crusted patches on the extremities.

Received 18 September 2017, Accepted 16 March 2018, Available online 28 March 2018

¹Department of Dermatology, Tabriz University of Medical Sciences, Iran. ²Department of Radiology, Urmia University of Medical Sciences, Urmia, Iran.

*Corresponding Author: Ghazaleh Davarnia, Tel/Fax: +98 41335406612, Email: ghd_md@yahoo.com



antibodies were negative.

These results prompted further work-up for a pancreatic islet cell tumor. Abdominal ultrasonography showed multiple hypoechoic liver masses (34, 32, 7, 23 mm) indicated for metastasis.

Abdominal computed tomography (CT) scan reported a well circumscribed eccentric mass in the tail of the pancreas (4 and 3 cm in diameter). Foci of dystrophic calcifications were noted within the mass. Heterogeneous enhancement was also noted in the mass. Numerous hypervascular lesions were in liver that showed washout of contrast media in the portal phase. These findings were compatible with metastatic malignant islet cell tumor (Figure 4).

Hormone analyses showed that glucagon level was elevated (>522 pg/mL- normal level up to 209).

With all of these findings glucagonoma syndrome was presented to the patient.

The patient refused liver biopsy and treatment. INR and prothrombin time (INR: 6, PT: 36.5) were increased in the course of illness within one year.

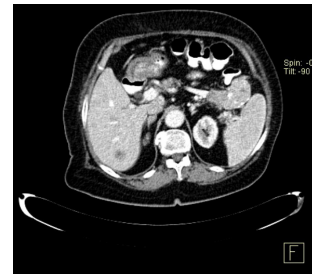


Figure 4. A well circumscribed eccentric mass in the tail of pancreas. Foci of dystrophic calcifications were noted within the mass.

Discussion

NME is a cutaneous manifestation generally associated with glucagonoma syndrome. This cutaneous finding is not unique to glucagonoma and can occur in other pathologic settings that may or may not be accompanied by an increased level of serum glucagon (4).

NME is a bullous dermatosis that develops in 2 weeks. Lesions first manifest as itching or painful vesicles and bullae and then develop as scaly patches and plaques with irregular and advancing borders. The appearance of this cutaneous finding has sometimes an eczematous state similar to psoriasis that gradually improves and disappears and new lesions appear over time (1).

Glucagonoma syndrome is accompanied by increased glucagon, glucose intolerance, anemia, weight loss and NME, and is usually developed in the context of glucagon-secreting pancreatic tumor (5).

Multi-detector row CT is an important modality for detection of pancreatic islet tumor. Pancreatic tumors leading to glucagonoma syndrome are usually smaller than 3 cm and CT scan shows enhancement, but non-syndromic pancreatic tumors are larger and mostly cystic and represent necrotic areas (6).

Prognosis of the disease depends on the stage of the disease at the time of diagnosis; therefore, early detection and diagnosis of signs and symptoms of glucagonoma syndrome are important (7).

Adam et al reported a case of NME that had been first diagnosed as psoriasis, but metastatic pancreatic tumor was confirmed (4).

In a case reported conducted by Colombo et al in 2007, NME had manifested about 1 year before the diagnosis of glucagonoma in the context of metastatic pancreatic tumor and it had not responded to corticosteroids and systemic antibiotics (8).

Tolliver et al in 2018 presented a case of pancreatic glucagonoma with 1 year history of skin rash which it improved after treatment by octreotide (9).

In 2004 van Beek et al reported a 16-year-old patient who was carrier of a mutation in MEN1 gene and had hyperglucagonemia in screening. He complained just skin lesions; he had no diabetes mellitus or weight loss. Multiple islet cell tumors were detected in evaluation (10).

In the mentioned cases, NME was associated with islet

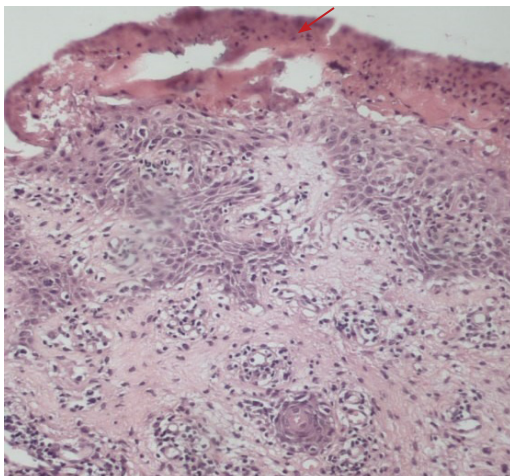


Figure 2. This skin biopsy of trunk shows parakeratosis (red arrow), focal loss of the granular layer, and necrosis of the upper layers of the epidermis, H&E staining (x320).

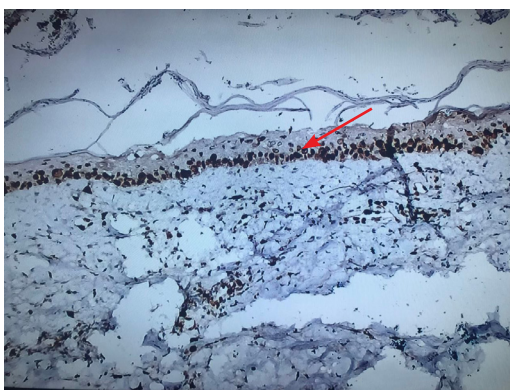

Figure 3. Ki67 staining of skin biopsy shows high proliferation index in basal layer of epithelium (red arrow) (x320).

tumor of the pancreas. In some cases, however, there may not be all criteria for glucagonoma syndrome, as the patient did not show diabetes mellitus throughout the study period.

Conclusion

This case of NME initially misdiagnosed as pemphigus foliaceus who had actually a malignancy of the pancreas. Therefore consideration of this cutaneous eruption is necessary, especially if it is accompanied by weight loss. Early diagnosis may be curative and life-saving.

Conflicts of Interests

Authors declare that they have no conflict of interests.

Ethical Issues

The patient's consent was obtained for publishing this case report.

Financial Support

None.

References

1. John AM, Schwartz RA. Glucagonoma syndrome: a review and update on treatment. *J Eur Acad Dermatol Venereol*. 2016;30(12):2016-2022. doi:10.1111/jdv.13752
2. Teixeira RC, Nico MM, Ghideti AC. Necrolytic migratory erythema associated with glucagonoma: a report of 2 cases. *Clinics (Sao Paulo)*. 2008;63(2):267-270.
3. Stacpoole PW. The glucagonoma syndrome: clinical features, diagnosis, and treatment. *Endocr Rev*. 1981;2(3):347-361. doi:10.1210/edrv-2-3-347
4. Adam DN, Cohen PD, Ghazarian D. Necrolytic migratory erythema: case report and clinical review. *J Cutan Med Surg*. 2003;7(4):333-338. doi:10.1007/s10227-002-0127-0
5. Afsharfard A, Atqiaee K, Lotfollahzadeh S, Alborzi M, Derakhshanfar A. Necrolytic migratory erythema as the first manifestation of glucagonoma. *Case Rep Surg*. 2012;2012 Article ID 974210:1-2. doi:10.1155/2012/974210
6. Horton KM, Hruban RH, Yeo C, Fishman EK. Multi-detector row CT of pancreatic islet cell tumors. *Radiographics*. 2006;26(2):453-464. doi:10.1148/rg.262055056
7. Edney JA, Hofmann S, Thompson JS, Kessinger A. Glucagonoma syndrome is an underdiagnosed clinical entity. *Am J Surg*. 1990;160(6):625-628; discussion 628-629.
8. Colombo E, Zuccoli R, Ugolini M, Dardano F, Leigheb G. Pancreatic glucagonoma presenting as necrolytic migratory erythema. *J Clin Oncol*. 2007;25(15):2135-2136. doi:10.1200/jco.2007.10.7409
9. Tolliver S, Graham J, Kaffenberger BH. A review of cutaneous manifestations within glucagonoma syndrome: necrolytic migratory erythema. *Int J Dermatol*. 2018. doi:10.1111/ijd.13947
10. van Beek AP, de Haas ER, van Vloten WA, Lips CJ, Roijers JF, Canninga-van Dijk MR. The glucagonoma syndrome and necrolytic migratory erythema: a clinical review. *Eur J Endocrinol*. 2004;151(5):531-537.

Copyright © 2018 The Author(s); This is an open-access article distributed under the terms of the Creative Commons Attribution License (<http://creativecommons.org/licenses/by/4.0>), which permits unrestricted use, distribution, and reproduction in any medium, provided the original work is properly cited.