



# A Rare Case Report of Idiopathic Primary Hypoparathyroidism Coexisting With Shortening of Third to Fifth Metacarpal Bones

Ali Saadati Shamir<sup>1</sup>, Mohammad Amin Dolatkhan<sup>2</sup>, Majid Shokoohi<sup>2</sup>, Hossein Kalarestaghi<sup>2,3</sup>, Ali Delshad Noghabi<sup>4</sup>, Arash Hasirbaf Momtaz<sup>5</sup>, Nazila Asgharan<sup>6</sup>, Hamed Shoorei<sup>2\*</sup>

## Abstract

A 20-year-old Iranian male after injury in a football match with pain in the finger was referred to the hospital. X-Ray images of his hand showed no fractures, but the shortening of third to fifth metacarpal bones was clearly observed. The short metacarpal bone is a very helpful diagnostic marker in the patients suffering from idiopathic hypoparathyroidism (IHP), pseudohypoparathyroidism type Ia (PHP-Ia) with Albright's hereditary osteodystrophy (AHO) phenotype, pseudopseudohypoparathyroidism (PPHP), and brachydactyly type E. Briefly, in hypoparathyroidism disease, the serum calcium level decreases and the serum phosphorus level increases in blood. PHP-Ia disorder is clinically similar to hypoparathyroidism; in this disease, the level of parathyroid hormone is normal but there is resistance to it. PPHP disease is not an endocrine disorder but is related to PHP-Ia. In this disease, serum levels of calcium and phosphorus are normal, also symptoms and signs in PPHP are similar to PHP-Ia, but there is no resistance to parathyroid hormone. In brachydactyly type E, shortening of metacarpal or metatarsal bones is caused by abnormal development of phalanges, metacarpals, or both. His laboratory tests revealed a low serum calcium level, high serum phosphate level, and low serum PTH level; therefore a diagnosis of IHP was reached.

**Keywords:** Albright's hereditary osteodystrophy, Pseudohypoparathyroidism, Pseudopseudohypoparathyroidism, Idiopathic primary hypoparathyroidism, Brachydactyly type E

## Introduction

The hand with complex and intricate anatomy is absolutely essential for doing quotidian things in our lives. Anatomically, it is distal to the forearm whose skeletal framework includes 5 metacarpal bones and 14 phalanges. Each metacarpal bone is characterized as having several parts; base, shaft, neck, and head. The first metacarpal bone is considered as the shortest and most mobile relative to the others; the second metacarpal bone has the longest shaft and largest base; the third metacarpal is a little smaller than the second; the fourth metacarpal is shorter and thinner than the second and third; also, the fifth metacarpal is the most medial and second shortest of the metacarpal bones (1). Several endocrine diseases can have adverse effects on the structure of body bones (2). In patients, shortening of fourth and/or fifth metacarpal bone is one of the most important diagnostic clues for pseudohypoparathyroidism type Ia (PHP-Ia) with Albright's hereditary osteodystrophy (AHO) phenotype if

laboratory test results show hypocalcemia and increased parathyroid hormone (PTH) (3-5). Additionally, shortening of metacarpal bone can be observed in the patients suffering from pseudopseudohypoparathyroidism (PPHP), idiopathic primary hypoparathyroidism, and brachydactyly type E (6). In 2 types of mentioned disorders, PHP-Ia and IHP, the serum level of calcium decreases and the serum level of phosphorus increases while in the patients with PPHP, serum calcium and phosphorus levels are normal. In 1942 and 1952, Fuller Albright reported the patients with PHP and PPHP, respectively (7,8). Nowadays, the term "Albright's hereditary osteodystrophy (AHO)" encompasses both concepts of PHP-Ia and PPHP disorders. Furthermore, AHO patients have several diagnostic clinical signs such as mental retardation, round face, obesity, somatic anomalies, short neck, short stature as well as short metacarpal bones (4,7,8). In the present case study, we report a rare case of idiopathic primary hypoparathyroidism who had shortening of

Received 6 January 2017, Accepted 16 July 2017, Available online 3 August 2017

<sup>1</sup>Department of Radiology, Faculty of Paramedical, Birjand University of Medical Sciences, Birjand, Iran. <sup>2</sup>Department of Anatomical Sciences, Faculty of Medicine, Tabriz University of Medical Sciences, Tabriz, Iran. <sup>3</sup>Department of Anatomy and Pathology, Faculty of Medicine, Ardabil University of Medical Sciences, Ardabil, Iran. <sup>4</sup>Department of Nursing, Faculty of Nursing and Midwifery, Gonabad University of Medical Sciences, Gonabad, Iran. <sup>5</sup>Department of Anatomy, Faculty of Medicine, Tarbiat Modares University, Tehran, Iran. <sup>6</sup>Faculty of Dentistry, Tabriz University of Medical Sciences, Tabriz, Iran.

\*Corresponding Author: Hamed Shoorei, Tel: +98-41-33342086, Mobile: +989357551569, Email: h.shoorei@gmail.com



the third to fifth metacarpal bones. Then, diagnosis of an idiopathic hypoparathyroidism (IHP) from other hypoparathyroidism disorders was discussed.

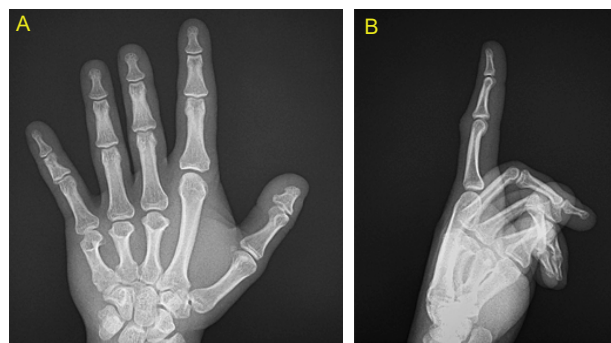
### Case Presentation

A 20-year-old Iranian male patient after right-hand injury in a football match was admitted to Imam Reza hospital, Tabriz, Iran. His main complaint was a severe pain in the right index finger. He claimed that he had no previous history of trauma. In order to make an accurate diagnosis, he was sent to the radiology department and laboratory. In radiographs from his right-hand (Figure 1A and B), no fractures were observed, but abnormalities in his hand with shortening of the third to fifth metacarpal bones associated with flattened metacarpal heads were revealed. In physical examination of his neck, normal bilateral submandibular parotid glands were revealed and also no local signs of inflammation were observed. There were no ectopic calcifications on his chest radiograph. Other changes such as joint space narrowing, osteopenia, and erosions were not observed in the right-hand radiograph. Chvostek's and Trousseau's signs were negative. His face was normal but showed short body stature and central obesity. His height, weight, and body mass index (BMI) were 164 cm, 76.3 kg, 28.36 kg/m<sup>2</sup>, respectively. His vital signs were normal; blood pressure: 130/90 mm Hg, temperature: 37°C, pulse rate: 76/min, and respiratory rate: 17/min. His laboratory tests showed the following results: hemoglobin (Hb) 11.9 g/dL (normal range for men, 13.5 to 17.5 g/dL), platelet count (Plt) 291000/μL (normal range, 150000 to 450000 Plt/μL), white blood cell count (WBC) 6400/μL (normal range, 4500 to 11000/μL), mean cell volume (MCV) 84 (fl), blood urea nitrogen 17 mg/dL (normal range, 7 to 20 mg/dL), creatinine 1.1 mg/dL (normal range for men, 0.6 to 1.2 mg/dL), blood sugar 104 mg/dL (normal range, 72 to 108 mg/dL), calcium 4.7 mg/dL (normal range, 8.5 to 10.2 mg/dL), serum phosphorus 5.9 mg/dL (normal range, 2.5 to 4.5 mg/dL), serum magnesium 2.1 mg/dL (normal range, 1.8 to 2.2 mg/dL), serum alkaline phosphatase (ALP) 101 IU/L (normal range, 44 to 147 IU/L), sodium 141 mEq/L (normal range, 135 to 145 mEq/L), serum albumin 4.2 g/dL (normal range, 3.5 to 5.5 g/dL), intact parathyroid hormone (PTH) 8.7 pg/mL (normal range, 10 to 65 pg/mL), erythrocyte sedimentation rate (ESR) 15 mm/h (normal range for men, 0 to 22 mm/h), serum angiotensin-converting enzyme (ACE) level 29 μg/L (normal range, 8 to 53 μg/L), and rheumatoid factor (RF) was negative. Urine analysis and thyroid function tests were also normal.

### Discussion

In humans, anatomical variations occur all the time and may be associated with other problems (9, 10).

Hypoparathyroidism is considered as a rare endocrine disorder due to deficiency or absence of parathyroid hormone. It is most often acquired from head and neck



**Figure 1.** (A) PA and (B) Lateral Right-Hand Radiograph Showing Shortening of Third to Fifth Metacarpal Bones.

surgery while it can also be idiopathic, genetic, congenital, and/or be associated with autoimmune problems (9).

In this disease, serum calcium levels decrease (hypocalcemia) and serum phosphorus levels increase (hyperphosphatemia). In the patients with hypoparathyroidism disease, many different health problems such as muscle spasms, tingling, heart problems, brittle nails, and seizures may occur (9). Hypoparathyroidism may also occur with unknown etiology called IHP. IHP is one of the rare abnormalities of endocrine disorders with the prevalence of 37 per 100000 (9). It can be revealed in a clinical trial and radiographic images. The x-ray images of his right-hand showed shortening of the third to fifth metacarpal bones. The short metacarpal bone is considered as a helpful diagnostic marker in the patients with pseudohypoparathyroidism (PHP-Ia), PPHP, IHP, and/or brachydactyly type E. PHP-Ia is an inherited disorder that clinically resembles hypoparathyroidism (hypocalcemia and hyperphosphatemia). In this disease, there is a normal or even elevated level of parathyroid hormone in blood, while involved target organs, namely kidneys and bones, cannot respond to PTH normally (5). PPHP not only is a mild form of PHP but despite its name, it is not an endocrine disorder. Therefore, in the patients with PPTH, skeletal abnormalities caused by pseudohypoparathyroidism are present but the levels of calcium and phosphorus are normal in the blood (10). Moreover, in 1951, the first classification for brachydactyly was presented by Bell (11). According to this classification, there is 5 types of brachydactyly. In type A, there is shortening of the middle phalanges of digits; in type B, there are more signs such as big toes, shortness or absence of the mid and distal phalanges of digits, and a deformity in the thumbs; in type C, ulnar deviation in the second finger, hypersegmentation in the proximal phalanges, and shortness in the proximal and middle phalanges of the second and third fingers can be observed; in type D, shortening and/or widening in the distal phalanx of the first digit of the hand or foot is recognizable; but, in type E, shortening is relative to the one or more metacarpal or metatarsal bones. On the other hand, brachydactyly

may also be seen together with syndactyly, polydactyly, and symphalangism. Additionally, brachydactyly type E is firmly associated with pseudohypoparathyroidism (12). However, in our patient, shortening of third to fifth metacarpal bones was clearly observed. On the other hand, the results of laboratory tests showed hypocalcemia, hyperphosphatemia, and low serum PTH levels. IPH patients have similar biochemical findings with PHP-Ia patients such as hypocalcemia and hyperphosphatemia, while IPH patients have PTH deficiency that is very useful to make a definite diagnosis (4,6). Based on the report of other cases, we figured out that metacarpal shortening is specifically not a sign of pseudohypoparathyroidism. Thus, in the absence of biochemical test results, a correct diagnosis between PHP-Ia (AHO phenotypic) and IPH is not possible. Therefore, in the present case based on laboratory analysis, the diagnosis of IHP was reached.

### Conclusions

Metacarpal signs can be a clinical marker of PHP-Ia, PPHP, and/or IPH. Thus, serum biochemical markers play an important role in making a correct diagnosis from mentioned endocrine diseases.

### Conflict of Interests

None.

### Ethical Issues

A written informed consent was obtained from the patient before conducting all the procedures.

### Financial Support

No grant was obtained for this research.

### Acknowledgments

We would like to thank Center of Radiology, Imam Reza hospital and Mr. Ali Saadati Shamir for taking the radiographs.

### References

1. Standring S. Gray's anatomy: the anatomical basis of clinical practice. Elsevier Health Sciences; 2015.
2. Mailhot G, Petit JL, Dion N, Deschenes C, Ste-Marie LG, Gascon-Barre M. Endocrine and bone consequences of cyclic nutritional changes in the calcium, phosphate and vitamin D status in the rat: an in vivo depletion-repletion-repletion study. *Bone*. 2007;41(3):422-436. doi:10.1016/j.bone.2007.04.199
3. Goswami M, Verma M, Singh A, Grewal H, Kumar G. Albright hereditary osteodystrophy: a rare case report. *J Indian Soc Pedod Prev Dent*. 2009;27(3):184-188. doi:10.4103/0970-4388.57101
4. Isozaki O, Sato K, Tsushima T, Shizume K, Takamatsu J. A patient of short stature with idiopathic hypoparathyroidism round face and metacarpal signs. *Endocrinol Jpn*. 1984;31(3):363-367.
5. Mantovani G. Clinical review: Pseudohypoparathyroidism: diagnosis and treatment. *J Clin Endocrinol Metab*. 2011;96(10):3020-3030. doi:10.1210/jc.2011-1048
6. Valizadeh N, Mehdizadeh A, Nazarbaghi S. Short fourth and fifth metacarpals in a case of idiopathic primary hypoparathyroidism. *Indian J Endocrinol Metab*. 2013;17(5):924-926. doi:10.4103/2230-8210.117221
7. Albright F, Reifstein EC. *The Parathyroid Glands and Metabolic Bone Disease*. London: Bailliere, Tindall and Cox; 1948.
8. Albright F, Forbes AP, Henneman PH. Pseudo-pseudohypoparathyroidism. *Trans Assoc Am Physicians*. 1952;65:337-350.
9. Powers J, Joy K, Ruscio A, Lagast H. Prevalence and incidence of hypoparathyroidism in the United States using a large claims database. *J Bone Miner Res*. 2013;28(12):2570-2576. doi:10.1002/jbmr.2004
10. Hanno HA, Weiss DI. Hypoparathyroidism, pseudohypoparathyroidism, and pseudo-pseudohypoparathyroidism. *Arch Ophthalmol*. 1961;65:238-242.
11. Bell J. *The Treasury of Human Inheritance: On Hereditary Digital Anomalies. On Brachydactyly and Symphalangism*. Penrose LS. Cambridge University Press; 1951.
12. Tulay Koca T, Ciledag Ozdemir F. Concomitance of types D and E brachydactyly: a case report. *Eur Rev Med Pharmacol Sci*. 2015;19(23):4549-4552

**Copyright** © 2018 The Author(s); This is an open-access article distributed under the terms of the Creative Commons Attribution License (<http://creativecommons.org/licenses/by/4.0>), which permits unrestricted use, distribution, and reproduction in any medium, provided the original work is properly cited.