



Comparing Pars Plana Vitrectomy and Observation for Vitreomacular Traction Syndrome

Mohammad Hossein Ahoor¹, Leila Alizadeh Ghavidel¹ , Araz Mohammadzadeh^{1*}

Abstract

Objectives: This study aimed to estimate the natural course of vitreomacular traction (VMT) disorder during a 6-month follow-up using the high-resolution spectral-domain optical coherence tomography (SD-OCT). In addition, it attempted to evaluate the visual and anatomical outcomes of the patients who underwent a follow-up or vitrectomy for VMT syndrome.

Materials and Methods: In this prospective study, 45 eyes from 45 patients with VMT syndrome underwent SD-OCT imaging and eye examinations. All the patients were observed for the 6 subsequent months. Further, those patients who demonstrated no spontaneous resolution of adhesion during this period underwent 3 port standard pars plana vitrectomy. Two patients were excluded from the study, then all the remaining patients were observed for 12 months. The mean observation period of all the patients was 18 months. Changes in visual acuity (VA) before and after the study were compared between the 2 groups.

Results: The mean age of patients was 64.21 ± 7.712 years (51-80 years). After 6 months follow-up, 20 patients (44.45 %) represented the spontaneous release of VTM. Furthermore, mean LogMAR VA improved from 0.7042 ± 0.21 (Snellen's equivalent of 20/100) to 0.585 ± 78 (Snellen's equivalent of 20/76). Baseline VA was greater than or equal to LogMAR VA of 0.7 (Snellen's equivalent of 20/100) in most of the patients who revealed a spontaneous resolution of VMT after a six-month follow-up. Moreover, all the patients with spontaneous release of VMT, indicated improvement in VA compared to the baseline, from mean baseline LogMAR VA of 0.5650 (Snellen's equivalent of 20/73) to 0.4700 (Snellen's 20/59). Finally, the mean baseline LogMAR VA improved from 0.8435 (Snellen's equivalent 20/138) to 0.7000 (Snellen's equivalent 20/100) in vitrectomy group.

Conclusions: Approximately 44.5% of the patients demonstrated the spontaneous resolution of vitreoretinal adhesion during the 6-month follow-up. The greater was the initial VA, the higher became the spontaneous separation rate, and eventually a better visual outcome.

Keywords: Vitreomacular traction Syndrome, Pars plana vitrectomy, Observation, Spontaneous separation

Introduction

Vitreomacular traction (VMT) syndrome is an idiopathic abnormality of the vitreoretinal interface in which persistent adhesions exist between the vitreous and the retina in the setting of a partial posterior vitreous detachment (PVD). As the vitreous liquefies due to age, vitreous detaches from the macula in normal eyes. However, in some people, it continues to pull on areas of the macula as the vitreous detaches peripherally, which may cause cystoid changes in the neurosensory retina (1,2).

Additionally, vitreoretinal adhesions transmit tractional forces to the retina from the vitreous body. In addition, the traction itself may induce various changes in macula such as macular surface wrinkling, tractional cystoid macular edema, chronic cystoid macular changes, retinoschisis, foveal cavitation, tractional macular detachment, and

macular holes (1-5).

VMT is characterized by some clinical symptoms such as metamorphopsia, photopsia, micropsia, and decreased visual acuity (VA) (1,2). Diagnosis of VMT may be challenging by biomicroscopy, especially when the area of vitreoretinal attachment is wide. Recently, optical coherence tomography (OCT) has become the most useful decisive tool in diagnosing and determining the extent of VMT and thus directing the treatment towards it (2, 3). Based on the results of several studies regarding the OCT examination, the prevalence of VMT was $(2.3 \pm 0.2\%)$ per eye or $(2.4 \pm 0.3\%)$ per subject. Further, it was higher in older population compared to the young, associated with age, and was significantly more common in postmenopausal women (2,6,7).

Recently, the international vitreomacular traction study (IVTS) group convened to support an OCT-based



anatomic classification system for diseases. In the newest classification system, VMT definition contained three aspects including the evidence of PVD from the retinal surface, macular attachment of the vitreous cortex within a 3 mm radius of the fovea, and association of attachment with distortion of the foveal surface, intraretinal structural changes, and/or elevation of the fovea above the retinal pigment epithelium, but no full-thickness interruption of all retinal layers. Furthermore, VMT can be sub-classified by the diameter of vitreous attachment to the macular surface as measured by the OCT. In addition, it is defined as focal or broad with the attachment of 1500 μM or less or more than 1500 μM (2,8).

Eyes with VMT syndrome can be managed by observation, vitrectomy, and recently, by intravitreal expansile gases (SF₆, C₃F₈) injection and nonsurgical treatment of VMT using enzymatic vitreolysis by intravitreal ocriplasmin (Jetrea) injection (9).

In some cases of VMT, spontaneous uneventful complete PVD and separation of the vitreous from the macular surface can occur concurrently leading to subsequent absorption of the intraretinal and subretinal fluid and restoration of normal vision (8,10). Recent studies based on OCT demonstrated that spontaneous separation might be more common than what was previously expected (11,12). Previously, the prevalence of spontaneous PVD was reported as 0%-11% while today, the spontaneous separation rate is reported as high as 47% using the spectral domain OCT (13-17). Odrobina et al observed a high rate of VMT in eyes without ERMs and with less vitreous surface adhesion, therefore they proposed that persistence of ERM on OCT and vitreous surface adhesion might be the prognostic factors for the spontaneous separation of VMT (17). However, in most eyes, VMT persists and vitrectomy may be an effective treatment option for patients with higher vitreous surface adhesion or coexisting ERM and symptomatic VMT (18,19). Moreover, surgical intervention is suggested when the persistence of symptomatic vitreoretinal traction is longer than 3-6 months and causes severe visual disturbance (2,20,21). Vitrectomy is more successful in the resolution of VMT and can lead to cataract formation, retinal tear or detachment, and epiretinal membrane formation. Therefore, the present prospective quasi-experimental study sought to evaluate the visual and structural outcomes of patients who underwent follow-up or vitrectomy for VMT syndrome.

Materials and Methods

A total of 45 patients who were diagnosed with VMT referring to the retinal clinic of Nikookary eye hospital of Tabriz University of Medical Sciences were selected for the purpose of the study. All the patients (45 eyes) underwent ophthalmic examination, namely, best corrected visual acuity (BCVA) and slit lamp biomicroscopy and spectral-domain optical coherence tomography (SD-OCT,

Heidelberg Engineering, Heidelberg, Germany).

The inclusion criterion was the presence of VMT based on the IVTS group definition. Additionally, the exclusion criteria were the presence of any concurrent ocular disease, previous ocular surgery on the studied eye, and previous treatment for VMT and media opacities.

All the patients were followed for 6 months and then were evaluated by measuring the VA and SD-OCT. The spontaneous release of VMT was observed on SD-OCT in 20 patients out of 45 study population. The remaining 25 patients who suffered a loss of VA in 6 months or had VA $\leq 20/200$ underwent standard three-port pars plana vitrectomy (PPV) surgery with induction of PVD. Two patients out of the 25 patients who underwent surgery were excluded from the study because of not participating in the follow-up program. All the patients were re-evaluated after 1 year using the SD-OCT and measuring the VA.

To analyze the obtained data, patients were divided into 2 groups including patients who were followed up and those who were operated later. Then, the first group (the follow-up patients) were compared to those who had standard three port PPV surgery, and the obtained results were analyzed in terms of changes in their VA. The main outcome measures contained BCVA and VMT release on SD-OCT.

Demographic information of the patients in both groups are listed in Table 1. In addition, the comparative demographic characteristics between the 2 groups are provided in Table 2. As shown in Table 2, concerning the participants' age and gender, both groups are almost the same, and there is no statistically significant difference between these 2 groups. Statistical analysis was performed using the Mann-Whitney test in order to compare the mean amounts of BCVA (LogMAR) in both groups. The results were considered statistically significant at $P < 0.05$.

Results

Totally, 45 patients with VMT were examined in the present study out of whom 2 of them were excluded. The mean age of the patients was 64.21 ± 7.712 years, namely, they were within the age range of 51-80 years. Concerning their gender, twenty patients were females while 23 of them were males. The mean duration of follow-up was 18 months. Further, the mean baseline LogMAR VA was 0.7042 ± 0.21 (Snellen's equivalent of 20/100) which was finally improved to 0.585 ± 78 (Snellen's equivalent of 20/76). After 6 months of follow-up, 20 patients (44.45%) demonstrated spontaneous release of VMT based on SD-OCT (Figure 1A and 1B). Average baseline LogMAR VA in this group was 0.5650 ± 0.2412 (Snellen's equivalent of 20/73). However, 25 patients (55.6%) who undergone three port PPV surgery (surgery group) were still experiencing the adhesion. The average baseline LogMAR VA in this group was 0.8435 ± 0.19265 (Snellen's equivalent of 20/139), which is not satisfactory.

Table 1. Demographic Characteristics of the Patients

No.	Age	Gender	BCVA
1	67	M	20/60
2	78	F	20/200
3	56	M	20/100
4	55	M	20/50
5	59	M	20/200
6	70	F	20/100
7	68	F	20/60
8	66	M	20/100
9	69	F	20/200
10	79	M	20/200
11	60	F	20/40
12	59	M	20/100
13	66	F	20/63
14	67	F	20/50
15	75	M	20/100
16	73	M	20/40
17	80	M	20/60
18	65	F	20/200
19	64	M	20/60
20	69	F	20/200
21	55	F	20/60
22	69	M	20/50
23	69	M	20/100
24	50	F	20/200
25	62	M	20/200
26	60	F	20/100
27	58	F	20/200
28	68	M	20/100
29	55	M	20/200
30	58	M	20/30
31	51	F	20/60
32	59	F	20/200
33	67	F	20/40
34	70	M	20/200
35	66	F	20/200
36	69	M	20/200
37	66	F	20/100
38	64	M	20/10000
39	61	M	20/200
40	55	M	20/100
41	64	F	20/60
42	69	M	20/100
43	51	F	20/100
44	49	M	20/100
45	70	F	20/200

Abbreviation: BCVA, best-corrected visual acuity.

	PPV	Follow up	P Value
Gender, No. (%)			0.43
Female	12 (52.2)	8 (40.0)	
Male	11 (47.8)	12 (60.0)	
Mean age	63.1739	65.2500	0.52

Abbreviation: PPV, Pars plana vitrectomy.

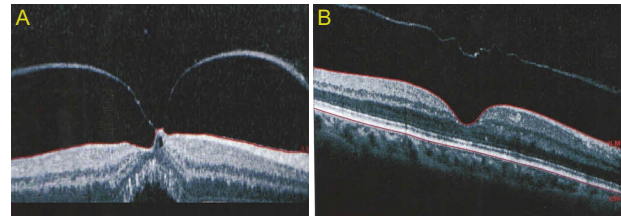


Figure 1. (A) The eye image of patient No.11 suffering from VMT. (B) The OCT image, which illustrates the spontaneous separation of VMT and the resolution of retinal changes for the following four months.

Baseline VA was greater than or equal to LogMAR VA 0.7 (Snellen's equivalent of 20/100) in most patients (85%) who represented a spontaneous resolution of VMT after a 6-month follow-up and only 3 patients (15%) had a LogMAR VA of less than 0.7 (Snellen's equivalent of 20/100). No surgery was performed on these patients despite the low baseline VA which was related to the spontaneous resolution. A number of 18 patients (78%) out of those patients who underwent surgery, had suffered a loss of VA during the first 6 months of follow-up. Furthermore, preoperative VA was less than 20/100 for all the patients who underwent vitrectomy except for 2 after this period. Moreover, thirteen patients (57%) suffered from the initial VA of less than 20/100 while 7 patients (30%) had the VA acuity between 20/66-20/100. Finally, the remaining patients had VA of greater than 20/66.

At the end of the study, all the patients with spontaneous release of VMT who were followed, demonstrated improvement in VA compared to the baseline, that is, their VA modified from mean baseline LogMAR VA of 0.5650 (Snellen's equivalent of 20/73) to 0.4700 (Snellen's equivalent of 20/59). Additionally, in vitrectomy group, the mean baseline LogMAR VA improved from 0.8435 (Snellen's equivalent 20/138) to 0.7000 (Snellen's equivalent 20/100) at the end of the study. The VA of 11 patients (48%) out of a total of 23 cases improved by ≥ 2 lines while in 9 of the patients (39%) no changes were observed in this regard and the remaining 3 patients (13%) represented deterioration in VA compared to the baseline. However, all the patients in the follow-up group finally demonstrated an improvement in VA compared to the baseline. Eventually, spontaneous or surgical release of VMT was observed in all the patients. The baseline and final VA in the follow-up group were significantly greater than those of the vitrectomy group ($P < 0.001$ & < 0.001 , respectively). In other words, the final VA improved in both groups compared to the baseline VA (Table 3). However, the final changes in VA of the follow-up group were significantly better than those of the surgical group compared to the baseline ($P = 0.02$). The obtained data in this regard are presented in Table 4.

Sixteen patients had LogMAR VA ≤ 1.0 (Snellen's equivalent of $\leq 20/200$). Among these 16 patients, the spontaneous release occurred in 3 cases (18%) while

Table 3. Comparison of the Baseline and Final Best Corrected Visual Acuity Between Both Groups

	PPV/Follow up	N	Mean	Standard Deviation	Standard Error Mean	P Value
BCVA	PPV	23	0.8435	0.19265	0.04017	< 0.001
	Follow up	20	0.5650	0.24121	0.05394	
Final BCVA	PPV	23	0.7000	0.26285	0.05481	< 0.001
	Follow up	20	0.4700	1.30317	0.29140	

Abbreviations: BCVA, best-corrected visual acuity; PPV, Pars plana vitrectomy.

Table 4. Final Visual Acuity Change Compared to the Baseline in Both Groups

Change in BCVA	N.	Mean	Standard Deviation	Standard Error Mean	P Value
PPV	23	0.1435	0.26428	0.05511	0.02
FU	20	0.0950	1.28932	0.28830	

Abbreviations: BCVA, best-corrected visual acuity; PPV, Pars plana vitrectomy.

vitrectomy was performed on the remaining 13 patients (82%). Based on the results, mean BCVA improved by 3.5 lines in spontaneous release of VMA while it enhanced only by 0.6 lines in the vitrectomized eyes. Over the follow-up period, unfavorable anatomical outcomes occurred in 4 (9.3%) eyes. The cataract developed in 3 eyes and 1 case after PPV and ERM, respectively.

Discussion

At present, reviewing the details of the vitreomacular interface is easily possible with the advent of high-resolution OCT. However, the diagnosis of this disease was really difficult before the availability of high-resolution OCT. In addition, in previous studies, spontaneous release of VMT was reported considerably less than that of the recent studies.

At the current study, by utilizing the SD-OCT, approximately 44.5% of the patients demonstrated the spontaneous resolution of vitreoretinal adhesion during the 6-month follow-up. This is similar to the result of Odrobina et al who claimed that the rate of spontaneous separation was 47% at a mean follow-up time of 8 months (17). However, Hikichi et al retrospectively studied 53 consecutive eyes with symptomatic VMT without using high-resolution OCT (4) and reported the separation rate as 11% with a resolution of symptoms after a 15-month follow-up, which was considerably lower than that of the current study. Further, Tzu et al pinpointed a spontaneous resolution of VMT 32% with regard to 230 eyes, at a mean time of 18 months follow-up (22).

In the present study, the baseline LogMAR VA was greater than 1.0 (> 20/200) in patients with spontaneous release of VMT (85%) or initial LogMAR VA and only 62% of the patients represented the spontaneous resolution of VMT. Furthermore, Koerner and Garweg observed a series of 50 patients and found that postoperative VA of 20/50 or better was achieved only in 66% of the eyes with preoperative LogMAR VA of better than 0.7 (>20/100) (23).

As regards the patients of the current study, 13 of them (57%) who underwent vitrectomy had the initial LogMAR VA of equal to/ less than 1.0 due to the continued adhesion after the six-month follow-up ($\leq 20/200$). Moreover, 82% of patients with LogMAR VA of less than/equal to 1.0 ($\leq 20/200$) continued the adherence and therefore underwent vitrectomy surgery. Based on the data, vitrectomy is regarded as a proper choice for patients with LogMAR VA less than/equal to 1.0 ($\leq 20/200$) due to VMT.

Finally, improvement in VA was observed in 72% of the patients compared to the baseline, which was 100% for those patients who had spontaneous release while it was only 48% for the vitrectomy group. Additionally, it was nearly 100% in vitrectomy group compared to the preoperative period. This is in line with the findings of Yamada and Kishi who described the improvement of ≥ 2 lines in VA after the surgery in 63% of the eyes ($n = 14$) with VMT syndrome (24). In a similar study, Smiddy et al investigated 16 eyes with VMT undergoing PPV to release of vitreoretinal traction on the macula out of which 10 eyes (63%) had improvement of at least 2 lines (25).

In every human attempt, no doubt, there exist some limitations and strengths which need to be acknowledged. With a limited number of study cases, the results may not be generalized. As a result, similar studies focusing on larger sample sizes are subject to further investigation. However, selecting a prospective type of study and the proper time of follow-up was considered the main advantages of this study compared to other similar studies.

Conclusions

Generally, the rate of spontaneous resolution with the availability of SD-OCT was found to be higher than before (i.e., 40-50% vs. 10-11%). In addition, initial VA can be used as a prognostic factor for disease progression. In other words, the lower initial VA is less likely to be separated spontaneously. Further, it is better for patients with VA of less than 20/100 to be the candidate for surgery. Other patients are recommended to be followed up for 3-6

months and if the adhesion is continued, then they should undergo the surgery.

Conflict of Interests

Authors have no conflict of interests.

Financial Support

None.

References

1. Steinle NC, Dhoot DS, Quezada Ruiz C, et al. Treatment of vitreomacular traction with intravitreal perfluoropropane (C3F8) injection. *Retina*. 2017;37(4):643-650. doi:10.1097/iae.0000000000001237
2. Shao L, Wei W. Vitreomacular traction syndrome. *Chin Med J (Engl)*. 2014;127(8):1566-1571.
3. Shechtman DL, Dunbar MT. The expanding spectrum of vitreomacular traction. *Optometry*. 2009;80(12):681-687. doi:10.1016/j.optm.2009.07.014
4. Hikichi T, Yoshida A, Trempe CL. Course of vitreomacular traction syndrome. *Am J Ophthalmol*. 1995;119(1):55-61.
5. Huang HW, Yeh PT, Huang JS, Yang CM, Yang CH, Ho TC. Long-term study of vitreomacular traction syndrome: Optical coherence tomographic patterns and surgical results. *Taiwan J Ophthalmol*. 2013;3(1):26-30. doi:10.1016/j.tjo.2012.12.004
6. Almeida DR, Chin EK, Rahim K, Folk JC, Russell SR. Factors associated with spontaneous release of vitreomacular traction. *Retina*. 2015;35(3):492-497. doi:10.1097/iae.0000000000000346
7. Shao L, Xu L, You QS, et al. Prevalence and associations of incomplete posterior vitreous detachment in adult Chinese: the Beijing Eye Study. *PLoS One*. 2013;8(3):e58498. doi:10.1371/journal.pone.0058498
8. Duker JS, Kaiser PK, Binder S, et al. The International Vitreomacular Traction Study Group classification of vitreomacular adhesion, traction, and macular hole. *Ophthalmology*. 2013;120(12):2611-2619. doi:10.1016/j.ophtha.2013.07.042
9. Kim BT, Schwartz SG, Smiddy WE, et al. Initial outcomes following intravitreal ocriplasmin for treatment of symptomatic vitreomacular adhesion. *Ophthalmic Surg Lasers Imaging Retina*. 2013;44(4):334-343. doi:10.3928/23258160-20130715-05
10. Chuo JY, Lee TY, Hollands H, et al. Risk factors for posterior vitreous detachment: a case-control study. *Am J Ophthalmol*. 2006;142(6):931-937. doi:10.1016/j.ajo.2006.08.002
11. Selver OB, Parlak M, Soylemezoglu ZO, Saatci AO. Spontaneous resolution of vitreomacular traction: a case series. *Clin Exp Optom*. 2013;96(4):424-427. doi:10.1111/cxo.12019
12. Snead DR, James S, Snead MP. Pathological changes in the vitreoretinal junction 1: epiretinal membrane formation. *Eye (Lond)*. 2008;22(10):1310-1317. doi:10.1038/eye.2008.36
13. Leclaire-Collet A, Muraine M, Siahmed K, Brasseur G. Spontaneous resolution of vitreomacular traction associated with diabetic macular edema. *Eur J Ophthalmol*. 2004;14(5):430-433.
14. Hung KH, Yang CS, Lin TC, Lee FL, Lee SM. Optical coherence tomography in spontaneous resolution of vitreomacular traction syndrome. *J Chin Med Assoc*. 2010;73(6):334-337. doi:10.1016/s1726-4901(10)70072-1
15. John VJ, Flynn HW Jr, Smiddy WE, et al. Clinical course of vitreomacular adhesion managed by initial observation. *Retina*. 2014;34(3):442-446. doi:10.1097/IAE.0b013e3182a15f8b
16. Larsson J. Vitrectomy in vitreomacular traction syndrome evaluated by ocular coherence tomography (OCT) retinal mapping. *Acta Ophthalmol Scand*. 2004;82(6):691-694. doi:10.1111/j.1600-0420.2004.00344.x
17. Odrobina D, Michalewska Z, Michalewski J, Dziegielewski K, Nawrocki J. Long-term evaluation of vitreomacular traction disorder in spectral-domain optical coherence tomography. *Retina*. 2011;31(2):324-331.
18. Sulkes DJ, Ip MS, Baurnal CR, Wu HK, Puliafito CA. Spontaneous resolution of vitreomacular traction documented by optical coherence tomography. *Arch Ophthalmol*. 2000;118(2):286-287.
19. Kusaka S, Saito Y, Okada AA, et al. Optical coherence tomography in spontaneously resolving vitreomacular traction syndrome. *Ophthalmologica*. 2001;215(2):139-141. doi:10.1159/000050847
20. Sonmez K, Capone A Jr, Trese MT, Williams GA. Vitreomacular traction syndrome: impact of anatomical configuration on anatomical and visual outcomes. *Retina*. 2008;28(9):1207-1214. doi:10.1097/IAE.0b013e31817b6b0f
21. Kovacevic D, Markusic V. Pars plana vitrectomy for vitreomacular traction syndrome. *Coll Antropol*. 2013;37 Suppl 1:271-273.
22. Tzu JH, John VJ, Flynn HW Jr, et al. Clinical Course of Vitreomacular Traction Managed Initially by Observation. *Ophthalmic Surg Lasers Imaging Retina*. 2015;46(5):571-576. doi:10.3928/23258160-20150521-09
23. Koerner F, Garweg J. Vitrectomy for macular pucker and vitreomacular traction syndrome. *Doc Ophthalmol*. 1999;97(3-4):449-458.
24. Yamada N, Kishi S. Tomographic features and surgical outcomes of vitreomacular traction syndrome. *Am J Ophthalmol*. 2005;139(1):112-117. doi:10.1016/j.ajo.2004.08.055
25. Smiddy WE, Michels RG, Glaser BM, deBustros S. Vitrectomy for macular traction caused by incomplete vitreous separation. *Arch Ophthalmol*. 1988;106(5):624-628.

Copyright © 2019 The Author(s); This is an open-access article distributed under the terms of the Creative Commons Attribution License (<http://creativecommons.org/licenses/by/4.0>), which permits unrestricted use, distribution, and reproduction in any medium, provided the original work is properly cited.