




# Prolonged Cough and Exercise Dyspnea: Teratoma in Lungs

Majid Montazer<sup>1</sup>, Haleh Farzin<sup>1</sup>, Maryam Hoseini<sup>1\*</sup>, Tala Hoseini<sup>1</sup>

## Abstract

**Objectives:** Teratoma is a rare tumor derived from pluripotent stem cells accounting for 10%-15% of the mediastinal tumors and are the most common subtypes of germ cells which undergo impaired migration during the embryonic developmental period. Teratomas are indemnified by the presence of the tissue from at least two embryonic germ layers and thus, the migration of these pluripotent cells along the lung bud can lead to intrapulmonary mass with or without mediastinal involvement.

**Case Presentation:** In the current report, the case of a 26-year-old woman was presented who was diagnosed with chronic cough from her childhood. The patient had no previous surgery. She mainly complained about cough and sputum production during her childhood period (10-12 years old) which failed to respond to conventional treatment. The 3-year post-operative follow-up indicated no pulmonary symptoms or signs in this patient.

**Conclusions:** In general, the anatomical location of teratoma is associated with several challenges while this tumor demonstrates different symptoms. The histopathological diagnosis of teratoma includes germ cells and other non-germ cells. Therefore, surgical resection is considered the optimal treatment for this tumor since it cannot respond to chemotherapy. Finally, lung teratoma has multifaceted challenges including histopathological diagnosis and therefore, surgery is regarded as the optimal modality of treatment.

**Keywords:** Cough, Exercise dyspnea, Teratoma, Lung

## Introduction

Until 1996, only 30 cases with lung teratomas were reported (1). Teratomas are tumors derived from different types of germ cells and their correct diagnosis indicates that they have a gonadal or an extra-gonadal origin. In addition, rare cases suffering from this tumor were reported since Mohr's description of teratoma in 1839 (2). In fact, teratomas are germ cell tumors which are commonly found in ovarian, testis, sacrum, and retroperitoneum (3).

Further, they are embryonic tumors which typically occur in the paraxial and midline part of the body and affect 75%-80% of the women. Shin et al. reported the predominance of benign teratomas in women (a 1.64:1 ratio). Furthermore, Takeda et al emphasized a female to male involvement ratio of 1.27:1 and 2.05:1 (4). Generally, 80% of teratomas are benign while the remaining 20% are malignant (5). These tumors can occur in young and middle-aged humans (6). The common site out of the abdomen is mediastinum with a diameter of 2.8–10 cm (3). They are considered the second most common mediastinal tumors in the anterior compartment of the mediastinum and can be asymptomatic or manifest by the cough, chest pain, and dyspnea (7). Additionally, the

size of the tumors is proportional to the severity of their symptoms (4).

On chest x-ray, teratomas can exhibit themselves as lobulated upper lung lobe tumors or intraparenchymal opacities. In addition, homogeneous or heterogeneous tumors can be observed in computed tomography of the chest (8). These tumors are treated with systemic therapy, radiation, and surgical debulking (9). Further, combined chemotherapy and surgery is recommended for the treatment of immature mediastinal tumor (10). Metastasis to the regional lymph node, lung, liver, and spleen are taken into account at diagnosis or recurrence (11). Based on the importance of the above-mentioned issue, the present case report sought to discuss the rare manifestation of teratoma undergoing operation.

## Case Report

A 26-year-old non-smoker woman referred to our thoracic surgery department and complained about her long-term childhood (approximately at the age of 12) cough habit. Her cough responded to no previous medical treatment. It was accompanied by small amounts of white sputum without any visible blood streaks. Furthermore, she

Received 11 February 2018, Accepted 23 September 2018, Available online 9 October 2018

<sup>1</sup>Imam reza Hospital, Anesthesiology, Tabriz, Iran.

\*Corresponding Author: Maryam Hosini, Tel: +989143145165, Email: hoseini59maryam@yahoo.com

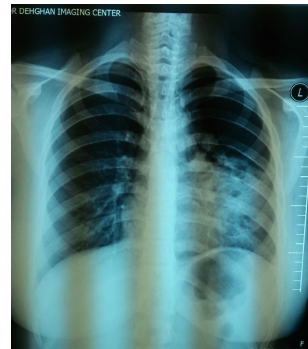


complained about mild dizziness, exercise dyspnea, and low-grade fever. No other symptoms such as hemoptysis, chest pain, or weight loss were observed. Additionally, the patient reported no contact with animals or patients with tuberculosis. On physical examination, she had good general health. Routine laboratory tests including  $\alpha$ -fetoprotein ( $\alpha$ -FP), human chorionic gonadotropin (HCG) were within normal ranges. However, crackles and sound reduction were heard in the left lung based on pulmonary auscultation. Three sputum cultures for Koch bacillus and fungus were negative. In addition, the ultrasound imaging for unknown sources of tumors and other tests were negative.

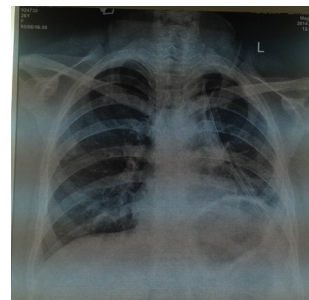
Chest x-ray (Figure 1) indicated opacity in the superior lobe of her left lung. Further, the results of the CT-scan (Figure 2) revealed small lymphadenopathy in perivascular, paratracheal, and the left hilar regions of the lung without any visible effusions. Furthermore, a thick-walled cavity and a large cavity were observed in the lingula and elongated to the anterior mediastinum, respectively. The distal part of the left bronchus was obstructed, therefore, the first diagnosis compatible with the symptoms was pulmonary hydatid cyst. Additionally, the anti-hydatid cyst antibody was checked twice and the results of the examination indicated that anti-hydatid cyst antibody level was normal, thus excluding pulmonary hydatid cyst as a probable diagnosis.

After considering the diagnostic and therapeutic conditions, surgery was recommended. Under general anesthesia, the following surgical procedure was performed on the patient: thoracotomy, en bloc resection of the thymus, left upper lobectomy, and mediastinal lymphadenectomy. In the medial part, lingula was extremely stuck to the pericardium (Figure 3). Then, it was slowly separated; as a result, the upper lobe tumor mass was expanded to the mediastinum. The phrenic nerve was removed in combination with the upper lobe of the left lung and thymus since it was affected as well. In addition, bronchus was cut using the TA45Wn stapler. The lower lobe was completely normal. After the operation, five samples were taken from the mediastinal lymph nodes of 1L, 5, 4L, and 6 and were sent for further pathologic evaluation (Figures 4-6). Next, all the samples were reported to be negative. Remaining intubated, the patient was transferred to the surgical intensive care unit of Imam Reza teaching hospital immediately postoperative period. She was discharged with good general health 4 days after the operation. However, the histopathological examination revealed a well-defined teratoma containing stratified squamous and respiratory epithelium, bone tissue, mature adipose tissue, cartilage, and connective tissues, indicating that teratoma affected her left lung and thereafter, chemotherapy was performed.

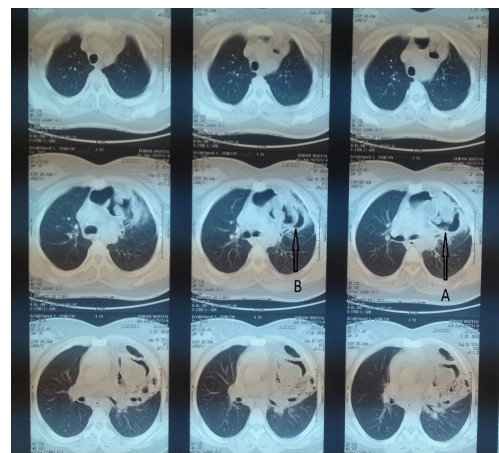
The patient was followed-up after the operation. During the follow-up session, she had abdominal pain two years after the thoracotomy. Further, an ovarian



**Figure 1.** Chest X-ray displaying an opacity in the superior lobe of the left lung before the operation compared to the chest X-ray after the operation.



**Figure 2.** Chest X-ray after en bloc left upper lobe with thymus resection, which shows chest tube and left diaphragm elevation.

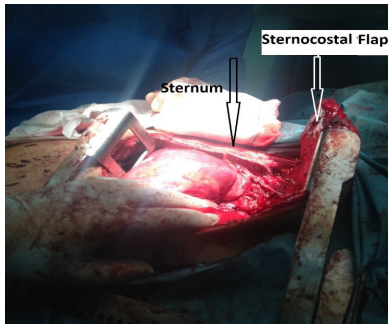


**Figure 3.** Thorax computed-tomography scan depicting a well-defined lesion in the anterior segment of the left upper lobe before the operation. Arrows represent tumor location and borders.

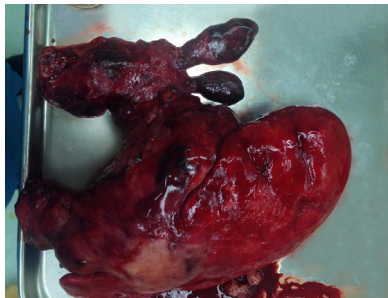
mass was found on physical examination. Subsequently, salpingo-oophorectomy was conducted and then, the ovarian masses were sent for further pathology evaluation. Fortunately, the histopathological diagnosis confirmed mature cystic teratoma without any malignancy.

**Discussion**

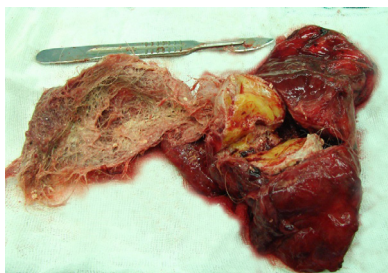
The first case of pulmonary teratoma was reported by Mohr in 1839 (12). Saini et al (12) presented a 38-year-



**Figure 4.** Left medial sternothoracotomy incision (hemi clamshell). Black arrow displays sternal longitudinal division site while white arrow illustrates left 5th intercostal space incision.



**Figure 5.** Gross pathology. Complete resection of the tumor in the upper lobe of left lung with thymus and removal involved left frenic nerve.



**Figure 6.** Post-resectional view of intra pulmonary teratoma depicts hairs and fat and sebaceous inside it.

old man with a 2-year history of intermittent episodes of cough and hemoptysis. He had no history of weight loss and fever. Furthermore, a variety of cell lines were found in pathology, which contained squamous epithelium and sebaceous glands, cartilage, pancreatic tissue, and gastric tissue.

The equal signs of these patients are refractory including intermittent cough, chest pain, dyspnea, and expectoration. Teratomas are observed nearly in the left lung. The microscopic examination of teratomas is almost the same in all patients including the case of the current research report and thoracotomy is recommended for all of these patients.

The patient of the present study had a cough, white color sputum, mild dizziness, exercise dyspnea, and low-grade fever, all of which were the most commonly reported

symptoms. Additionally, in pathology, the microscopic view of the resected surgical sample had squamous and respiratory epithelium, bone tissue, mature adipose tissue, cartilage, and connective tissues all of which emphasized intrapulmonary teratoma. Surprisingly, lung teratoma in the studied women was malignant while the ovarian tumor was benign.

Mediastinal germ cell tumors should be among differential diagnosis of anterior mediastinal masses. Benign teratomas can be observed in this site and thus, complete surgical resection is a way to complete the treatment. Malignant mediastinal seminomas are treated by radiotherapy (mediastinal disease) or chemotherapy (metastatic disease) which is associated with long-term survival rate. The history of success with chemotherapy should prompt thorough pathologic and serologic evaluation of all the patients with mediastinal malignancies hoping to define a curable process. In particular, poorly differentiated carcinomas at this site should be treated as germ cell tumors and therefore, long-term survival is attainable.

Mediastinal nonseminomatous germ cell tumors are manifested as development of non-germ cell malignancies (e.g., embryonal rhabdomyosarcomas) and hematologic malignancies (e.g., acute megakaryocytic leukemia and malignant histiocytosis). It seems that such malignancies are an expression of the multipotential nature of the primitive germ cells (13). Making differential radiologic diagnosis between benign and malignant teratomas is normally difficult, particularly in mature ruptured teratoma. Malignant teratomas manifest by large mass lesions and the presence of metastasis is the marker of malignancy. In malignant teratomas, teratomas are considered lesions with spiculated borders in CT or MR images (e.g., thick capsules, heterogeneous contents, fat plane obliteration around the tumor, or direct invasion into the adjacent structures with or without effusion). These results were occasionally mimicked by the ruptured teratomas. Therefore, a sudden start of the symptoms after rupturing may be evidence of true diagnosis (14).

The patient was found to have a cough which remained uncured and the cough produced small amounts of white sputum without any blood streaks. In addition, she complained about mild dizziness, exercise dyspnea, and low-grade fever. The chest X-ray demonstrated opacity in the superior lobe of her left lung (Figure 1). Further, the results of her CT-scan revealed small lymphadenopathy in pre-vascular, paratracheal, and left hilar regions without any effusions, thick-walled cavity in lingula, and a large cavity elongated to the anterior mediastinum and that the distal part of the left bronchus was obstructed. Accordingly, patients exhibiting these symptoms are recommended to undergo surgery (Figure 2).

### Conclusions

In general, lung teratoma is an extremely rare benign

mass which has multifaceted challenges including histopathological diagnosis, and thus, surgery is considered its optimal treatment modality. Despite the scarcity of lung teratoma, it should be taken into account in the differential diagnosis of lung masses, especially in the presence of cough and prolonged sputum. These tumors have the potential for malignancy and therefore, interventions such as surgery should be immediately performed for these patients.

#### Conflict of Interests

None to be declared.

#### Ethical Issues

Written informed consent was obtained from the patient for the publication of this case report and any connected images.

#### Financial Support

None.

#### Acknowledgments

The authors would like to thank the patient and all the colleagues who helped us in conducting this research.

#### References

1. Ustun MO, Demircan A, Paksoy N, Ozkaynak C, Tuzuner S. A case of intrapulmonary teratoma presenting with hair expectoration. *Thorac Cardiovasc Surg.* 1996;44(5):271-273. doi:10.1055/s-2007-1012035
2. Choi SJ, Lee JS, Song KS, Lim TH. Mediastinal teratoma: CT differentiation of ruptured and unruptured tumors. *AJR Am J Roentgenol.* 1998;171(3):591-594. doi:10.2214/ajr.171.3.9725279
3. Villalobos RE, Benedicto J, Villaruel A, Almenario H. A Giant Intrapulmonary Mature Teratoma Located Entirely Within the Lung: An Extraordinary Case. *Chest J.* 2016;150(4):688A. doi:10.1016/j.chest.2016.08.783
4. Takeda S, Miyoshi S, Ohta M, Minami M, Masaoka A, Matsuda H. Primary germ cell tumors in the mediastinum: a 50-year experience at a single Japanese institution. *Cancer.* 2003;97(2):367-376. doi:10.1002/cncr.11068
5. Azizkhan RG, Caty MG. Teratomas in childhood. *Curr Opin Pediatr.* 1996;8(3):287-292.
6. Asgary MR, Aghajanzadeh M, Hemmati H, Jafari M. Epidemiology of Mediastinal Tumors during Six Years (2006-2012) in Rasht City. *Emergencias.* 2014;2(4):88-94.
7. Duwe BV, Sterman DH, Musani AI. Tumors of the mediastinum. *Chest.* 2005;128(4):2893-2909. doi:10.1378/chest.128.4.2893
8. Rosado-de-Christenson ML, Templeton PA, Moran CA. From the archives of the AFIP. Mediastinal germ cell tumors: radiologic and pathologic correlation. *Radiographics.* 1992;12(5):1013-1030. doi:10.1148/radiographics.12.5.1326777
9. Narayan V, Hwang WT, Lal P, et al. Cyclin-Dependent Kinase 4/6 Inhibition for the Treatment of Unresectable Mature Teratoma: Long-Term Follow-Up of a Phase II Study. *Clin Genitourin Cancer.* 2016;14(6):504-510. doi:10.1016/j.clgc.2016.03.010
10. Arai K, Ohta S, Suzuki M, Suzuki H. Primary immature mediastinal teratoma in adulthood. *Eur J Surg Oncol.* 1997;23(1):64-67. doi:10.1016/S0748-7983(97)80145-X
11. Mustafa OM, Mohammed SF, Aljubran A, Saleh WN. Immature mediastinal teratoma with unusual histopathology: A case report of multi-lineage, somatic-type malignant transformation and a review of the literature. *Medicine (Baltimore).* 2016;95(26):e3378. doi:10.1097/md.0000000000003378
12. Saini ML, Krishnamurthy S, Kumar RV. Intrapulmonary mature teratoma. *Diagn Pathol.* 2006;1:38. doi:10.1186/1746-1596-1-38
13. Oberman HA, Libcke JH. Malignant germinal neoplasms of the mediastinum. *Cancer.* 1964;17:498-507.
14. Sasaka K, Kurihara Y, Nakajima Y, et al. Spontaneous rupture: a complication of benign mature teratomas of the mediastinum. *AJR Am J Roentgenol.* 1998;170(2):323-328. doi:10.2214/ajr.170.2.9456938

**Copyright** © 2019 The Author(s); This is an open-access article distributed under the terms of the Creative Commons Attribution License (<http://creativecommons.org/licenses/by/4.0>), which permits unrestricted use, distribution, and reproduction in any medium, provided the original work is properly cited.