

Cone Beam Computed Tomography Study of Root and Canal Morphology of Maxillary first Molar in an Iranian Population

Farhad Faramarzi¹; Mitra Vossoghi^{1*}; Abbas Shokri²; Bahare Shams³; Maryam Vossoghi⁴; Elham Khoshbin¹

¹Endodontics Department, Faculty of Dentistry, Hamadan University of Medical Sciences, Hamadan, IR Iran

²Radiology Department, Faculty of Dentistry, Hamadan University of Medical Sciences, Hamadan, IR Iran

³Periodontics Department, Faculty of Dentistry, Shahid Beheshti University of Medical Sciences, Tehran, IR Iran

⁴Prosthodontics Department, Kerman University of Medical Sciences, Kerman, IR Iran

*Corresponding author: Mitra Vossoghi, Endodontics Department, Faculty of Dentistry, Hamadan University of Medical Sciences, Hamadan, IR Iran. Tel: +98-8118381086, Fax: +98-8118381085, E-mail: Mit.Vossoghi@gmail.com

Received: October 11, 2014; Revised: December 8, 2014; Accepted: January 9, 2015

Background: The success of endodontic treatment depends on detection of all root canals so that they could be cleaned, shaped and obturated appropriately. To achieve this, it is essential to know root canals complexities such as the number of canals and types of each root canal, which are genetically determined. Besides, the highest failure rates occur in maxillary first molars.

Objectives: Therefore, the aim of this study was to investigate the root and canal morphology of maxillary first molars in an Iranian population using cone-beam computed tomography (CBCT).

Materials and Methods: In this study, images of 156 extracted maxillary first molars placed in the waxed blocks were produced using CBCT. Two professional investigators checked images by NNT software in New Tom 3G system. Axial view and cross section of 1 mm thickness were used. The number of roots, canals, each roots canal, MB₁-MB₂ orifice distances and canal types of the Vertucci classification were recorded. Finally, data was analyzed using SPSS16 software.

Results: We found 100% of cases with three separated roots, from which 69.23% had four canals including MB₂ and 30.77% with three canals. 71.3% of mesiobuccal roots were two canals of type two Vertucci and 28.7% type 4 with the mean distance value of 2.55 ± 0.57 mm between MB₁ and MB₂ orifice.

Conclusions: Most extracted maxillary first molars were three rooted and four canals. CBCT has relatively high reproducibility and accuracy of distinguishing MB₂ canal.

Keywords: Cone Beam Computed Tomography; Molars; Maxillae

1. Background

To recognize variations in root canal anatomy is an essential prerequisite for successful endodontic diagnosis and treatment. The complexities of internal anatomy are often masked by the external surfaces, which relatively have a simple and uniform anatomy (1). Internal complexities include the number of canals in each root, distances of orifices, canals type etc., which are more difficult to detect (2). Internal root canal complexities are genetically determined and have a definite importance in anthropology and thereby necessitating the identification of root canal morphologies of different ethnic populations (1). The highest failure rates occur in maxillary first molars, which is due to anatomy complexities, number of canals, difficulty to find and access the canals orifices, especially the second mesiobuccal (MB₂) (3). The methods used in analyzing root canal morphology are canal staining and tooth clearing, conventional radiographs, digital radiographic techniques, radiographic assessment enhanced by contrast media and more re-

cently computed tomography (CT) technique (2). The distinct advantage of CT over conventional radiography, is that it allows 3D reconstruction of root canal systems with the ability to distinguish details in each canal. Recently CBCT is introduced as an extra oral technique with capability of 3D imaging, which has considerably lower radiation dose than conventional CT (1). Therefore, its benefits are lower exposure time, higher resolution and accuracy (4, 5). Besides, it has been shown to be more accurate than digital radiographs to determine root canal systems with its in vivo usage in diagnosis and preoperative assessments (1). CBCT could be used to show the number of canals, foramina, additional canals (6) and estimating the distance between canals orifice (7). Besides, it has a high accuracy to distinguish MB₂ maxillary canal of first molars (3) and distolingual canal of mandibular molars (5). This study was therefore performed regarding the importance of knowing morphology of each canal in success of endodontic therapy.

There are updated researches in countries such as Poland, China, Thailand and Brazil, but no similar comprehensive study in Iran.

2. Objectives

The aim of this study was to evaluate root and canal morphology of maxillary first molar using CBCT in an Iranian population.

3. Materials and Methods

In this experimental in vitro study, 156 extracted first maxillary molars with complete roots were collected from an Iranian population. Immediately after extraction, the teeth were washed under tap water and stored in normal saline until the collection was completed. Then the samples were washed again under tap water thoroughly, and immersed in 2.5% sodium hypochlorite for five minutes to remove adherent soft tissues (1). The extracted teeth were placed in wax blocks of eight

layers from cementoenamel junction to apex. Then all nine blocks were numbered by metal indicators. For reconstructing soft tissues, each block was placed in a plastic container full of water (8). Then we exposed them by CBCT (New Tom 3G, Verona, Italy) at 110 kvp, 15 mA, 12 seconds. Consequently, two observers (endodontist and radiologist) separately investigated the samples on the flatron LG monitor (screen pixel resolution = 1440900, color depth = 32) from 12 inch distance in a dark room (9). For investigating and evaluating canals, NNT software in New Tom 3G system was used with axial view and cross section of 1 mm thickness. All selected sections should include the floor of pulp chamber and initiated point of canals. Figure 1 represents axial view of samples. Two of our investigators distinguished the number of roots, canals, the number of canals in each root, distance between MB₁ and MB₂ orifices of canals in two canals mesiobuccal roots and the Vertucci classification. Finally, data was analyzed using SPSS software (IBM Corp. Released 2010. IBM SPSS Statistics for Windows, Version 19.0).

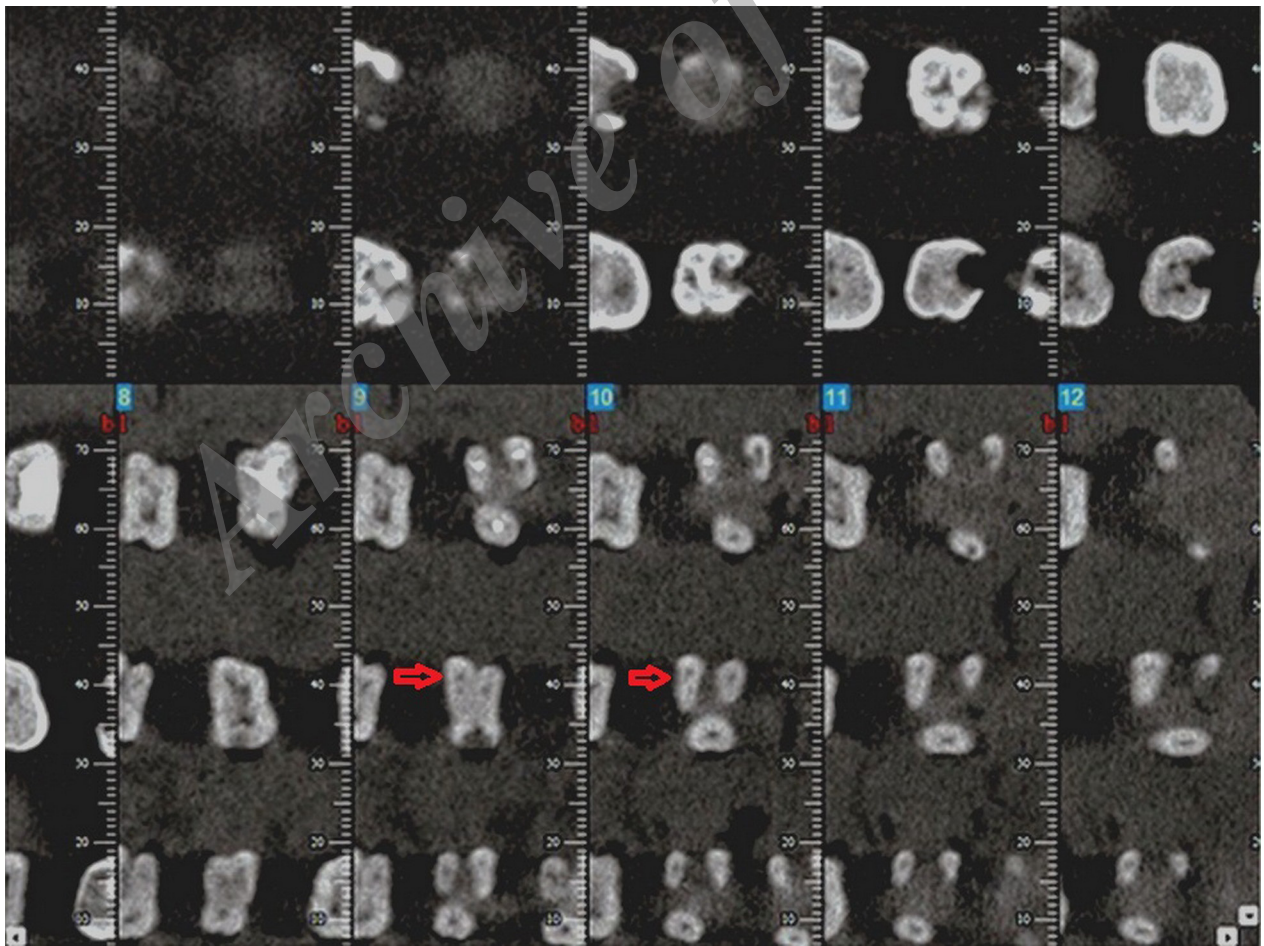


Figure 1. Axial View of Samples

4. Results

Data was analyzed by SPSS16 software and the reliability between the two investigators were calculated by kappa, which was 0.904; kappa greater than 0.75 indicated a high agreement. In our study, 100% of extracted teeth had three separated roots and in all cases, the first mesiobuccal, distobuccal and palatal canals could be seen. In all cases, distobuccal and palatal roots had one canal. According to Table 1, which indicates the frequency of canals number in mesiobuccal root, 108 extracted teeth with two canals were found and the rest of 48 extracted teeth had one canal. According to Table 2, 71.3% of cases with MB₂ canal were type two of the Vertucci classification and 28.7% were type 4. The highest distance between MB₁ and MB₂ orifices was 4 mm and the lowest one was 1.5 mm with the mean value of 2.555 ± 0.567 mm.

Table 1. The Number of Canals in Mesiobuccal Root ^a

Canal Numbers of Mesiobuccal Root	Frequency
One canal (MB ₁)	48 (30.77)
Two canals (MB ₁ + MB ₂)	108 (69.23)
Total	156 (100)

^a Data are presented as No. (%).

Table 2. Types of Canals in Two Mesiobuccal Canals of Maxillary First Molar ^a

Type	Frequency
Type 2	77 (71.3)
Type 4	31 (28.7)
Total	108 (100)

^a Data are presented as No. (%).

5. Discussion

The most therapeutic failures might occur in maxillary molars because of anatomical complexities, multiple canals and occasionally difficulty for finding canals, especially the second mesiobuccal canal. Therefore, it is important to investigate root and canal morphology of maxillary first molar (3). CBCT was used in this investigation to assess 156 extracted maxillary first molars. Our findings showed that 100% of samples had three separated roots and 69.23% of them had four canals including MB₂ and the rest 30.77% had three canals. Overall, 71.3% of samples with MB₂ canal were type two of the Vertucci classification and 28.7% were type 4. The most distance between MB₁ and MB₂ orifices was 1.5 mm with the mean value of 2.555 ± 0.567 mm. A wide range of variety in roots and canals morphology is reported in every tooth such as fused roots, variety in morphology and types of canals. These diverse findings could be due to different methods, conditions of performing research, age, gender and anatomical variety in different races and

populations. Gray (10), Ng (11) and Alavi (12) showed that 100% of maxillary first molars had three roots. However, Al Shalabi reported that 97.6% had three roots and the rest were two-rooted (13), while Thomas showed 94.6% of samples with three roots and 5.6% with two roots (14). Although Al Shalabi (13), Yang (15) and Hou G1 (16) reported that 6.2% of maxillary first molars had two or three fused roots (17), this study showed that 100% of cases had three separated roots. In some case reports such as Weisman (18), Thews (19), Stone (20) and Jacobsen (21) two palatal rooted maxillary first molars were reported, and in Maggiore (22) and Wong (23) studies three palatal rooted were reported. In Barbizam (24) study, two palatal and two mesiobuccal rooted maxillary first molars were reported, while we did not find any additional root in this study. 100% of cases indicated by Pattanshetti (25), Wasti (26) and Alavi (12), had one canal of distobuccal and palatal roots in maxillary first molars. whereas Ng (11) found 96% of distobuccal and 100% of palatal roots with one canal. Thomas (14) reported 95% of distobuccal and palatal roots with one canal. Also in this study, 100% of samples had one canal of distobuccal and palatal roots. Mesiobuccal root of maxillary first molars was evaluated in different studies based on second mesiobuccal canal. Regarding in vivo studies, the highest percentage of MB₂ was 71-77% reported by Wolcott who used head loop and 3.5X magnification (27). Using microscopy surgery, the highest rate of MB₂ canals in in vitro studies performed by de Carvalho and Zuolo was 96% (28). The results of in vitro and in vivo studies had great differences, which indicate the significance of paying more attention to MB₂ canal. Pomeranz and Fishelberg reported the occurrence of the second mesiobuccal in 31% of in vivo and 69% of in vitro studies (29). Different ways of study on the root and canal morphology of teeth include staining and tooth clearing, dental model preparation with clear resin, decalcification, dissecting and sectioning, direct examination or magnification and microscope surgery, loops with fiber optic, conventional radiography and finally 3D imaging with CT and CBCT (30). Different methods might yield different results. For example, for analyzing internal morphology of maxillary first molars, Baratto et al. used three different methods of microscope surgery, conventional radiography and CBCT. The results of microscope, radiography and CBCT regarding the frequency of MB₂ were respectively 67.14%, 53.5% and 59.25% (6). Alacam et al. used direct observation, microscope, combination of microscope and ultrasonic methods and dissecting technique for evaluating MB₂; the results were 62%, 67%, 74% and 82% respectively, which indicates that different methods have different results (31). At present, using microscope surgery is advantageous to distinguish MB₂. Buhrey et al. demonstrated that the frequency of MB₂ with the use of microscope was 71.1% and without microscope was 17.2% (32). In this study, we found that 69.23% of samples had four canals including MB₂ and 30.77% of teeth had three canals,

which were relatively similar to the findings of Park (65.2%) (33), Thomas (68%) (14), Degerness (78.8%) (34), Yoshioka (66.32%) (35), Alavi (67.8%) (12), Al Shalabi (78%) (13) and Ng (68%) (11). However, Zhang (36) and Zheng (37) obtained different results of MB₂ in Chinese population using CBCT. They reported 52% and 50%, respectively, which were lower than the result of this study. Different results could be due to different CBCT systems used to evaluate the samples or different races and populations. Besides, Neelakantan et al. (1) reported MB₂ in 44.1%; they used another type of CBCT system (3D Accuatom, Japan). Rathi et al. (38) evaluated the frequency of MB₂ by CT and reported its percentage as 57%, while Wasti et al. (26) used tooth clearing technique and found the second mesiobuccal frequency in maxillary first molar as 52%. The obtained results of these two studies were lower than this study. It could be due to the use of different methods or races. In the Vertucci classification, 71.3% of two canals mesiobuccal roots were type two and 28.7% were type four, which was similar to the Park (33) and Baratto Filho (6) studies who reported the frequency of type two as 61% and 65.3% and type four as 28.3% and 29.5%, respectively. Pattanshetti (25) reported 79.43% of type two and 20.53% of type three in the Weine classification. In this study, the highest distance between MB₁-MB₂ was 4 mm and the lowest was 1.5 mm and the mean distance between the two orifices was 2.55 mm, which is different from the result of Degerness (34) study, which reported the mean distance value between the two orifices as 1.2 mm in an American population and it could be due to different geographic areas or genetics and races influencing root and canal anatomy.

In this study, most of maxillary first molars were three rooted with four canals. Overall, 69.23% of the second mesiobuccal canals were found with two canals divided into two groups. 71.3% of them were type two and 28.7% were type four of the Vertucci classification. The highest distance between MB₁ and MB₂ orifices was 4 mm and the lowest was 1.5 mm with the mean value of 2.555 mm. CBCT has relatively high reproducibility and accuracy to distinguish MB₂ canal.

Acknowledgements

Endodontic and radiologic department of Hamadan University of Medical Sciences provided general support to accomplish this research, also dentistry school of Hamadan University of Medical Sciences was financial supporter of the study.

Financial Disclosure

Dentistry school of Hamadan University of Medical Sciences.

Funding/Support

Endodontic and Radiologic Departments of Hamadan Dentistry School.

References

1. Neelakantan P, Subbarao C, Ahuja R, Subbarao CV, Gutmann JL. Cone-beam computed tomography study of root and canal morphology of maxillary first and second molars in an Indian population. *J Endod.* 2010;**36**(10):1622-7.
2. Neelakantan P, Subbarao C, Subbarao CV. Comparative evaluation of modified canal staining and clearing technique, cone-beam computed tomography, peripheral quantitative computed tomography, spiral computed tomography, and plain and contrast medium-enhanced digital radiography in studying root canal morphology. *J Endod.* 2010;**36**(9):1547-51.
3. Blattner TC, George N, Lee CC, Kumar V, Yelton CD. Efficacy of cone-beam computed tomography as a modality to accurately identify the presence of second mesiobuccal canals in maxillary first and second molars: a pilot study. *J Endod.* 2010;**36**(5):867-70.
4. Danforth RA, Dus I, Mah J. 3-D volume imaging for dentistry: a new dimension. *J Calif Dent Assoc.* 2003;**31**(11):817-23.
5. Wang Y, Zheng QH, Zhou XD, Tang L, Wang Q, Zheng GN, et al. Evaluation of the root and canal morphology of mandibular first permanent molars in a western Chinese population by cone-beam computed tomography. *J Endod.* 2010;**36**(11):1786-9.
6. Baratto Filho F, Zaitter S, Haragushiku GA, de Campos EA, Abuabara A, Correr GM. Analysis of the internal anatomy of maxillary first molars by using different methods. *J Endod.* 2009;**35**(3):337-42.
7. Tu MG, Huang HL, Hsue SS, Hsu JT, Chen SY, Jou MJ, et al. Detection of permanent three-rooted mandibular first molars by cone-beam computed tomography imaging in Taiwanese individuals. *J Endod.* 2009;**35**(4):503-7.
8. Qu X, Li G, Zhang Z, Ma X. Detection accuracy of in vitro approximal caries by cone beam computed tomography images. *Eur J Radiol.* 2011;**79**(2):e24-7.
9. Kamburoglu K, Kolsuz E, Kurt H, Kilic C, Ozen T, Paksoy CS. Accuracy of CBCT measurements of a human skull. *J Digit Imaging.* 2011;**24**(5):787-93.
10. Gray R, Bjornal AM, Skidmore AE. The maxillary first molar anatomy and morphology of permanent teeth. *Univ Iowa Coll Dent.* 1983:31-40.
11. Ng YL, Aung TH, Alavi A, Gulabivala K. Root and canal morphology of Burmese maxillary molars. *Int Endod J.* 2001;**34**(8):620-30.
12. Alavi AM, Opananon A, Ng YL, Gulabivala K. Root and canal morphology of Thai maxillary molars. *Int Endod J.* 2002;**35**(5):478-85.
13. Al Shalabi RM, Omer OE, Glennon J, Jennings M, Claffey NM. Root canal anatomy of maxillary first and second permanent molars. *Int Endod J.* 2000;**33**(5):405-14.
14. Thomas RP, Moule AJ, Bryant R. Root canal morphology of maxillary permanent first molar teeth at various ages. *Int Endod J.* 1993;**26**(5):257-67.
15. Yang ZP, Yang SF, Lee G. The root and root canal anatomy of maxillary molars in a Chinese population. *Endod Dent Traumatol.* 1988;**4**(5):215-8.
16. Hou GL, Tsai CC. The morphology of root fusion in Chinese adults (I). Grades, types, location and distribution. *J Clin Periodontol.* 1994;**21**(4):260-4.
17. Ingle J, Bakland L. *Endodontics*. Hamilton: BC Decker; 2008.
18. Weisman MI. A rare occurrence: a bi-rooted upper canine. *Aust Endod J.* 2000;**26**(3):119-20.
19. Thews ME, Kemp WB, Jones CR. Aberration in palatal root and canal morphology of two maxillary first molars. *J Endod.* 1979;**5**(3):94-6.
20. Stone LH, Stroner WF. Maxillary molars demonstrating more than one palatal root canal. *Oral Surg Oral Med Oral Pathol.* 1981;**51**(6):649-52.
21. Jacobsen EL, Nii C. Unusual palatal root canal morphology in maxillary molars. *Endod Dent Traumatol.* 1994;**10**(1):19-22.
22. Maggioro F, Jou YT, Kim S. A six-canal maxillary first molar: case report. *Int Endod J.* 2002;**35**(5):486-91.
23. Wong M. Maxillary first molar with three palatal canals. *J Endod.* 1991;**17**(6):298-9.
24. Barbizam JV, Ribeiro RG, Tanomaru Filho M. Unusual anatomy

- of permanent maxillary molars. *J Endod.* 2004;**30**(9):668-71.
25. Pattanshetti N, Gaidhane M, Al Kandari AM. Root and canal morphology of the mesiobuccal and distal roots of permanent first molars in a Kuwait population—a clinical study. *Int Endod J.* 2008;**41**(9):755-62.
 26. Wasti F, Shearer AC, Wilson NH. Root canal systems of the mandibular and maxillary first permanent molar teeth of south Asian Pakistanis. *Int Endod J.* 2001;**34**(4):263-6.
 27. Wolcott J, Minnich S, Ishley D, Kennedy W, Johnson S. Second mesiobuccal canals in maxillary molars: their incidence and importance. *Compend Contin Educ Dent.* 2002;**23**(9):818-20-824 passim.
 28. de Carvalho MC, Zuolo ML. Orifice locating with a microscope. *J Endod.* 2000;**26**(9):532-4.
 29. Pomeranz HH, Fishelberg G. The secondary mesiobuccal canal of maxillary molars. *J Am Dent Assoc.* 1974;**88**(1):119-24.
 30. Stephen C, Kenneth M. *Cohen's Pathways of the Pulp Expert Consult.* 10th ed; 2012.
 31. Alacam T, Tinaz AC, Genc O, Kayaoglu G. Second mesiobuccal canal detection in maxillary first molars using microscopy and ultrasonics. *Aust Endod J.* 2008;**34**(3):106-9.
 32. Buhrlay LJ, Barrows MJ, BeGole EA, Wenckus CS. Effect of magnification on locating the MB2 canal in maxillary molars. *J Endod.* 2002;**28**(4):324-7.
 33. Park JW, Lee JK, Ha BH, Choi JH, Perinpanayagam H. Three-dimensional analysis of maxillary first molar mesiobuccal root canal configuration and curvature using micro-computed tomography. *Oral Surg Oral Med Oral Pathol Oral Radiol Endod.* 2009;**108**(3):437-42.
 34. Degerness RA, Bowles WR. Dimension, anatomy and morphology of the mesiobuccal root canal system in maxillary molars. *J Endod.* 2010;**36**(6):985-9.
 35. Yoshioka T, Kikuchi I, Fukumoto Y, Kobayashi C, Suda H. Detection of the second mesiobuccal canal in mesiobuccal roots of maxillary molar teeth ex vivo. *Int Endod J.* 2005;**38**(2):124-8.
 36. Zhang R, Yang H, Yu X, Wang H, Hu T, Dummer PM. Use of CBCT to identify the morphology of maxillary permanent molar teeth in a Chinese subpopulation. *Int Endod J.* 2011;**44**(2):162-9.
 37. Zheng QH, Wang Y, Zhou XD, Wang Q, Zheng GN, Huang DM. A cone-beam computed tomography study of maxillary first permanent molar root and canal morphology in a Chinese population. *J Endod.* 2010;**36**(9):1480-4.
 38. Rathi S, Patil J, Jaju PP. Detection of Mesiobuccal Canal in Maxillary Molars and Distolingual Canal in Mandibular Molars by Dental CT: A Retrospective Study of 100 Cases. *Int J Dent.* 2010;**2010**:291276.