

Diagnostic Value of Panoramic Radiography in Determining the Position of Impacted Permanent Maxillary Canines

Fatemeh Ezoddini,¹ Soghra Yassaei,² and Sahar Ghanea^{3,*}

¹Department of Oral and Maxillofacial Radiology, Faculty of Dentistry, Shahid Sadoughi University of Medical Sciences, Yazd, IR Iran

²Department of Orthodontics, Faculty of Dentistry, Shahid Sadoughi University of Medical Sciences, Yazd, IR Iran

³Department of Oral and Maxillofacial Radiology, Faculty of Dentistry, Rafsanjan University of Medical Sciences, Rafsanjan, IR Iran

*Corresponding author: Sahar Ghanea, Department of Oral and Maxillofacial Radiology, Faculty of Dentistry, Rafsanjan University of Medical Sciences, Rafsanjan, IR Iran.

E-mail: s_ghanea82@yahoo.com

Received 2015 November 05; Revised 2016 June 02; Accepted 2016 July 26.

Abstract

Background: This study was performed to assess the diagnostic accuracy of panoramic radiography in determining the position of impacted permanent maxillary canines.

Methods: This was a diagnostic study to define how accurate panoramic radiography is in determining the position of impacted permanent maxillary canines. In panoramic radiographs of 33 patients (with 44 total impacted maxillary canines), α and β angulation, magnification and superimposition were assessed. The long axis of the impacted canine to the occlusal line was named α angle. The long axis of the impacted canine to the vertebral line was named β angle. The real position of the teeth was determined by CBCT. Sensitivity, specificity, positive predictive value, negative predictive value and accuracy of panoramic radiography were calculated. Kappa test was used to assess the agreement between panoramic radiography and CBCT. Roc curves were used to define cut-off point values.

Results: α angulation showed 84.3% of palatal impacted maxillary canines and 41.6% of buccal teeth in their real position. β angulation showed these positions in 81.8% and 87.5% of cases, magnification in 37.5% and 58.3% of cases and superimposition in 53.6% and 100% of cases. The degree of agreement between CBCT and α angulation, β angulation, magnification, and superimposition was 0.275, 0.526, 0.03 and 0.224, respectively. Cut-off point values for α angulation, β angulation and CII were 65 degrees, 63 degrees and 1.11, respectively.

Conclusions: Among different methods, β angulation showed the highest accuracy in the localization of impacted maxillary canines. α angulation and superimposition ranked second and third in terms of accuracy. Magnification had the least accuracy.

Keywords: Canine Tooth, Panoramic, Radiography

1. Background

Maxillary canines are the most frequently impacted teeth after third molars (1-5). Disturbed development of permanent maxillary canines is common due to having the longest development period, the most superior position of development and the most difficult developmental path (6-9).

Canines determine the occlusion, stability, form and function of dental arch (10). Impacted canines may lead to such problems as displacement and resorption of adjacent teeth, cystic degeneration, canine ankylosis, and a small dental arch (9). Therefore, the treatment method of choice is surgical exposure and placement of the tooth in the dental arch. Surgical exposure is performed from buccal or palatal sides. When the tooth is nearer to the buccal cortex, access is much easier from the buccal vestibule, and when it is nearer to the palatal cortex, access is easier from the palatal mucosa (10).

Determining the position of impacted maxillary ca-

nines affects prognosis and is necessary for selecting the therapeutic method (11). The position of canines can be determined by some radiologic methods (10). One method of tooth localization is panoramic radiography, which uses such variables such as angulation, magnification and superimposition (11).

Katsnelson et al. (10) introduced a simple method for the localization of impacted maxillary canines. According to the canine angulation to the occlusal plane, an angle greater than 65 degrees shows a buccally positioned impacted canine (11). Chaushu et al. (12) proposed that the mesiodistal dimensions of canines and ipsilateral incisors in panoramic radiography can be used for determining the position of the impacted maxillary canine. If the ratio of the widest mesiodistal dimension of the impacted canine to that of the ipsilateral central incisor (canine incisor index = CII) is equal to or more than 1.15, the position of the impacted canine can be considered to be palatal (13, 14). They also determined the position of the impacted canine in relation to the developed adjacent incisor. If the canine

is superimposed on the root of central incisor, it proposes the position of the impacted canine (11, 15, 16).

The other method for determining the position of maxillary impacted canines is cone beam computed tomography (CBCT). CBCT is used for the diagnosis, assessment and analysis of maxillofacial anomalies. CBCT has some advantages, such as the ability to detect the structural anomalies of teeth and the localization of the position of impacted and supernumerary teeth and their relation to adjacent roots or other anatomic structures. However, CBCT is costly and imposes a high radiation dose to the patient, and it is not easily available (17).

Each patient with an impacted maxillary canine has a panoramic radiograph at the time of diagnosis (10), so it would be beneficial if the buccal or palatal positions of the tooth could be determined by this method. Panoramic radiography is inexpensive, easily available and imposes a smaller dose of radiation to the patient (18-20).

2. Objectives

This study was performed to assess the accuracy of three methods of localization of impacted maxillary canines: by panoramic radiography, by determining the cut-off point values of angulation and CII in an Iranian population and by using the cervical line additional to occlusal plane for the angulation.

3. Methods

This was a cross-sectional, diagnostic study. The study population consisted of patients with impacted maxillary canines who were referred to the orthodontic ward of the dental college in Shahid Sadoughi University of Medical Sciences. Thirty-three patients (23 females and 10 males) with a total of 44 impacted maxillary canines entered the study. Thirty patients had already undergone either panoramic radiographs or CBCT (and sometimes both). Fourteen patients only had CBCT, so panoramic radiography was created from CBCT images.

The study was approved by the ethics committee of Shahid Sadoughi University of Medical Sciences (number \neq 31421).

Inclusion criteria consisted of the following conditions: presence of an impacted maxillary canine, sixth maxillary tooth, maxillary incisors and second cervical vertebra in panoramic radiography. Those with the following criteria were excluded from the study: craniofacial syndromes and cleft lip or palate, an impacted maxillary canine with rotation, a first maxillary molar with rotation, all types of malocclusion, mesiobuccal cusp restoration, and

superimposition of the vertebral column on the ramus in panoramic radiography.

Panoramic radiography was performed by EC Planmeca (Proline XC, Helsinki, Finland) operated at 80 KVP and 12 mA, and CBCT was done by Planmeca (Promax 3D, Helsinki, Finland) operated at 84 KVP and 12 mA. Panoramic images were analyzed by Planmeca Romexis 2.9.2. R and CBCT images were observed by the same software.

Panoramic radiographs were numbered and the patients' names were covered to ensure blindness. Measurements of the variables were performed by an observer blinded to the study. All measurements were repeated by the same observer two weeks later, and the mean value was recorded. Another observer determined the real position of impacted maxillary canines by CBCT. The real position of the teeth were determined by CBCT.

In panoramic radiography, the position of impacted permanent maxillary canines in relation to the ipsilateral incisor is determined by the following variables:

1. Angulation: The angle of the impacted maxillary canine is measured in relation to two planes. The occlusal plane is obtained from the connection of the tip of the mesiobuccal cusp of the two first maxillary molars. The long axis of the impacted canine is drawn in relation to this plane. The intersection angle of these lines is named alpha (α) and recorded for each impacted canine (Figure 1A). Considering the problems of the first maxillary molar for drawing the occlusal plane, in this study another plane the cervical plane was drawn from the connection of the most anterior and inferior point of the bilateral second cervical vertebra. The intersection angle of this plane and long axis of the impacted canine is named beta (β) and is recorded for each impacted canine (Figure 1B).

2. According to An et al. (11), if the α angle was greater than 65, the impacted canine is considered to be buccally positioned; otherwise, it is considered palatal. For the β , each angle is written down.

3. Magnification: CII is used to determine magnification. CII is the ratio of the widest dimension of the mesiodistal canine crown to that of the ipsilateral central incisor crown. According to Chaushu et al. (12), if CII is equal to or greater than 1.15, the impacted canine is considered to be palatally positioned. Otherwise, it is considered buccal.

4. Superimposition: It is determined by the overlap of the canine crown over the adjacent incisor root. According to An et al. (11), if the impacted canine is superimposed on the central root of adjacent incisor, it is considered to be palatally positioned.

Data was analyzed by SPSS (Ver. 17) using the Mann-Whitney U test. The level of significance is set at $P < 0.05$. Sensitivity, specificity, positive predictive value (PPV), neg-

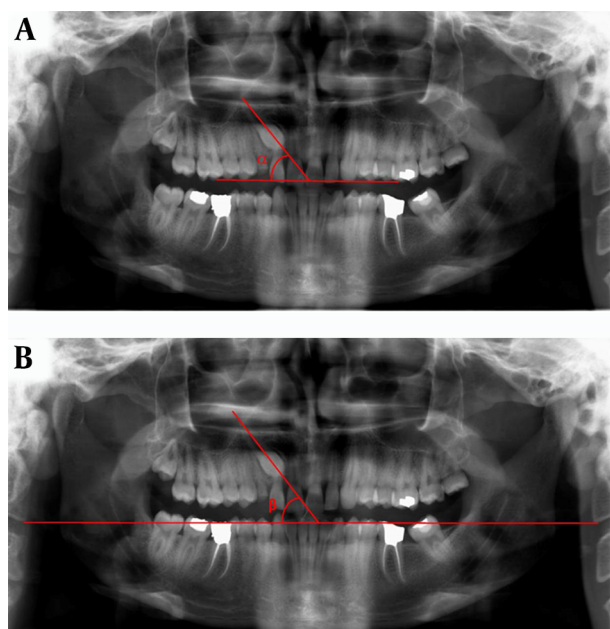


Figure 1. (A) Measurement of α angle in the angulation method. The tips of the mesiobuccal cusps of the two first maxillary molars were connected to each other as the occlusal plane. The long axis of the impacted canine was drawn in relation to this plane. The intersection angle of these lines was named α angle; (B) Measurement of β angle in the angulation method. The connection of the most anterior and inferior point of the bilateral second cervical vertebra was drawn as the cervical plane. The intersection angle of this plane and long axis of impacted canine was named β angle.

ative predictive value (NPV) and accuracy of panoramic radiography are calculated using the Chi-square test, and the palatal position is recorded as the positive state. The kappa test is used to assess the degree of agreement between panoramic radiography and CBCT. Roc curves are used to define cut-off point values.

4. Results

In this study, 33 panoramic radiographs that included 44 impacted permanent maxillary canines (11 bilateral cases) were assessed. The mean values of α angle, β angle and CII were as follows: 50.59 degrees, 54.07 degrees and 1.15, respectively.

According to CBCT images, 12 canines (27.27%) were located buccally and 32 (72.73%) were located palatally. Table 1 shows the comparison of the mean and standard deviation of α angle, β angle and CII according to the position of impacted permanent maxillary canines. Table 2 compares the position of impacted canines obtained by superimposition and CBCT.

Table 3 presents sensitivity, specificity, PPV, NPV and accuracy of α angle, β angle, CII and superimposition in lo-

calization of impacted permanent maxillary canines.

Sensitivity was calculated according to palatal position and specificity for the buccal position.

β angulation had the highest diagnostic value versus other variables in determining the position of impacted maxillary canines.

The degree of agreement of α angle, β angle, CII and superimposition with CBCT was assessed.

Kappa test showed that β angle had the highest agreement with CBCT results ($\chi^2 = 0.526$, $P = 0.001$) (Table 4).

Cut of point of α angle (65°), β angle (63°) and CII (1.11) was achieved by the ROC curve. Figure 2 show the ROC curves of three methods.

5. Discussion

Maxillary canines are the most commonly impacted teeth after third molars. Canines determine the occlusion, stability, form and function of the dental arch. Determination of the position of impacted maxillary teeth is an effective step in selecting a therapeutic method and assessing the prognosis. In this study, considering the high probability of restoration of the mesiobuccal cusp of the first maxillary molars, vertical or horizontal malocclusion of these teeth or extraction of the sixth tooth which make it difficult to draw the occlusal plane and use angulation we used an additional angle for calculating angulation. In this method, the most anterior and inferior point of the second cervical vertebra were connected to form the cervical plane. The angle between this line and the line passing the long axis of the impacted canine was used as the β angle.

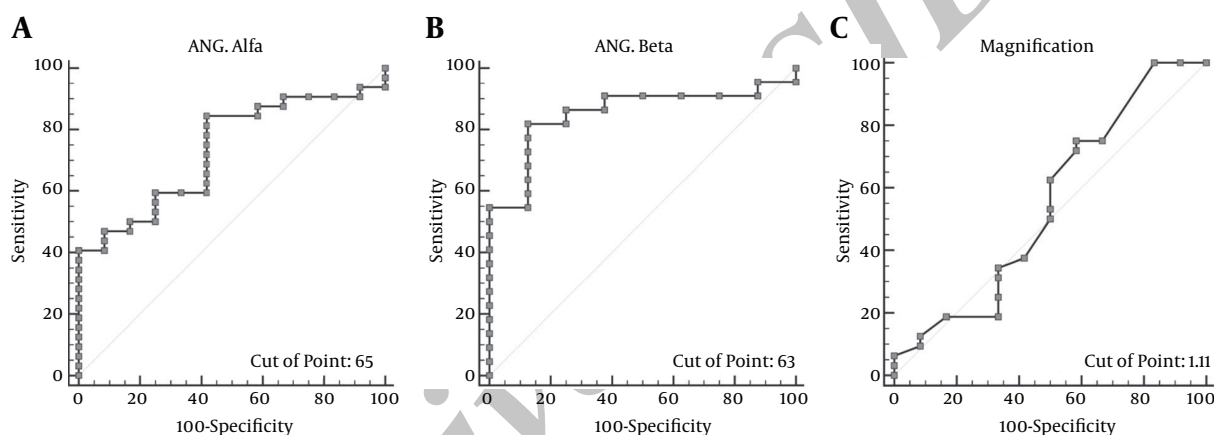
In this study, in order to determine the position of impacted permanent maxillary canines, three methods in panoramic radiography were used: angulation (by α and β angles), magnification (by CII) and superimposition. The real position of the impacted teeth were determined by CBCT.

Angulation using α angle showed 84.3% of palatal and 41.6% of buccal impacted permanent maxillary canines in their real position. The accuracy of this method was 72.8%. The agreement value of α angulation with CBCT was 0.275. Angulation using β angle showed 81.8% of palatal and 87.5% of buccal impacted permanent maxillary canines in their real position. The accuracy of this method was 83.3%. The agreement value of β angulation with CBCT was 0.526.

Magnification using CII showed 37.5% of palatal and 58.3% of buccal impacted permanent maxillary canines in their real position. The accuracy of this method was 43.2%. The agreement value of CII with CBCT was 0.03. Superimposition showed 53.6% of palatal and 100% of buccal impacted permanent maxillary canines in their real position. The accuracy of this method was 59.4%. The agreement

Table 1. Comparison of the Mean and Standard Deviation of α Angle, β Angle and CII According to the Position of Impacted Permanent Maxillary Canines

Variables	Location	N ^a	Mean	SD ^b	Range	P Value
Angulation α	P ^c	32	46.63	18.58	20.92 - 85.20	0.019
	B ^d	12	61.13	17.10	36.00 - 84.26	
	Total	44	50.59	19.14	20.92 - 85.20	
Angulation β	P	22	44.50	18.05	25.30 - 88.41	0.008
	B	8	72.50	12.08	49.00 - 86.34	
	Total	30	54.07	19.71	25.30 - 88.41	
CII	P	32	1.16	0.14	1.00 - 1.50	0.623
	B	12	1.11	0.20	0.77 - 1.40	
	Total	44	1.15	0.15	0.77 - 1.50	

^aNumber.^bStandard Deviation.^cPalatal.^dBuccal.**Figure 2.** (a) ROC Curve of α Angle, (b) ROC Curve of β Angle and (c) ROC Curve of Magnification**Table 2.** Position of Impacted Permanent Maxillary Canines According to Superimposition and CBCT

	CBCT		Total
	P	B	
Superimposition			
Yes	15	0	15
No	13	4	17
Total	28	4	32

value of superimposition with CBCT was 0.224. The cut-off point value was 65 degrees for α angle, 63 degrees for β angle and 1.11 for CII.

Katsnelson et al. (10) and An et al. (11) used angulation with α angle to determine the position of impacted permanent maxillary canines. Katsnelson et al. found that panoramic radiography using α angle is valid in localizing impacted maxillary canines, which is inconsistent with the results of the current study (10). In the two aforemen-

tioned studies, teeth with horizontal or vertical malocclusion or a restored mesiodistal cusp have not been excluded from the study. An et al. (11) found that angulation is not an appropriate method for the localization of impacted maxillary canines, which is consistent with the current study.

Among the variables used in this study, β angle showed the highest sensitivity, specificity, accuracy, diagnostic value and the highest agreement with CBCT. The problems with using α angle, the availability of landmarks to draw β angle and the higher stability of these landmarks compared to the sixth tooth, in addition to the higher diagnostic value and accuracy of β angle makes this method beneficial for the localization of impacted permanent maxillary canines.

Several studies have used magnification to localize the position of impacted maxillary canines with panoramic radiography (11, 12, 20, 21). Chaushu et al. (12) and Sudhakar et al. (20) showed that using CII for calculation of magnifica-

Table 3. Sensitivity, Specificity, Positive Predictive Value, Negative Predictive Value and Accuracy of Different Methods in the localization of Impacted Maxillary Canines

Variable	Sensitivity (%)	Specificity (%)	Positive Predictive Value	Negative Predictive Value	Accuracy (%)
Angulation α	84.3	41.6	79.4	50.0	72.8
Angulation β	81.8	87.5	94.7	63.6	83.3
CII	37.5	58.3	70.5	25.9	43.2
Superimposition	53.6	100.0	100.0	23.5	59.4

Table 4. Degree of Agreement of α Angel, β Angel, CII and Superimposition With CBCT

Variable	Value	P Value
Angulation α	0.275	0.066
Angulation β	0.599	0.001
CII	0.030	0.80
Superimposition	0.224	0.045

tion provides beneficial information about the position of the canines, which was not in agreement with the results of the current study. In digital radiography, measurements are more precise with lesser errors.

Nagpal et al. (21) found that magnification in panoramic radiography cannot be used as a reliable method for the localization of impacted maxillary canines. In this study, the root of the ipsilateral incisor was divided into three horizontal zones, and CII of each zone was calculated. The study showed that calculated CII does not vary regarding the zones (21). The results of the Nagpal et al. (21) study about magnification were consistent with the results of the current study. In this study, digital panoramic radiography was used as well. For magnification to be reliable there is a need for an ideal dental arch congruous with image layers in order to make buccal impacted canines more than 1 and palatal ones less than 1, which is difficult (21).

An et al. (11) found that magnification is not an appropriate method for the localization of impacted maxillary canines by panoramic radiography. Magnification was more successful than angulation in locating the position of impacted canines. They used a similar number of specimens and excluded canines with rotation, similar to the current study.

In this study, buccally impacted canines were more prevalent than palatally impacted canines, which is common among Chinese. Wolf and Mattila (16) found that magnification more accurately localizes palatally impacted canines than buccally impacted ones. According to the study of An et al. (11), magnification is more successful than angulation in finding the position of impacted maxillary canines. An et al. (11) showed that superimposition in panoramic radiography cannot be used alone for the local-

ization of impacted maxillary canines, which was consistent with the results of the present study. The sample size and the method of calculation were similar in both studies.

Several studies have found 65 degrees to be the cut-off point value for α angle (10, 11), which is consistent with the results of the current study. It seems that this value is similar in different races, so 65 degrees can be used as the cut-off value in different populations.

The cut-off point value for β angle was 63 degrees in the present study. A β angle of 63 degree and more indicates a buccal position, and an angle that is less than 63 degrees indicates a palatal position. In order to use this angle, further studies in different populations are required.

The cut-off point value of 1.15 for CII has been obtained in some studies (11, 12, 20, 21). In the current study, this value was 1.11, and its sensitivity (62%) and specificity (50%) were not acceptable. The difference in cut-off point values between the present study and other studies can be attributed to different races and different variables related to magnification in panoramic radiography devices.

5.1. Conclusion

This study showed that using β angle in the angulation method is an appropriate method for the localization of impacted maxillary canines, while magnification and superimposition were not appropriate methods in panoramic radiography for the localization of impacted maxillary canines though superimposition was better than magnification. Angulation using α angle was not an acceptable method, although it was better than magnification and superimposition.

It is recommended other studies should be performed to assess the accuracy of β angle in panoramic radiography for the localization of impacted maxillary canines in other populations.

Footnote

Authors' Contribution: Study concept and design: Fatemeh Ezoddini; acquisition of data: Soghra Yasaee; analysis and interpretation of data: Sahar Ghanea; drafting of the manuscript: Fatemeh Ezoddini; critical revision of

the manuscript for important intellectual content: Soghra Yasaei; statistical analysis: Sahar Ghanea; administrative, technical and material support: Fatemeh Ezoddini; study supervision: Soghra Yasaei

References

- Alqerban A, Jacobs R, Fieuws S, Willems G. Comparison of two cone beam computed tomographic systems versus panoramic imaging for localization of impacted maxillary canines and detection of root resorption. *Eur J Orthod*. 2011;**33**(1):93-102. doi: [10.1093/ejo/cjq034](https://doi.org/10.1093/ejo/cjq034). [PubMed: [21270321](https://pubmed.ncbi.nlm.nih.gov/21270321/)].
- Elefteriadis JN, Athanasiou AE. Evaluation of impacted canines by means of computerized tomography. *Int J Adult Orthodon Orthognath Surg*. 1996;**11**(3):257-64. [PubMed: [9456629](https://pubmed.ncbi.nlm.nih.gov/9456629/)].
- Ericson S, Kurol J. Incisor resorption caused by maxillary cuspids. A radiographic study. *Angle Orthod*. 1987;**57**(4):332-46. doi: [10.1043/0003-3219\(1987\)057<0332:IRCBMC>2.0.CO;2](https://doi.org/10.1043/0003-3219(1987)057<0332:IRCBMC>2.0.CO;2). [PubMed: [3479035](https://pubmed.ncbi.nlm.nih.gov/3479035/)].
- Ericson S, Kurol J. Resorption of maxillary lateral incisors caused by ectopic eruption of the canines. A clinical and radiographic analysis of predisposing factors. *Am J Orthod Dentofacial Orthop*. 1988;**94**(6):503-13. [PubMed: [3195514](https://pubmed.ncbi.nlm.nih.gov/3195514/)].
- Stewart JA, Heo G, Glover KE, Williamson PC, Lam EW, Major PW. Factors that relate to treatment duration for patients with palatally impacted maxillary canines. *Am J Orthod Dentofacial Orthop*. 2001;**119**(3):216-25. doi: [10.1067/mod.2001.110989](https://doi.org/10.1067/mod.2001.110989). [PubMed: [11244415](https://pubmed.ncbi.nlm.nih.gov/11244415/)].
- Alqerban A, Jacobs R, Lambrechts P, Loozen G, Willems G. Root resorption of the maxillary lateral incisor caused by impacted canine: a literature review. *Clin Oral Investig*. 2009;**13**(3):247-55. doi: [10.1007/s00784-009-0262-8](https://doi.org/10.1007/s00784-009-0262-8). [PubMed: [19277728](https://pubmed.ncbi.nlm.nih.gov/19277728/)].
- Bedoya MM, Park JH. A review of the diagnosis and management of impacted maxillary canines. *J Am Dent Assoc*. 2009;**140**(12):1485-93. [PubMed: [19955066](https://pubmed.ncbi.nlm.nih.gov/19955066/)].
- Bishara SE, Ortho D. Impacted maxillary canines: a review. *Am J Orthodont Dentofac Orthoped*. 1992;**101**(2):159-71.
- Jung YH, Liang H, Benson BW, Flint DJ, Cho BH. The assessment of impacted maxillary canine position with panoramic radiography and cone beam CT. *Dentomaxillofac Radiol*. 2012;**41**(5):356-60. doi: [10.1259/dmfr/14055036](https://doi.org/10.1259/dmfr/14055036). [PubMed: [22116130](https://pubmed.ncbi.nlm.nih.gov/22116130/)].
- Katsnelson A, Flick WG, Susarla S, Tartakovsky JV, Miloro M. Use of panoramic x-ray to determine position of impacted maxillary canines. *J Oral Maxillofac Surg*. 2010;**68**(5):996-1000. doi: [10.1016/j.joms.2009.09.022](https://doi.org/10.1016/j.joms.2009.09.022). [PubMed: [20138419](https://pubmed.ncbi.nlm.nih.gov/20138419/)].
- An S, Wang J, Li J, Cheng Q, Jiang CM, Wang YT, et al. Comparison of methods for localization of impacted maxillary canines by panoramic radiographs. *Dentomaxillofac Radiol*. 2013;**42**(8):20130129. doi: [10.1259/dmfr.20130129](https://doi.org/10.1259/dmfr.20130129). [PubMed: [23894190](https://pubmed.ncbi.nlm.nih.gov/23894190/)].
- Chaushu S, Chaushu G, Becker A. Reliability of a method for the localization of displaced maxillary canines using a single panoramic radiograph. *Clin Orthod Res*. 1999;**2**(4):194-9. [PubMed: [10806943](https://pubmed.ncbi.nlm.nih.gov/10806943/)].
- Bishara SE. Clinical management of impacted maxillary canines. *Semin Orthod*. 1998;**4**(2):87-98. [PubMed: [9680907](https://pubmed.ncbi.nlm.nih.gov/9680907/)].
- Ericson S, Kurol J. CT diagnosis of ectopically erupting maxillary canines—a case report. *Eur J Orthod*. 1988;**10**(2):115-21. [PubMed: [3164678](https://pubmed.ncbi.nlm.nih.gov/3164678/)].
- Smailiene D. [Localization of impacted maxillary canines by palpation and orthopantomography]. *Medicina (Kaunas)*. 2002;**38**(8):825-9. [PubMed: [12474755](https://pubmed.ncbi.nlm.nih.gov/12474755/)].
- Wolf JE, Mattila K. Localization of impacted maxillary canines by panoramic tomography. *Dentomaxillofac Radiol*. 1979;**8**(2):85-91. doi: [10.1259/dmfr.1979.0011](https://doi.org/10.1259/dmfr.1979.0011). [PubMed: [296087](https://pubmed.ncbi.nlm.nih.gov/296087/)].
- Suomalainen A. Cone beam computed tomography in oral radiology. University of Helsinki; 2010.
- Fox NA, Fletcher GA, Horner K. Localising maxillary canines using dental panoramic tomography. *Br Dent J*. 1995;**179**(11-12):416-20. [PubMed: [8534570](https://pubmed.ncbi.nlm.nih.gov/8534570/)].
- Southall PJ, Gravely JF. Radiographic localization of unerupted teeth in the anterior part of the maxilla: a survey of methods currently employed. *Br J Orthod*. 1987;**14**(4):235-42. [PubMed: [3481273](https://pubmed.ncbi.nlm.nih.gov/3481273/)].
- Sudhakar S, Patil K, Mahima VG. Localization of impacted permanent maxillary canine using single panoramic radiograph. *Indian J Dent Res*. 2009;**20**(3):340-5. doi: [10.4103/0970-9290.57381](https://doi.org/10.4103/0970-9290.57381). [PubMed: [19884720](https://pubmed.ncbi.nlm.nih.gov/19884720/)].
- Nagpal A, Pai KM, Setty S, Sharma G. Localization of impacted maxillary canines using panoramic radiography. *J Oral Sci*. 2009;**51**(1):37-45. [PubMed: [19325198](https://pubmed.ncbi.nlm.nih.gov/19325198/)].