



# The Evaluation of Relationship Between Maxillary Sinus Diseases and Dental Pathologies Using Dental Volumetric Tomography

Yeşim Deniz<sup>1\*</sup>, Ayşe Zeynep Zengin<sup>2</sup>

## Abstract

**Background:** The diagnosis of odontogenic sinusitis is important because the pathology, microbiology and the treatment of the odontogenic sinusitis are different from other forms of the sinusitis. In this study, the relationship between dental pathologies and maxillary sinus diseases was examined comprehensively.

**Methods:** In this study, 500 dental volumetric tomography (DVT) images were examined retrospectively. The vertical distances between the maxillary sinus floor and the teeth apices were examined. The dental pathologies and maxillary sinus diseases were reported. Chi-squared and Fisher exact tests were used for data analysis.

**Results:** Focal mucosal thickening (FMT) was the most common sinus pathology (60.2%). A relationship was found between the mucosal thickening of apical lesions, remaining roots and healthy implants ( $P < 0.05$ ). Mucus retention cysts (MRCs) were associated with apical lesions and periodontal defects ( $P < 0.05$ ). Polyp was related to the deep caries, healthy implants, horizontal bone loss and fixed orthodontic treatment ( $P < 0.05$ ). Periostitis was associated with apical lesions and periodontal defects. A relationship was detected between sinusitis with root fragments and apical lesions ( $P < 0.05$ ).

**Conclusions:** Odontogenic infections and odontogenic sources may play role in the formation of maxillary sinus pathologies. DVT is very useful in showing the relationship between maxillary sinus and maxillary teeth and the diagnosis of odontogenic sinus pathologies.

## \*Correspondence to

Yeşim Deniz,  
Çanakkale Onsekiz Mart  
University, Faculty of  
Dentistry, Department of  
Dental and Maxillofacial  
Radiology, 17110 Kepez,  
Çanakkale, Turkey.  
Phone: +90 (507) 3578000  
Email: yesimdeniz@comu.  
edu.tr, yesimdeniz@gmail.  
com

**Keywords:** Maxillary  
sinus, Dental volumetric  
tomography, Cone-beam  
computed tomography,  
Odontogenic sinusitis

Received Sep 10, 2018

Accepted Dec. 13, 2018

ePublished Dec. 27, 2018



Citation: Deniz Y, Zengin AZ. The evaluation of relationship between maxillary sinus diseases and dental pathologies using dental volumetric tomography. Avicenna J Dent Res. 2018;10(4):133-139. doi: 10.15171/ajdr.2018.26.

## Background

It is well known that the maxillary posterior teeth root is in close anatomical relationship with maxillary sinus floor. As a result of this close anatomical relationship, dental pathogens may contaminate the sinus mucosa and mucosal pathological changes may be initiated. This condition is named as odontogenic sinusitis. The diagnosis of odontogenic sinusitis is important because the pathology, microbiology and the treatment of the odontogenic sinusitis are different from those of the other forms of the sinusitis (1). Dental pathogen sources may include maxillary posterior teeth infections, pathological lesions of jaws and teeth, trauma or iatrogenic causes of maxillary sinus membrane. Odontogenic bacteria can reach the sinus mucosa by various ways such as the direct diffusion, the blood and lymph circulation through the tubular structure of the maxillary bone, deterioration of the sinus membrane structure due to tooth extraction or surgical procedures. Most common mucosal

## Highlights

- ▶ Odontogenic sources were related to sinus pathologies.
- ▶ Apical lesions and periodontal lesions were related to sinus diseases including periostitis.
- ▶ There was a relationship between orthodontic treatments and sinus pathologies
- ▶ Dentin caries, successful root canal treatment and root fragments were interrelated with sinus diseases.

abnormalities caused by the pathological sources are focal mucosal thickening (FMT), mucus retention cysts (MRCs), polyps, sinusitis and periostitis.

## Focal Mucosal Thickening

Normally, the maxillary sinus mucosa is approximately 1 mm thick, but when inflammation occurs in the sinus mucosa, the thickness may increase and be observed on the radiographs (Figure 1a). This inflammatory response

<sup>1</sup>Çanakkale Onsekiz Mart University, Department of Dental and Maxillofacial Radiology, Çanakkale, Turkey. <sup>2</sup>Ondokuz Mayıs University, Faculty of Dentistry, Department of Dental and Maxillofacial Radiology, Samsun, Turkey.

is referred to as mucositis (mucosal thickening) and is usually asymptomatic. Radiologically thickened mucosa is seen as homogeneous opacity in the form of a lying band on the sinus floor, more radiopaque than air-filled sinus, and with no cortical boundaries (2).

#### Mucus Retention Cyst

MRC formation may be caused by allergy, trauma, periapical and periodontal infections as with other maxillary sinus mucosal abnormalities (3). The MRC rarely shows symptoms and is often found incidentally on the radiograph. Its radiographic appearance is a well-defined, uniform dome-shaped radiopaque mass with no cortical boundaries (Figure 1b). The base of the lesion is often wider. It does not affect the surrounding tissues (4).

#### Antral Polyps

The polyps are irregular meetings of infected sinus mucous membrane. Radiologically, they are seen as well-circumscribed and round lesions in soft tissue densities and they often appear side by side (Figure 1c). Antral polyps are distinguished from the MRC with thickened sinus mucosa because polyps usually accompany the thickened sinus mucosa (2-5).

#### Periostitis

The inflammatory exudate of the dental lesions may diffuse into the bone and stimulate the periosteum to produce the new bone by lifting the periosteal layer of the cortex (7). This new bone formation may be in the form of one or more thin lines or a single thick line on the images (Figure 1d).

#### Maxillary Sinusitis

Maxillary sinusitis occurs as a result of certain conditions such as cold, influenza, chronic inflammatory diseases, allergies and obstructions in the osteomeatal complex. Sinusitis may give an irregular soft tissue radiological view due to the edema and the secretion (Figure 1e). Chronic sinusitis inflammation can cause thickening of the sinus cortical bone margins and dystrophic calcifications (6-8).

#### Imaging of Maxillary Sinus

The evaluation of midfacial region by direct radiographs is difficult because of its complicated structure and may be insufficient to assess the relationship between the teeth and the maxillary sinus base. Dental volumetric tomography (DVT) is very useful for paranasal sinus examinations because of its low radiation dose and high-quality bone imaging feature (2,6-8). The aim of the study is to investigate the relationship between these odontogenic sources and the maxillary sinus abnormalities using DVT.

#### Methods

The examination of the 500 DVT data and measurements were performed by two observers. Each observer recorded the maxillary sinus findings, pathologies of maxillary canines, premolars and molar tooth, other odontogenic sources in related areas, and anatomical relationship of maxillary sinus with the teeth. The evaluations were repeated within a week in the same conditions.

#### Exclusion Criteria

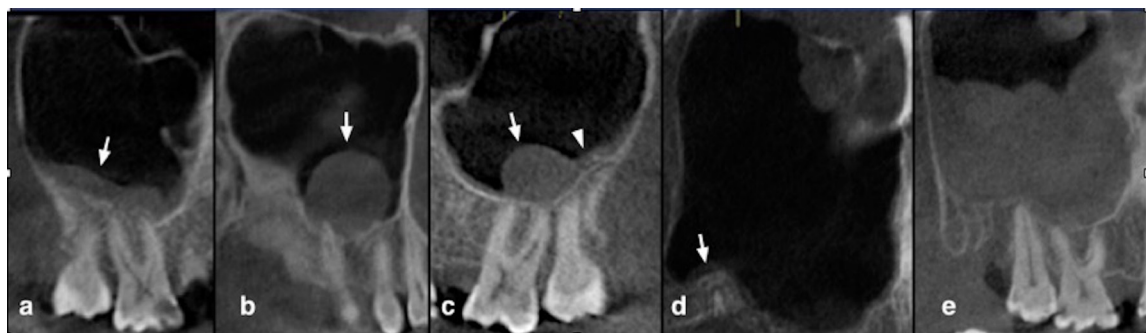
Images of patients under the age of 18, having any trauma, surgical operation or tumor formation in examined areas were excluded from the study. Images with fixed prosthetic restorations were not included in the study because metal artifacts could dissimulate detectable diagnosis.

#### Classifications of Sinus Diseases and Evaluation Methods

Inflammatory maxillary sinus pathologies were examined and classified into the FMT, MRC, polyps, periostitis and sinusitis (Figure 1). Fungal sinusitis, antrolith and mucocele were not included in the study because of lack of number. The strip-like structure was evaluated as FMT if thickening was bigger than 4 mm on the vertical measurement (9). Sinuses without any pathology were evaluated as healthy. The evaluation of sinus diseases prevalence was performed according to the gender and age groups (18-29 years, 30-39 years, 40-49 years, 50-59 years, 60 years and over).

#### Dental Conditions/Pathologies and Evaluation Method

Dental conditions/pathologies were examined and



**Figure 1.** (a) Focal mucosal thickening. (b) Mucus retention cysts. (c) Antral polyps (arrow head shows polyp with focal mucosal thickening). (d) Periostitis. (e) Maxillary sinusitis.

classified into filling without caries, enamel caries, dentin caries, apical lesion, succeeded root canal treatment, overfilled root canal treatment, inadequate root canal treatment, horizontal alveolar bone loss (HBL), vertical alveolar bone loss (VBL), furcation defect, root fragment, odontogenic cyst, healthy implant, peri-implantitis, teeth with bracket (orthodontic treatment), foreign body, or antral fistula, and internal and external root resorption. Tooth without any pathology were evaluated as healthy.

When the teeth roots were in the maxillary sinus or the distance between the apexes and the sinus floor was 0.5 mm or shorter, teeth were recorded as adjacent to sinus (10). For this measurement each tooth position was adjusted by angling tool to make the long axis of the tooth parallel to the sagittal plane (Figure 2). The teeth which had more than one dental condition/pathology were not included in the study. For example, when the tooth had a periodontal disease and a caries, the teeth was not included in the study.

#### Technical features of DVT

DVT images were obtained with GALILEOS Comfort Plus, Sirona Dental Systems, Bensheim, Germany operating at 98 kV and 15-30 mA. Measurements were performed in 1 mm thickness slices by using "distance tool bar" feature of the SIDEXIS XG 2.56 (Sirona Dental Inc., Bensheim, Germany) image analysis program. All examinations and measurements were performed under light illumination at 3.7 MP, 68 cm, 2560 x 1440 resolution, 27-inch color LCD display (The RadiForce MX270W, Eizo Nanao Corporation, Ishikawa, Japan).

#### Statistical Analysis

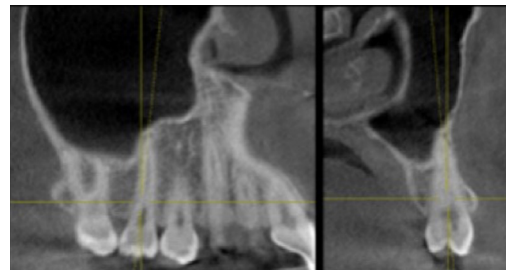
The data obtained from the study were entered in the SPSS Statistics version 21.0 (IBM Corp., New York) package program and analyzed. In the comparison of the data obtained by counting, "chi-squared test" "Fisher's exact test" were used; for interobserver and intraobserver agreement "Kappa test" was used. The statistical significance level was considered  $P < 0.05$ .

#### Results

The images of 1000 maxillary sinuses and 4353 maxillary teeth were examined. 288 of the patients were female (57.6%) and 212 of them were male (42.4%). All patients were between 18-96 years and their average age was 42.84 ( $\pm 15.05$ ) years. The mean age of the women was 42.98 ( $\pm 14.87$ ) and the mean age of the men was 42.64 ( $\pm 15.33$ ).

#### Prevalence of Maxillary Sinus Pathologies

FMT and MRC were found to have a significantly high incidence in the age group of 50-59 years; polyps and sinusitis were high in the age group of 18-29 years ( $P < 0.05$ ). The relationship between age groups and sinus pathologies is shown in Table 1. The most common sinus pathology was FMT (60.2%). MRC was more



**Figure 2.** Adjusting of the Tooth Position by the Angling Tool for Measurement of the Vertical Distance Between the Maxillary Sinus Floor and the Tooth Apex.

frequently observed in women than in men ( $P < 0.05$ ). The relationship between sinus pathologies and age group and gender is shown in Table 1.

#### Anatomical Relationship Between the Maxillary Sinus Base and the Teeth Roots

A total of 4353 teeth were evaluated on DVT images. 2250 of these teeth were located in the right maxilla and 2103 in the left maxilla. 851 of the right maxillary teeth (37.8%) were adjacent to the sinus and 1399 of right maxillary teeth (62.1%) were not adjacent to sinus. 798 left maxillary teeth (37.9%) were adjacent to maxillary sinus and 1305 left maxillary teeth (62.01%) were not adjacent to the sinus. There was no relationship between the gender and the anatomical relationships ( $P > 0.05$ ). It was found that right/left premolar, and molar teeth in the 18-29 age group were closer to the sinus base ( $P < 0.05$ ). The nearest tooth was the second molar and the second closest tooth was the first molar. The distribution of the anatomical relationships is shown in Table 2.

#### Relationships Between Dental Pathologies And Maxillary Sinus Pathologies

##### Restored Tooth

In this study, 95 restored teeth without another dental or periodontal pathology were detected. 53 of them were adjacent and 42 of them were not adjacent to the maxillary sinus. There was no relationship between the filled teeth and pathologies in the related area of maxillary sinus floor ( $P > 0.05$ ).

##### Enamel Caries

Enamel caries were detected in 22 of the teeth. 18 of them (81.8%) were adjacent to the sinus floor and 4 of them were not adjacent to the sinus (18.2%). There was no statistical correlation between the enamel caries and the pathology of adjacent sinuses ( $P > 0.05$ ).

##### Dentin Caries

There was a significant correlation between maxillary sinus pathologies and dentin caries without another dental pathology ( $P < 0.05$ ). Table 3 shows the relationships

**Table 1.** Distributions of Age Group and Gender According to Maxillary Sinus Diseases

	Age Groups										P	Total	F %	M %	P
	18-29		30-39		40-49		50-59		60 and over						
	No.	%	No.	%	No.	%	No.	%	No.	%					
FMT	192	22.1	112	12.9	181	20.8	239	27.6	144	15.5	0.00	868	45.7	54.3	0.06
MRC	11	18.8	9	17.0	16	30.2	19	34.0	1	0.0	0.03	56	73.6	26.4	0.00
Polyp	68	38.6	19	10.2	10	5.7	40	22.7	40	22.7	0.01	177	46.0	54.0	0.63
Periostitis	12	41.4	11	34.5	2	6.9	2	6.9	3	10.3	0.07	30	62.1	37.9	0.11
Sinusitis	95	31.0	3	1.0	55	17.6	69	22.5	85	27.8	0.00	307	48.4	51.6	0.77
Total	378	26.1	154	10.6	262	18.2	369	25.6	273	18.8	0.23	1436	47.7	52.3	0.79

between MRC, polyps with dentin caries ( $P < 0.05$ ).

**Apical Lesion**

A significant relationship was found between the apical lesions and the maxillary sinus pathologies. Table 3 shows the relationships between the apical lesions and the FMT, MRC, periostitis and sinusitis.

**Root Canal Treatment**

There was a significant correlation between succeeded

**Table 2.** Anatomical Relationship Between Tooth Roots and Maxillary Sinus Base

	Not Close to the Sinus		Close to the Sinus		Total
	No.	%	No.	%	
<b>Left</b>					
Canine	441	95.7	20	4.3	461
1.Premolar	325	88.8	41	11.2	366
2.Premolar	230	64.2	128	35.8	358
1.Molar	96	31.0	214	69.0	310
2.Molar	108	27.8	280	72.2	388
3.Molar	105	47.7	115	52.3	220
<b>Right</b>					
Canine	435	94.6	25	5.4	460
1.Premolar	327	89.6	38	10.4	365
2.Premolar	193	56.4	149	43.6	342
1.Molar	269	53.9	230	46.1	499
2.Molar	105	26.6	289	73.4	394
3.Molar	70	36.8	120	63.2	190

root treatment teeth and polyps ( $P < 0.05$ ) (Table 3). Statistical analysis could not be performed for inadequate root canal treatments and overfilled root canal treatments because of inadequacy of the number.

**Periodontal Diseases**

In this study, significant relationships were found between the HBL with the MRC, polyps and periostitis (Table 4). VBL was observed in 10 teeth without any other dental pathology. Two of the teeth were adjacent to the maxillary sinus and 8 of them were not adjacent to the maxillary sinus. The VBL number was not adequate for the statistical evaluation. A significant correlation was investigated between maxillary sinus pathologies and the teeth with furcation defect without another dental pathology ( $P < 0.05$ ). Table 4 shows the relationship between furcation defect and MRC, polyp and periostitis ( $P < 0.05$ ).

**Other Dental Pathology Sources**

There were relationships between the root fragments and the FMT and sinusitis; healthy implants and FMT; and bracket teeth for orthodontic treatment and polyps ( $P < 0.05$ ). There were no relationships between odontogenic cysts and maxillary sinus pathologies as well as between impacted third molars and total of sinus pathologies ( $P > 0.05$ ) (Table 5). The number of the peri-implantitis, antrolith, ora-antral fistula, internal and external root resorptions and the supernumerary teeth were not adequate for statistical evaluation.

**Table 3.** Relationships Between Dentin Caries, Successful Root Canal Treatment, Apical Lesions and Sinus Diseases

	Dentin Caries					Apical Lesions					Successful Root Canal Treatment				
	Not close to sinus		Close to Sinus		P	Not Close to Sinus		Close to Sinus		P	Not Close to Sinus		Close to Sinus		P
	No.	%	No.	%		No.	%	No.	%		No.	%	No.	%	
FMT	12	14.11	34	40.0	0.24	29	21.0	40	28.9	0.02	2	16.6	3	25.0	0.23
MRC	0	0.0	7	8.2	0.00	2	1.4	8	5.7	0.03	1	8.3	0	0.0	0.44
Polyp	0	0.0	13	15.3	0.00	4	2.9	5	3.6	0.58	0	0.0	3	25.0	0.00
Periostitis	1	1.1	4	4.7	0.06	4	2.9	35	25.3	0.00	0	0.0	2	16.6	0.05
Sinusitis	4	4.7	10	11.7	0.95	3	2.1	8	5.7	0.04	1	8.3	0	0.0	0.44
Total	17	20.0	68	80.0	0.00	43	30.4	96	69.5	0.02	4	33.3	8	66.6	0.03

**Table 4.** Relationships Between the Horizontal Bone Loss and the Furcation Defect and Sinus Diseases

	Horizontal Bone Loss				P	Furcation Defect				P
	Not Close to Sinus		Close to Sinus			Not Close to Sinus		Close to Sinus		
	No.	%	No.	%		No.	%	No.	%	
FMT	69	20.1	148	43.1	0.08	10	17.8	15	26.7	0.75
MRC	6	1.74	8	2.3	0.01	0	0.0	4	7.1	0.02
Polyp	18	5.2	39	11.3	0.02	2	3.57	3	5.35	0.89
Periostitis	1	0.29	5	1.4	0.00	2	3.57	10	17.8	0.01
Sinusitis	32	9.3	17	4.95	0.57	3	5.35	7	12.5	0.06
Total	126	36.7	217	63.2	0.04	17	30.3	39	69.4	0.03

**Table 5.** Relationship Between the Root Fragments, Impacted Teeth, Odontogenic Cysts With the Sinus Pathologies

	Root Fragment					Impacted Teeth					Odontogenic Cysts				
	Not close to sinus		Close to Sinus		P	Not Close to Sinus		Close to Sinus		P	Not Close to Sinus		Close to Sinus		P
	No.	%	No.	%		No.	%	No.	%		No.	%	No.	%	
FMT	6	22.2	12	44.4	0.04	8	14.5	20	36.3	0.62	3	17.6	5	29.4	0.51
MRC	0	0.0	0	0.0	-	1	1.8	1	1.8	0.59	0	0.0	0	0.0	----
Polyp	1	3.7	1	3.7	0.44	1	1.8	8	14.5	0.15	1	5.8	0	0.0	0.61
Periostitis	1	3.7	0	0.0	0.09	2	3.6	5	9.09	0.82	0	0.0	1	5.8	0.54
Sinusitis	2	7.4	4	14.8	0.04	2	3.6	7	12.72	0.50	3	17.6	4	23.5	0.14
Total	10	37.0	17	62.9	0.3	14	25.4	41	74.5	0.02	7	41.1	10	58.8	0.22

**Discussion**

This study showed that odontogenic infections can affect the maxillary sinus and may cause various inflammatory sinus diseases as reported in previous reports (11,12). The pathological bacteria, bacterial products and inflammatory cytokines can be transmitted to the sinus mucosa by direct diffusion or blood and lymphatic pathways. They may lead to pathological changes in the mucosa due to several vascular anastomoses.

Investigators have reported that the most common causes of odontogenic sinusitis are iatrogenic causes of dental abscess perforating the sinus membrane and the periodontal disease interacting with sinus membrane (13-15). In this study, the aim was to evaluate the relationship between dental pathologies and sinus pathologies.

Researchers have reported that the sinus pathology is more frequently seen in male patients. The researchers attributed this to the inadequate oral hygiene in male patients (12,16,17). On the contrary, Arias-Irimia et al (18) reported that sinus pathologies were more frequently observed in female patients. In this study, no difference was observed between the genders ( $P > 0.05$ ).

The investigators accepted different values for the FMT. In this study 4 mm thickness value was agreed upon for the FMT with reference to Hansen et al study (9). Hansen et al investigated the pathologic mucosal thickening on T1-weighted images due to the increased protein level in the Schneiderian membrane, and the thickening over 4 mm in the T2-weighted images due to the increased fluid content (9). Researchers have reported that FMT is more common in male patients (12,16). In this study,

there was no correlation between FMT and gender but quantitatively, more FMT was observed in male patients ( $P > 0.05$ ). Sheikhi et al reported that FMTs increased with age. In agreement with this finding, FMT has been frequently observed in the patients aged 50-59 in this study ( $P < 0.05$ ) (19).

Researchers have reported that the second leading sinus pathology is the MRC (16,20-22). MRC was detected in 2.3% of patients in this study. In accordance with this study, previous investigators concluded that the MRC accounted for 2%-10% of the sinus pathologies (16,23). MRC may be related to changes in seasonal allergies, cold, humidity, or temperature changes. High prevalence of MRC may be explained by these conditions.

Bomeli et al and Brüllmann et al argued that teeth with dentin caries constitute sinus pathology. In this study, a significant relationship was found between dentin caries and MRC and polyps (8,24). The bacteria in caries may infiltrate into the pulp chamber and reach the apex via the root canal (7,25). In addition, bacteria may reach the sinus membrane through many vascular anastomoses due to the sinus proximity of the teeth.

Previous studies have shown a relationship between the apical lesions and the FMT (12,16,17,26), but Phothikhun et al found no relationship between them (11). In this study, there was a relationship between the apical lesion and the FMT ( $P < 0.05$ ).

Phothikhun et al and Janner et al reported no association between the periapical lesions and MRC (11,17). In accordance with our study, Vallo et al found a statistically significant relationship between apical lesions and MRC

(12). The reason for this relationship may be the direct diffusion of the pathological bacteria, bacterial products and the inflammatory cytokines into the sinus mucosa or the lymphatic pathways leading to the pathological changes in the mucosa.

A significant relationship was also found between the apical lesions and the periostitis in our study. The possible cause of the periostitis may be focal infectious agents' access to the sinus floor leading to new bone formation there.

Vallo et al found that there was a significant relationship between the MRC and the root treatment (12). Brüllmann et al found an association between the root treatment and the FMT (8). Janner et al reported that there was no relationship between endodontically treated teeth and FMT (17). Phothikhun et al reported that they could not find a relationship between channel therapy and maxillary sinus pathology (11). In this study, no relation was found between FMT and the appropriate channel-treated teeth. However, a statistically significant relationship was found between the appropriate channel-treated teeth and polyps. Polyps are defined as irregular mucosal folds that form on the chronically inflamed sinus membrane. Sinus mucosa may be damaged by root canal instruments due to excessive preparation of the canal, outflow of infected debris, canal irrigation solutions, and drainage of duct filler materials from the root (27).

Bomeli et al have argued that periodontal diseases alone are not a source of the maxillary sinus pathology, but sinus pathology occurs when a periodontal defect accompanies a dental abscess (24). Falk et al found a decrease in sinus mucosa thickness after periodontal treatment (28). They reported that there was no improvement in the sinus mucosa in the two quadrants whose treatment was unsuccessful (28). With the periodontal bone loss, pathological bacteria, bacterial products and inflammatory cytokines may come to the destruction zone. As the periodontal destruction increases, the levels of this products also increase. These products may spread directly to the sinus mucosa through the disordered periodontal tissues and widened periodontal space. Phothikhun et al classified periodontal bone loss as mild, moderate, and severe (11). They reported that there was a significant relationship between FMT and other periodontal diseases except for moderate periodontal bone loss. The same researchers also found a direct correlation between bone loss level and MRC (11).

Contrary to the present study, Lopatin et al reported that 10 of 70 diagnosed odontogenic cysts accompanied odontogenic sinusitis, which is in agreement with to Costa et al study (29,30). In this study, no relationship between odontogenic cysts and sinus pathologies was observed. It is thought that corticated walls prevent penetration of cyst's content to the sinus mucosa. However, this result may be changed by the infected cysts content and the cyst

wall perforations.

In this study, a relationship between the FMT and the healthy implants was detected. This may be due to the use of the autologous, allogeneic and the alloplastic graft materials during implantation (31). These treatment methods could impair the physical mechanism of the maxillary sinus by disrupting the anatomical integrity of the maxillary sinus.

In this study, a correlation was found between the teeth with and orthodontic treatment and polyps. The study of Wehrbein et al which was conducted on dogs showed that orthodontic tooth movements caused histological changes in the maxillary sinus membrane (32). Additionally, Fuhrmann et al reported that when the upper molar teeth were moved orthodontically in adult patients, the defects occurred at the base of the maxillary sinus adjacent to these teeth (33). The movement of the teeth leads to periodontal space widening (34). The widening may lead to pathogens' reaching maxillary sinus mucosa.

The limitation of this retrospective study was that some dental pathologies could not be included because of insufficient number of these pathologies. Consequently, histological diagnosis may be more valuable in the evaluation of these relationships.

## Conclusions

Clinicians are advised to remove odontogenic factors to prevent the formation of sinus pathologies. DVT is a very useful imaging method for the diagnosis of maxillary sinus pathologies and for examining the relationship between maxillary posterior teeth and maxillary sinus. In this study, unlike previous studies, some relationships were observed between dentin caries with MRC and polyp; apical lesions with periostitis; periodontal lesions with polyp and periostitis; horizontal bone loss with polyp and periostitis; furcation defects with periostitis; orthodontic treatments with sinus diseases.

## Authors' Contribution

All of the listed authors contributed to the conduct of the study. Study design, data collection, statistical analysis, data interpretation, manuscript preparation and literature search were applied by all of the listed authors.

## Ethical Statement

This retrospective study was approved by Ondokuz Mayıs University Clinical Research Ethics Committee (11.12.2014, B.30.2.ODM.0.20.08/1367).

## Conflict of Interest Disclosures

The authors declare that they have no conflict of interests.

## References

1. Brook I, Frazier EH, Gher ME Jr. Microbiology of periapical abscesses and associated maxillary sinusitis. *J Periodontol.* 1996;67(6):608-10. doi: [10.1902/jop.1996.67.6.608](https://doi.org/10.1902/jop.1996.67.6.608).
2. Ruprecht A, Lam EWN. Paranasal Sinus Diseases. In: White SC, Pharoah MJ, eds. *Oral radiology: principles and interpretation.* 7th ed. St. Louis: Mosby; 2014:472-89.
3. Moskow BS. A histomorphologic study of the effects

- of periodontal inflammation on the maxillary sinus mucosa. *J Periodontol.* 1992;63(8):674-81. doi: [10.1902/jop.1992.63.8.674](https://doi.org/10.1902/jop.1992.63.8.674).
4. Som PM, Brandwein MS. Sinonasal cavities: inflammatory diseases. In: Som PM, Curtin HD, eds. *Head and neck imaging*. 4th ed. St. Louis: Mosby; 2003:193-259.
  5. Larheim TA, Westesson PL. *Maxillofacial imaging*. New York: Springer; 2006.
  6. Mehra P, Murad H. Maxillary sinus disease of odontogenic origin. *Otolaryngol Clin North Am.* 2004;37(2):347-64. doi: [10.1016/s0030-6665\(03\)00171-3](https://doi.org/10.1016/s0030-6665(03)00171-3).
  7. Brook I. Microbiology of acute and chronic maxillary sinusitis associated with an odontogenic origin. *Laryngoscope.* 2005;115(5):823-5. doi: [10.1097/01.mlg.0000157332.17291.fc](https://doi.org/10.1097/01.mlg.0000157332.17291.fc).
  8. Brüllmann DD, Schmidtman I, Hornstein S, Schulze RK. Correlation of cone beam computed tomography (CBCT) findings in the maxillary sinus with dental diagnoses: a retrospective cross-sectional study. *Clin Oral Investig.* 2012;16(4):1023-9. doi: [10.1007/s00784-011-0620-1](https://doi.org/10.1007/s00784-011-0620-1).
  9. Hansen AG, Helvik AS, Nordgard S, Bugten V, Stovner LJ, Haberg AK, et al. Incidental findings in MRI of the paranasal sinuses in adults: a population-based study (HUNT MRI). *BMC Ear Nose Throat Disord.* 2014;14(1):13. doi: [10.1186/1472-6815-14-13](https://doi.org/10.1186/1472-6815-14-13).
  10. Fanuscu MI, Chang TL. Three-dimensional morphometric analysis of human cadaver bone: microstructural data from maxilla and mandible. *Clin Oral Implants Res.* 2004;15(2):213-8. doi: [10.1111/j.1600-0501.2004.00969.x](https://doi.org/10.1111/j.1600-0501.2004.00969.x).
  11. Phothikhun S, Suphanantachat S, Chuenchompoonut V, Nisapakultorn K. Cone-beam computed tomographic evidence of the association between periodontal bone loss and mucosal thickening of the maxillary sinus. *J Periodontol.* 2012;83(5):557-64. doi: [10.1902/jop.2011.110376](https://doi.org/10.1902/jop.2011.110376).
  12. Vallo J, Suominen-Taipale L, Huuonen S, Soikkonen K, Norblad A. Prevalence of mucosal abnormalities of the maxillary sinus and their relationship to dental disease in panoramic radiography: results from the Health 2000 Health Examination Survey. *Oral Surg Oral Med Oral Pathol Oral Radiol Endod.* 2010;109(3):e80-7. doi: [10.1016/j.tripleo.2009.10.031](https://doi.org/10.1016/j.tripleo.2009.10.031).
  13. Melen I, Lindahl L, Andreasson L, Rundcrantz H. Chronic maxillary sinusitis. Definition, diagnosis and relation to dental infections and nasal polyposis. *Acta Otolaryngol.* 1986;101(3-4):320-7.
  14. Brook I. Sinusitis of odontogenic origin. *Otolaryngol Head Neck Surg.* 2006;135(3):349-55. doi: [10.1016/j.otohns.2005.10.059](https://doi.org/10.1016/j.otohns.2005.10.059).
  15. Nimigean VR, Nimigean V, Maru N, Andressakis D, Balatsouras DG, Danielidis V. The maxillary sinus and its endodontic implications: clinical study and review. *B-ENT.* 2006;2(4):167-75.
  16. Rege IC, Sousa TO, Leles CR, Mendonca EF. Occurrence of maxillary sinus abnormalities detected by cone beam CT in asymptomatic patients. *BMC Oral Health.* 2012;12:30. doi: [10.1186/1472-6831-12-30](https://doi.org/10.1186/1472-6831-12-30).
  17. Janner SF, Caversaccio MD, Dubach P, Sendi P, Buser D, Bornstein MM. Characteristics and dimensions of the Schneiderian membrane: a radiographic analysis using cone beam computed tomography in patients referred for dental implant surgery in the posterior maxilla. *Clin Oral Implants Res.* 2011;22(12):1446-53. doi: [10.1111/j.1600-0501.2010.02140.x](https://doi.org/10.1111/j.1600-0501.2010.02140.x).
  18. Arias-Irimia O, Barona-Dorado C, Santos-Marino JA, Martinez-Rodriguez N, Martinez-Gonzalez JM. Meta-analysis of the etiology of odontogenic maxillary sinusitis. *Med Oral Patol Oral Cir Bucal.* 2010;15(1):e70-3. doi: [10.4317/medoral.15.e70](https://doi.org/10.4317/medoral.15.e70).
  19. Sheikhi M, Pozve NJ, Khorrami L. Using cone beam computed tomography to detect the relationship between the periodontal bone loss and mucosal thickening of the maxillary sinus. *Dent Res J (Isfahan).* 2014;11(4):495-501.
  20. Rhodus NL. A comparison of periapical and panoramic radiographic surveys in the diagnosis of maxillary sinus mucous retention cysts. *Compendium.* 1989;10(5):275-7, 80-1.
  21. Bhattacharyya N. Do maxillary sinus retention cysts reflect obstructive sinus phenomena? *Arch Otolaryngol Head Neck Surg.* 2000;126(11):1369-71.
  22. Rodrigues CD, Freire GF, Silva LB, Fonseca da Silveira MM, Estrela C. Prevalence and risk factors of mucous retention cysts in a Brazilian population. *Dentomaxillofac Radiol.* 2009;38(7):480-3. doi: [10.1259/dmfr/48774803](https://doi.org/10.1259/dmfr/48774803).
  23. Cha JY, Mah J, Sinclair P. Incidental findings in the maxillofacial area with 3-dimensional cone-beam imaging. *Am J Orthod Dentofacial Orthop.* 2007;132(1):7-14. doi: [10.1016/j.ajodo.2005.08.041](https://doi.org/10.1016/j.ajodo.2005.08.041).
  24. Bomeli SR, Branstetter BFT, Ferguson BJ. Frequency of a dental source for acute maxillary sinusitis. *Laryngoscope.* 2009;119(3):580-4. doi: [10.1002/lary.20095](https://doi.org/10.1002/lary.20095).
  25. Abrahams JJ, Glassberg RM. Dental disease: a frequently unrecognized cause of maxillary sinus abnormalities? *AJR Am J Roentgenol.* 1996;166(5):1219-23. doi: [10.2214/ajr.166.5.8615273](https://doi.org/10.2214/ajr.166.5.8615273).
  26. Nascimento EH, Pontual ML, Pontual AA, Freitas DQ, Perez DE, Ramos-Perez FM. Association between Odontogenic Conditions and Maxillary Sinus Disease: A Study Using Cone-beam Computed Tomography. *J Endod.* 2016;42(10):1509-15. doi: [10.1016/j.joen.2016.07.003](https://doi.org/10.1016/j.joen.2016.07.003).
  27. Zehnder M, Belibasakis GN. On the dynamics of root canal infections-what we understand and what we don't. *Virulence.* 2015;6(3):216-22. doi: [10.4161/21505594.2014.984567](https://doi.org/10.4161/21505594.2014.984567).
  28. Falk H, Ericson S, Hugoson A. The effects of periodontal treatment on mucous membrane thickening in the maxillary sinus. *J Clin Periodontol.* 1986;13(3):217-22.
  29. Lopatin AS, Sysolyatin SP, Sysolyatin PG, Melnikov MN. Chronic maxillary sinusitis of dental origin: is external surgical approach mandatory? *Laryngoscope.* 2002;112(6):1056-9. doi: [10.1097/00005537-200206000-00022](https://doi.org/10.1097/00005537-200206000-00022).
  30. Costa F, Emanuelli E, Robiony M, Zerman N, Polini F, Politi M. Endoscopic surgical treatment of chronic maxillary sinusitis of dental origin. *J Oral Maxillofac Surg.* 2007;65(2):223-8. doi: [10.1016/j.joms.2005.11.109](https://doi.org/10.1016/j.joms.2005.11.109).
  31. Regev E, Smith RA, Perrott DH, Pogrel MA. Maxillary sinus complications related to endosseous implants. *Int J Oral Maxillofac Implants.* 1995;10(4):451-61.
  32. Wehrbein H, Bauer W, Schneider B, Diedrich P. [Experimental bodily tooth movement through the bony floor of the nose--a pilot study]. *Fortschr Kieferorthop.* 1990;51(5):271-6.
  33. Fuhrmann R, Bucker A, Diedrich P. Radiological assessment of artificial bone defects in the floor of the maxillary sinus. *Dentomaxillofac Radiol.* 1997;26(2):112-6. doi: [10.1038/sj.dmfr.4600223](https://doi.org/10.1038/sj.dmfr.4600223).
  34. Sanz M, Martin C. Tooth movement in the periodontally compromised patient. In: Lang NP, Lindhe J, eds. *Clinical periodontology and implant dentistry*. 6th ed. India: John Wiley & Sons; 2015:1297-325.