

Tuberculous Constrictive Pericarditis

Gary Tse,^{1,2} Aamir Ali,¹ Francisco Alpendurada,¹ Sanjay Prasad,¹ Claire E Raphael,^{1,2,*} and Vassilis Vassiliou^{1,*}

¹Cardiovascular Magnetic Resonance Unit, Royal Brompton Hospital, London, UK

²School of Medicine, Imperial College London, London, UK

*Corresponding authors: Claire E Raphael, Cardiovascular Magnetic Resonance Unit, Royal Brompton Hospital, London, UK. Vassilis Vassiliou, Cardiovascular Magnetic Resonance Unit, Royal Brompton Hospital, London, UK. Tel: +44-2073518800, Fax: +44-2073518816, E-mail: garytse@doctors.org.uk

Received: May 13, 2015; Accepted: July 13, 2015

Introduction: Constrictive pericarditis is characterized by constriction of the heart secondary to pericardial inflammation. Cardiovascular magnetic resonance (CMR) imaging is useful imaging modality for addressing the challenges of confirming this diagnosis. It can be used to exclude other causes of right heart failure, such as pulmonary hypertension or myocardial infarction, determine whether the pericardium is causing constriction and differentiate it from restrictive cardiomyopathy, which also causes impaired cardiac filling.

Case Presentation: A 77-year-old man from a country with high incidence of tuberculosis presented with severe dyspnea. Echocardiography revealed a small left ventricle with normal systolic and mildly impaired diastolic function. Left heart catheterization revealed non-obstructive coronary disease, not felt contributory to the dyspnea. Anatomy imaging with cardiovascular magnetic resonance imaging (CMR) showed global, severely thickened pericardium. Short tau inversion recovery (STIR) sequences for detection of oedema/inflammation showed increased signal intensity and free breathing sequences confirmed septal flattening on inspiration. Late gadolinium imaging confirmed enhancement in the pericardium, with all findings suggestive of pericardial inflammation and constriction.

Conclusions: CMR with STIR sequences, free breathing sequences and late gadolinium imaging can prove extremely useful for diagnosing constrictive pericarditis.

Keywords: Constrictive Pericarditides; Pericardial Effusion; Tuberculosis

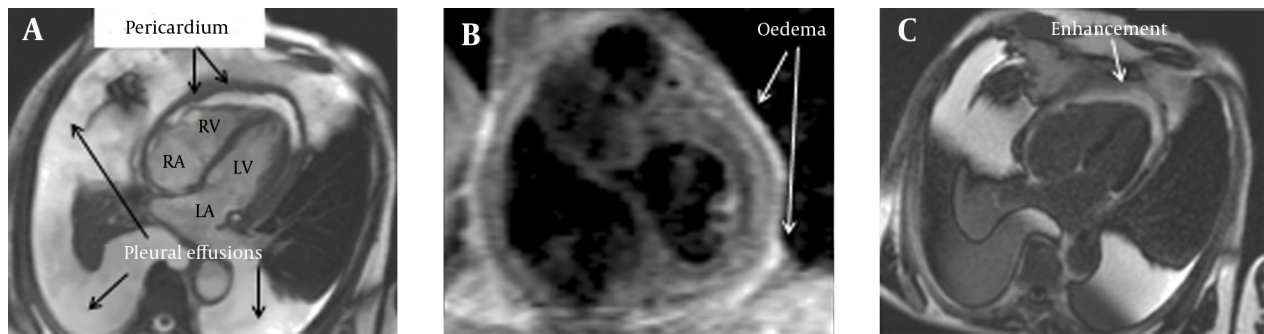
1. Introduction

Constrictive pericarditis was first described by Lower in 1669 (1) and is characterized by constriction of the heart secondary to pericardial inflammation. Common causes include repeated pericarditis, previous cardiac surgery and radiation therapy. However, less commonly, it can be caused by tuberculosis particularly in sub-Saharan Africa and parts of Asia (2), neoplasms, autoimmune disorders or uraemia. Here, we report a rare cause of constrictive pericarditis of tuberculous etiology in an immunocompetent patient, where the diagnosis was reached with the help of cardiovascular magnetic resonance imaging (CMR).

2. Case Presentation

A 77-year-old man originating from a country with high incidence of tuberculosis, presented with severe increasing dyspnea to our institution. Echocardiography revealed a small left ventricle (LV) with normal systolic but mildly impaired diastolic function. Trans-mitral and trans-tricuspid Doppler demonstrated variations in LV and right ventricular (RV) filling, respectively, of 30%. The peak E and A velocities were 43.8 and 51.5 cm/s, respectively, resulting in an E/A ratio of 0.9. Tissue Doppler measurements demonstrated E' septal velocity of 6.0 cm/s and E' lateral velocity of 7.7 cm/s. These findings were suggestive of pericardial constriction with a restrictive component, however it had not been pos-

sible to identify the aetiology. Left heart catheterization revealed non-obstructive coronary artery disease, which was not felt significant to explain the degree of breathlessness. Cardiovascular magnetic resonance imaging (CMR) was performed three days later and showed a small LV with mildly impaired ejection fraction and normal indexed mass. This study also demonstrated global, severely thickened pericardium (maximum thickness of 13 mm, normal < 3 mm), comprising of both pericardial thickening and a small effusive component along the lateral aspect of the LV and large bilateral pleural effusions (Figure 1A). Short tau inversion recovery (STIR) sequences showed increased signal intensity and imaging in the late phase after administration of the paramagnetic contrast agent gadolinium confirmed enhancement in the pericardium (Figure 1B and C), both suggesting pericardial inflammation. Furthermore, there was marked septal flattening on inspiration and ventricular septal bounce consistent with constrictive physiology (Supplementary Video 1). These findings strongly supported the diagnosis of constrictive pericarditis most likely of a tuberculous etiology. The patient passed away shortly after the CMR and histology demonstrated fibrotic pericardium, accompanied by chronic inflammation with numerous epithelioid granulomas and marked central caseous necrosis, confirming mycobacterial infection.

Figure 1. Cardiovascular Magnetic Resonance Imaging

A, Demonstrating significant bilateral pleural effusion and pericardial thickening (13 mm). B, Short tau inversion recovery sequences (fat suppression) showing increased pericardial edema, suggestive of inflammation. C, Delayed gadolinium enhancement was observed for the pericardium, in keeping with pericardial inflammation. These images are consistent with constrictive pericarditis with a tuberculous origin later confirmed by histology.

Video 1: To see the video, refer to article's online version.

3. Discussion

Constrictive pericarditis is characterized by constriction of the heart secondary to pericardial inflammation. Common causes include repeated pericarditis, previous cardiac surgery and radiation therapy (3). Less commonly it can be caused by tuberculosis (TB) particularly in sub-Saharan Africa and parts of Asia (2) and patients with tuberculous pericarditis often have concomitant human immunodeficiency virus (HIV) infection (4). Our patient did not have HIV, but it is interesting to note that HIV can alter the natural history, progression and outcomes of tuberculous pericarditis. Immunocompromised patients appear less likely to develop constrictive pericarditis but nonetheless have a significantly higher mortality compared with their immunocompetent counterparts (5). Tuberculous pericarditis represents a form of extrapulmonary tuberculosis and remains unusual in the Western world. Other causes of constrictive pericarditis include neoplasms, autoimmune disorders and uraemia. Constriction causes impaired diastolic filling, in turn producing three important effects (3).

First, there is dissociation between intra-thoracic and intra-cardiac pressures. The pressure gradient between the pulmonary veins and the left atrium is decreased, impairing left sided diastolic filling and trans-mitral flow. Secondly, there is increased inter-ventricular dependence; during inspiration, decreased left ventricular filling induces increased right ventricular filling, causing a right-to-left septal shift, and increases in the tricuspid inflow E velocity and hepatic vein diastolic forward velocity. The opposite occurs with expiration. Finally, increased cardiac filling pressures with pressure equalization in all four cardiac chambers occur.

These functional consequences can be assessed by multiple modalities (6):

Echocardiography may show a restrictive physiology pattern, including an increased early (E) to late (A) ra-

tio of mitral filling velocities of greater than 0.8 with a preserved or raised diastolic mitral annular relaxation velocity (e'), plethoric inferior vena cava and flat Doppler profile in the superior vena cava (6). In contrast, cardiac catheterization with hemodynamic pressure waveform monitoring may reveal respiratory discordance of simultaneous left and right ventricular systolic pressures. This is reflected by an increase in systolic area index, which is defined as the ratio of right ventricular to left ventricular systolic area in inspiration versus expiration (7). Moreover, cardiac computed tomography can show a thickened and calcified pericardium as well as dilated suprahepatic inferior vena cava both supporting constriction. It can also be used to exclude other causes of hypertension and right heart failure and in particular acute or chronic pulmonary thrombo-embolism as well as potential neoplastic lesions responsible for the constriction.

Finally, CMR imaging is useful for addressing the challenges of confirming a diagnosis of constrictive pericarditis by both visualizing the thickened pericardium and also allowing via free breathing sequences to look for ventricular septal flattening on inspiration suggesting constrictive physiology (8). CMR can also detect rare complications of tuberculous pericarditis such as left ventricular pseudo-aneurysms (9). CMR can additionally be used to exclude other causes of right heart failure, such as pulmonary hypertension or myocardial infarction. It can determine whether the pericardium is causing constriction and may differentiate it from restrictive cardiomyopathy, which also causes impaired cardiac filling (10). This distinction is crucial as constrictive pericarditis can be successfully treated by early pericardiectomy (11) (with medical therapy showing no benefit over placebo (2)), whereas the optimal treatment for restrictive cardiomyopathy is medical therapy (12).

Findings favouring the diagnosis of constrictive pericarditis include increased pericardial thickening, oedema, active inflammation and fibrosis. Nevertheless, pericardial thickening per se does not necessarily imply

pericardial constriction (13) and constrictive pericarditis can occur despite normal pericardial thickness (14). During CMR, STIR sequences allowed detection of pericardial inflammation, as did late gadolinium enhancement (LGE). The latter has been previously described in tuberculous constrictive pericarditis (15) and subsequently associated with fibroblastic proliferation, chronic inflammation and neovascularization (16). The presence of inflammation is clinically important because such patients may benefit from non-steroidal anti-inflammatory drug (NSAID) therapy and the constrictive pericarditis observed may be reversible (16).

A restrictive physiology of increased early diastolic filling and absent late filling can be demonstrated using velocity-coded phase contrast CMR; septal bounce due to respiration-related variations in cardiac filling can be observed in bright blood cine images, whereas ventricular inter-dependence can be evaluated using real-time cine sequences (17). The nature of any pericardial fluid present can also be determined using CMR; a transudate shows low signal intensity during T1-weighted spin-echo sequences but high signal intensity in T2-weighted sequences. In contrast, an exudate shows high intensity during T1 but low intensity during T2 sequences. Adherence of the pericardium to the underlying myocardium can be confirmed by tagging (18).

Despite a significant decline in the TB seen in wealthier industrialized countries in the last century, the estimated number of new TB cases has increased steadily to over 10 million in 2005 (19). Tuberculous pericarditis is caused by *Mycobacterium tuberculosis* and can be found in up to 1% of the autopsied cases of patients with TB, and up to 2% of the cases of pulmonary TB. Without treatment mortality exceeds 90% whereas anti-tuberculous therapy, usually in the form of rifampicin, isoniazid, pyrazinamide, and ethambutol for at least two months, followed by isoniazid and rifampicin for another four months, is highly effective in treating patients with extra-pulmonary TB and can reduce the mortality to under 20% in immunocompetent individuals and ~30% in HIV-infected patients. Reaching the correct diagnosis is therefore crucial in initiating appropriate therapy. Constrictive pericarditis is the most serious sequel of tuberculous pericarditis and management involves prompt initiation of anti-tuberculous therapy and appropriate timing of pericardiectomy for selected patients who have failed to respond to medical therapy (19).

In summary, diagnostic evaluation of constrictive pericarditis is important and can direct correct management. Appropriate evaluation requires a multi-modality approach and suspected patients would benefit from simple tests such as echocardiography but also further, more complex imaging, including CT and CMR. CMR can be particularly useful as it can demonstrate cardiac morphology and structures to a high resolution. It further enables the detection of pericardial thickening and inflammation, adhesion of the pericardium to the myo-

cardium, ventricular coupling and cardiac filling as well as characterisation of any pericardial fluid. We therefore recommend that CMR should be considered early, if resources allow, for all patients with strong suspicion of constrictive pericarditis, as it can confirm its diagnosis, help identify the aetiology and guide appropriate management.

Financial Disclosure

Sanjay Prasad has received honoraria for talks from Bayer. No other authors have any conflict of interest.

Funding/Support

This work was supported by NIHR Cardiovascular Biomedical Research Unit of Royal Brompton & Harefield NHS Foundation Trust and Imperial College London.

References

1. Lower R. *Treatment of Heart [in Latin]*. London: Allestry; 1669.
2. Mayosi BM, Ntsekhe M, Bosch J, Pandie S, Jung H, Gumedze F, et al. Prednisolone and *Mycobacterium indicus pranii* in tuberculous pericarditis. *N Engl J Med*. 2014;**371**(12):1121–30.
3. Myers RB, Spodick DH. Constrictive pericarditis: clinical and pathophysiologic characteristics. *Am Heart J*. 1999;**138**(2 Pt 1):219–32.
4. Mayosi BM, Wiysonge CS, Ntsekhe M, Volmink JA, Gumedze F, Maartens G, et al. Clinical characteristics and initial management of patients with tuberculous pericarditis in the HIV era: the Investigation of the Management of Pericarditis in Africa (IMPI Africa) registry. *BMC Infect Dis*. 2006;**6**:2.
5. Ntsekhe M, Mayosi BM. Tuberculous pericarditis with and without HIV. *Heart Fail Rev*. 2013;**18**(3):367–73.
6. Welch TD, Oh JK. Constrictive pericarditis: old disease, new approaches. *Curr Cardiol Rep*. 2015;**17**(4):20.
7. Talreja DR, Nishimura RA, Oh JK, Holmes DR. Constrictive pericarditis in the modern era: novel criteria for diagnosis in the cardiac catheterization laboratory. *J Am Coll Cardiol*. 2008;**51**(3):315–9.
8. Bogaert J, Francone M. Cardiovascular magnetic resonance in pericardial diseases. *J Cardiovasc Magn Reson*. 2009;**11**:14.
9. Wei W, Hui C, Sheng-Yu W, Xin D. Uncommon cause of left ventricular pseudoaneurysm: case report and review of literature. *Thorac Cardiovasc Surg*. 2014;**62**(4):375–7.
10. Troughton RW, Asher CR, Klein AL. Pericarditis. *Lancet*. 2004;**363**(9410):717–27.
11. Ling LH, Oh JK, Schaff HV, Danielson GK, Mahoney DW, Seward JB, et al. Constrictive pericarditis in the modern era: evolving clinical spectrum and impact on outcome after pericardiectomy. *Circulation*. 1999;**100**(13):1380–6.
12. Mookadam F, Jiamsripong P, Raslan SF, Panse PM, Tajik AJ. Constrictive pericarditis and restrictive cardiomyopathy in the modern era. *Future Cardiol*. 2011;**7**(4):471–83.
13. Nishimura RA. Constrictive pericarditis in the modern era: a diagnostic dilemma. *Heart*. 2001;**86**(6):619–23.
14. Talreja DR, Edwards WD, Danielson GK, Schaff HV, Tajik AJ, Tazelaar HD, et al. Constrictive pericarditis in 26 patients with histologically normal pericardial thickness. *Circulation*. 2003;**108**(15):1852–7.
15. Ha JW, Ko YG, Choi BW. Images in cardiology. Delayed hyperenhancement of the pericardium by magnetic resonance imaging as a marker of pericardial inflammation in a patient with tuberculous effusive constrictive pericarditis. *Heart*. 2006;**92**(4):494.
16. Zurick AO, Bolen MA, Kwon DH, Tan CD, Popovic ZB, Rajeswaran J, et al. Pericardial delayed hyperenhancement with CMR imaging in patients with constrictive pericarditis undergoing surgical pericardiectomy: a case series with histopathological correlation. *JACC Cardiovasc Imaging*. 2011;**4**(11):1180–91.
17. Anavekar NS, Wong BF, Foley TA, Bishu K, Kolipaka A, Koo CW, et al.

- Index of biventricular interdependence calculated using cardiac MRI: a proof of concept study in patients with and without constrictive pericarditis. *Int J Cardiovasc Imaging*. 2013;**29**(2):363-9.
18. Kojima S, Yamada N, Goto Y. Diagnosis of constrictive pericarditis by tagged cine magnetic resonance imaging. *N Engl J Med*. 1999;**341**(5):373-4.
19. Mayosi BM, Burgess LJ, Doubell AF. Tuberculous pericarditis. *Circulation*. 2005;**112**(23):3608-16.

Archive of SID