

# The Spine Vertebral Bodies 3D Modeling and its Biomechanical Advantages

Amir Hossein Saveh<sup>1</sup>, Ali Reza Zali<sup>1</sup>, Farzad Ashrafi<sup>1</sup>, Sohrab Shahzadi<sup>1</sup>, Afsoun Seddighi<sup>1</sup>, Sirous Momenzadeh<sup>1</sup>, Behdad Behnam<sup>1</sup>, Omid Dehpour<sup>2</sup>, Mahmoud Chizari<sup>3</sup>, Kazuyoshi Gammada<sup>4</sup>

<sup>1</sup> Functional Neurosurgery Research Center, Shahid Beheshti University of Medical Sciences, Tehran, Iran

<sup>2</sup> Islamic Azad University, Scientific and Research Branch, Tehran, Iran

<sup>3</sup> School of Design and Engineering, Brunel University West London, UK

<sup>4</sup> Medical Engineering and Technology, Graduate School of Medical Technology and Health Welfare Sciences, Hiroshima, Japan

## ABSTRACT

To perform an accurate approach to the spine specially for fracture stabilization a 3D model of spine surgical region may improve this mechanism and it can help the surgeon to have a deeper glance to this scenario. The pre-op planning facility is another advantage of the patient spine specific model to take a chance of making guides to direct pedicle screws safely and increase the pathomechanics of volumes of interest stability factor parallel with its mobility restoration. There are some algorithms for making 3D-reconstruction from CT or MR data-set but the main goal of in-vivo component 3D making is right component extraction from its peripheral segments to achieve the best judgment especially about the surgical approach. Here is a cervical vertebral bodies segmentation and 3D-reconstruction of two cervical adjacent levels combined with the registration process that is shown the intervertebral degree regarding to range of motion percent.

**Keywords:** Spine; Vertebral Body; Registration; Fluoroscopy

ICNSJ 2015; 2 (1):23-25

www.journals.sbm.ac.ir/neuroscience

**Correspondence to:** Amir Hossein Saveh; Functional Neurosurgery Research Center, Shahid Beheshti University of Medical Sciences, Tehran, Iran; E-Mail: saveh@aut.ac.ir

Received: February, 8, 2015

Accepted: February, 23, 2015

## INTRODUCTION

The cervical spine can be divided and perceived as consisting of four units, each with a unique Morphology that determines its kinematics and its contribution to the functions of the complete cervical spine<sup>1</sup>. Functional flexion– extension radiography is the most widely used method in clinical diagnosis of lumbar spinal instability; how-ever, it is limited to few, end-of-range spinal positions, while in-between intervertebral motion is disregarded<sup>2</sup>.

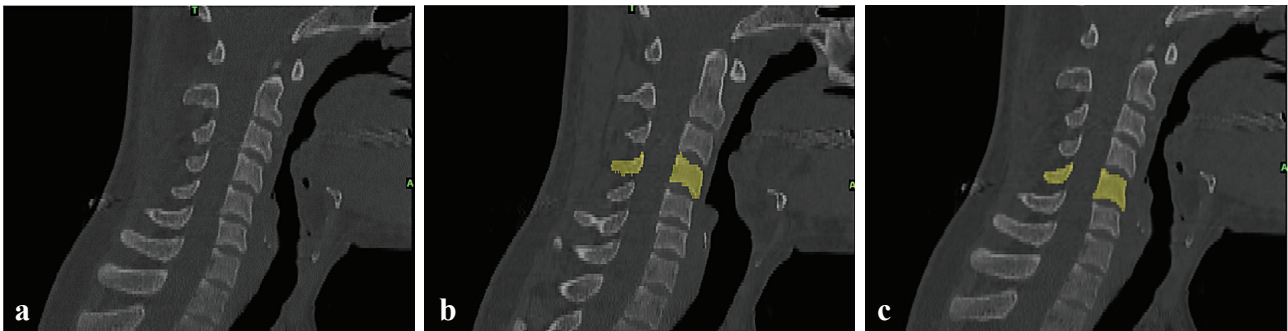The mechanical effects of arthrodesis and disc arthroplasty on adjacent segments are often evaluated by in vitro testing of cervical specimens and finite element models derived from in vitro tests. The preferred in vitro testing protocol is one that most closely follows the in vivo kinematic pattern for all segments of the cervical

spine<sup>3</sup>. Most previous work examined neck mobility by assessing the cervical spine as an isolated entity without any consideration of the adjacent region of the spine i.e. the thoracic spine<sup>4</sup>.

## MATERIAL AND METHODS

According to CT dataset the segmentation of the two C4 and C5 vertebral bodies of a 34 years old male with a mild pain in his cervical region performed as it is shown in Figure 1 (a,b,c) Mimics 10.1 software (Materialise NV) then the fluoroscopic imaging is achieved by angio-fluoroscopic unit at CATLAB when the patient is doing flexion-extension. Three-dimensional imaging system could be helpful for a better in vivo investigation of cervical spine 3D<sup>5</sup>.

After taking the fluoroscopic frames then C4 and C5 3D



**Figure 1.** (a) The CT-Data Set of the spine, (b) C-4 is segmented from other cervical vertebral bodies, (c) C-5 is segmented.

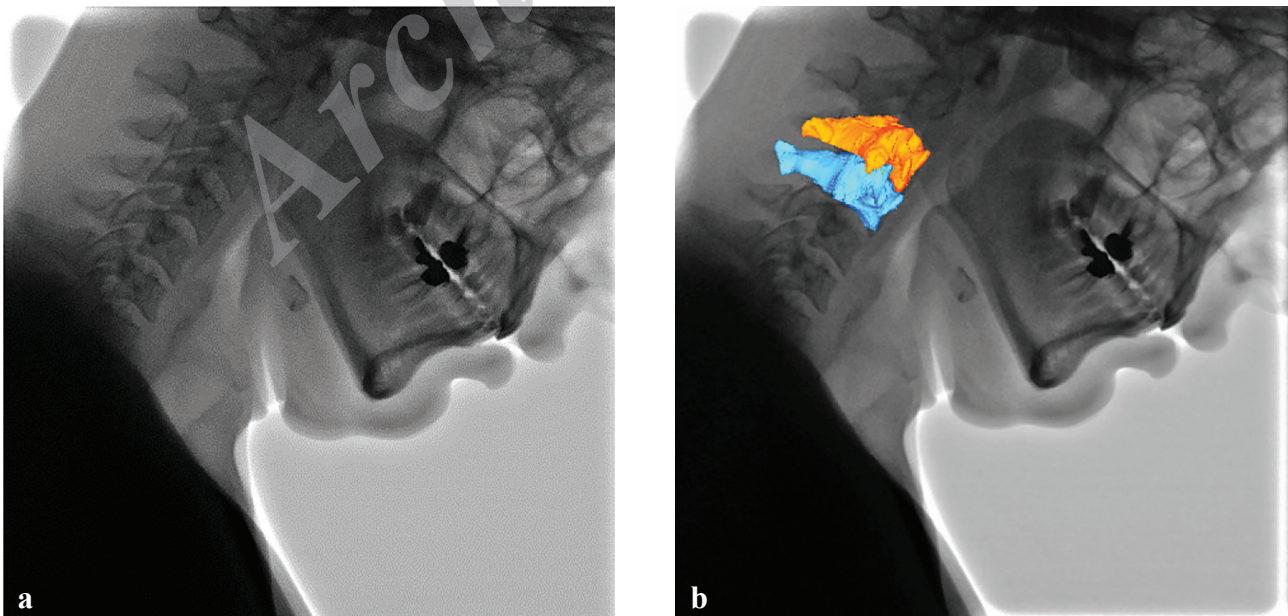
models are registered by 2D-To-3D registration technique on fluoroscopic frames as it is shown in Figure 2 (a,b). Three-dimensional (3D) joint kinematics analysis of the spine could supply information such as location and orientation of instantaneous axis of movement. Indeed, previous studies investigating cervical kinematics mainly used 2D analysis for describing joint displacement and motion axis location<sup>6,7</sup>.

As it is known that one of the most important reasons of cervical spine surgery is the motion restoration especially in disk pathomechanic surgical correction then it may be a proper index to achieve the C4/C5 inter-vertebral angle during flexion-extension to assess the cervical pathomechanics improvement in post-ops compared with pre-ops. Several studies have been carried out to evaluate the load-displacement properties of the normal lower cervical spine in vitro and in vivo as well as in different types of artificial defect situations<sup>8</sup>.

Cervical spine kinematics in the sagittal plane have traditionally been determined during static full-flexion and full-extension radiographs. However, measurements made using static, end range positions may not accurately represent dynamic behavior, and these images provide no information regarding mid-range motion that is most often encountered during activities of daily living<sup>9</sup>. Accurate measurement of the coupled intervertebral motion patterns is helpful for characterizing the geometric changes of the intervertebral discs for manual therapists in managing relevant clinical problems for assessing the effects of surgical fusion on motions of adjacent vertebrae and for evaluating various surgical approaches<sup>10</sup>.

## RESULTS

The C4/C5 angle during head flexion-extension is achieved according to range of motion percent and it is shown the curve as it is seen in Figure 3, involving



**Figure 2.** (a) The Fluoroscopic frame of flexion-extension, (b) C4 and C5 vertebral bodies registered on fluoroscopic frame.

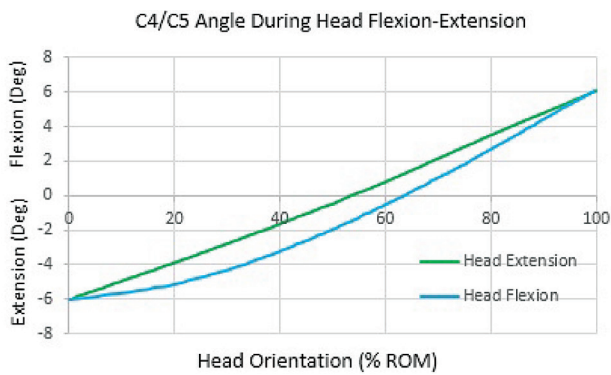


Figure 3. C4/C5 intervertebral angle during flexion-extension.

two pairs one is shown the head flexion and another is shown the extension.

The compound graph is shown that the flexion curve is different from extension despite that the path is the same.

## DISCUSSION

There are numerous reports in the literature documenting patients with a normal neutral position lateral projection radiograph of the cervical spine in whom a flexion radiograph demonstrated a hyperflexion subluxation injury. For this reason, a growing number of emergency departments are performing flexion/extension studies on selected spine trauma patients<sup>6</sup>. According to Figure 3 the intervertebral C4/C5 angle for the patient with pain in his flexion-extension ROM is identified as this curve and if it is compared with the normal case may identify the pathomechanical signs regarding to normal condition.

## REFERENCES

1. Bogduk N, Mercer S. Biomechanics of the cervical spine. I: Normal kinematics. *Clin Biomech (Bristol, Avon)*. 2000 Nov;15(9):633-48.
2. Bifulco P; Cesarelli M; Cerciello T; Romano M. A continuous description of intervertebral motion by means of spline interpolation of kinematic data extracted by videofluoroscopy. *J Biomech* 2012 Feb 23;45(4):634-41.
3. Anderst WJ, Donaldson WF 3rd, Lee JY, Kang JD. Continuous cervical spine kinematics during in vivo dynamic flexion-extension. *Spine J*. 2014 Jul 1;14(7):1221-7.
4. Tsang SM, Szeto GP, Lee RY. Normal kinematics of the neck: the interplay between the cervical and thoracic spines. *Man Ther*. 2013 Oct;18(5):431-7.
5. Barrey C, Champain S, Campana S, Ramadan A, Perrin G, Skalli W. Sagittal alignment and kinematics at instrumented and adjacent levels after total disc replacement in the cervical spine. *Eur Spine J*. 2012 Aug;21(8):1648-59.
6. Bohrer SP, Chen YM, Sayers DG. Cervical spine flexion patterns. *Skeletal Radiol*. 1990;19(7):521-5.
7. Dugailly PM, Sobczak S, Sholukha V, Van Sint Jan S, Salvia P, Feipel V, et al. In vitro 3D-kinematics of the upper cervical spine: helical axis and simulation for axial rotation and flexion extension. *Surg Radiol Anat*. 2010 Feb;32(2):141-51.
8. Richter M, Wilke HJ, Kluger P, Claes L, Puhl W. Load-displacement properties of the normal and injured lower cervical spine in vitro. *Eur Spine J*. 2000 Apr;9(2):104-8.
9. Anderst WJ, Donaldson WF, Lee JY, Kang JD. Cervical spine intervertebral kinematics with respect to the head are different during flexion and extension motions. *J Biomech*. 2013 May 31;46(8):1471-5.
10. Lin CC, Lu TW, Wang TM, Hsu CY, Hsu SJ, Shih TF. In vivo three-dimensional intervertebral kinematics of the subaxial cervical spine during seated axial rotation and lateral bending via a fluoroscopy-to-CT registration approach. *J Biomech*. 2014 Oct 17;47(13):3310-7.