

Cerebral Venous Sinus Thrombosis after Submandibular Abscess: A Case Report

Reza Taherian¹, Elham Gharib²

¹ Students' Research Office, School of Medicine, Shahid Beheshti University of Medical Sciences, Tehran, Iran

² School of Medicine, Semnan University of Medical Sciences, Semnan, Iran

ABSTRACT

Infection-related cerebral venous sinus thrombosis (CVST) is a rare cerebral vascular diseases which has no pathognomonic sign or definite diagnostic approach. It is crucial to early suspect and recognize the disease to lower morbidity and mortality of it. However, its low incidence and atypic presentation often leads to misdiagnosis and treatment delay which increase complications and mortality of septic CVST. The patient of this study is a 26-year-old man presented with complaint of agitation, ataxia, weakness and confusion three weeks after abscess drainage. On examination, right abducent nerve palsy, bilateral papilledema, left eye vision loss (hand motion at 1 meters), right hemiparesis, right central facial hemiparesis and fever (T: 38.4) were noted. Magnetic resonance imaging and venography was performed which showed CVST with left occipital lobe infarction. The patient received antibiotics and his symptoms and signs subsided gradually.

Keywords: Cerebral venous sinus thrombosis; Submandibular abscess; Occipital infarction

ICNSJ 2016; 3 (1):47-49

www.journals.sbmu.ac.ir/neuroscience

Correspondence to: Reza Taherian; Students' Research Office, School of medicine, Shahid Beheshti University of Medical Sciences, Tehran, Iran; Tel: +98 (912) 331 4094; Email: Taherian.reza72@gmail.com

Received: May 2016

Accepted: Jun 2016

INTRODUCTION

Cerebral venous sinus thrombosis (CVST) is a potentially fatal disease if passed unrecognized or its treatment delay. The incidence of this disorder is quiet rare, however, extensive use of magnetic resonance imaging (MRI) may has increased diagnosis of this disease in recent years. Although the majority of cases of CVST are due to non-infectious causes, septic thrombosis is still a potential fatal etiology which need early diagnosis and emergency treatment¹. The infection often spreads from adjacent structures. For example, cavernous sinus thrombophlebitis is the results of spread of infection from sphenoid and ethmoid sinuses and lateral sinus thrombophlebitis is a result of spread of infection from mastoid. Besides, infection of other sites such as tonsil, teeth, nose, face, soft palate and ears may cause thrombophlebitis in lateral, cavernous or

other sinuses. The most severe complication of CVST is cerebral infarction as well as pseudotumor cerebri. Cerebral infarctions are often bilateral, multifocal with involvement of both subcortical grey and white matters². Septic CVST includes both venous thrombosis and abscess and may be associated with epidural abscess. Subdural empyema or a bacterial meningitis. A septic SCVT is rarely caused by metastatic spread of infection³.

CASE PRESENTATION

The patient was a 26-year-old man who presented to our hospital with complaint of agitation, ataxia, weakness and confusion. His family mentioned that he have had headache, nausea, vomiting, agitation and alteration in mental status since one week ago. His past medical history showed submandibular abscess surgery two weeks ago. There was no history of seizure and bowel

or bladder incontinency. On admission, his vital signs were as follows: PR: 93, BP: 110/70, RR: 16, T: 38.4. General physical examination revealed no abnormalities except cervical spine tenderness and neck movement limitation. On neurological examination, he was confused and his verbal communication was impaired. Lower and upper extremity muscle force, tendon reflex and sensory examination were normal. Signs of meningeal irritation such as kernig and brudzinski signs were positive. In the next day, new signs were revealed including right abducent nerve palsy, bilateral papilledema, left eye vision loss (hand motion at 1 meters), right hemiparesis and right central facial hemiparesis. In laboratory tests, blood sugar, urea nitrogen, electrolytes and creatinine were all in normal limits. ESR: 95, CRP 3+ and WBC: 16000 were noted.

Since the electro-encephalography and CT-scan were normal, MRI was requested. In MRI, infarction of left occipital lobe was observed (Figure 1). In magnetic resonance venography (MRV), thrombosis of left lateral venous sinus was revealed (Figure 2).

Since the non-infectious causes of CVST such as diabetes, anti-thrombin III deficiency as well as C and S proteins deficiency were evaluated in this patient and

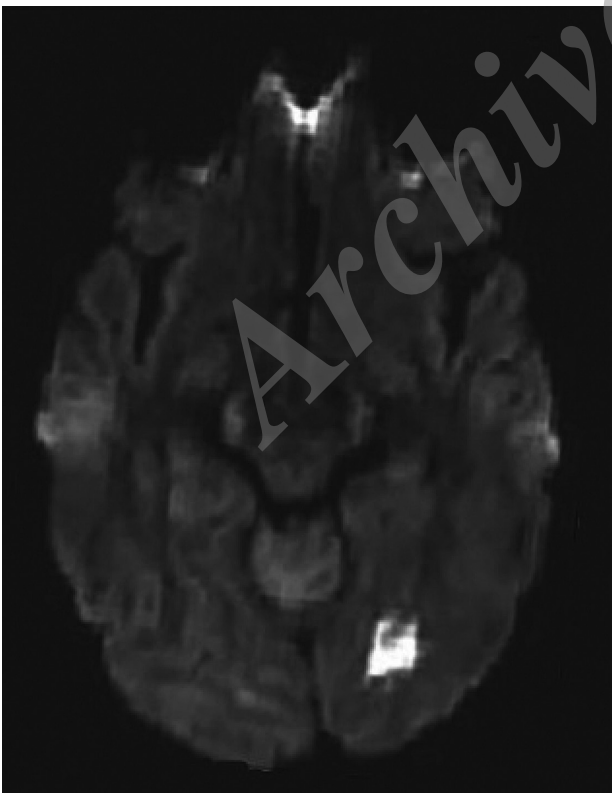

Figure 1. A hypersignal lesion is evident in the left occipital lobe which is the infarction.

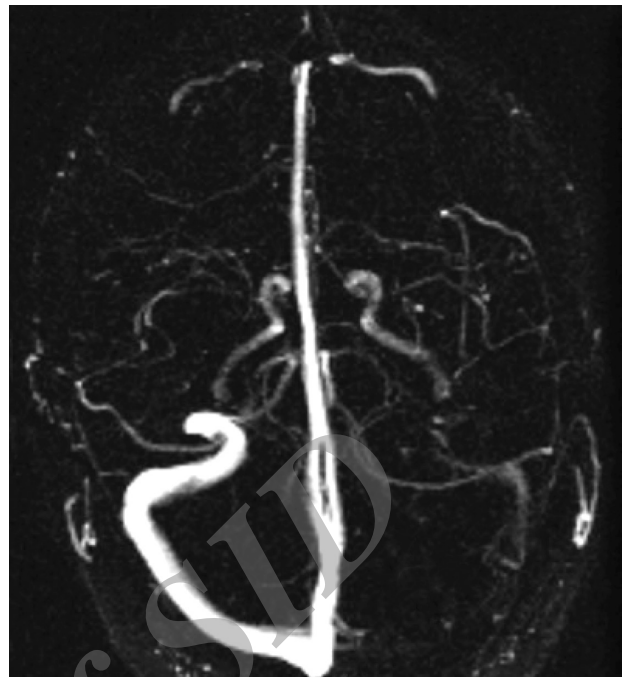


Figure 2. Thrombosis of left lateral venous sinus.

all were negative, patient received antibiotic therapy, i.e. ceftriaxone, vancomycin and metronidazole, and mannitol. Two weeks after the beginning of antibiotic therapy, the patient's symptoms and signs subsided gradually and he was discharged with a good general state.

DISCUSSION

The cerebral and emissary veins and dural sinuses have no valve. This causes these venous systems to be vulnerable to spread of infection from adjacent structures which eventually causes a septic CVST⁴. Hence, the septic CVST may be complication of an epidural or subdural abscess, meningitis or an infection spread through extracranial veins. Antibiotics can efficiently prevent this complication in patients with infections of the mentioned areas. Staphylococcus aureus, streptococcus and E.coli are the main pathogens of septic CVST⁵.

Laboratory test are usually not diagnostic in septic CVST. In cerebrospinal fluid (CSF) examination, mild pleocytosis and elevated CSF protein may be observed. In patients with a progressive disease, the result of blood culture may be positive. MRI is the best non-invasive diagnostic method for septic CVST. Focal cerebral edema with its contrast enhancement is probably seen on MRI of a patient with CVST. Both MRI and MRV can show cerebral angiographic pattern and thrombosis. Although high-resolution CT scan (HRCT) has lower sensitivity

and specificity compared to MRI, it may be used as an alternative imaging in diagnosis of venous sinuses thrombosis, with or without contrast. Moreover, MRI and CT can evaluate the paranasal sinuses, epidural or subdural infections, cerebral infarctions, cerebritis, cerebral hemorrhage or edema.

Before the introduction and widespread use of antibiotics, septic CVST had an about 90% mortality rate. However, using antibiotics, this rate has declined dramatically. Selecting suitable antibiotics for treating septic CVST depends on the clinical conditions of the patient and the primary site of the infection⁶. An empirical regimen may include vancomycin, metronidazole and cephalosporin (third or fourth generation). This medication should be continued for about one month. If the medication was not be effective, surgical thrombectomy may be applied. Using anticoagulants is controversial⁷ and some previous studies reject using anticoagulants in patients with septic lateral or superior sagittal sinuses thrombosis due to the high rate of the consequent venous hemorrhagic infarction⁸. Due to the risk of recurrence in six weeks after treatment or intracranial abscess after 8 months, the patients should be followed up for one year.

Disclosure statement

The authors have nothing to disclose.

REFERENCES

1. Kojan S, Al-Jumah M. Infection related cerebral venous thrombosis. *JOURNAL-PAKISTAN MEDICAL ASSOCIATION*. 2006;56(11):494.
2. Stam J. Thrombosis of the cerebral veins and sinuses. *New England Journal of Medicine*. 2005;352(17):1791-8.
3. Bousser M-G, Ferro JM. Cerebral venous thrombosis: an update. *The Lancet Neurology*. 2007;6(2):162-70.
4. Skeik N, Stark MM, Tubman DE. Complicated cerebral venous sinus thrombosis with intracranial hemorrhage and mastoiditis. *Vascular and endovascular surgery*. 2012;46(7):585-90.
5. Syms MJ, Tsai PD, Holtel MR. Management of lateral sinus thrombosis. *The Laryngoscope*. 1999;109(10):1616-20.
6. Medel R, Monteith SJ, Crowley RW, Dumont AS. A review of therapeutic strategies for the management of cerebral venous sinus thrombosis. *Neurosurgical focus*. 2009;27(5):E6.
7. Ferro JM, Canhão P. Cerebral venous sinus thrombosis: update on diagnosis and management. *Current cardiology reports*. 2014;16(9):1-10.
8. Bhatia K, Jones N. Septic cavernous sinus thrombosis secondary to sinusitis: are anticoagulants indicated? A review of the literature. *The Journal of Laryngology & Otology*. 2002;116(09):667-76.