

Outcomes of Phosphorus-32 Intracavitary Irradiation for Craniopharyngiomas: A Review of the Literature

Parisa Azimi¹, Sohrab Shahzadi¹, Ali Montazeri²

¹Department of Neurosurgery, Shahid Beheshti University of Medical Sciences, Tehran, Iran.

²Mental Health Research Group, Health Metrics Research Centre, Iranian Institute for Health Sciences Research, ACECR, Tehran, Iran.

ABSTRACT

Purpose: To review on outcomes of Phosphorus-32 (³²P) intracavitary irradiation for Craniopharyngiomas.

Methods: A literature review of all full publications in English biomedical journals (1981-2014) was performed. The search strategy included a combination of key words “phosphorus-32”, “craniopharyngioma”, “intracystic treatment”, “brain”, “cyst”, “tumor”, “brachytherapy”, “intracavitary irradiation”, “isotope” in the title and abstract of the manuscripts using the PubMed. The major findings were summarized, with a focus on outcome as visual acuity, complications, cyst volume, and irradiation dose delivered to the cyst wall in Gy. Finally, the future of ³²P intracavitary irradiation for Craniopharyngiomas was explored.

Results: A total of 25 citations were identified and screened. In all, 19 citations were eligible for inclusion. The synthesis of the data showed several benefits and adverse events for ³²P intracavitary. Overall benefits included improvements in visual, endocrinological, and neurological outcomes, while adverse effects included complications such as III palsy and diabetes insipidus.

Conclusion: In general ³²P intracavitary irradiation was found to be a reasonable option in treatment of highly selected patients with newly diagnosed or recurrent cystic craniopharyngioma. This approach can be expected to overcome some limitations introduced by other approaches with a relatively low complication rates.

Keywords: Phosphorus-32; Craniopharyngiomas; Review; Outcomes

ICNSJ 2016; 3 (1):7-24

www.journals.sbmu.ac.ir/neuroscience

Correspondence to: Functional Neurosurgery Research Center of Shohada Tajrish Hospital, Shahid Beheshti University of Medical Sciences, Sharadari St., Tajrish Square, Tehran 1989934148, Iran; Tel: 98-2122749204; Fax: +98-2188265188; E-mail: parisa.azimi@gmail.com

Received: Feb 2016

Accepted: Feb 2016

INTRODUCTION

Craniopharyngioma is a cyst brain tumor that develops near the pituitary gland. It is more common among children and young adults and constitutes approximately 10% of all brain cysts in young people¹. However, it can be found in people of any age. Craniopharyngiomas are almost always histologically benign (World Health Organization grade I), but can cause compressing or infiltrating of the surrounding structures, such as the optic chiasm, hypothalamus, and the floor of the third ventricle²⁻³.

The most common symptoms are visual disturbances and endocrine deficiencies⁴. The three most commonly applied treatment choices include complete excision of the tumor surgically, partial removal followed by radiation therapy or Stereotaxic intracavitary irradiation (brachytherapy). Benign lesions in the brain could be cured if amenable to total or partial surgical resection, although gross total resection of craniopharyngioma is not always curative and may be associated with significant additional morbidities². Stereotaxic intracavitary irradiation

(brachytherapy) using beta and gamma radiation-emitting radionuclides remain treatment modality for this challenging disorder. For the first time in 1967 Leksell, et al. described Stereotaxic intracavitary irradiation of cystic craniopharyngiomas using Phosphorus-32 (^{32}P) chromic phosphate⁵. Subsequent application of this technique using a variety of different beta and gamma radiation-emitting isotopes such as rhenium-186 (^{186}Re), yttrium-90 (^{90}Y) and gold-198 (^{198}Au) has been described by a number of authors⁶⁻⁷. However, ideal radionuclides for internal irradiation must have a short half-life, easy clinical applicability, and be a pure beta emitter⁵.

Although individual studies showed benefits for phosphorus-32 intracavitary irradiation for treating craniopharyngiomas, we were interested to investigate on overall results that are benefits and adverse effects. Thus, the main purpose of this review was to evaluate benefits and adverse outcomes of phosphorus-32 intracavitary irradiation for treating patients with CPs. It was hoped the findings from this review could help clinicians to make right decision for improved patients' safety and health status.

MATERIAL AND METHODS

A brief introduction to treatment of cystic CPs with ^{32}P intracavitary irradiation

Instillation of isotopes such as ^{32}P directly within cystic portions is a treatment of choice for patients with CPs. A multi-disciplinary team of neurosurgeons, radiation oncologists, and radiation physicists should perform the treatment. The treatment includes two main procedures: aspiration of the cyst fluid, and ^{32}P injection. The localization of the cysts will be determined using stereotactic techniques. The cyst volume should be estimated based on preoperative CT or MRI and the treating contoured cyst cavity will be indicated by radiation therapy treatment planning systems as GammaPlan in order to find out the dose needed for a given patient. Then, a solution (the ^{32}P colloidal phosphate/saline) should be prepared for injection based on the cyst volume. In fact the ^{32}P colloidal phosphate/saline solution should meet the appropriate concentration of ^{32}P and the solution typically diluted with saline⁸, with appropriate activity volume. The required activity could be calculated by several approaches. As such some investigators suggested that the required activity should assume uniform distribution of the colloid in the cyst and a dose of typically 300 Gy to the cyst wall using the following formula to calculate the actual activity: $[0.1365(\text{Dose in Gy}) \times \text{vol}(\text{ml})] / 0.455$ ⁸. Consequently a skull opening must be made

for either the placement of a semi-permanent tube into the cyst or to provide an avenue for the direct injection of the ^{32}P into the cyst⁹. In order to determine whether there is any possible leakage of the ^{32}P to the outside of the target cyst, bremsstrahlung scanning of the target cyst is recommended by single photon emission computed tomography (SPECT) equipment in intervals up to the third day of post-instillation. Then, clinical follow-up visit is needed. The shrinkage of the cyst and relaxation of symptoms/signs are both should be considered for evaluating the effectiveness of the treatment. The effectiveness could be assured if the cyst size is considerably shrunk based on the WHO standard¹⁰. The benefits of treatment of cystic CPs with ^{32}P intracavitary irradiation might include visual improvement, a better endocrinology and neurological function.

Search strategy

A literature search was performed using PubMed to identify potentially relevant publications. The search strategy included a combination of key words "phosphorus-32", and "craniopharyngioma", "intracystic treatment", "brain", "cyst", "tumor", "brachytherapy", "intracavitary irradiation", "isotope" in the titles/abstract of publications. Since the first study of phosphorus-32 intracavitary irradiation for CPs was published in 1981, time interval was set from 1981 to end of December 2014. The initial search was carried out in early 2014 and updated two times in 2014 (September, and October) and once in April 2015.

Inclusion and exclusion criteria

The reference points for this study were the date of initial phosphorus-32 intracavitary irradiation procedure. All research articles using the ^{32}P in CPs were included. Papers were excluded if the topic was about other disease conditions.

Data synthesis

The data obtained from each study were synthesized by providing descriptive tables reporting authors' names, publication year, study setting, study sample, disease conditions (where relevant data were available), and the main findings or conclusions. The findings were then sorted and presented chronologically.

RESULTS

Statistics

A total of 25 citations were identified and screened. Overall 6 papers were found irrelevant (Dosimetric

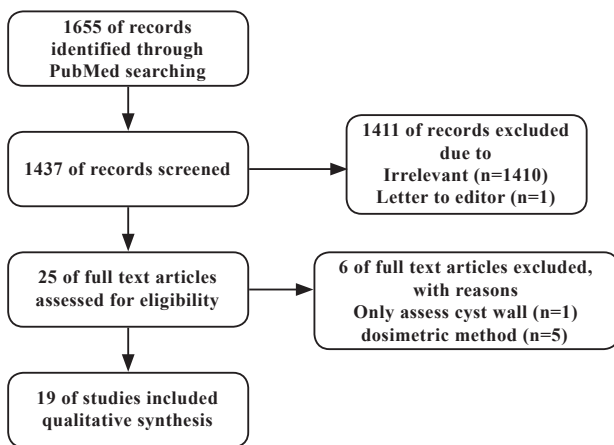


Figure 1. Relevant manuscript selection process.

method = 5, only assess cyst wall = 1). Thus, 19 citations were examined for eligibility and were included in this review (Figure 1).

(i) Visual outcome

Visual improvement or stable condition was reported ranging from 63% to 95.5% for primary and adjuvant treatment after phosphorus-32 intracavitary irradiation^{6,8,11-15}. Some studies reported that no difference in visual deterioration between patients who received primary or adjuvant treatment⁹. In general vision impairment was reported for less than 10% of patients¹². However, a study reported that vision improved in 15-30% after ^{32}P but has been reported to worsen in 27-58%¹⁶.

(ii) Endocrinological outcome

Patients with preoperative endocrine abnormalities showed almost complete normalization or had improvement in endocrine function. Patients who exhibited residual neuroendocrine function before isotope instillation developed no significant deterioration in endocrine status during the follow-up period^{2,6-8,9,11,14,15,17-19}. Some studies reported that no endocrine preservation difference was noted between patients who received either primary or adjuvant treatment^{9,20}. However, a study found that endocrine function worsened in 25%¹⁷. Overall studies showed that more than 70% of patients had stable endocrine function after treatment¹².

(iii) Neurological outcome

Pollock *et al.* reported that no difference was noted between primary and adjuvant treatment patients with respect to neurological outcome after phosphorus-32

intracavitary irradiation⁹. Kickingreder *et al.* reported that 13.7 % of patients had experienced transient neurological deficits after instillation of ^{32}P . They also reported that neurological outcome improved (31.4%) and remained unchanged (52.9%) at last clinical follow-up¹². Overall, patients with preoperative neurological deficits showed either stabilized or improved after treatment^{6,14,21,22}. Some studies reported that cognitive disturbances were disappeared completely in all affected patients and Hemiparesis improved significantly in patients^{2,12,20}.

(iv) Adverse effects and complications

Injected ^{32}P can leak from the cystic wall resulting in toxic damage to both the optic chiasm and optic nerve¹⁴. However, Hasegawa *et al.* observed visual deterioration because of adverse effects of ^{32}P in 6.1 % of their patients¹⁴. Albeit, some studies reported that no permanent visual acuity or visual field impairments were related to instillation of ^{32}P ¹². No mortality rate was reported due to ^{32}P procedures¹². Reported complications included III palsy²¹, manifested signs of a slowly progressive dementia¹¹, and diabetes insipidus in 4%¹⁷. A study reported New-onset diabetes insipidus in 18% of patients who had normal posterior pituitary function preoperatively⁹.

(v) Using this approach

All of study's reported that stereotaxic ^{32}P intracavitary irradiation was a safe and effective treatment which may be considered for cystic CPs^{2,6-8,9,11-15,17-25}.

(vi) General findings

1. Quality of life and survival: The data from the literature prove that intracystic ^{32}P improves the rate of survival and quality of life in patients with CPs¹². Studies have shown that the 5- year and 10-year survival rates in children were approximately 100% and 80% respectively^{14,18}.
2. Re-growth and recurrences rate: Overall, progression occurred in all patients during the first year after treatment^{9,12}. The shrinkage of the cyst following ^{32}P or other beta-emitting radioisotopes begins after several months and becomes stable after 6 months to 1 year⁹. Barriger *et al.* reported an overall cyst control rate of 67% with intracystic ^{32}P ⁸. The recurrence rate of CPs after ^{32}P was reported ranging from 1% to 14.3%^{7,22}. However, recurrence rates after this procedure have not been reported by many of investigators. The ^{32}P has been reported to

be ineffective with regard to development of new cysts or the progression of solid tumor parts^{8,14,20,21}. Out-of-field control was reported that significantly superior for cystic CPs than for mixed solitary cystic tumors.¹² Some studies reported that no difference was noted between patients who received either primary or adjuvant treatment with respect to cyst control⁹.

3. The intracavitary irradiation times: The intracavitary irradiation times with ^{32}P is not limited and is an advantage of this method and were reported from 1 to 4¹⁸.

4. Treatment volume and dose to the cyst wall: The treatment volumes were reported from 1.0 ml, 18 up to 126 ml⁷. In addition, ^{32}P doses require adjustment to cyst volume. Dose to the cyst wall reported from 90 Gy¹⁵, to up to approximately 500 Gy¹⁸.

We summarized the findings in Table 1 to 3.

DISCUSSION

The present work is the first identifiable review on outcomes of ^{32}P intracavitary irradiation for cystic CPs. The findings provided a summary of relevant publications

Table 1. Studies on visual outcome on intracavitary brachytherapy using stereotactically applied phosphorus-32 colloid for treatment of cystic craniopharyngiomas.

Author(s) ^{Ref}	Year	Country	Sample size (n)	internal cyst wall (median volume)	follow up	Irradiation dose delivered to the cyst wall in Gy.	Re-growth and recurrences rate	Adverse effects and complications	Results/ Conclusion(s)
Kobayashi et al. ²⁴	1981	Japan	4	25cc	Median 90.75 (Ranging from 69 to 156) months	405	Two patients had tumor re-growth and one patient died due to tumor re-growth 13 years after the initial treatment	Deleterious side-effects occurred in one patient. One patient died due to tumor re-growth 13 years after the initial treatment	One patient complained of nausea, headache, and blurred vision of the left eye 6 hours after injection of ^{32}P .
Lunsford et al. ⁶	1982	USA	10	Not accessible	Between 1 and 15 months	250-300	Recurrences was not observed	Complication was not observed	Between 1 and 15 months after surgery craniopharyngioma cyst regressed. Visual, deficits either stabilized or improved.
Taasan et al. ²³	1985	USA	3	8.6 ml	8 months	0.34 mCi	No rate of recurrence data has been accumulated at the time of report.	Side effects and complications were not observed. There was no instance of radionuclide leakage outside of the target cyst.	No reported
Kumar et al. ²⁵	1986	USA	1	5ml	2 year	0.5 mCi	No recurrence was observed in retreatment of recurrent cystic	There were no postoperative complications from the procedure, and the patient was discharged the next day on tapering doses of prednisone.	The patient's symptoms were relieved, and he is without evidence of disease or cystic fluid accumulation four years after intracavitary (^{32}P) irradiation
Pollack et al. ¹¹	1988	USA	9	ranged from 2.8 to 80 ml	ranged from 14 to 45 months (mean 27 months)	200-300	Because of recurrent symptoms, one patient required a craniotomy 14 months after isotope instillation	No complications resulted from the initial isotope instillation. No patient demonstrated deterioration in CT evidence of radiation injury to the surrounding brain.	Three of five patients with impaired visual acuity before surgery had significant improvement in acuity after treatment. Preoperative visual field defects in eight patients improved in four after ^{32}P therapy.
Anderson et al. ¹³	1989	USA	7	Not accessible	Not accessible	Not accessible	Two patients received single treatments with ^{32}P , whereas five required multiple instillations for recurrent cyst expansion.	No observed	Visual acuity improved in 13 eyes and remained stable in 1. Visual fields normalized in three patients, improved in two, and remained stable in two.

Table 1. Continued

Author(s) ^{Ref}	Year	Country	Sample size (n)	internal cyst wall (median volume)	follow up	Irradiation dose delivered to the cyst wall in Gy.	Re-growth and recurrences rate	Adverse effects and complications	Results/ Conclusion(s)
Lunsford et al. ¹⁹	1994	USA	32	Ranged from 1.8 to 126 ml (median 6.1)	Ranged from 6 to 116 months (median 31)	200-250	Two patients had evidence of progressive growth of the solid components of their tumor, and both eventually underwent repeat microsurgery.	No mortality or morbidity was observed due to procedure.	Visual acuity and visual fields after stereotactic intracavitary irradiation (n=26) were assessed improved (n=4), unchanged (n=15), delayed worsening (n=7), and improved (n=8), unchanged (n=10), and delayed worsening (n=8), respectively
Pollock et al. ⁹	1995	USA	30	The mean treated cyst volume was greater in the adjuvant treatment group compared to the primary treatment group (16.8 ml vs. 5.9 ml);	median follow-up was 37 months (mean 46 months, range 7-116 months).	The primary treatment group was calculated to receive an average of 267 Gy (range 178 to 400 Gy) to the cyst wall over five half-lives of the ³² P; compared to 240 Gy (range 167 to 326 Gy) for the adjuvant treatment group	Phosphorus-32 intracavitary irradiation resulted in cyst regression in 28 of 32 treated cysts (88%). Ten patients (33%) have had tumor progression requiring further surgical intervention.	New-onset diabetes insipidus occurred in 3 of 17 patients (18%) who had normal posterior pituitary function preoperatively. Three patients (10%) died: two of tumor progression, and one of unrelated causes.	Visual acuity and fields improved or were unchanged in 69% of patients undergoing primary treatment of their craniopharyngioma, compared to 59% of patients having ³² P intracavitary irradiation as adjuvant treatment. No difference was noted between primary and adjuvant treatment patients with respect to visual deterioration after phosphorus-32 intracavitary irradiation.
Voges et al. ²⁰	1997	Germany	62, a total of 78 craniopharyngioma cysts. Eight of 78 cysts were treated with [³² P]chromic phosphate	The median volume of the cysts was 18.5 cc (range, 2.2-330.0 cc)	The median observation time was 11.9 years (range, 1.5-16.4 yr).	Cumulative dose to the inner surface of the cyst wall, 200 Gy	Three of eight cysts treated with ³² P disappeared completely and four of eight cysts partially. However, recurrence was not observed.	There was neither operative nor perioperative morbidity or mortality. Cyst leakage, which never caused any sequelae, was documented in 1 of 8 patients after ³² P instillation. Because of its shorter range in tissue and longer half-life, the application of ³² P instead of ⁹⁰ Y may help to reduce side effects	Six months postoperatively, visual deficits had improved in 61% patients and were stable in 39% patients.
Tian et al. ⁷	1997	China	50	28-126 cm ³ (average 38 cm ³).	Follow-up at 1-5 years (average 2.6 years)	1.2-5.6 mCi	Tumor recurrence was observed in 2 cases	There were no operative deaths and death in 2 patients (1 from diabetes, another from septicemia).	One month after the operation, 46 (92%) patients improved clinically: visual acuity improved in 56% (28/50) of cases, visual fields improved in 52% (24/46).
Schefter et al. ²²	2002		7	mean tumor size of approximately 2.5 cm	50 months, (range 20-116 months).	Cumulative dose to the inner surface of the cyst wall, 200 Gy	Recurrence was observed in 1 case	No complication was observed.	None of the patients who had normal vision prior to treatment suffered a decline in vision following their initial therapy.

Table 1. Continued

Author(s) ^{Ref}	Year	Country	Sample size (n)	internal cyst wall (median volume)	follow up	Irradiation dose delivered to the cyst wall in Gy.	Re-growth and recurrences rate	Adverse effects and complications	Results/ Conclusion(s)
Hall et al. ¹⁷	2003	USA	1	1 ml	1 month	20 000 cGy	No	No complication was observed	Patient experienced an improvement in both his visual fields and visual acuity following treatment with P32 within a few days after surgery.
Hasegawa et al. ¹⁴	2004	USA	49	mean, 13 ml	The mean follow-up periods were 7 years after diagnosis and 4 years after (32)P treatment	mean, 224 Gy	The actuarial survival rates were 90% at 5 years after the diagnosis and 80% at 10 years. The actuarial tumor cyst control rates were 76% at 5 years and 70% at 10 years after the diagnosis. During follow-up, six patients (13%) developed new cysts and three had cyst progression cysts.	Hasegawa et al. observed visual deterioration because of adverse effects of 32P in 6.1 % of their patients	After treatment, 9 (23%) of 40 patients who underwent preoperative and postoperative visual testing were found to have delayed worsening in visual function, 6 as a result of tumor progression and 3 attributed to irradiation. Nineteen patients (48%) had improved visual function and 5 (29%) had worsened visual function.
Albright et al. ²¹	2005	USA	12	ranged from 2.1 to 145 cm3, with a mean of 30 cm3.	mean, 25 months	200–250 Gy	Two child had cyst progression after initial 32P treatment	There was no mortality or morbidity in patients from primary treatment with 32P.	Visual preservation or improvement.
Shahzadi et al. ³	2008	Iran	22	26.5 (range: 4.5 – 86.6) mL	median of 10.5 months 10.5(range: 3 – 120) months	250	The mean+/-SD survival after intracavitary irradiation was 25.4+/-6.8 months In eight (36%) patients, was repeated irradiation.	Two patients eventually died of tumor progression. There was neither intra- nor peri-operative mortality. Infection ensued after the procedure in three patients. No cyst leakage as detected with gamma camera examination during the first 48 hr, was found in the patients.	Visual function improved in six patients and remained stable in 15 patients; one experienced deterioration of the visual acuity and field.
Floyd et al. ¹⁵	2009	USA	1	0.5 mL	6 months	20 000 cGy	The second recurrence was cystic, and confined to the sella. A minimally invasive, transnasal endoscopic approach was selected for the instillation of phosphorus 32 radionucleotide into the cyst At six months, there was no progression of the cyst	There were no complications, and the patient was discharged home on postoperative day one.	Visual function improved
Zhao et al. ¹⁸	2010	China	20	28.7 ml	median follow-up was 47.7 months (ranging from 36 to 336 months)	400 approximately 500	Fourteen patients (70%) had tumor progression and required further two to four times intracavitary irradiation.	No operative morbidity or mortality was found from P-32 intracavitary irradiation.	Visual disturbances after the last therapy were no change (n=5), alleviated(n=13), absent (n=1), and worsening (n=1)

Table 1. Continued

Author(s) ^{Ref}	Year	Country	Sample size (n)	internal cyst wall (median volume)	follow up	Irradiation dose delivered to the cyst wall in Gy.	Re-growth and recurrences rate	Adverse effects and complications	Results/ Conclusion(s)
Barriger et al. ⁸	2011	USA	22	9 ml.	median follow-up was 62 months (range 8-136 months)	300	Overall cyst control rate after the initial P-32 treatment was 67%. Complete tumor control after P-32 was 42%. Kaplan-Meier 1-, 3-, and 5-year initial freedom-from-progression rates were 68%, 49%, and 31%, respectively. Following salvage therapy, the Kaplan-Meier 1-, 3-, and 5-year ultimate freedom-from-progression rates were 95%, 95%, and 86%, respectively.	Intracystic P-32 can be an effective for controlling cystic components of craniopharyngiomas, but frequently were allowed for progression of solid tumor components. Disease progression in the form of solid tumor progression, re-accumulation of cystic fluid, or development of new cysts may require further radiotherapy or surgical intervention for optimal long-term disease control. All patients were alive at the last follow-up.	Sixteen patients had pre- and post-treatment visual testing records. Nine evaluable patients had normal pre-treatment visual acuity/fields, of which 1 worsened after treatment. Pre-treatment visual deficits were present in 7 patients, and 2 worsened after treatment. Overall, visual function was stable or improved in 81% when compared prior to P-32 therapy.
Kickingreder et al. ¹²	2012	Germany	53	6.1 ml.	Median clinical follow-up was 60.2 months	200	Actuarial tumor cyst control was 86.0 ± 5.3 % at 12, 24, and 60 months. Actuarial overall progression-free survival was 79.4 ± 6.1, 72.4 ± 6.8, and 45.6 ± 8.7 % at 12, 24, and 60 months, respectively. The procedure does not, however affect the development of new cysts or the progression of solid tumor parts.	Stereotactically applied (32) P was associated with a low risk of permanent morbidity.	Visual function improved in 12, was unchanged in 34, and worsened in 5 patients, correlating with tumor progression in each case.

and might be useful to guide future research in this area. Stereotactically applied ³²P was found to be a reasonable option and a safe and effective treatment that can be expected to provide accurate results with a relatively low complication rates in highly selected patients with newly diagnosed or recurrent cystic CPs.

The aim of therapy for CPs is local control and improvement of tumor-related symptoms. The target tissue is the cyst wall, which is only millimeters thick²⁶. Gross total resection of CPs is the best initial treatment option. It is technically challenging since the tumor is surrounded by vital structures, and nearly all CPs have an attachment to the pituitary stalk, and limited visibility in some of region during the surgery^{27,28}. Complications of gross total resection include the need for hormone replacement, obesity²⁹, severe behavioral problems, blindness, seizures, spinal fluid leak, false aneurysms, and difficulty with eye movements²⁶. Rare complications of gross total resection include death from intraoperative

hemorrhage, hypothalamic damage, or stroke²⁶. However, if alternatively conservative surgery with incomplete tumor removal is performed, it might be associated with a high recurrence rate, which itself is associated with high mortality and morbidity²⁶. Yet, if needed, radiation therapy combined with surgery may be used in patients for prevent early progression³⁰. Complications of radiation include loss of pituitary hormonal function, cognitive dysfunction, development of late strokes and vascular malformations, delayed blindness, development of second tumors, and, rarely, malignant transformation of the primary tumor within the radiation field^{31,32}. It is argued that radio-surgery as Gamma Knife, limits the rate of radiation complications and gives better primary cure and recurrence rates for CPs³³. But, in selected cases, small and medium sized targets (i.e. less than 3.5 centimeters) are safely treated with radiosurgery^{26,34}. Meanwhile, tumor progression remains a possibility, and it is typically not likely to repeat the radiation dose³⁴.

Table 2. Studies on endocrinological outcome on intracavitary brachytherapy using stereotactically applied phosphorus-32 colloid for treatment of cystic craniopharyngiomas.

Author(s) ^{Ref}	Year	Country	Sample size (n)	internal cyst wall (median volume)	follow up	Irradiation dose delivered to the cyst wall in Gy.	Re-growth and recurrences rate	Adverse effects and complications	Results/Conclusion(s)
Kobayashi et al. ²⁴	1981	Japan	4	25cc	Median 90.75 (Ranging from 69 to 156) months	405	One patient Two patients have tumor re-growth and one patient died due to tumor re-growth 13 years after the initial treatment	Deleterious side-effects occurred in one patient. One patient died due to tumor re-growth 13 years after the initial treatment	No reported
Lunsford et al. ⁶	1982	USA	10	Not accessible	Between 1 and 15 months	250-300	Recurrences was not observed	Complication was not observed	Between 1 and 15 months after surgery craniopharyngioma cyst regressed. Endocrinological deficits either stabilized or improved.
Taasan et al. ²³	1985	USA	3	8.6 ml	8 months	0.34 mCi	No rate of recurrence data has been accumulated at the time of report.	Side effects and complications were not observed. There was no instance of radionuclide leakage outside of the target cyst.	No reported
Kumar et al. ²⁵	1986	USA	1	5ml	2 year	0.5 mCi	No recurrence was observed in retreatment of recurrent cystic	There were no postoperative complications from the procedure, and the patient was discharged the next day on tapering doses of prednisone.	The patient was well, now six years of age, four years after retreatment with intracavitary chromic ^{32}p .
Pollack et al. ¹¹	1988	USA	9	ranged from 2.8 to 80 ml	ranged from 14 to 45 months (mean 27 months)	200-300	Because of recurrent symptoms, one patient required a craniotomy 14 months after isotope instillation	No complications resulted from the initial isotope instillation. No patient demonstrated deterioration in CT evidence of radiation injury to the surrounding brain.	Of seven patients with preoperative endocrine abnormalities, one individual showed almost complete normalization and another had improvement in endocrine function. Patients who exhibited residual neuroendocrine function before isotope instillation developed no significant deterioration in endocrine status during the follow-up period.
Anderson et al. ¹³	1989	USA	7	Not accessible	Not accessible	Not accessible	Two patients received single treatments with ^{32}P , whereas five required multiple instillations for recurrent cyst expansion.	No observed	No reported

Table 2. Continued

Author(s) ^{Ref}	Year	Country	Sample size (n)	internal cyst wall (median volume)	follow up	Irradiation dose delivered to the cyst wall in Gy.	Re-growth and recurrences rate	Adverse effects and complications	Results/Conclusion(s)
Lunsford et al. ¹⁹	1994	USA	32	Ranged from 1.8 to 126 ml (median 6.1)	Ranged from 6 to 116 months (median 31)	200-250	Two patients had evidence of progressive growth of the solid components of their tumor, and both eventually underwent repeat microsurgery.	No mortality or morbidity was observed due to procedure.	Endocrinological outcomes were assessed in 26 cases. 22 cases had no change from their preoperative status and 6 had delayed deterioration in one or more pituitary hormonal axes. Seven cases had completely normal endocrinological function preoperatively; 4 had preservation of endocrinological function, but 3 had deterioration (manifest by development of diabetes insipidus in 1 case, reduced cortisone function in 1 case, and panhypopituitarism in 1 case).
Pollock et al. ¹³	1995	USA	30	The mean treated cyst volume was greater in the adjuvant treatment group compared to the primary treatment group (16.8 ml vs. 5.9 ml);	median follow-up was 37 months (mean 46 months, range 7-116 months).	The primary treatment group was calculated to receive an average of 267 Gy (range 178 to 400 Gy) to the cyst wall over five half-lives of the ^{32}P , compared to 240 Gy (range 167 to 326 Gy) for the adjuvant treatment group	Phosphorus-32 intracavitary irradiation resulted in cyst regression in 28 of 32 treated cysts (88%). Ten patients (33%) have had tumor progression requiring further surgical intervention.	New-onset diabetes insipidus occurred in 3 of 17 patients (18%) who had normal posterior pituitary function preoperatively. Three patients (10%) died: two of tumor progression, and one of unrelated causes.	Fifteen patients had residual anterior pituitary function before intracavitary irradiation and 10 (67%) retained their preoperative endocrine status. No difference was noted between primary and adjuvant treatment patients with respect to endocrine preservation after phosphorus-32 intracavitary irradiation.
Voges et al. ²⁰	1997	Germany	62, a total of 78 craniopharyngioma cysts. Eight of 78 cysts were treated with [^{32}P]chromic phosphate	The median volume of the cysts was 18.5 cc (range, 2.2-330.0 cc)	The median observation time was 11.9 years (range, 1.5-16.4 yr).	Cumulative dose to the inner surface of the cyst wall, 200 Gy	Three of eight cysts treated with ^{32}P disappeared completely and four of eight cysts partially. However, recurrence was not observed.	There was neither operative nor perioperative morbidity or mortality. Cyst leakage, which never caused any sequelae, was documented in 1 of 8 patients after ^{32}P instillation. Because of its shorter range in tissue and longer half-life, the application of ^{32}P instead of ^{90}Y may help to reduce side effects	The preoperative status did not change in patients with endocrine dysfunction.

Table 2. Continued

Author(s) ^{Ref}	Year	Country	Sample size (n)	internal cyst wall (median volume)	follow up	Irradiation dose delivered to the cyst wall in Gy.	Re-growth and recurrences rate	Adverse effects and complications	Results/Conclusion(s)
Tian <i>et al.</i> ⁷	1997	China	50	28-126 cm ³ (average 38 cm ³).	Follow-up at 1-5 years (average 2.6 years)	1.2-5.6 mCi	Tumor recurrence was observed in 2 cases	There were no operative deaths and death in 2 patients (1 from diabetes, another from septicaemia).	One month after the operation, 46 (92%) patients improved clinically: diabetes insipidus resolved in 61% (11/18). CT re-examination confirmed the postoperative shrinkage of the tumour in 46 (92%) cases.
Schefter <i>et al.</i> ²²	2002		7	mean tumor size of approximately 2.5 cm	50 months, (range 20–116 months).	Cumulative dose to the inner surface of the cyst wall, 200 Gy	Recurrence was observed in 1 case	No complication was observed.	The preoperative status did not change in patients with endocrine dysfunction
Hall <i>et al.</i> ¹⁷	2003	USA	1	1 ml	1 month	20 000 cGy	No	No complication was observed	Endocrine status has remained normal both before and after the treatment with P32.
Hasegawa <i>et al.</i> ¹⁴	2004	USA	49	mean, 13 ml	The mean follow-up periods were 7 years after diagnosis and 4 years after (32)P treatment	mean, 224 Gy	The actuarial survival rates were 90% at 5 years after the diagnosis and 80% at 10 years. The actuarial tumor cyst control rates were 76% at 5 years and 70% at 10 years after the diagnosis. During follow-up, six patients (13%) developed new cysts and three had cyst progressioncysts.	Hasegawa <i>et al.</i> observed visual deterioration because of adverse effects of 32P in 6.1% of their patients.	Of 17 patients who had normal preoperative pituitary function or stalk effect, 12 (71%) had preserved.
Albright <i>et al.</i> ²¹	2005	USA	12	ranged from 2.1 to 145 cm ³ , with a mean of 30 cm ³ .	mean, 25 months	200–250 Gy	Two child had cyst progression after initial 32P treatment	There was no mortality or morbidity in patients from primary treatment with 32P.	Endocrine preservation
Shahzadi <i>et al.</i> ³	2008	Iran	22	26.5 (range: 4.5 – 86.6) mL	median of 10.5 months 10.5(range: 3 – 120) months	250	The mean+/-SD survival after intracavitary irradiation was 25.4+/-6.8 months In eight (36%) patients, was repeated irradiation.	Two patients eventually died of tumor progression. There was neither intra- nor peri-operative mortality. Infection ensued after the procedure in three patients. No cyst leakage as detected with gamma camera examination during the first 48 hr, was found in the patients.	The anterior pituitary function did not change in any patients. Diabetes insipidus improved in one patient, persisted in two, and developed in one patient after the procedure.

Table 2. Continued

Author(s) ^{Ref}	Year	Country	Sample size (n)	internal cyst wall (median volume)	follow up	Irradiation dose delivered to the cyst wall in Gy.	Re-growth and recurrences rate	Adverse effects and complications	Results/Conclusion(s)
Floyd et al. ¹⁵	2009	USA	1	0.5 mL	6 months	20 000 cGy	The second recurrence was cystic, and confined to the sella. A minimally invasive, transnasal endoscopic approach was selected for the instillation of phosphorus 32 radionuclide into the cyst. At six months, there was no progression of the cyst.	There were no complications, and the patient was discharged home on postoperative day one.	There were no complications related to endocrinological outcome.
Zhao et al. ¹⁸	2010	China	20	28.7 ml	median follow-up was 47.7 months (ranging from 36 to 336 months)	400 approximately 500	Fourteen patients (70%) had tumor progression and required further two to four times intracavitary irradiation.	No operative morbidity or mortality was found from P-32 intracavitary irradiation.	GH deficiency, ACTH deficiency, TSH deficiency and Hyperprolactinemia pre- and postoperative were 14/20 (70%), 14/18 (78%), 15/20 (75%), 7/20 (35%); and 14/20 (70%), 11/18 (61%), 10/20 (50%) and 10/20 (50%), respectively.
Barriger et al. ⁸	2011	USA	22	9 ml.	median follow-up was 62 months (range 8-136 months)	300	Overall cyst control rate after the initial P-32 treatment was 67%. Complete tumor control after P-32 was 42%. Kaplan-Meier 1-, 3-, and 5-year initial freedom-from-progression rates were 68%, 49%, and 31%, respectively. Following salvage therapy, the Kaplan-Meier 1-, 3-, and 5-year ultimate freedom-from-progression rates were 95%, 95%, and 86%, respectively.	Intracystic P-32 can be an effective for controlling cystic components of craniopharyngiomas, but frequently were allowed for progression of solid tumor components. Disease progression in the form of solid tumor progression, re-accumulation of cystic fluid, or development of new cysts may require further radiotherapy or surgical intervention for optimal long-term disease control. All patients were alive at the last follow-up.	Nineteen patients had pre- and post-treatment endocrine function data available from medical records. Five patients had normal pre-treatment pituitary function, 9 patients had pre-treatment partial pituitary deficiency, and 5 patients had panhypopituitarism. Of the 5 patients with normal pre-treatment pituitary function, 2 retained stable function, 2 developed partial pituitary deficiencies, and 1 developed panhypopituitarism. Overall, Pituitary function remained stable in 74% of patients following P-32 therapy.
Kickingreder et al. ¹²	2012	Germany	53	6.1 ml.	Median clinical follow-up was 60.2 months	200	Actuarial tumor cyst control was 86.0 ± 5.3 % at 12, 24, and 60 months. Actuarial overall progression-free survival was 79.4 ± 6.1, 72.4 ± 6.8, and 45.6 ± 8.7 % at 12, 24, and 60 months, respectively. The procedure does not, however affect the development of new cysts or the progression of solid tumor parts.	Stereotactically applied (³² P) was associated with a low risk of permanent morbidity.	Endocrinological deterioration occurred for 10 patients; for nine patients this was a result of tumor progression or after tumor resection and for one it was attributed to irradiation.

Table 3. Studies on neurological outcome on intracavitary brachytherapy using stereotactically applied phosphorus-32 colloid for treatment of cystic craniopharyngiomas.

Author(s) Ref	Year	Country	Sample size (n)	internal cyst wall (median volume)	follow up	Irradiation dose delivered to the cyst wall in Gy.	Re-growth and recurrences rate	Adverse effects and complications	Results/ Conclusion(s)
Kobayashi et al. ²⁴	1981	Japan	4	25cc	Median 90.75 (Ranging from 69 to 156) months	405	Two patients have tumor re-growth and one patient died due to tumor re-growth 13 years after the initial treatment	Deleterious side-effects occurred in one patient. One patient died due to tumor re-growth 13 years after the initial treatment	One patient developed third nerve palsy
Lunsford et al. ⁶	1982	USA	10	Not accessible	Between 1 and 15 months	250-300	Recurrences was not observed	Complication was not observed	Between 1 and 15 months after surgery craniopharyngioma cyst regressed. Neurological deficits either stabilized or improved.
Taasan et al. ²³	1985	USA	3	8.6 ml	8 months	0.34 mCi	No rate of recurrence data has been accumulated at the time of report.	Side effects and complications were not observed. There was no instance of radionuclide leakage outside of the target cyst.	No reported
Kumar et al. ²⁵	1986	USA	1	5ml	2 year	0.5 mCi	No recurrence was observed in retreatment of recurrent cystic	There were no postoperative complications from the procedure, and the patient was discharged the next day on tapering doses of prednisone.	The patient was well, now six years of age, four years after retreatment with intracavitary chronic ³² p.
Pollack et al. ¹¹	1988	USA	9	ranged from 2.8 to 80 ml	ranged from 14 to 45 months (mean 27 months)	200-300	Because of recurrent symptoms, one patient required a craniotomy 14 months after isotope instillation	No complications resulted from the initial isotope instillation. No patient demonstrated deterioration in CT evidence of radiation injury to the surrounding brain.	One patient manifested signs of a slowly progressive dementia. No other patient demonstrated deterioration in neurological function.
Anderson et al. ¹³	1989	USA	7	Not accessible	Not accessible	Not accessible	Two patients received single treatments with ³² P, whereas five required multiple instillations for recurrent cyst expansion.	No observed	No reported
Lunsford et al. ¹⁹	1994	USA	32	Ranged from 1.8 to 126 ml (median 6.1)	Ranged from 6 to 116 months (median 31)	200-250	Two patients had evidence of progressive growth of the solid components of their tumor, and both eventually underwent repeat microsurgery.	No mortality or morbidity was observed due to procedure.	13 cases had preoperative headache syndromes; 9 had resolution and 2 had no change. One case had subsequent worsening of headache and underwent microsurgery.

Table 3. Continued

Author(s) Ref	Year	Country	Sample size (n)	internal cyst wall (median volume)	follow up	Irradiation dose delivered to the cyst wall in Gy.	Re-growth and recurrences rate	Adverse effects and complications	Results/ Conclusion(s)
Pollock et al. ⁹	1995	USA	30	The mean treated cyst volume was greater in the adjuvant treatment group compared to the primary treatment group (16.8 ml vs. 5.9 ml);	median follow-up was 37 months (mean 46 months, range 7-116 months).	The primary treatment group was calculated to receive an average of 267 Gy (range 178 to 400 Gy) to the cyst wall over five half-lives of the ³² P, compared to 240 Gy (range 167 to 326 Gy) for the adjuvant treatment group	Phosphorus-32 intracavitary irradiation resulted in cyst regression in 28 of 32 treated cysts (88%). Ten patients (33%) have had tumor progression requiring further surgical intervention.	New-onset diabetes insipidus occurred in 3 of 17 patients (18%) who had normal posterior pituitary function preoperatively. Three patients (10%) died: two of tumor progression, and one of unrelated causes.	Fourteen of 20 adult patients (70%) continued to perform at their preoperative functional level; 3 of 5 pediatric patients who were age appropriate at the time of treatment continued to develop normally. No difference was noted between primary and adjuvant treatment patients with respect to neurological outcome after phosphorus-32 intracavitary irradiation.
Voges et al. ²⁰	1997	Germany	62, a total of 78 craniopharyngioma cysts. Eight of 78 cysts were treated with [³² P]chromic phosphate	The median volume of the cysts was 18.5 cc (range, 2.2-330.0 cc)	The median observation time was 11.9 years (range, 1.5-16.4 yr).	Cumulative dose to the inner surface of the cyst wall, 200 Gy	Three of eight cysts treated with ³² P disappeared completely and four of eight cysts partially. However, recurrence was not observed.	There was neither operative nor perioperative morbidity or mortality. Cyst leakage, which never caused any sequelae, was documented in 1 of 8 patients after ³² P instillation. Because of its shorter range in tissue and longer half-life, the application of ³² P instead of ⁹⁰ Y may help to reduce side effects	Tumor outcomes were observed completely response (n=3), partial response (n=4) and stable disease (n=1). Cognitive disturbances disappeared completely in all affected patients. Hemiparesis improved significantly in patients.
Tian et al. ⁷	1997	China	50	28-126 cm ³ (average 38 cm ³).	Follow-up at 1-5 years (average 2.6 years)	1.2-5.6 mCi	Tumor recurrence was observed in 2 cases	There were no operative deaths and death in 2 patients (1 from diabetes, another from septicaemia).	One month after the operation, 46 (92%) patients improved clinically: headache diminished in 80% (35/44), vomiting disappeared in 84% (31/37), and hemiplegia improved in 71% (10/14). CT re-examination confirmed the postoperative shrinkage of the tumour in 46 (92%) cases.
Schefter et al. ²²	2002		7	mean tumor size of approximately 2.5 cm	50 months, (range 20-116 months).	Cumulative dose to the inner surface of the cyst wall, 200 Gy	Recurrence was observed in 1 case	No complication was observed.	No significant neurologic sequelae were observed.

Table 3. Continued

Author(s) Ref	Year	Country	Sample size (n)	internal cyst wall (median volume)	follow up	Irradiation dose delivered to the cyst wall in Gy.	Re-growth and recurrences rate	Adverse effects and complications	Results/ Conclusion(s)
Hall et al. ¹⁷	2003	USA	1	1 ml	1 month	20 000 cGy	No	No complication was observed	Patient returned to work full-time one month after surgery.
Hasegawa et al. ¹⁴	2004	USA	49	mean, 13 ml	The mean follow-up periods were 7 years after diagnosis and 4 years after (32)P treatment	mean, 224 Gy	The actuarial survival rates were 90% at 5 years after the diagnosis and 80% at 10 years. The actuarial tumor cyst control rates were 76% at 5 years and 70% at 10 years after the diagnosis. During follow-up, six patients (13%) developed new cysts and three had cyst progression.	Hasegawa et al. observed visual deterioration because of adverse effects of ^{32}P in 6.1 % of their patients.	In this study, patients did not undergo detailed neuropsychological evaluations before and after surgery. The majority of patients were able to return to their preoperative level of functioning and maintained this level in the long term.
Albright et al. ²¹	2005	USA	12	ranged from 2.1 to 145 cm ³ , with a mean of 30 cm ³ .	mean, 25 months	200–250 Gy	Two child had cyst progression after initial ^{32}P treatment	There was no mortality or morbidity in patients from primary treatment with ^{32}P .	Neurocognitive preservation
Shahzadi et al. ³	2008	Iran	22	26.5 (range: 4.5 – 86.6) mL	median of 10.5 months 10.5(range: 3 – 120) months	250	The mean \pm SD survival after intracavitary irradiation was 25.4 \pm 6.8 months In eight (36%) patients, was repeated irradiation.	Two patients eventually died of tumor progression. There was neither intra- nor peri- operative mortality. Infection ensued after the procedure in three patients. No cyst leakage as detected with gamma camera examination during the first 48 hr, was found in the patients.	No cognitive disturbance was observed in the patients. Hemiparesis improved in one patient after intracranial irradiation with ^{32}P .
Floyd et al. ¹⁵	2009	USA	1	0.5 mL	6 months	20 000 cGy	The second recurrence was cystic, and confined to the sella. A minimally invasive, transnasal endoscopic approach was selected for the instillation of phosphorus 32 radionucleotide into the cyst At six months, there was no progression of the cyst	There were no complications, and the patient was discharged home on postoperative day one.	No complications was observed
Zhao et al. ¹⁸	2010	China	20	28.7 ml	median follow-up was 47.7 months (ranging from 36 to 336 months)	400 approximately 500	Fourteen patients (70%) had tumor progression and required further two to four times intracavitary irradiation.	No operative morbidity or mortality was found from P-32 intracavitary irradiation.	All 20 cases achieved tumor shrinkage or stabilization with effective outcome 3–6 months after the last P-32 therapy.

Table 3. Continued

Author(s) Ref	Year	Country	Sample size (n)	internal cyst wall (median volume)	follow up	Irradiation dose delivered to the cyst wall in Gy.	Re-growth and recurrences rate	Adverse effects and complications	Results/ Conclusion(s)
Barriger et al. ⁸	2011	USA	22	9 ml.	median follow-up was 62 months (range 8-136 months)	300	Overall cyst control rate after the initial P-32 treatment was 67%. Complete tumor control after P-32 was 42%. Kaplan-Meier 1-, 3-, and 5-year initial freedom-from-progression rates were 68%, 49%, and 31%, respectively. Following salvage therapy, the Kaplan-Meier 1-, 3-, and 5-year ultimate freedom-from-progression rates were 95%, 95%, and 86%, respectively.	Intracystic P-32 can be an effective for controlling cystic components of craniopharyngiomas, but frequently were allowed for progression of solid tumor components. Disease progression in the form of solid tumor progression, re-accumulation of cystic fluid, or development of new cysts may require further radiotherapy or surgical intervention for optimal long-term disease control. All patients were alive at the last follow-up.	Three patients had cranial nerve (CN) deficits: 1 developed a unilateral CN6 deficit that spontaneously resolved over the course of 1 year, 1 patient was blind from complications of a prior surgical procedure over 10 years before presenting with recurrent disease, and the patient who received 4 separate P-32 procedures developed bilateral superior temporal quadrantanopsia.
Kickingreder et al. ¹²	2012	Germany	53	6.1 ml.	Median clinical follow-up was 60.2 months	200	Actuarial tumor cyst control was $86.0 \pm 5.3\%$ at 12, 24, and 60 months. Actuarial overall progression-free survival was 79.4 ± 6.1 , 72.4 ± 6.8 , and $45.6 \pm 8.7\%$ at 12, 24, and 60 months, respectively. The procedure does not, however affect the development of new cysts or the progression of solid tumor parts.	Stereotactically applied (^{32}P) was associated with a low risk of permanent morbidity.	Within six months of IBT seven patients (13.7%) experienced transient neurological deficits and two patients (3.9%) deteriorated permanently (hemiparesis and third nerve palsy).

Some CPs with a large cystic component and recurrent cystic tumor may be treated by stereotaxic delivery of ^{32}P or other radioactive compounds^{8,12,18,35}, although none have shown efficacy against solid portions of the tumor. In general there is no consensus as to the ideal treatment of diagnosed CPs. Very few data exist to compare the different procedures in terms of quality of life or recurrence rate. For this reason, treatment is individualized. So, future studies are needed to clarify these issues.

Four radionuclides as ^{186}Re , ^{90}Y , ^{198}Au and ^{32}P have been used in intracavitary therapy of cystic CPs.³⁸ However, there is controversy regarding the ideal isotope¹². The ^{32}P has a pure beta-emitting radionuclide with an ideal mean energy of 0.69 MeV, the maximum penetration pathway of beta irradiation in soft tissue is 7.9 mm (the mean 2.63mm), and less than 50% of the given dose penetrates beyond 0.8 mm^{24,36}. Meanwhile, compared to ^{32}P , ^{186}Re has a lesser tissue penetration (less than 50% of the given dose penetrates beyond 0.3 mm) and then edematogenic

effects are likely to be less in normal brain³⁶. In addition compared to ^{90}Y , the risk of radiation injury to adjacent visual pathways may be reduced with ^{32}P ¹². Finally, at present, ^{186}Re , ^{198}Au and ^{90}Y are not generally available in all treatment centers. The advantages of using ^{32}P include its general availability and the greater experience with this radionuclide compared to other radionuclides³⁸.

The radiation dose used in previously reported series ranges from 50 to 1000 Gy¹¹, and the optimum and safe dose to the cyst wall may be between 90 and 300Gy^{6,15,24,25}. Additionally, cell culture studies of CPs cells have revealed that a ^{32}P dose of 50 μCi / ml for 48 hr results in irreversible cellular damage (fibrosis of the wall)³⁶. Nearly in 20 studies the prescribed dose to the cyst wall was between 200 and 300Gy. The optimal prescribed dose to the cyst wall was reported to be 200–300Gy^{37,38}. However, a number of studies reported that in order to enhance the therapeutic efficiency, the radiation dose was increased to 400–500 Gy^{18,24}. They showed there was no development of adverse reactions or any

damages in patients. High doses can be delivered to the cyst preventing cyst volume re-accumulation and even causing involution of some tumor cysts²⁶. However, they did not report on toxicity to adjacent sensitive structures²⁶. In addition, there is evidence that dose to the cyst wall exceeding 400 Gy will result in significant increase in risks especially to the optic apparatus¹⁵⁻³⁹. Even with these ideal physical characteristics of the ^{32}P source, critical and radiosensitive structures, such as optic chiasm and cavernous sinus should be monitored intensively during the treatment planning step in order to prevent accidental over dosage¹⁹. The best dose to the cyst wall is controversial. Recently based on film dosimetry data and compared with Monte Carlo simulation, Sadeghi *et al.* reported that a prescribed dose to the cyst wall can be considered as follows: (a) dose rate in relation to administered activity concentration for the cyst with inner diameter between 3 and 5cm is 7 (Gy/h) / (mCi/cc) or 0.19 (Gy/h) / (MBq/cm³); (b) required activity to achieve 200–300 Gy is A_{200} (mCi) = $58 \times V$ (cm³), A_{250} (mCi) = $73 \times V$ (cm³); and (c) for the first few hours of ^{32}P injection, cyst motion is necessary to achieve the prescribed dose for treatment³⁷.

Janicki C *et al.* reported that a minimum treatment volume of 0.5 ml (equivalent to approximately 1 cm in diameter) is required for accurate dose calculation⁴⁰. In contrast, there is evidence that cyst volumes exceeding 100 ml will not respond well²¹. Lunsford *et al.* also reported that the technique only should be used for small CPs (< 2.5 cm) that are, preferably, 2-3 mm or more distant from the optic apparatus¹⁹. It seems that several considerations might be useful for selecting effective minimum and maximum treatment volume including thickness of cyst wall, dose to the cyst wall, and CPs distance from vital parts. A 50% decrease in cyst volume was usually apparent between the 2nd and 4th months. A 70% decrease in cyst volume was seen by the 5th and 6th months and an 80% reduction by the 7th and 8th months⁴¹. Overall, an average of 75% shrinkage of the initial cyst volume was reported in the literatures¹². In the future, software simulations may help multidisciplinary teams for best treatment planning.

Overall studies showed that compared with the initial size, cyst volume was significantly reduced after treatment with ^{32}P ^{12,22,25}. Clinical outcomes including visual, endocrinological, and neurological outcomes were significantly improved and a fewer adverse effect and complications were observed^{6,8,11-15}. Thus, ^{32}P is an excellent approach for treatment of cystic CPs. However, for patients with mixed solitary-cystic tumors it is only

suitable as part of a multi-modal approach¹². A number of theoretical explanations for these less successful results reported by Julow *et al.* including: a) the cyst may not shrink if the solid or mainly calcified part of the tumor represents its major component; b) if the cyst is walled in by the sella itself rather than secreting endothelium; or c) if the ^{32}P leaks out of the cyst into the subarachnoidal space through the puncture hole⁴¹.

Kickingeder *et al.* found that gender; age (children vs. adults), tumor morphology (cystic vs. cystic-solidary), previous treatment, and treated cyst volume had no effect on the risk of in-field progression. They are also reported that ^{32}P instillation had no effect on solid tumor parts or on the development of new cysts¹². Thus, patients with CPs will need life-time follow-up⁴². Although many researchers state their cure rate in terms of 5 or 10 year follow up. Recurrences of this tumor can occur remote from brachytherapy. There have been reported a recurrence rates up to 57% even after total removal as judged by post-operative scans, due to their invasiveness⁴². The follow-up could include not only the possibility of tumor regrowth, but also continued monitoring and cure of side-effects related to brachytherapy and other adjuvant treatments. Hence, it is recommended that cases will follow annually until ten years after treatment with ^{32}P . This treatment can be repeated as needed or used in combination with other treatment methods as microsurgery, conformal external radiation therapy, endoscopy, or stereotactic radiosurgery. However, with the progress of neurosurgery and nuclear medicine management, it is expected that the recurrence rate will be reduced and survival period will be extended¹⁸.

CPs is considered very difficult lesions to treat due to an extremely variable growth pattern⁴³. Comparison and evaluation of ^{32}P intracystic will remain difficult on all aspects. Although, randomized clinical trials (RCTs) are the gold standard for evaluation of best treatment plans, however, they are certainly difficult in the context of rare tumors as CPs. To optimized and standardized ^{32}P intracystic treatment, it is recommended that an international center be considered to be performing systematic evaluations and definitions.

This review has a number of limitations. Firstly, the search strategy was limited to the key words in the titles/abstracts of the publications. Thus, we might have missed some papers. Secondly, the search engine was restricted to PubMed. Thirdly, non-English publications were not considered in this study. Thirdly, we included studies that used mixed cyst sizes and locations (prechiasmatic,

lateral, and infratentorial expansions) and thus providing specific conclusion was not possible. Finally, Although the brachytherapy method has emerged as less invasive, effective, harmless, economical, and easy to perform and valid technique to manage properly selected CPs, there has been no any systematic study with large samples comparing ³²P therapy alone with combined treatment by surgery first and followed by ³²P in the literatures ¹⁸.

CONCLUSION

³²P intracavitary irradiation is a reasonable option in highly selected patients with newly diagnosed or recurrent cystic craniopharyngioma. This method can be expected to overcome some limitations with a relatively low complication rates and a good quality of life.

ACKNOWLEDGMENT

The authors thank the staff of the Neurosurgery Unit at Shohada Tajrish Hospital, Tehran, Iran.

DISCLOSURE OF FUNDING

There is not any funding for this work.

COMPETING INTERESTS

The authors declare that they have no any competing interests.

REFERENCES

- Shapiro K, Till K, Grant DN. Craniopharyngiomas in childhood. A rational approach to treatment. *J Neurosurg.* 1979;50 (5):617-23.
- Müller HL. Childhood craniopharyngioma—current concepts in diagnosis, therapy and follow-up. *Nat Rev Endocrinol.* 2010;6(11):609-18.
- Shahzadi S, Sharifi G, Andalibi R, Zali A, Ali-Asgari A. Management of cystic craniopharyngiomas with intracavitary irradiation with ³²P. *Arch Iran Med.* 2008 Jan;11(1):30-4.
- Müller HL. Craniopharyngioma. *Endocr Rev.* 2014;35:513-43.
- Leksell L, Bactdud EO, Johansson L. Treatment of craniopharyngiomas. *Acta Chir Scand* 1967; 133(5):345-350.
- Lunsford LD, Gumerman L, Levine G. Stereotactic intracavitary irradiation of cystic neoplasms of the brain. *Appl Neurophysiol.* 1985;48 (1-6):146-50.
- Tian Z. Stereotactic intracavitary irradiation of large cystic craniopharyngiomas. *J Clin Neurosci.* 1997;4 (2):161-2.
- Barriger RB, Chang A, Lo SS, Timmerman RD, DesRosiers C, Boaz JC, Fakiris AJ. Phosphorus-32 therapy for cystic craniopharyngiomas. *Radiother Oncol.* 2011 Feb;98(2):207-12.
- Pollock BE, Lunsford LD, Kondziolka D, Levine G, Flickinger JC. Phosphorus-32 intracavitary irradiation of cystic craniopharyngiomas: current technique and long-term results. *Int J Radiat Oncol Biol Phys.* 1995 Sep 30;33(2):437-46.
- Therasse P, Arbutck SG, Eisenhauer EA, Wanders J, Kaplan RS, Rubinstein L, et al. New guidelines to evaluate the response to treatment in solid tumors. European Organization for Research and Treatment of Cancer, National Cancer Institute of the United States, National Cancer Institute of Canada. *J Natl Cancer Inst.* 2000 Feb 2;92(3):205-16.
- Pollack IF, Lunsford LD, Slamovits TL, Gumerman LW, Levine G, Robinson AG. Stereotaxic intracavitary irradiation for cystic craniopharyngiomas. *J Neurosurg.* 1988 Feb;68(2):227-33.
- Kickingereder P, Maarouf M, El Majdoub F, Fuetsch M, Lehrke R, Wirths J, Et al. Intracavitary brachytherapy using stereotactically applied phosphorus-32 colloid for treatment of cystic craniopharyngiomas in 53 patients. *J Neurooncol.* 2012 Sep;109(2):365-74.
- Anderson DR, Trobe JD, Taren JA, Gebarski SS. Visual outcome in cystic craniopharyngiomas treated with intracavitary phosphorus-32. *Ophthalmology.* 1989 Dec;96(12):1786-92.
- Hasegawa T, Kondziolka D, Hadjipanayis CG, Lunsford LD. Management of cystic craniopharyngiomas with phosphorus-32 intracavitary irradiation. *Neurosurgery.* 2004 Apr;54(4):813-20.
- Floyd JR, Cmelak A, Russell P, Weaver KD. Endoscopic, image-guided, transnasal instillation of (³²P) for recurrent infrachiasmatic cystic craniopharyngioma. *Minim Invasive Neurosurg.* 2009 Jun;52(3):137-40.
- Einhaus SL, Sanford RA. Craniopharyngiomas. In: Albright AL, Pollack IF, Adelson PD (eds) *Principles and practice of pediatric neurosurgery.* Thieme, New York, 1999. pp 545–562.
- Hall WA, Liu H, Truwit CL. Intraoperative MR-guided instillation of phosphorus-32 for cystic craniopharyngiomas: case report. *Technol Cancer Res Treat.* 2003;2(1):19-24.
- Zhao R, Deng J, Liang X, Zeng J, Chen X, Wang J. Treatment of cystic craniopharyngioma with phosphorus-32 intracavitary irradiation. *Childs Nerv Syst.* 2010 May;26(5):669-74.
- Lunsford LD, Pollock BE, Kondziolka DS, Levine G, Flickinger JC. Stereotactic options in the management of craniopharyngioma. *Pediatr Neurosurg.* 1994;21 Suppl 1:90-7.
- Voges J, Sturm V, Lehrke R, Treuer H, Gauss C, Berthold F. Cystic craniopharyngioma: long-term results after intracavitary irradiation with stereotactically applied colloidal beta-emitting radioactive sources. *Neurosurgery.* 1997 Feb;40(2):263-9; discussion 269-70.
- Albright AL, Hadjipanayis CG, Lunsford LD, Kondziolka D, Pollack IF, Adelson PD. Individualized treatment of pediatric craniopharyngiomas. *Childs Nerv Syst.* 2005 Aug;21(8-9):649-54.
- Schefter JK, Allen G, Cmelak AJ, Johnson M, Toms S, Duggan D, et al. The utility of external beam radiation and intracystic

- ^{32}P radiation in the treatment of craniopharyngiomas. *J Neurooncol.* 2002 Jan;56(1):69-78.
23. Taasan V, Shapiro B, Taren JA, Beierwaltes WH, McKeever P, Wahl RL, et al. Phosphorus-32 therapy of cystic Grade IV astrocytomas: technique and preliminary application. *J Nucl Med.* 1985 Nov;26(11):1335-8.
 24. Kobayashi T, Kageyama N, Ohara K. Internal irradiation for cystic craniopharyngioma. *J Neurosurg.* 1981;55(6):896-903
 25. Kumar PP, Good RR, Skultety FM, Jones EO, Chu WK. Retreatment of recurrent cystic craniopharyngioma with chromic phosphorus P 32. *J Natl Med Assoc.* 1986 Jun;78(6):542-3, 547-9.
 26. Winn RH (Ed). *Youmans neurological surgery.* Aghi MK, McDermott MW, Sneed PK, Berger MS. Interstitial and intracavitary irradiation of brain tumors. Chapter 253. Philadelphia: W.B. Saunders Press; 2011. pp. 2609- 2615.
 27. Elliott RE, Hsieh K, Hochm T, Belitskaya-Levy I, Wisoff J, Wisoff JH. Efficacy and safety of radical resection of primary and recurrent craniopharyngiomas in 86 children. *J Neurosurg Pediatr.* 2010 Jan;5(1):30-48.
 28. Sands SA, Milner JS, Goldberg J, Mukhi V, Moliterno JA, Maxfield C, et al. Quality of life and behavioral follow-up study of pediatric survivors of craniopharyngioma. *J Neurosurg.* 2005 Oct;103(4 Suppl):302-11.
 29. Müller HL, Gebhardt U, Teske C, Faldum A, Zwiener I, Warmuth-Metz M, et al. Study Committee of KRANIOPHARYNGEOM 2000. Post-operative hypothalamic lesions and obesity in childhood craniopharyngioma: results of the multinational prospective trial KRANIOPHARYNGEOM 2000 after 3-year follow-up. *Eur J Endocrinol.* 2011 Jul;165(1):17-24.
 30. Lin LL, El Naqa I, Leonard JR, Park TS, Hollander AS, Michalski JM, et al. Long-term outcome in children treated for craniopharyngioma with and without radiotherapy. *J Neurosurg Pediatr.* 2008 Feb;1(2):126-30.
 31. Ishida M, Hotta M, Tsukamura A, Taga T, Kato H, Ohta S, et al. Malignant transformation in craniopharyngioma after radiation therapy: a case report and review of the literature. *Clin Neuropathol.* 2010 Jan-Feb;29(1):2-8.
 32. Aquilina K, Merchant TE, Rodriguez-Galindo C, Ellison DW, Sanford RA, Boop FA. Malignant transformation of irradiated craniopharyngioma in children: report of 2 cases. *J Neurosurg Pediatr.* 2010 Feb;5(2):155-61.
 33. Kobayashi T, Kida Y, Mori Y, Hasegawa T. Long-term results of gamma knife surgery for the treatment of craniopharyngioma in 98 consecutive cases. *J Neurosurg.* 2005 Dec;103(6 Suppl):482-8.
 34. Kobayashi T. Long-term results of gamma knife radiosurgery for 100 consecutive cases of craniopharyngioma and a treatment strategy. *Prog Neurol Surg* 2009; 22: 63-76.
 35. Julow J, Backlund EO, Lányi F, Hajda M, Bálint K, Nyáry I, et al. Long-term results and late complications after intracavitary yttrium-90 colloid irradiation of recurrent cystic craniopharyngiomas. *Neurosurgery.* 2007 Aug;61(2):288-95; discussion 295-6.
 36. Young HF, Fu YS, Fratkin MJ. Organ culture of craniopharyngioma and its cellular effects induced by colloidal chromic phosphate. *J Neuropathol Exp Neurol* 1976;35(4):404-412.
 37. Sadeghi M, Moradi S, Shahzadi S, Pourbeigi H. Dosimetry of (^{32}P) radiocolloid for treatment of cystic craniopharyngioma. *Appl Radiat Isot.* 2007 May;65(5):519-23.
 38. Hechtman CD, Li Z, Mansur DB, Perez CA, Myerson RJ, Simpson JR, et al. Dose distribution outside of a sphere of P-32 chromic phosphorous colloid. *Int J Radiat Oncol Biol Phys.* 2005 Nov 1;63(3):961-8.
 39. Derrey S, Blond S, Reyns N, Touzet G, Carpentier P, Gauthier H, et al. Management of cystic craniopharyngiomas with stereotactic endocavitary irradiation using colloidal ^{186}Re : a retrospective study of 48 consecutive patients. *Neurosurgery.* 2008 Dec;63(6):1045-52; discussion 1052-3.
 40. Janicki C, Seuntjens J. Re-evaluation of the dose to the cyst wall in P-32 radiocolloid treatments of cystic brain tumors using the dose-point-kernel and Monte Carlo methods. *Med Phys.* 2003;30(9):2475-81.
 41. Julow J, Lanyi F, Hajda M, Szeifert GT, Balint K, Drasny G, et al. Treatment of cystic craniopharyngiomas with yttrium-90 colloid solution. *Neurosurg Focus.* 1997 Dec 15;3(6):e6.
 42. Fahlbusch R, Hofmann BM. Surgical management of giant craniopharyngiomas. *Acta Neurochir (Wien).* 2008;150(12):1213-26.
 43. Cavallo LM, Frank G, Cappabianca P, Solari D, Mazzatenta D, Villa A, et al. The endoscopic endonasal approach for the management of craniopharyngiomas: a series of 103 patients. *J Neurosurg.* 2014 Jul;121(1):100-13.