

FAST and abnormal urinalysis: the effective screening tools in pediatric abdominal trauma



Majid Zamani, Farhad Heydari*, Mehrdad Esmailian

Emergency Medicine Research Center, Department of Emergency Medicine, Isfahan University of Medical Sciences, Isfahan, Iran

Received: 18 March 2018
Accepted: 23 April 2018
Published online: 1 May 2018

***Corresponding author:** Farhad Heydari;

Email: drfarhadheydari@gmail.com

Competing interests: None.

Funding information: The study was sponsored by Isfahan University of Medical Sciences.

Citation: Zamani M, Heydari F, Esmailian M. FAST and abnormal urinalysis: the effective screening tools in pediatric abdominal trauma. *Journal of Emergency Practice and Trauma* 2019; 5(1): 14-18. doi: 10.15171/jept.2018.05.

Abstract

Objective: The present study examines the diagnostic accuracy of abdominal ultrasonography and urinalysis test in children with blunt abdominal trauma, compared with CT scan. The aim of this study was to compare the diagnostic value of ultrasound and urinalysis test with CT scan as a golden standard diagnostic method in predicting abdominal peritoneal injury in these patients.

Methods: This prospective study, based on diagnostic accuracy evaluation, was performed on children with blunt abdominal traumas less than 12 years of age who were referred to the emergency department from 2017-2018 and for whom abdominal ultrasonography, urinalysis and abdominal CT scans were requested. Demographic data, mechanism of trauma, the results of urine tests, ultrasound and CT scan of the abdomen were recorded. Sensitivity, specificity, positive and negative predictive values were used to measure the diagnostic power of the tests.

Results: In this study, 100 children with multiple traumas were included. The mean age of these patients was 5.75 ± 3 years with a range of 1-12 years. In terms of sexual distribution, 69 (69%) were boys and 31 (31%) were girls. According to the results, ultrasound with an abnormal urinalysis test had sensitivity of 85.7%, specificity of 91.9%, positive predictive value of 63.2% and negative predictive value of 97.5%. The accuracy was 91%.

Conclusion: According to the results of this study, the combination of ultrasonography and urinalysis resulted in a significant increase in diagnostic value ($P < 0.001$). Pediatric patients with a negative ultrasonography and urinalysis test should be observed rather than subjected to the radiation risk of CT.

Keywords: Pediatric, Abdominal trauma, FAST, Urinalysis

Introduction

The outcome of a highly ill or injured child depends on the speed and precision of emergency care. This care begins with the rapid diagnosis of dangerous diseases and continues in all situations before and after the hospitalization. Despite profound advances in reduction of adults' mortality in emergencies, due to difficult diagnosis of life-threatening disorders in kids, this index has not significantly decreased in kids (1,2). The most important mortality cause in 1-12 year old kids is accidents which half of it consists of accidents with motor vehicles. The next main cause of death in kids includes falling (25%-30%) (3-6). More than half of death incident due to trauma happens in the place of accident. While if patient reaches the care center and has a constant condition for one hour after injury, he will have a good fate (3,4).

Blunt abdominal trauma is very common in children. The most susceptible parts that suffer are spleen, liver, genitourinary tract, stomach, small intestine, colon, pancreas, pelvis and large vessels respectively (7,8). The optimal treatment for injured children who have a stable condition is frequent physical examinations and CT scans

to confirm the existence and severity of the damage to the organs. Computed tomography scans have been identified as standard diagnostic tools, but CT-scan is not available in all areas and treatment centers and therefore efforts are needed to achieve a tool that can accurately determine the patient's condition. In this regard, some studies have shown the role of ultrasound in detecting such injuries (8-14). On the other hand, the presence of blood or blood elements in the urine from the past has been recognized as a predictive criterion for urinary tract damage, as well as severity of injury to other organs, and urinalysis is one of the most common evaluations in these patients, and according to these measures the next diagnosis is done (15).

Therefore, considering the findings and the fact that ultrasound is less invasive than CT scan and is more available, if this function is effective, it can replace the CT scan. On the other hand, ultrasound alone is not desirable (16-19). Other tests, such as liver enzymes are used in combination to improve the accuracy of ultrasound diagnosis (20). The present study aims to compare the diagnostic accuracy of ultrasound with urine test and CT



scan in intra abdominal injuries in children with multiple traumas referring to Ayatollah Kashani and Al-Zahra hospitals in Esfahan from May 2017 to February 2018.

Methods

This is a descriptive-analytic study carried out in 2017 and 2018 in the emergency department of Ayatollah Kashani and Al-Zahra hospitals in Esfahan. The inclusion criteria encompassed 1-12 year old children with multiple blunt abdominal traumas, referred to the emergency department in 2017 and 2018. It was also stipulated that children with a drop in pressure and with gross hematuria and referral from other centers and referral after 24 hours of trauma and injury to the head and organs were excluded.

Sampling method was census and all children with inclusion criteria entered the study. The minimum sample size was estimated according to the sample size estimation formula for the prevalence studies and the 95% confidence level and Sensitivity of ultrasound test was estimated to be 0.8 and the acceptance error rate was 0.1 in 61 cases.

The method of study was that children aged 1-12 years suffering from multiple traumas after receiving clinical history and physical examination were under abdominal ultrasound. In order to prevent subversion, all ultrasounds were taken by a radiologist and the results were recorded in a special checklist of the plan. On the other hand, based on the existing guidelines, after the visit of the surgeon, CT scan of the abdomen and pelvis with intravenous contrast was performed, and CT scan results were recorded. Urinalysis (U/A) was performed for all patients.

The data were finally entered into the computer and analyzed by SPSS version 20 and MedCalc software. The results of CT scan, ultrasound and urine test were compared. To analyze data, descriptive statistics, sensitivity and specificity, and positive and negative predictive values were used. The accuracy of the diagnosis and the KAPPA agreement test was used. For estimation accuracy, 95% confidence interval was used and $P < 0.05$ was considered as a significance level.

Results

In this study, 100 children with multiple traumas were included. The mean age of these patients was 5.75 ± 3 years with a range of 1-12 years. In terms of sexual distribution, 69 (69%) were boys and 31 (31%) were girls. The mean age of boys and girls was 5.75 ± 3.12 and 6.16 ± 2.84 years respectively. According to *t* test, there was no significant difference between the two sexes ($P = 0.37$).

According to the damage mechanism, the motor vehicle accident was 52% (including throwing off the car 7% and roll over the car 12%), bike accident 8%, pedestrian car collisions 29%, fall 9% and assault 2%.

In total, 58 children were discharged after being observed by the emergency department. 27 were admitted in the ward and 11 were admitted to the ICU, and four children were transferred to the operating room, only one of which

resulted in death. Demographic information is shown in Table 1.

Ultrasonography and urinalysis were performed for all patients and abdominal and pelvic CT scans in 90 patients. In 10 children that CT scan was not performed with the doctor's opinion, ultrasound and urinalysis were normal and children without any problem were discharged from the emergency department (these subjects were calculated in the normal CT scan group). According to the results, 20 patients had abnormal sonography, 22 had abnormal urine tests, and 14 had abnormal CT scan (including 17 injuries). The type of injury in these patients included 1 (5.8%) bladder injury and severe bleeding, 5 cases (29.4%) had kidney damage with low grade, 6 cases (35.3%) had liver damage and 5 cases (29.4%) had spleen injury. Two cases of patients with spleen injury, one patient suffering from liver damage and one patient with bladder injury were transferred to the operating room (4% of all patients). The only patient with bladder rupture died later. Figure 1 shows the percentage of injury type in patients with abnormal CT scan.

Table 1. Demographic and basic information in children

Variable	
Average age, Mean \pm SD	5.75 ± 3
Boy	5.75 ± 3.12
Girl	6.16 ± 2.84
Gender, No. (%)	
Boy	69 (69)
Girl	31 (31)
The mechanism, No. (%)	
Motor vehicle accident	52 (52)
Pedestrian car accident	29 (29)
Cycling crash	8 (8)
Fall	9 (9)
Assault	2 (2)
Abdominal examination, No. (%)	
Tenderness	30 (30)
Normal	70 (70)
Para-clinical findings, No. (%)	
Presence of hematuria	22 (22)
Free fluid in ultrasound	20 (20)
Abdominal injury in CT	14 (14)

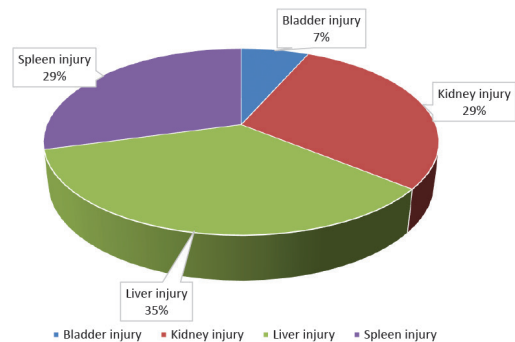


Figure 1. The percentage of injury type in patients with abnormal CT scan.

Based on the results, 14 patients had a positive CT and 10 cases had a positive ultrasound. In 76 patients with CT-negative and 10 patients without CT, ultrasound was also reported negative. Therefore, sensitivity, specificity and positive predictive value and negative predictive value of ultrasound test compared to CT scan were 71.4%, 88.3%, 50%, and 94.5% respectively. On the other hand, the likelihood ratio for positive and negative cases of ultrasound was 1.6 and 0.32. The accuracy of ultrasound was 86%.

Of 86 normal CT patients, 73 had normal urinalysis and 13 had positive urine tests (red blood cells in numbers greater than 50 in high power field). Of the 14 patients with CT-positive, 9 and 5 had positive and negative urine tests. Therefore, we obtained these findings based on the results: total urinalysis test with sensitivity of 64.3%, specificity of 84.9%, positive predictive value of 40.9% and negative predictive value of 93.5%. The likelihood ratio for positive and negative urinalysis test was 4.26 and 0.42 respectively. The accuracy of the test was 82%.

If the results of ultrasound and urinalysis are considered simultaneously, all statistical results will be significantly improved ($P < 0.001$) (Table 2). According to the results, ultrasound with an abnormal urine test had sensitivity of 85.7%, specificity of 91.9%, positive predictive value of 63.2%, and negative predictive value of 97.5%. The accuracy of the test was 91%.

According to the results, 70 patients with negative sonography also had a negative urine test, and their CT results were normal. They were discharged with good general condition from the hospital. In 4 patients, CT and urine tests were abnormal, and from the beginning they had hemoperitoneum in CT scan. Their ultrasound was also abnormal and they were sent to the operating room and underwent surgery. Five patients from the beginning had microhematuria in urinalysis and a few free fluids in the abdomen in ultrasound, but we did not see any abnormal findings in CT. These patients were eventually discharged with good general condition.

According to the findings, the combination of ultrasound results and urinalysis results caused a significant increase in sensitivity, specificity, positive and negative predictive value.

Discussion

The purpose of this study was to determine and compare the diagnostic accuracy of intra-abdominal injuries by ultrasound and urinalysis test compared with CT scan in children with multiple traumas who referred to Ayatollah Kashani and Alzahra hospitals in Isfahan. In this study, 100 children, with a mean age of 5.75 ± 3 years, with multiple traumas were studied. Abdominal and pelvic ultrasound, CT scan, and urinalysis tests were performed for all children.

The results showed that sensitivity and specificity and positive predictive value and negative predictive value of ultrasound examination were 71.4%, 88.3%, 50%, and 94.5% respectively, compared to CT scan. The accuracy of ultrasound was 86%. On the other hand, this test had 10% false positive and 4% false negative. Due to the importance of the discovery of intra-abdominal free fluid, in patients with significant traumas, relying solely on ultrasound may lead to miss patients, and so that, it is necessary to perform extra measures and care for patients who are diagnosed with normal ultrasonography, which is one way to achieve complete assurance that CT scan is performed in these patients. But due to the lack of CT scan facilities in all of the treatment centers and its high cost, if other diagnostic and assurance tests can be used, a large number of patients can be evaluated without a CT scan. Other suggested methods include using para-clinical tests, such as urinalysis to determine hematuria (due to kidney damage), amylase and lipase, and liver enzymes (in cases of suspected liver trauma). Ultrasonography and urinalysis alone have a low sensitivity and positive predictive value. According to the results of this study, the combination of ultrasound and urinalysis results lead to a significant increase in sensitivity, specificity, positive and negative predictive value ($P < 0.001$) (Table 2).

According to the results, ultrasound with an abnormal urine test has a sensitivity of 85.7%, 91.9%, positive predictive value of 63.2%, and negative predictive value of 97.5%. The accuracy of the test was 91%. Meanwhile, false positive cases dropped from 11 to 7 and false negatives from 5 to 2. Consequently, if the result of ultrasound and urine tests does not indicate intraabdominal injury and the patient's general condition is also satisfactory, with

Table 2. Comparison of ultrasound statistical results by ultrasound with abnormal urine test

Variable	Ultrasound	Ultrasound and abnormal urinalysis	P value
True positive	9	12	
True negative	75	79	
False positives	11	7	
False negative	5	2	
Sensitivity	71.4	85.7	<0.001
Specificity	88.3	91.9	<0.001
Positive predictive value	50	63.2	<0.001
Negative predictive value	94.5	97.5	<0.001
Accuracy	86	91	<0.001

high reliability can be assured that the patient do not have serious damage and evaluated the patient without performing a CT scan.

Similar results were obtained in the study by Sola et al in which they combined the results of ultrasonography with abnormal liver enzymes (19). In the study of Fox et al, similar results were obtained from ultrasonography in abdominal trauma in children and according to their study, the positive predictive value of ultrasound was 45% and the negative predictive value was 95% (14).

Also, in the study of Raz et al, the sensitivity of ultrasound was 59%, its specificity was 14%, and the positive predictive value was 48% (15). Kim and colleagues studied ultrasound with 61.3% sensitivity, 96.3% attribute and 89.1% positive predictive value (16).

On the other hand, in the study of Retzlaff et al, The diagnostic accuracy of ultrasound in diagnosis of abdominal and pelvic trauma was more than 97%, which is higher than the accuracy of our study (17).

The cause of low sensitivity of ultrasound is the absence of free fluid in most cases of low grade liver and spleen damage, as well as damage to the pancreas and kidneys. For example, the Fox and colleagues in 2011 analyzed 357 children (0–17 years) with blunt abdominal traumas, 23 patients had significant hemoperitoneum (22 on CT and one at surgery). Twelve of the 23 had true-positive FAST (sensitivity = 52%). FAST was true negative in 321 of 334 (specificity = 96%). In this study, the positive predictive value of ultrasound was 45% and the negative predictive value was 95% (14).

In a study by Raz et al in 2011, 47 children were diagnosed with blunt abdominal trauma, of which 59% had microhematuria and 41% macrohematuria. In CT scan, 67% of patients with microhematuria and 16% of children with macrohematuria were not injured. The sensitivity of ultrasound in this study was 59%, its specificity was 14%, and the positive predictive value was 48% (15). In a study by Kim et al in 2012, 240 trauma patients whose CT scan results were available were evaluated. Of these, 80 (33.3%) had free fluid, and compared with CT scan, ultrasound had 61.3% sensitivity, 96.3% and 89.1% positive predictive values (16).

Conclusion

According to the results of this study, the combination of ultrasonography and urinalysis resulted in a significant increase in diagnostic value. Pediatric patients with a negative ultrasonography and urinalysis test should be observed rather than subjected to the radiation risk of CT.

Limitations

Because the studied patients were selected from conscious children with stable vital signs, the results of this study may not be generalized to other patients.

Acknowledgments

The authors appreciate the insightful cooperation of

doctors and residents of Medical Sciences and the staffs of the emergency departments of Al-Zahra and Ayatollah Kashani hospitals in Isfahan, Iran.

Authors' contributions

All authors performed the data collection, writing, critical revision and drafting of the manuscript.

Ethical issues

The study was approved by the by the Ethics Committee of Isfahan University of Medical Sciences (IR.MUI.REC.1397.2.019).

References

- Schmidt TA, Salo D, Hughes JA, Abbott JT, Geiderman JM, Johnson CX, et al. Confronting the ethical challenges to informed consent in emergency medicine research. *Acad Emerg Med* 2004; 11(10): 1082-9. doi: 10.1197/j.aem.2004.05.028.
- Arias E, MacDorman MF, Strobino DM, Guyer B. Annual summary of vital statistics--2002. *Pediatrics* 2003; 112(6 Pt 1): 1215-30.
- Soudack M, Epelman M, Maor R, Hayari L, Shoshani G, Heyman-Reiss A, et al. Experience with focused abdominal sonography for trauma (FAST) in 313 pediatric patients. *J Clin Ultrasound* 2004 ;32(2):53-61. doi: 10.1002/jcu.10232.
- Poletti PA, Kinkel K, Vermeulen B, Irmay F, Unger PF, Terrier F. Blunt abdominal trauma: should US be used to detect both free fluid and organ injuries? *Radiology* 2003; 227(1): 95-103. doi: 10.1148/radiol.2271020139.
- Kirkpatrick AW. Clinician-performed focused sonography for the resuscitation of trauma. *Crit Care Med* 2007; 35(5 Suppl):S162-72. doi:10.1097/01.ccm.0000260627.97284.5d.
- Ashrafi A, Heydari F, Kolahdouzan M. The utility of ultrasound and laboratory data for predicting intra-abdominal injury among children with blunt abdominal trauma. *Int J Pediatr* 2018; 6(8): 8047-59. doi: 10.22038/ijp.2018.29824.2626.
- Meera T, Nabachandra H. A study of pattern and injury severity score in blunt thoraco-abdominal trauma cases in Manipal. *Medico-Legal Update* 2005; 5(2): 47-52.
- Goletti O, Ghiselli G, Lippolis PV, Chiarugi M, Braccini G, Macaluso C, et al. The role of ultrasonography in blunt abdominal trauma: results in 250 consecutive cases. *J Trauma* 1994; 36(2): 178-81.
- Patel JC, Tepas J 3rd. The efficacy of focused abdominal sonography for trauma (FAST) as a screening tool in the assessment of injured children. *J Pediatr Surg* 1999; 34(1): 44-7.
- Akgur FM, Aktug T, Kovanhkaya A, Erdag G, Olguner M, Hosgor M, et al. Initial evaluation of children sustaining blunt abdominal trauma: ultrasonography vs. diagnostic peritoneal lavage. *Eur J Pediatr Surg* 1993; 3(5): 278-80. doi: 10.1055/s-2008-1063559.
- Luks FI, Lemire A, St-Vil D, Di Lorenzo M, Filiatrault D, Ouimet A. Blunt abdominal trauma in children: the practical value of ultrasonography. *J Trauma* 1993; 34(5): 607-10.
- Filiatrault D, Longpre D, Patriquin H, Perreault G, Grignon A, Pronovost J, et al. Investigation of childhood blunt

- abdominal trauma: a practical approach using ultrasound as the initial diagnostic modality. *Pediatr Radiol* 1987; 17(5): 373-9.
13. Hoelzer DJ, Brian MB, Balsara VJ, Varner WD, Flynn TC, Miner ME. Selection and nonoperative management of pediatric blunt trauma patients: the role of quantitative crystalloid resuscitation and abdominal ultrasonography. *J Trauma* 1986; 26(1): 57-62.
 14. Fox JC, Boysen M, Gharahbaghian L, Cusick S, Ahmed SS, Anderson CL, et al. Test characteristics of focused assessment of sonography for trauma for clinically significant abdominal free fluid in pediatric blunt abdominal trauma. *Acad Emerg Med* 2011; 18(5): 477-82. doi: 10.1111/j.1553-2712.2011.01071.x.
 15. Raz O, Haifler M, Copel L, Lang E, Abu-Kishk I, Eshel G, et al. Use of adult criteria for slice imaging may limit unnecessary radiation exposure in children presenting with hematuria and blunt abdominal trauma. *Urology* 2011; 77(1): 187-90. doi: 10.1016/j.urology.2010.05.014.
 16. Kim CH, Shin SD, Song KJ, Park CB. Diagnostic accuracy of focused assessment with sonography for trauma (FAST) examinations performed by emergency medical technicians. *Prehosp Emerg Care* 2012; 16(3): 400-6. doi: 10.3109/10903127.2012.664242.
 17. Retzlaff T, Hirsch W, Till H, Rolle U. Is sonography reliable for the diagnosis of pediatric blunt abdominal trauma? *J Pediatr Surg* 2010; 45(5): 912-5. doi: 10.1016/j.jpedsurg.2010.02.020.
 18. Kessler DO. Abdominal Ultrasound for Pediatric Blunt Trauma: FAST Is Not Always Better. *JAMA* 2017; 317(22): 2283-5. doi: 10.1001/jama.2017.6163.
 19. Sola JE, Cheung MC, Yang R, Koslow S, Lanuti E, Seaver C, et al. Pediatric FAST and elevated liver transaminases: An effective screening tool in blunt abdominal trauma. *J Surg Res* 2009; 157(1): 103-7. doi: 10.1016/j.jss.2009.03.058.
 20. Scaife ER, Rollins MD, Barnhart DC, Downey EC, Black RE, Meyers RL, et al. The role of focused abdominal sonography for trauma (FAST) in pediatric trauma evaluation. *J Pediatr Surg* 2013; 48(6): 1377-83. doi: 10.1016/j.jpedsurg.2013.03.038.