

Effects of *Lactobacillus rhamnosus* (ATCC 7469) ointment on second-degree burn wound in Wistar rat

Amir Abbas Barzegari^{1*}, Masood Hashemzaei¹, Ali-Reza Alihemmati², Soroush Soltani¹, Behrouz Naseri¹

1. Department of Biology, Faculty of Basic science, University of Maragheh, Maragheh, Iran
2. Department of Histology and Embryology, Tabriz University of Medical Sciences, Tabriz, Iran

*Corresponding author: Tel: +98 4137278001 Fax: +98 4137276060

Address: Amir Abbas Barzegari, Department of Biology, Faculty of Basic science, University of Maragheh, Maragheh, East Azerbaijan Province, Iran

E-mail: abarzegari@maragheh.ac.ir

Received; 2017/09/6 revised; 2017/10/2 accepted; 2017/11/5

Abstract

Introduction: Burn is among the traumas that impose great physical and psychological damages to the injured people. Scientists still are looking for new treatments and methods for burn management that lack the defects of previous ones. Recently, the potential of probiotic bacteria for the treatment of skin disease and problems has been investigated. Considering that the effects of probiotics are strain-dependent, the aim of current study was to evaluate the effects of *Lactobacillus rhamnosus* (ATCC 7469) on the process of burn wound healing.

Materials and methods: After induction of second-degree burn wounds on the back of rats, they were randomly divided into experimental, vehicle control, and negative control groups. The experimental groups received a bacterial ointment for 1, 3, 7, and 14 days. The vehicle control groups received Eucerin for durations like the experimental groups. The negative control groups received no treatment in the same days. The evaluation of wound healing was conducted macroscopically by computing of the healing percent and microscopically by Hematoxylin and Eosin staining of the tissue samples of the wound area on different days.

Results: The wound healing percent in the experimental group, compared with control groups, significantly increased, until the day 7 of the experiments. Moreover, the microscopic results indicate that the bacteria may have some anti-inflammatory effects. Also, the bacteria increased the rate of fibroblastic migration and re-epithelialization in the wound area.

Conclusion: Overall, *L. rhamnosus* (ATCC 7469) when used topically on the burn wounds may have some positive effects on the process of burn wound healing.

Keywords: *Lactobacillus rhamnosus*, Probiotics, Burns, Wound healing, Rats

Introduction

The intolerable contact of skin tissues with thermal sources in sufficient time may induce the thermal burn wounds. Burn wounds are among the preventable traumas that have a high risk of incidence in developing countries (1). Dermatologists classify the cutaneous burn wounds with respect to the depth of skin lesions into one-, second- and third-degree levels. In the second- and third-degree burn wounds that involve both epidermis and dermis injuries, the healing process is

usually a long-term one. Because in skin lesions it loses part of its barrier function, the wound area is vulnerable to the entrance of pathogenic agents that may cause the local infection of the wounds and even the sepsis of injured persons. Although there are currently various drugs and methods for treatment of the wounds, because of the limitations and defects of such treatments (2, 3), scientists still showing great interests for finding new routes for burn management that in

addition to prevention of burn wound infection, have the ability to accelerate the healing process.

A nearly new context for treatment of skin diseases and problems that have recently attracted the attention of researchers is the application of probiotic organisms. One of the most accepted definition for probiotics is that they are microorganisms, especially the bacteria that if consumed in sufficient quantities by the host, may have beneficial effects on their hosts other than their probable nutritional properties (4). Moreover, the long history of probiotic use by the human in dairy products and their rare side-effects indicates their safety (5). One group of probiotic bacteria that have long been used in the dairy products and treatment of skin diseases are lactic acid bacteria (LAB). The functions and properties of probiotic bacteria are very specific; therefore, it is said that they have species or even strain-dependent effects (6, 7). Previous studies on the effects of topical treatment of wounds with some strains of lactic acid bacteria on the healing process have shown some promising results (8-11).

L. rhamnosus (ATCC 7469) is among the lactic acid bacteria that its application is in the trial stage. The role of the strain of bacteria in the modulation of the immune system has been shown in some previous research. Moreover, Sambantha Moorthy showed that some products of the strain of *L. rhamnosus* have antibacterial and anti-biofilm potential against the pathogenic bacteria that may infect wounds(12). Moreover, some previous studies indicate that *L. rhamnosus* GG accelerates the healing of gastric ulcer in rats and protects the integrity of the gastric mucosal barrier against nonsteroidal anti-inflammatory drugs (13) (14). In addition to these effects, *L. rhamnosus* (ATCC 7469) has modulatory effects on the immune system (15). Considering the above and because of specificity of probiotics effects that depend on species or even the strains that are used (6, 7), the

aim of current study was to evaluate the topical application of *L. rhamnosus* (ATCC 7469) on the healing of second-degree burn wound in male Wistar rats.

Materials and methods

Animals: In the current study, 60 male Wistar rats were used. The naive animals (weighing between 220-250g) obtained from pastor institute, Tehran, Iran and housed in a standard animal room with 12/12 h light-dark cycle and temperature about 22° C. There were a ten days interval until the beginning of the experiments for adaptation of the animals to the new conditions. All the animals had access to food and water, and libitum, before and during the experiments.

Microorganisms: The probiotic bacteria that were used in the experiments were *L. rhamnosus* (ATCC 7469) that were received from the Persian Type Culture Collection (PTTC) of Iranian research organization for science and technology. The bacterium was cultured anaerobically, for one day, at 37°C in the liquid MRS medium. After that, the medium containing bacteria, centrifuged for 20 min at 12000 rpm. Then, the obtained precipitant was washed two times with phosphate buffer. The fresh bacteria that were obtained in this method were used for the preparation of an ointment that contained 10^{10} to 10^{11} CFU/ml of freshly cultured bacteria in 4 ml of Eucerin. The ointment immediately used for treatment of the wound areas on the back of the rats. The animals of experimental groups received 0.8 ml of the mixture per rat.

Second-degree burn wound induction: All the animal experiments were conducted under the supervision of a local bioethics committee at the University of Maragheh. The method of burn wound induction was similar to the Dos Santos Tavares Pereira et al. with little modifications (16). In this protocol, initially, the rats received an anesthetic cocktail of xylazine (10 mg/ kg) and ketamine (90 mg/ kg), intraperitoneally

and the hairs of their dorsum around the area between the forelimbs were removed with a clipper. Then the area was antisepticated and a solid aluminum bar with a diameter of 10 mm (temperature about 100°) was contacted with the area for 15 seconds. After the induction of wounds, to reduce the pain of animals, all the rats received buprenorphine that has long analgesic effects in the rodents. Finally, each rat was placed in separate polycarbonate cages for the next steps of the experiments. The day of burn wound induction considered as day 0 of the experiments.

Experimental design: In the current study, the rats were randomly assigned to different negative control, vehicle control and experimental groups. Each group was further subdivided into four subgroups of five rats. In negative control subgroups, the rats received no treatment until the days of their euthanization in days of 1, 3, 7 and 14 post-burn. The rats in the vehicle control and the experimental groups received Eucerin as vehicle and a mixture of bacteria in Eucerin, respectively. In the experimental and the vehicle control groups, the rats of different subgroups received a daily treatment for 1, 3, 7, and 14 days after the burn induction.

Evaluation of wound healing: Macroscopic evaluation of wound healing was conducted with the calculation of wound healing percent. For this purpose, first, the periphery of the wounds in days 1, 3, 7, and 14 post-burn was depicted on a nylon sheet. Then, from a fixed distance, the images were photographed with a digital camera. In the next step, using the pictures of the wounds peripheries, the wounds surface area were measured by Digimizer software. For each rat, the percent of wound healing in different days was calculated.

For microscopic assessment of the wound healing, the skin samples of the wound area in 1st, 3th, 7th and 14th days of experiments were harvested for preparation of tissue slices as follow: First,

the tissue processing of the samples was conducted and the resulting specimens were embedded in paraffin for preparation of paraffin blocks of the tissue samples. Then, the blocks were cut into the sections with the thickness of 5 micrometers. After all, the sections were stained using the Hematoxylin-Eosin method. The stained tissue sections were studied for the finding the rate of the inflammatory response, fibroblasts migration, granulation tissue formation, and epithelialization in each tissue section. For this, a histologist, blind to the experiment conditions analyzed 5 different visual fields on each slide and the mean score of each evaluated parameter on the visual fields scored as follows: (-=absence), (+= mild presence), (+=moderate presence) and (+++ = strong presence). On each tissue slice, the presence of polymorphonuclear leukocytes (PNM) indicated the inflammatory response, the presence of fibroblasts, myofibroblasts, and neovascularization indicated the granular tissue formation, the density of fibroblasts indicated the fibroblast migration and the proliferation of squamous cells and keratinization indicated the Epithelization.

Statistical analysis

SPSS software was used for the analysis of all quantitative data. For comparison of the means, factorial ANOVA method was used and if the results were significant, LSD post hoc would be conducted. The results were expressed as mean± SEM. If $P < 0.05$ then the differences were considered significant.

Results

Macroscopic results: Comparison of the wound healing percent in different days showed that the experimental group, only in the day 7 post-burn, had a significantly higher percent of wound healing than the control ones. Moreover, in all experimental, vehicle control and negative control groups, in the day 3 of the

experiments, there was an increase in the wound area compared to the first day of the experiments, in other words, the percent of wound healing was negative in

all groups. After the 3th day of the experiments, the process of wound healing became positive for all groups (Figure1).

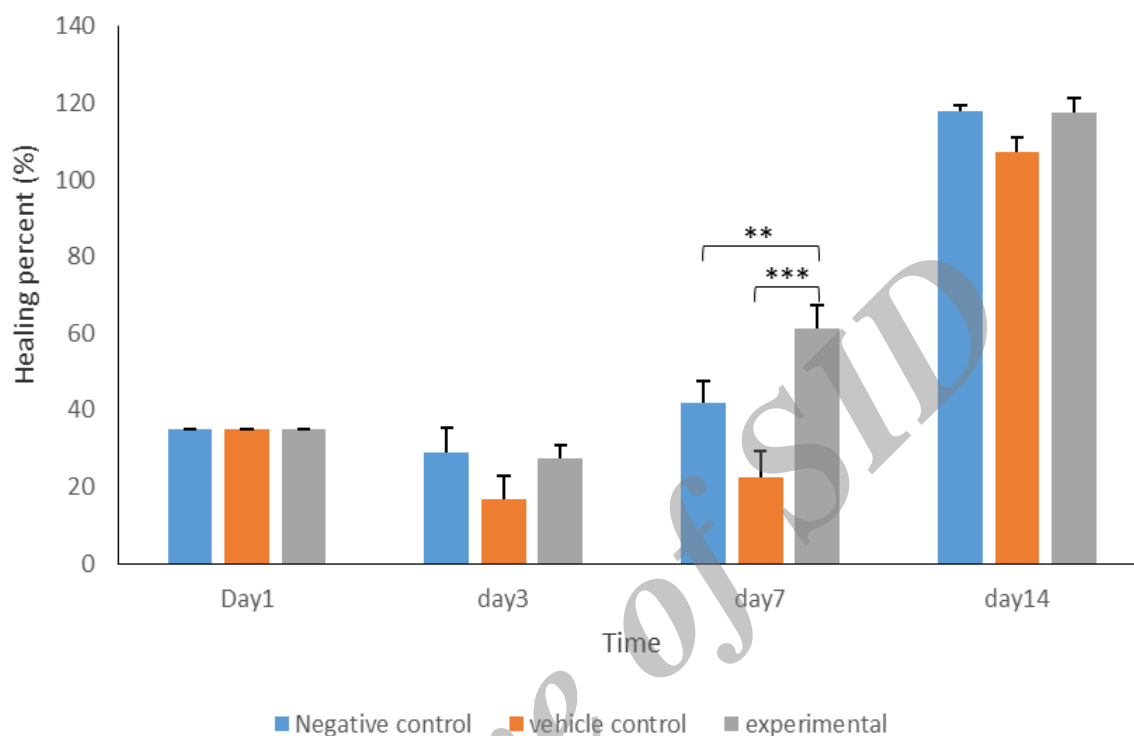


Figure1. In the 7th day of the experiments, the wound healing percent in experimental groups was significantly higher than both negative controls ($P<0.01$) and vehicle control ($P<0.001$) groups. ** indicates $P<0.01$ and *** indicates $P<0.001$.

Histological Results: Analyzing the tissue sections showed that the inflammatory response until the day 3 post-burn was high in all groups. Then, in all groups, the response decreased in the next days of the experiments. So, the most decrease in the inflammatory response was observed in the experimental group compared to the control ones. Among all groups, the most intense inflammatory response was observed in the vehicle control group. Evaluation of fibroblast migration showed that experimental group on day 7 of the experiments had the highest rate of fibroblast migration. On the other hand, there was a steady increase in the

granulation tissue formation and re-epithelialization from days 3 to 14 of the experiments in all groups. Moreover, on day 14 post-burn, both negative control and experimental groups had the highest granulation tissue formation compared to the vehicle control group. Moreover, the formation of epithelial tissue in the experimental group was the highest compared to the control ones especially in the days 7 and 14 post-injury (Table 1). Figures 2-5 shows the tissue changes in 1st, 3th, 7th and 14th days of the experiments in the experimental and control groups.

Table 1. Histopathological assessment of the degree of the inflammatory response, density of granulation tissue, fibroblast migration and new epithelialization of the tissue samples of the wound area, in 1st, 3th, 7th and 14th days' post- burn.

Groups	Time (Day)	Inflammatory Response	Fibroblast Migration	Granulation Tissue	Epithelialization
Negative Control	1st	+++	-	-	-
	3th	+++	+	+	+
	7th	++	++	++	+
	14th	++	++	+++	++
Vehicle Control	1st	+++	-	-	-
	3th	+++	+	+	+
	7th	+++	++	++	+
	14th	++	++	++	++
<i>L. rhamnosus</i>	1st	+++	-	-	-
	3th	+++	+	+	+
	7th	+	+++	+++	++
	14th	+	++	++	+++

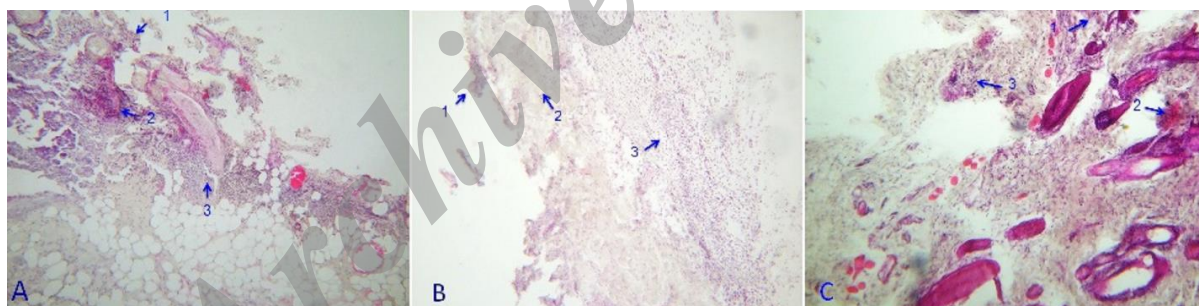


Figure 2. Superficial tissues necrosis (1), intense denaturation of deep collagen fibers (2) and leukocyte infiltration in 1th day of the experiments, in the negative control (A), vehicle control (B) and the experimental (c) groups.

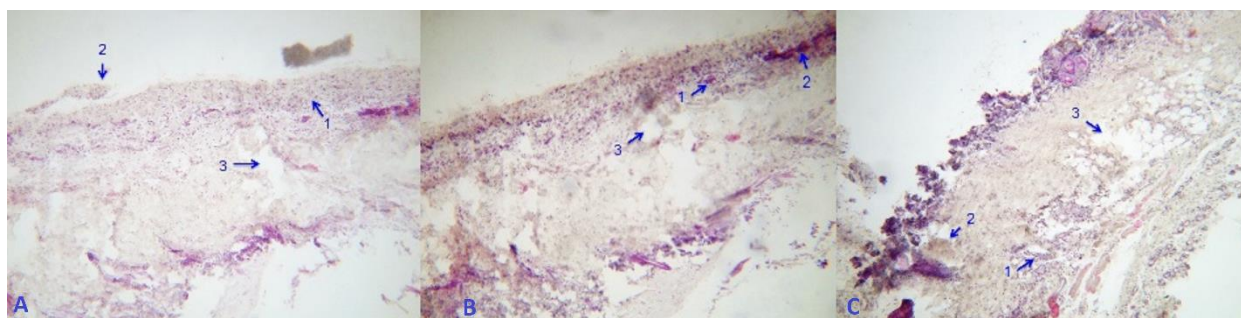


Figure 3. Leukocyte infiltration (1) formation of necrotic tissue (2) and disruption of dermal tissues (3), in 3th day of the experiments, in the negative control (A), vehicle control (B) and experimental (c) groups.

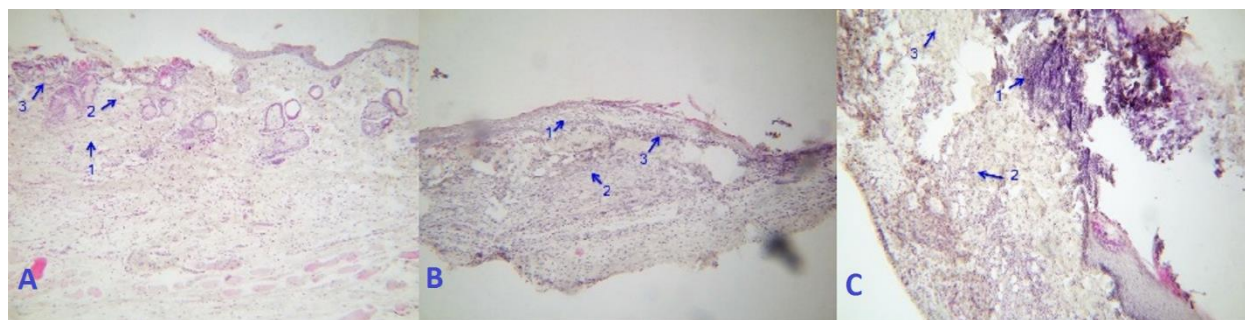


Figure 4. Tissue changes in 7th days of the experiments. Parts A and B show the proliferation of fibroblast and collagen deposition (1), the appearance of new blood vessels (2) and infiltration of inflammatory cells (3) in negative control and vehicle control groups, respectively. Part C shows the high density of inflammatory cell (1), widespread proliferation of fibroblasts (2) and more density of fibrotic tissues (3) in the experimental group.

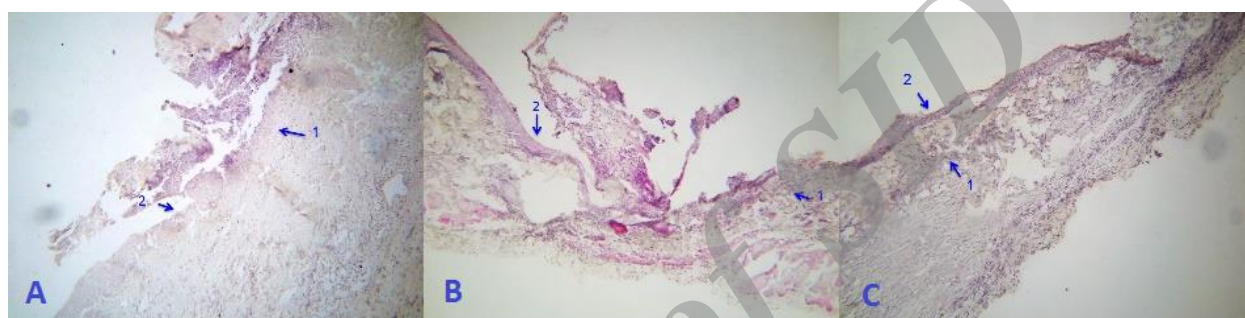


Figure 5. Microscopic picture of tissue samples of (A) negative control, (B) vehicle control and (c) experimental groups in 14th days of the experiments. Partial reduction in the inflammatory response (1) and formation of more regular epithelium (2).

Discussion

Wound healing is a coordinated process that has three overlapping steps including; inflammatory, proliferative and remodeling phases (17). The first step, inflammatory phase, is needed for combating with the pathogens that penetrating through wound area. The decrease in inflammation of the wound area indicates the success of the immune system against the pathogens and signals the initiation of the next phase i.e. proliferative phase. Therefore, Prolongation of the stage indicates that there is still a battle between pathogens and immune cells in the wound area, so the overall process of wound healing may take more time. In day 3 of the experiments, the inflammatory response in all the groups was very high; therefore, none of the groups not only did showed any healing but also had negative healing, namely the wound area increased compared to the day 1. The increase in the wound area on day 3

can also be ascribed to skin muscle tension around the wound area. As we saw from the results section, in the experimental group, the percent of wound healing, on day 7 post-burn was significantly higher than control ones. As it was shown in table 1, in the experimental group the density of the granulation tissue and the re-epithelialization on the day 7 were high. As we know, the process of re-epithelialization and the contraction of the myofibroblasts have an important role in acute wounds closures; therefore, on the day 7, the experimental group had the highest percent of wound healing in comparison to control groups. Moreover, on the day 7, while the inflammatory response in the experimental group was very low, the response was still relatively high in the control ones. Therefore, it can be deduced that the prolongation of the inflammatory response in the control groups is another reason for the retard in

the healing process and the less percent of wound healing in the groups, on day 7. As we saw, on day 14 of the experiments, the experimental group, with respect to wound healing, had no advantage to control groups. Table 1 shows that the process of the re-epithelialization in the experimental group is higher than the control ones on the days 7 and 14 of the experiments. Moreover, the density of myofibroblasts in experimental group was high in the day 7 post-burn. Because of both issues, the closure of the wound area in the experimental group began sooner and there was less surface area for the probiotic bacteria that exert their effects; therefore, in the day 14 post-burn, with respect to the wound healing process, there was no advantage in the experimental group compared to the control ones.

Conclusion

Briefly, the results of the current study showed that *L. rhamnosus* (ATCC 7469) may accelerate the healing process of burn wound healing at least in middle phases of the process. It seems that the bacterium exerts its effects on the wound healing through the different mechanisms like reducing the inflammatory response and increasing the fibroblast migration and re-epithelialization. These results are consistent with the findings of previous research that has shown the positive effects of some strain of probiotic bacteria in these respects. For example, research indicates that some strains of probiotic bacteria have anti-inflammatory properties (18, 6). Moreover, positive effects of some lactic acid bacteria on the epidermal cells and the fibroblastic migration have been shown by other research (19, 20, 9).

The results of the current study are in line with previous ones which have shown that some strains of probiotic bacteria, when used topically, may exert positive influences on the wound healing process.

For example, in one limited clinical study by Peral et al, epicutaneous application of the *Lactobacillus plantarum* on the second and third-degree-burn wounds had promising effects on the wound healing (8). Moreover, the results of other studies on the effects of local application of kefir grains, the mixtures of probiotic organisms, on the skin wounds indicated that kefir grains in addition to prevention of bacterial infection of the wounds may accelerate the healing processes of the wounds (10, 11).

Although, the overall conclusion of the current study is that the topical use of *L. rhamnosus* (ATCC 7469) on the burn wounds may have some positive effects on the healing processes of the wounds; but, there are some limitations in this study. The main limitation of the experimental results is that the current study conducted on a rat model of burn wounds. As we know, the structure of skin in rat and human have some crucial differences. For example, rat and human skin are different from each other with respect to hair follicle distribution and the presence of cutaneous muscle, panniculus carnosus, in the rats that play a major role in the wound healing process (21). Therefore, in addition to other complementary experimental studies, the effects of the bacterial strain on the wound-healing should be studied clinically on the human volunteer patients with burn-wounds. Thus, there should be many new studies before the use of the strain of bacterium in the treatment of burn wound.

Acknowledgements

We thanks the socio-cultural affairs of the University of Maragheh (Scientific Society of Biology) for their financial supports.

Conflict of interest

There is no conflicts of interests to declare.

References

1. Ahuja RB, Bhattacharya S. Burns in the developing world and burn disasters. *BMJ*. 2004; 329(7463):447.
2. Percival S, Bowler P, Russell D. Bacterial resistance to silver in wound care. *J Hosp Infect*. 2005; 60(1):1-7.
3. Cho A-R. Effect of silver sulfadiazine on the skin cell proliferation and wound healing process in hairless mouse 2nd degree burn model. *J Pharm Investig*. 2002; 32(2):113-7.
4. Araya M, Morelli L, Reid G, Sanders M, Stanton C, Pineiro M. Joint FAO/WHO Working Group report on drafting guidelines for the evaluation of probiotics in food. London, Canada: World Health Organization, Food and Agriculture Organization of the United Nations. 2002.
5. Borriello S, Hammes W, Holzapfel W, Marteau P, Schrezenmeir J, Vaara M et al. Safety of probiotics that contain lactobacilli or bifidobacteria. *Clin Infect Dis*. 2003; 36(6):775-80.
6. Kekkonen RA, Lummela N, Karjalainen H, Latvala S, Tynkkynen S, Järvenpää S et al. Probiotic intervention has strain-specific anti-inflammatory effects in healthy adults. *World J Gastroenterol*. 2008; 14(13):2029-36.
7. Maassen CB, Claassen E. Strain-dependent effects of probiotic lactobacilli on EAE autoimmunity. *Vaccine*. 2008; 26(17):2056-7.
8. Peral MC, Huaman Martinez MA, Valdez JC. Bacteriotherapy with *Lactobacillus plantarum* in burns. *Int Wound J*. 2009; 6(1):73-81.
9. Nasrabadi H, Ebrahimi T, Banadaki D, Kajousangi T. Study of cutaneous wound healing in rats treated with *Lactobacillus plantarum* on days 1, 3, 7, 14 and 21. *Afr J Pharm Pharmacol*. 2011; 5(21):2395-401.
10. Rodrigues KL, Caputo LRG, Carvalho JCT, Evangelista J, Schneedorf JM. Antimicrobial and healing activity of kefir and kefir extract. *Int J Antimicrob Agents*. 2005; 25(5):404-8.
11. Huseini HF, Rahimzadeh G, Fazeli MR, Mehrazma M, Salehi M. Evaluation of wound healing activities of kefir products. *Burns*. 2012; 38(5):719-23.
12. Sambanthamoorthy K, Feng X, Patel R, Patel S, Paravitana C. Antimicrobial and antibiofilm potential of biosurfactants isolated from lactobacilli against multi-drug-resistant pathogens. *BMC Microbiol*. 2014; 14(1):197.
13. Gotteland M, Cruchet S, Verbeke S. Effect of *Lactobacillus* ingestion on the gastrointestinal mucosal barrier alterations induced by indometacin in humans. *Aliment Pharmacol Ther*. 2001; 15(1):11-7.
14. Lam EK, Yu L, Wong HP, Wu WK, Shin VY, Tai EK et al. Probiotic *Lactobacillus rhamnosus* GG enhances gastric ulcer healing in rats. *Eur J Pharmacol*. 2007; 565(1):171-9.
15. Jorjão AL, Oliveira FED, Leão MVP, Carvalho CAT, Jorge AOC, Oliveira LDd. Live and heat-killed *Lactobacillus rhamnosus* ATCC 7469 may induce modulatory cytokines profiles on macrophages RAW 264.7. *Sci World J*. 2015; 2015:716749.
16. Pereira T, Dos Santos D, Lima-Ribeiro MHM, de Pontes-Filho NT, Carneiro-Leão AMdA, Correia MTdS. Development of animal model for studying deep second-degree thermal burns. *Biomed Res Int*. 2012; 2012 .
17. Gonzalez ACdO, Costa TF, Andrade Zda, Medrado ARAP. Wound healing- A literature review. *An Bras Dermatol*. 2016; 91(5):614-20.
18. von Schillde M-A, Hörmannspurger G, Weiher M, Alpert C-A, Hahne H, Bäuerl C et al. Lactocepin secreted by *Lactobacillus* exerts anti-inflammatory effects by selectively degrading

- proinflammatory chemokines. *Cell Host Microbe*. 2012; 11(4):387-96.
19. Prince T, McBain AJ, O'Neill CA. *Lactobacillus reuteri* protects epidermal keratinocytes from *Staphylococcus aureus*-induced cell death by competitive exclusion. *Appl Environ Microbiol*. 2012; 78(15):5119-26.
 20. Mohammedsaeed W, Cruickshank S, McBain AJ, O'Neill CA. *Lactobacillus rhamnosus* GG Lysate Increases Re-Epithelialization of Keratinocyte Scratch Assays by Promoting Migration. *Sci Rep*. 2015 5;5:16147.
 21. Dorsett-Martin WA. Rat models of skin wound healing: a review. *Wound Repair Regen*. 2004; 12(6):591-9.

Archive of SID