



DOI: 10.19187/abc.20163266-69

## Bell's Palsy As a Rare First Presentation of Breast Cancer

 Mostafa Hosseini<sup>a</sup>, Elham Vafaei<sup>a</sup>, Rahele Moein Ara<sup>b</sup>, Alimohamad Asghari<sup>c</sup>, Nahid Nafissi<sup>\*a, b</sup>
<sup>a</sup> Department of Surgery, Hazrat-e Rasoul Akram Hospital, Iran University of Medical Sciences, Tehran, Iran

<sup>b</sup> Cancer center, Khatam Al-Anbia Hospital, Tehran, Iran

<sup>c</sup> Department of Otolaryngology, Hazrat-e Rasoul Akram Hospital, Iran University of Medical Sciences, Tehran, Iran

### ARTICLE INFO

**Received:**  
15 April 2016  
**Revised:**  
4 May 2016  
**Accepted:**  
10 June 2016

**Keywords:**  
Metastasis,  
breast cancer,  
temporal bone,  
cranial nerve palsy

### ABSTRACT

**Background:** Otagia and Bell's palsy are rare manifestations of metastasis and the most common presentation of an inflammatory process in the temporal bone.

**Case presentation:** This article explains a 34-year-old woman with breast cancer who presented with cranial nerve palsy symptoms. The 7<sup>th</sup> and 8<sup>th</sup> cranial nerves were involved in the metastatic phase and then hoarseness was added to her symptoms. Brain MRI showed a petrous lesion in the temporal bone due to metastasis, which was the first clue to cancer. Her metastatic workup showed multiple bone lesions. On chest CT scan, multiple lung lesions were noted. Also, a breast mass was discovered on her chest CT scan. On breast examination an irregular mass fixed to the pectoralis muscle was found. Pathologic evaluation of samples obtained through ultrasound-guided core needle biopsy confirmed the diagnosis of invasive ductal carcinoma.

**Conclusion:** Temporal bone metastases are rare and may be asymptomatic, or with mild symptoms mimicking mastoid infections. Physicians should consider metastatic cancer on the list of differential diagnoses in patients presenting with prolonged otologic symptoms or facial nerve disorders.

### Introduction

Temporal bone lesions are most commonly inflammatory.<sup>1</sup> In patients with a history of cancer, metastases to the head and neck region are not frequent. Metastases to the temporal bone are rare and mostly originate from the breast, followed by lung, kidney, and prostate cancer and lymphoma.<sup>2,3</sup> The presentation is nonspecific and stable or progressive; therefore, a high index of suspicion is necessary for prompt and accurate diagnosis.

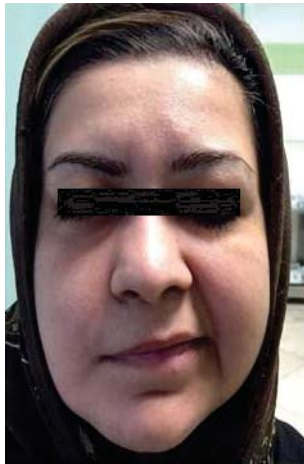### Case presentation

We report a 34-year-old female who presented with otalgia. She was initially treated with antibiotics. After three weeks, she presented with left eye ptosis as the first presentation of facial nerve palsy and received conservative anti-inflammatory therapy.

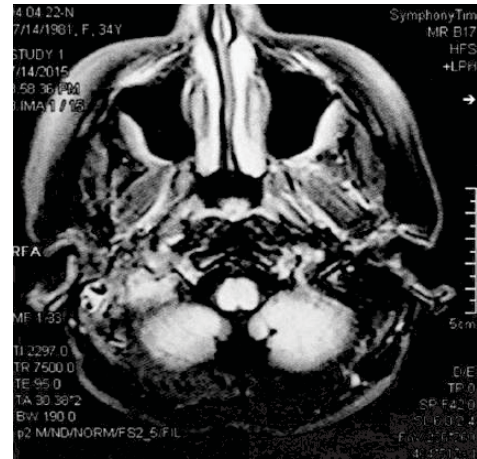
Two weeks later, the second facial nerve palsy was detected as a change in the lateral commissure of her lips (Figure 1). Consequently, brain MRI (with and without contrast) was done to identify the cause of Bell's palsy. An expert radiologist reported mucosal thickening in the left sphenoid sinus with an enhancing mass (35\*15 mm) at the body of the petrous bone with a normal CPA, and involvement of the 7<sup>th</sup> and 8<sup>th</sup> cranial nerves (Figure 2). The patient was hospitalized and prepared for open biopsy in the operating room. In this process, in less than one month, she experienced vocal hoarseness.

### Address for correspondence:

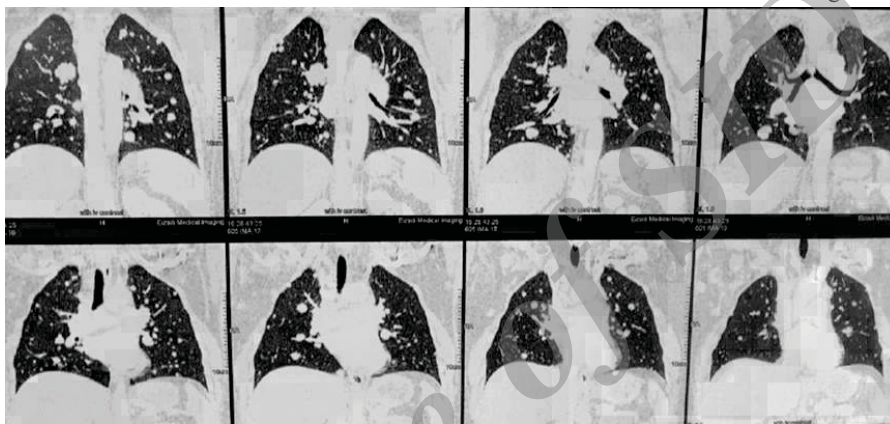
Nahid Nafissi, MD  
 Address: Hazrat-e Rasool General Hospital, Niyayesh St.,  
 Satarkhan St., Tehran, Iran  
 Tel: +98 21 66517341  
 Fax: +98 21 66517118  
 Email: nafissi.n@iums.ac.ir



**Figure 1.** Left eye ptosis and facial nerve palsy



**Figure 2.** Mucosal thickening at right sphenoid sinus with an enhancing mass in brain MRI



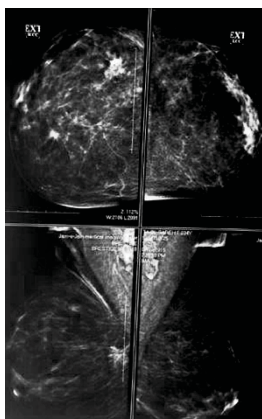
**Figure 3.** Multiple metastatic lesions in the lungs and a mass in right breast

proving that another cranial nerve was involved. Therefore, chest CT scan was done to rule out lung cancer or lung metastases. The CT scan showed multiple metastatic lesions in the lungs and a mass in the right breast (Figure 3). So, the team decided not to perform petrous bone biopsy and referred the case to a breast surgeon. The patient had never done breast self-examination (BSE) or undergone clinical breast exam in her life and ignored any breast problem at this time.

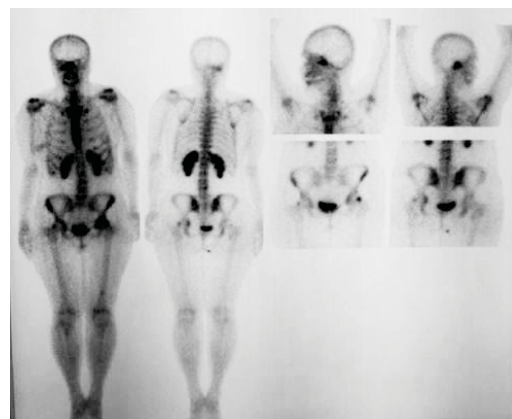
After a long discussion to decrease her anxiety, the breast surgeon did a physical examination and

found an irregular mass of approximately 25mm and a mass fixed to the pectoralis muscle in right upper outer quadrant of the right breast and axilla; so, mammography was done to look for breast lesions which showed a spiculated mass in the upper outer quadrant (UOQ) of the right breast, near the axilla (Figure 4).

Ultrasound-guided core needle biopsy was done on the breast mass and axillary lymph node, and the pathology showed invasive ductal carcinoma NOS type, tumor grade (histologic and nuclear) II with lymphovascular invasion. The IHC showed an ER



**Figure 4.** Spiculated mass in upper outer quadrant near axilla in the right breast



**Figure 5.** Bone scan of patient showing multiple metastatic involvements, in the left femur head, right femur neck, L4 spine, bilateral ischia, distal left femur and left temporal bone



and PR positive and Her2 negative tumor. The lymph node also showed tumoral involvement. Metastatic workup including whole body bone scan and abdomino-pelvic CT scan was done. The bone scan reported multiple metastatic involvements highly suggested in the left femur head, right femur neck, L4 spine, bilateral ischia, left distal femur, and right temporal bone (Figure 5). Abdomino-pelvic CT was normal. Decision making was done in a multidisciplinary team and neoadjuvant chemotherapy was initiated for her.

She received 8 sessions of AC-T chemotherapy in 5 months, in addition to 10 sessions of local temporal bone radiation therapy. Afterwards, the breast mass regressed, lung and bone metastases partially disappeared, and she looked generally better. The involvement of the cranial nerves, including ptosis and Bell's palsy, has resolved by 80%, but hoarseness and difficulty swallowing still exist after nine months. Now, she is receiving tamoxifen, zoledronic acid, and capecitabine without any signs of tumor progression.

### Discussion

The incidence of breast cancer increases with age, with a vast majority of women diagnosed after the age of 40 years. Breast cancer is rare and typically aggressive in young women.<sup>1</sup>

Breast cancer is the most prevalent and the 5<sup>th</sup> leading cause of death among Iranian women; near 25 percent of breast cancer patients eventually die despite significant advances in diagnosis and treatment.<sup>4</sup> Akbari *et al.* evaluated 461 Iranian patients of breast cancer during 1994-2007 and showed that 18.4% of them were in stage I, 36.1% stage II, 27.7% stage III, and 17.7% stage IV, indicating that 54.5% of the patients were in early stages of cancer and about half of them (45.5%) were diagnosed in an advanced stage.<sup>5</sup>

In developing countries with no facilities for regular breast cancer screening, breast self-exam (BSE) and clinical breast examination (CBE) can still be used to down stage breast cancer. There are two surveys on knowledge and attitude in breast cancer in Iran. According to a study by Nafissi *et al.* in 2012, 59.9% of the participants were able to perform BSE but only 12.9% of the respondents practiced BSE regularly and 36.5% never did BSE. The main reasons for ignoring BSE were forgetfulness (41.6%) and lack of knowledge on the correct approach to BSE (33.4%). Also, 15.8% of the subjects feared to find a mass in their breasts, so they did not perform BSE.<sup>6</sup> It seems that the most common cause of delayed diagnosis of breast cancer in developing countries is that regular breast screening programs are not regularly and routinely implemented that do not offer is lack of BSE and CBE.

Metastatic disease is found in 5% of the women at the time of breast cancer diagnosis. About 30% of the

women with early stage breast cancer will ultimately; develop distant metastases.<sup>7</sup>

The most common sites of metastases, beyond regional lymph nodes, are the bones, lung, liver, and brain.<sup>3</sup>

The temporal bone may be invaded by tumors originating from adjacent areas or as metastases from distant sites. About 25% of temporal metastases originate from breast cancer.<sup>2</sup>

Ming-Ying Lan *et al.* reported 4 routes for metastasis to the temporal bone: the first one is hematogenous dissemination of the tumors cells to the bone marrow. The second one is direct extension of the regional tumor, such as nasopharynx, hypopharynx, and parotid gland tumors. The third one is meningeal carcinomatosis (otitis interna carcinomatosa). The fourth is leptomeningeal extension from an intracranial primary tumor, like leukemic or lymphomatous infiltration.<sup>8</sup> The most common area of the temporal bone metastatic infiltration is the petrous apex of the mastoid.<sup>9,10</sup>

Temporal bone invasion may be silent or present itself with otologic symptoms like otalgia, otorrhea, tinnitus, hearing loss, vertigo, and aural mass. These conditions are most frequently the symptoms of mastoid infection; so, if there are prolonged inflammatory symptoms with no response to antibiotics and anti-inflammatory drugs, further evaluation is needed.<sup>8</sup>

Fascial nerve palsies are rare complications of metastatic cancer in the advanced stage of mastoid bone invasion.<sup>9-11</sup>

In this case, the presentation began with otalgia; then, cranial nerve palsy presented one by one as the involvement of 7<sup>th</sup> cranial nerve followed by the 8<sup>th</sup> and 9<sup>th</sup> nerves.

Imaging of the temporal bone by CT scan or MRI is important for differentiation of tumor invasion from infection. By tumor erosion, osteolytic and destructive bone lesions are seen. Moreover, sclerosis and bone formation are other presentations on imaging studies. Similar to our patient, progressive bony erosion seems to be more characteristic of a malignant disease.<sup>8</sup> Positron emission tomography (PET scan) should also be considered as another imaging modality for detection of all metastases like temporal bone lesions.

The treatment of metastatic temporal bone lesions is systemic chemotherapy with local radiotherapy to the affected temporal region.<sup>2,8,11</sup> A multidisciplinary team decided to do neoadjuvant chemotherapy and local radiotherapy followed by hormone therapy in this patient.

In conclusion, temporal bone metastasis is rare and may be asymptomatic, or with mild symptoms mimicking mastoid infections. Facial nerve palsy is rare as the first presentation. Otolaryngologists should consider metastatic cancer versus infection on the list of differential diagnoses in patients



presenting with prolonged otologic symptoms or facial nerve disorders. Complete physical examination, audiometry, and imaging are important for diagnosis.

#### References

1. Tsakiropoulou E, Fyrmipas G, Konstantinidis I, Efstratiou I, Constantinidis I. Temporal bone metastasis from breast carcinoma. *Otorhinolaryngol Head Neck Surg* 2013; (52): 30-2.
2. Streitmann M, Sismanis A. Metastatic carcinoma of the temporal bone. *Am J Otol* 1996; 17(5): 780-3.
3. Wanamaker J, Kraus D, Eliachar I, Lavertu P. Manifestations of metastatic breast carcinoma to the head and neck. *Head Neck* 1993; 15(3): 257-62.
4. Akbari M, Akbari M, Zirakzadeh H, Nafisi N, Heidari A, HosseinizadeganShirazi F. Margin status influence on the outcome of patients treated with breast conserving surgery. *Iran J Cancer Prev* 2011; 4(4): 177-82.
5. Akbari M, Khayamzadeh M, Khoshnevis S, Nafisi N, Akbari A. Five and ten years survival in breast cancer patients mastectomies vs. breast conserving surgeries personal experience. *Iran J Cancer Prev* 2008; 1(2): 53-6.
6. Nafissi N, Saghafinia M, Motamedi M, Akbari M. A survey of breast cancer knowledge and attitude in Iranian women. *J Cancer Res Ther* 2012; 8(1): 46-9.
7. O'Shaughnessy J. Extending survival with chemotherapy in metastatic breast cancer. *Oncologist* 2005; 10 Suppl 3: 20-9.
8. Lan M, Shiao A, Li W. Facial paralysis caused by metastasis of breast carcinoma to the temporal bone. *J Chin Med Assoc* 2004; 67(11): 587-90.
9. Carty N, Foggitt A, Hamilton C, Royle G, Taylor I. Patterns of clinical metastasis in breast cancer: an analysis of 100 patients. *Eur J Surg Onc* 1995; 21(6): 607-8.
10. Fukumoto M, Osaki Y, Yoshida D, Ogawa Y, Fujiwara M, Miyazaki N, *et al.* Dual-isotope SPECT diagnosis of a skull-base metastasis causing isolated unilateral hypoglossal nerve palsy. *Ann Nuc Med* 1998; 12(4): 213-6.
11. Jones H. Case of metastasis in the temporal bone from a carcinoma of the breast. *J Laryngol Otol* 1969; 83(3): 293-8.

Archive of SID