



The First Report of *Cysticercus fasciolaris* From Alborz Province, Iran

Abolfazl Miahipour¹, Hajar Aghei¹, Mohammad Zibaei^{1,2*}

¹Department of Parasitology and Mycology, School of Medicine, Alborz University of Medical Sciences, Karaj, Iran

²Evidence-based Phytotherapy and Complementary Medicine Research Center, Alborz University of Medical Sciences, Karaj, Iran

*Corresponding Author: Mohammad Zibaei, Email: zibaeim@sums.ac.ir.

Received August 1, 2020; Revised August 12, 2020; Accepted August 20, 2020

Published Online August 30, 2020

T*enia taeniaeformis* is a cestode parasite found in the intestine of cats and other final hosts. Rodents, various species of rats, and voles act as intermediate hosts for the parasite. The intermediate hosts infected through ingestion of contaminated feed, water, and beddings from eggs of the parasite pass by cats. Eggs develop into larval form in the liver of intermediate host. The larva inhabits the liver of the rodent, an intermediate host. The larval form of *T. taeniaeformis* is called *Cysticercus fasciolaris*.¹ A small number of fibrosarcoma cases in the liver of rats associated with cysts of *T. taeniaeformis* have been reported.² *T. taeniaeformis* is a parasite with zoonotic significance because humans can act as accidental hosts.³ Adult parasites and metacestodes (*C. fasciolaris*) have been detected in intestines and liver of people from Taiwan, Sri Lanka, Argentina, and Czech Republic.^{4,5} As far as the researchers of this study investigated, there are few reports of *T. taeniaeformis* in the rodents from Iran,⁶ and there is no *C. fasciolaris* reports in our region. The purpose of the present report was to present a case from naturally infected rat in the Alborz province, Iran (Figure 1 and Figure 2).

Conflict of Interest Disclosures

The authors declare that they have no conflict of interests.

Ethical Approval

The study was approved by the ethics committees of the Alborz University of Medical Sciences, Iran.

Acknowledgments

We thank the technical assistance of Mrs. L. Moshki of the Parasitology Laboratory, School of Medicine, Alborz University of Medical Sciences, Iran.

References

- Jithendran KP, Somvanshi R. Experimental infection of mice with *Taenia taeniaeformis* eggs from cats - Course of infection and pathological studies. *Indian J Exp Biol*. 1998;36(5):523-525.
- Hanes MA, Stribling LJ. Fibrosarcomas in two rats arising from hepatic cysts of *Cysticercus fasciolaris*. *Vet Pathol*.

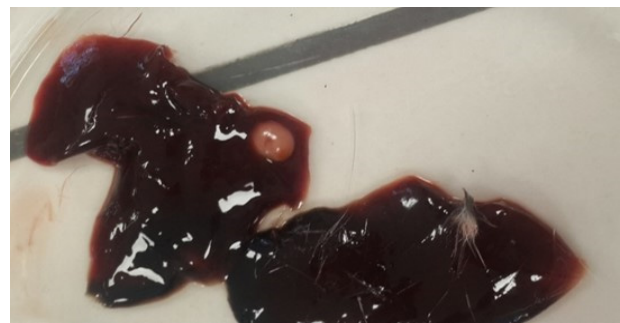


Figure 1. *Cysticercus Fasciolaris* Cyst in a *Muse Musculus* Liver.

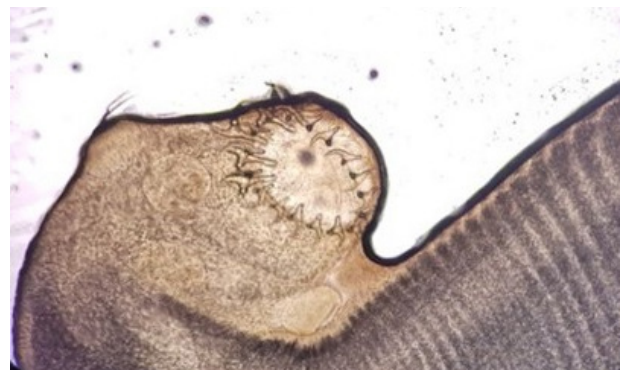

Figure 2. Scolex of *Taenia Taeniaeformis* with Rows of Hooks.

- 1995;32(4):441-444. doi: 10.1177/030098589503200418.
- Zibaei M, Sadjjadi SM, Sarkari B. Prevalence of *Toxocara cati* and other intestinal helminths in stray cats in Shiraz, Iran. *Trop Biomed*. 2007;24(2):39-43.
- Ekanayake S, Warnasuriya ND, Samarakoon PS, Abewickrama H, Kurupparachchi ND, Dissanaikie AS. An unusual 'infection' of a child in Sri Lanka, with *Taenia taeniaeformis* of the cat. *Ann Trop Med Parasitol*. 1999;93(8):869-873. doi: 10.1080/00034989957871.
- Oryan A, Alidadi S. Public health concerns of Taenidae and their metacestodes. *Trop Med Surg*. 2015;3(1):e123. Doi:10.4172/2329-9088.1000e123.
- Moradpour N, Borji H, Darvish J, Moshaverinia A, Mahmoudi A. Rodents helminth parasites in different region of Iran. *Iran J Parasitol*. 2018;13(2):275-284.