

Case Report: Acute Myocardial Injury and Electrocardiogram Changes in a Case of Aluminum Phosphide Poisoning



Bitá Dadpour¹, Nasrin Milani¹, Omid Mehrpour², Fares Najari^{3*}

1. Department of Toxicology, Faculty of Medicine, Mashhad University of Medical Sciences, Mashhad, Iran.

2. Department of Internal Medicine, Faculty of Medicine, Birjand University of Medical Sciences, Birjand, Iran.

3. Department of Forensic Medicine, Faculty of Medicine, Shahid Beheshti University of Medical Sciences, Tehran, Iran.



Citation: Dadpour B, Milani N, Mehrpour O, Najari F. Acute Myocardial Injury and Electrocardiogram Changes in a Case of Aluminum Phosphide Poisoning. International Journal of Medical Toxicology and Forensic Medicine. 2019; 9(2):91-96.



Article info:

Received: 25 Oct 2018

First Revision: 15 Dec 2018

Accepted: 29 Feb 2019

Published: 01 Apr 2019

Keywords:

Aluminum phosphide,
Poisoning, ECG changes,
Acute myocardial injury

ABSTRACT

Aluminum Phosphate (AIP) poisoning is one of the major causes of mortality among toxic substances. The related symptoms and signs are nonspecific and dose-dependent., contact method, the interval between exposures to poison. A 20-year-old woman was admitted to the emergency department due to the consumption of one AIP tablet. ECG was normal at 2 hours post-ingestion and echocardiography revealed LVEF of 55-60% at 4 hours post admission. ECG abnormalities in this patient included VT and VF on the second night. She experienced an unusual rhythm disturbance in term of LBBB and Brugada pattern besides low ejection fraction of left ventricue (about 20-25%) on the third day. The main emphasis for AIP poisoning cases is on a timely, precise and prompt symptomatic treatment.

1. Introduction

Aluminum phosphide (AIP) is a highly toxic inorganic compound used as a pesticide. When exposed to atmospheric moisture or hydrochloric acid in the stomach, it releases mortal phosphine gas. The poisoning mechanism includes the inhibition of cytochrome C oxidase and the formation of highly reactive free hydroxyl radicals.

The signs and symptoms are nonspecific and instantaneous [1, 2] and depend on the dosing instructions. AIP

poisoning particularly affects the cardiac and vascular tissues. It manifests as profound and refractory hypotension, without the direct involvement of the central nervous system. Electrocardiographic abnormalities include myocarditis, subendocardial infarction or pericarditis [3, 4].

2. Case Report

A 20-year-old woman was admitted to the emergency room due to consuming one AIP tablet at 1.5 hours before admission. She was completely alert and vital signs included systolic/diastolic blood pressure=110.70 mmHg,

* Corresponding Author:

Fares Najari, MD.

Address: Department of Forensic Medicine, Faculty of Medicine, Shahid Beheshti University of Medical Sciences, Tehran, Iran.

Tel: +98 (912) 3195140

E-mail: fares.hospital@yahoo.com

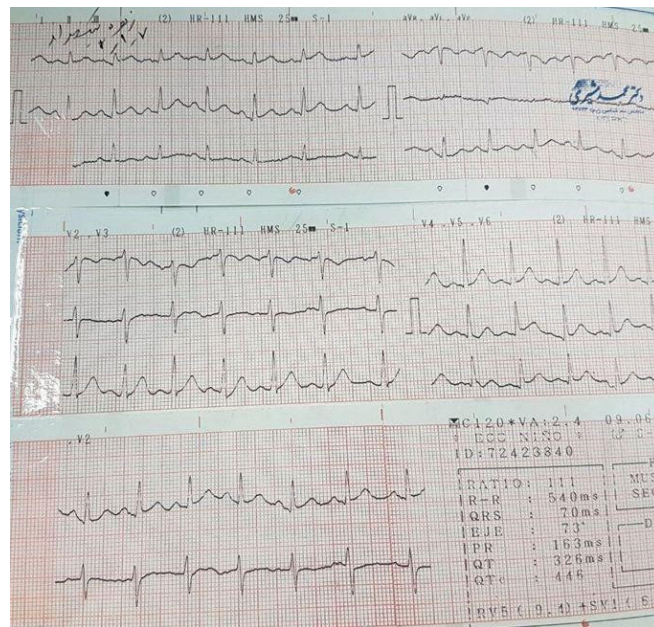


Figure 1. Electrocardiographic changes following aluminium phosphide poisoning.

PR=70/minute, RR=17/minute T=37°C at admission. Gastric lavage was performed and activated charcoal was early prescribed in the ED. She was transferred to ICU 45 minutes later. Gasometry once admission to ICU revealed PH=7.41, Pco₂=26.6, and Hco₃=17.6. Serum therapy was employed in addition to sodium bicarbonate. NAC was prescribed based on a dose of 9 grams in 200 mL of DW5% for the first hour, 3 gram in 500 mL of DW5% in the next 4 hours, and 6 gram in 1000 mL of DW5% for the following 16 hours. Dexamethasone 8 mg Stat and 4 grams were injected every 8 hours.

Magnesium sulfate was prescribed as 2 grams every 6 hours. Amp Vitamin E and Vitamin C were other daily prescribed drugs. ECG was normal at 2 hours post-ingestion and echocardiography revealed LVEF 55-60% at 4 hours post admission. She experienced VT and VF on the second night and received 200 j and 250 j ECT for two times, respectively until the rate and rhythm turned back to normal (Figure 1). Amiodarone infusion was initiated at dose 150 mg intravenous, then 1 mg per minute over 6 hours, followed by 0.5 mg per minute over the next 18 hours. LVEF was 20%-25% and ECG demonstrated LBBB on the next day (Figure 2).

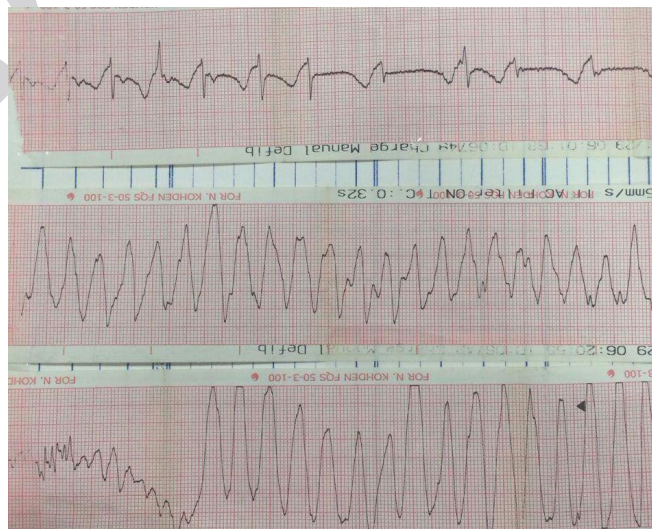


Figure 2. ECG recorded 1 day after showing VT

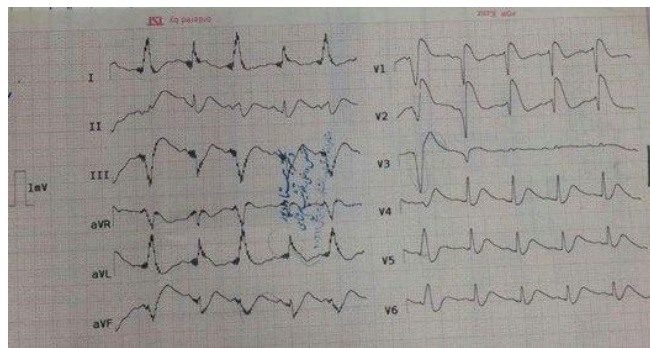


Figure 3. ECG recorded 2. Days later showing LBBB

International Journal of
Medical Toxicology & Forensic Medicine

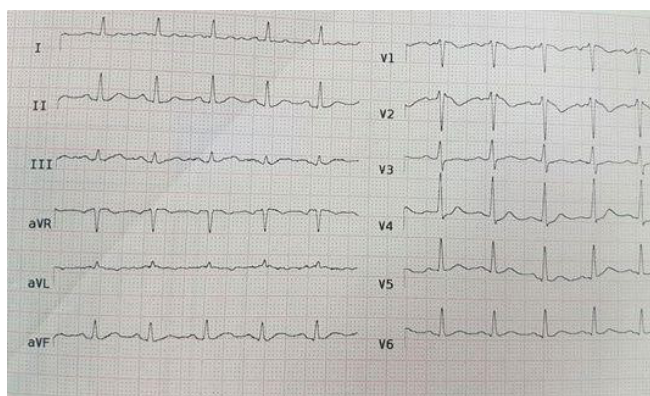


Figure 4. ECG recorded 2 days after showing Brugada

International Journal of
Medical Toxicology & Forensic Medicine

It was in accordance with Brugada pattern on day 3 (Figure 3). Troponin-I amount was 4.67 on the next day. Troponin-I was in the normal range of admission. Metabolic acidosis resolved and gasometry was normal on

day three post admission; however, in a couple of hours, she was intubated due to respiratory distress and fever and drop in oxygen saturation. She was febrile and CXR revealed infiltration in the lower zone of the left lung

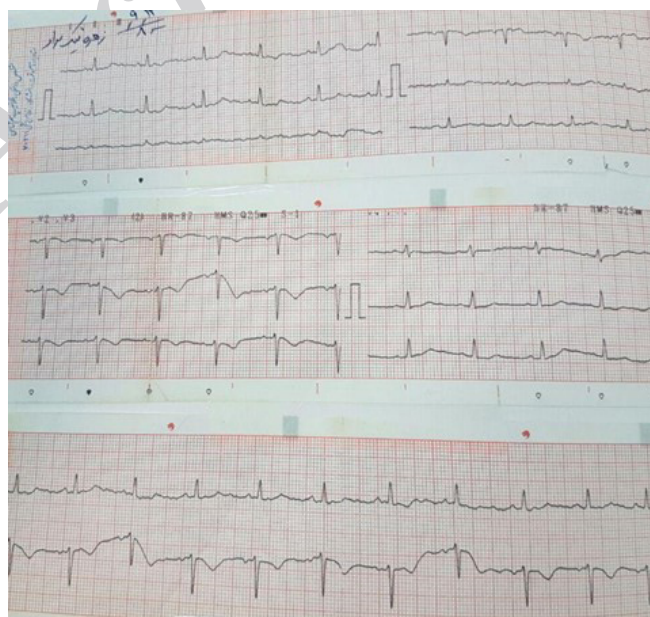


Figure 5. ECG recorded 6 days later

International Journal of
Medical Toxicology & Forensic Medicine

at that time. Antibiotic therapy was initiated by meropenem, vancomycin, and ciprofloxacin.

On day 4, echocardiography was repeated and LVEF was still 20-25%, whereas ECG changes improved partly. She was extubated on day 5 when being entirely alert and there was no respiratory distress. ECG was normal on day 5 and echocardiography revealed LVEF 55% on day 6. She was transferred to the poisoning ward on day 8 and was self-discharged from the ward in the following day (Figure 4 and 5).

3. Discussion

A study by Siwach et al. on the incidence of various arrhythmias in patients of AIP poisoning suggested ventricular tachycardia in 40%, and atrial flutter/fibrillation in 20%, ventricular fibrillation in 23.3%, and supraventricular tachycardia in 46.7% of the cases [5]. Only a few cases of AIP poisoning were followed-up in respect of cardiac function by echocardiography. The relevant data revealed the dysfunction of the left ventricle that was reversible over a few days; the frequency of hypotension varies from 76-100% [6].

The range of cardiac arrhythmias has been reported in the patients of AIP poisoning. Supraventricular tachycardia and atrial flutter/fibrillation occurred in 46.7% and 20% of the patients, respectively [7]. S-T depression and S-T elevation occurred in 10% and 90% of the cases, respectively; toxic myocarditis caused by phosphine is probably in charge of the development of these arrhythmias [8]. AIP poisoning is relatively prevalent in Iran [9].

The main toxicity is related to phosphine gas; i.e. released when AIP tablet is exposed to water or ambient air. There is no specific antidote for this poisoning and unfortunately, its mortality rate is high. Myocardial injury and ECG changes are frequently reported in this poisoning. Cardiac changes may be reversible or not. The early and prompt conservative treatment of metabolic acidosis and hypotension in addition to the recommended but not antidotal treatments may save the lives of the patients. In our case, the results of ECG patterns were normal on day 1, LBBB on day 2, VT on 36 hours post-ingestion, Brugada-like pattern on day 3, and the gradual normalization of ECG changes on days 4 and 5. LVEF was 55-60% on day 1, 20-25%.

3. Conclusion

Although cardiac manifestations and major dysrhythmias are considered as poor prognosis indices in AIP poisoning, prompt and precise therapeutic measures can be life-saving.

Ethical Considerations

Compliance with ethical guidelines

All information was confidential and the informed consent was signed by from the relatives of the patient.

Funding

This research did not receive any specific grant from funding agencies in the public, commercial, or not-for-profit sectors.

Authors' contributions

All authors contributed in designing, running, and writing all parts of the research.

Conflict of interest

The authors declared no conflict of interest.

Acknowledgements

The authors appreciate the insightful cooperation of staff of the emergency department.

References

- [1] Nik NM, Hawari R, Shafie H. A case report of aluminium phosphide poisoning. *The Medical Journal of Malaysia*. 2016; 71(4):213-4. [PMID]
- [2] Lehoux J, Hena Z, McCabe M, Peek G. Aluminium phosphide poisoning resulting in cardiac arrest, successful treatment with Extracorporeal Cardiopulmonary Resuscitation (ECPR): A case report. *Perfusion*. 2018; 33(7):597-8. [DOI:10.1177/0267659118777196] [PMID]
- [3] Mehrpour O, Jafarzadeh M, Abdollahi M. A systematic review of aluminium phosphide poisoning. *Archives of Industrial Hygiene and Toxicology*. 2012; 63(1):61-73. [DOI:10.2478/10004-1254-63-2012-2182] [PMID]
- [4] Meel BL. Aluminium phosphide (tank pill) poisoning in the Transkei region of South Africa: A case report. *Medicine, Science and the Law*. 2011; 51(2):116-8. [DOI:10.1258/msl.2010.010205] [PMID]

- [5] Dadpour B, Mokhtarpour M, Abdollahi M, Afshari R. An outbreak of aluminium phosphide poisoning in Mashhad, Iran. *Arhiv za Higijenu Rada i Toksikologiju*. 2016; 67(1):65-6. [DOI:10.1515/aiht-2016-67-2769] [PMID]
- [6] Singh RB, Rastogi SS, Singh DS. Cardiovascular manifestations of aluminium phosphide intoxication. *The Journal of the Association of Physicians of India*. 1989; 37(9):590-2. [PMID]
- [7] Akkaoui M, Achour S, Abidi K, Himdi B, Madani A, Zeggwagh AA, et al. Reversible myocardial injury associated with aluminum phosphide poisoning. *Clinical Toxicology*. 2007; 45(6):728-31. [DOI:10.1080/15563650701517350] [PMID]
- [8] Hirani SA, Rahman A. Aluminium phosphide poisoning: A case report. *Journal of Ayub Medical College Abbottabad*. 2010; 22(4):221-2. [PMID]
- [9] Mouhaoui M, Khaleq K, Rabbai O, Yaqini K, Louardi H. [Aluminium phosphide poisoning and pregnancy (case report) (French)]. *Annales Françaises d'Anesthésie et de Réanimation*. 2008; 27(2):181-2. [DOI:10.1016/j.annfar.2007.11.021] [PMID]

Archive of SID

This Page Intentionally Left Blank

Archive of SID