



# Prevalence of Ventricular Septal Defect and Associated Diseases Among Patients Under 18 Years in Shiraz During 2016-2017

Hamid Mohammadi<sup>1</sup>, Nima Mehdizadegan<sup>1</sup>, Mohammad Reza Edraki<sup>2</sup>, Saeed Karimi<sup>3</sup>, Negar Yazdani<sup>4</sup>, Reza Bahrami<sup>5</sup>, Mohammad Bahrami<sup>6</sup>

<sup>1</sup>Assistant Professor, Cardiovascular Research Center, School of Medicine, Shiraz University of Medical Sciences, Shiraz, Iran

<sup>2</sup>Associated Professor, Cardiovascular Research Center, School of Medicine, Shiraz University of Medical Sciences, Shiraz, Iran

<sup>3</sup>School of Medicine, Shiraz University of Medical Sciences, Shiraz, Iran

<sup>4</sup>PhD in Nursing, Neonatal Research Center, Shiraz University of Medical Sciences, Shiraz, Iran

<sup>5</sup>Assistant Professor, Neonatal Research Center, Shiraz University of Medical Sciences, Shiraz, Iran

<sup>6</sup>Student of Medicine (MD), School of Medicine, Shiraz University of Medical Sciences, Shiraz, Iran

## Abstract

**Background and aims:** Since ventricular septal defect (VSD) is the most common congenital heart disease, this study aimed to investigate its prevalence, characteristics, and associated diseases in a referral children's heart clinic in south of Iran.

**Methods:** In this cross-sectional study that was conducted based on the databases of children with heart diseases, patients under 18 years of age referring to Imam Reza clinic were examined. All patients with at least one record of VSD in echocardiography during 2016-2017 were included. Demographic and echocardiographic characteristics including size of VSD, shunt gradient, pulmonary hypertension (PH), aortic regurgitation, and associated cyanotic and acyanotic defects were analyzed.

**Results:** The prevalence of VSD found in 7458 echocardiography records was 12%, the median age of patients was 9.3, and the male/female ratio was 1.08. The perimembranous VSDs were determined to be the most common types of VSD. The most common associated complication with VSD was detected to be PH followed by aortic regurgitation. Sub-pulmonic showed the highest association with aortic failure. Atrial septal defect and tetralogy of Fallot (TOF) were the most common acyanotic and cyanotic heart defects, respectively. Only 0.5% of the patients had Eisenmenger syndrome.

**Conclusion:** Fortunately, the prevalence of the complication of VSD was not high in south of Iran, and the number of Eisenmenger syndrome was low. The types of VSD and the number of its complications identified in study population were similar to those in other populations.

**Keywords:** Aortic regurgitation, Atrial septal defect, Fars, Iran, Tetralogy of Fallot, Ventricular septal defect

## \*Corresponding Author:

Reza Bahrami,

Tel: 00987136122218,

Email: bahramir@sums.ac.ir

Received: 9 Nov. 2020

Accepted: 19 May 2021

ePublished: 29 June 2021



## Introduction

With a prevalence of 4 per 1000 live births, ventricular septal defect (VSD) is one of the most common congenital heart defects,<sup>1</sup> which is more common in infants than in children.<sup>2</sup> The disorder may occur on its own or together with other congenital heart diseases (CHD) such as atrioventricular septal defect (AVSD), tetralogy of Fallot (TOF), and sometimes D-transposition of the great arteries (d-TGA).<sup>3</sup>

The ventricular septum is a three-dimensional structure consisting of four components: the septum of the atrioventricular (AV) canal, the muscular septum or ventricular sinus septum, the septal band or proximal conical septum, and the parietal band or distal conical septum. VSD results from the lack of growth of these

components, and varies in size from small to large defect.<sup>4</sup> The clinical symptoms vary depending on the size of the defect. Infants with small VSD are usually asymptomatic, whereas infants with moderate to severe VSD usually show symptoms of heart failure by 3-4 weeks of age.<sup>5</sup> Symptoms in moderate to severe VSD include tachypnea, poor nutrition and weight gain, tachycardia, enlarged liver, abnormal breath sounds (moaning and retraction in severe heart failure), and paleness.<sup>6</sup> Echocardiographic findings can also vary from an isolated systolic murmur in small defects to signs of left ventricular outflow failure, depending on the size of the wall defect. The severity of symptoms is directly correlated with the amount of left-to-right shunt. During the shunt, systolic blood pressure from left ventricle to right ventricle leads to left ventricular

*Archive of SID*

volume overload and pulmonary hypertension (PH) due to shunt continuity from left to right.<sup>7</sup> In addition to the clinical symptoms, there are various diagnostic methods in this regard, including electrocardiography, chest radiography, two-dimensional echocardiography, color Doppler, and angiography.<sup>8</sup> Since this disorder can cause dangerous complications such as pulmonary arterial hypertension, aortic valve regurgitation, right ventricular outflow tract obstruction, left ventricular outflow tract obstruction, and infective endocarditis, it is essential to early diagnose and appropriate treatment.<sup>9</sup>

Among the various types of VSD, the small to medium types are usually closed and cured spontaneously and naturally. But in the case of the large type and after having a surgery in the first year of life, the increasing of pulmonary vascular resistance is stopped and after a while, it returns to the normal condition. In rare case where large VSD is not treated until late childhood, prolonged left-to-right shunt can increase pulmonary artery blood flow, resulting in remodeling of the pulmonary vascular bed and in histological intimal and medial hypertrophy of the pulmonary arteries. When pulmonary vascular resistance exceeds systemic vascular resistance, the final shift of current with the right-to-left shunt causes hypoxemia and Eisenmenger syndrome, which is a serious problem and life-threatening condition leading to death.<sup>8</sup>

Despite the importance of VSD and its impact on the Infant Mortality Rate (IMR) as an important indicator of community health and development, there is only the lack of information regarding the statistics and characteristics of VSD and its associated defects in Iran.

Therefore, this study aimed to investigate the prevalence and characteristics of VSD, as well as the associated defects among patients referred to the Children's Heart Clinic of Imam Reza Clinic in Shiraz in 2016-2017.

## Materials and Methods

### Study Design

This cross-sectional study was performed using a review of echocardiographic records of children referred to the Children's Heart Clinic of Imam Reza Clinic in Shiraz during one year from October 2016 to October 2017. Samples were selected by convenient and available sampling method using census. All children referring to the clinic and having a confirmed VSD in at least one echocardiography record during the given year were included. Being under the age of 18 and registering the VSD as congenital defect were the inclusion criteria in the present study, while patients with congenital heart defects were excluded.

### Data Collection

Since the diagnosis of CHD in children depends on echocardiography test and because the Children's Heart Clinic of Imam Reza Clinic is the largest referral/examination center in the south of the country and the only public center for treating patients with heart problems,

a large number of children suffering from heart diseases refer to this clinic. A researcher-made checklist was used to collect patients' information including demographic variables and echocardiographic information. The studied demographic variables were gender, age at initial diagnosis, as well as age at final diagnosis of the disease.

Furthermore, echocardiographic variables (e.g., severity and gradient of tricuspid regurgitation (TR), pulmonary regurgitation (PR), and mitral regurgitation (MR)), VSD characteristics (e.g., size, size grading, shunt gradient, associated defects including aortic regurgitation, cyanotic lesion, single ventricle, acyanotic defects, as well as the presence and severity of PH), and the performed surgeries were also investigated and recorded in the follow-up checklist.

Echocardiography was performed on all patients using HS70 (Samsung) with both two-dimensional probes of 3-5 and 4-8 MHz, and a Doppler; when necessary, the tissue echocardiography was also conducted from different views.

The size and VSD associated defect were determined, and the PH was diagnosed based on the gradient of TR or PR gradient or VSD shunt gradient. With respect to the set of defects and the diagnosis of the disease. PR was divided into four categories: normal (mean of under 25 mm Hg); mild (mean systemic blood pressure of above 25% and below 30%); moderate (systemic blood pressure of 30-60%); and severe (systemic blood pressure of above 60%).

As for the Eisenmenger syndrome patients, additional data such as angiography or other available data were used to confirm the diagnosis.

The divisions of VSD were as follows: less than 30% of aortic diameter was designated as *small*, 30-50% of aortic diameter as *medium*, and above 50% of aortic diameter as *large*.

### Data Analysis

Data analysis was conducted using SPSS version 18. The results of the study were reported using descriptive statistics (i.e., frequency, percentage, mean, and standard deviation). ANOVA was also used for comparing three groups of small, medium and large VSD, as well as the factors leading to PH in isolated VSD patients.

Due to the existence of both quantitative (numerical measures) and qualitative (mild, moderate, and severe severity) variables, Pearson's correlation coefficient was adopted to investigate the relationship between different defects.

## Results

A total of 9104 patients underwent echocardiography in 2016-2017 in the studied clinic, 7458 of whom were included in the present study. Some patients underwent echocardiography more than once. Percentages were calculated based on the number of the patients (n=7458).

All patients undergoing echocardiography had 906 (12%) VSDs. The mean age of patients with VSD was 31.8

Archive of SID

(median: 9.3) months. As for the gender of the patients, 52% (n: 471) were boys, and 48% (n: 435) were girls.

The most common type of VSD was found to be perimembranous type [n: 507 (55.96%)]. Other types of VSDs were muscular or apical [n: 180 (19.86%)], sub-aortic, [n: 143 (15.78%)], inlet [n: 63 (6.95%)], and sub-pulmonic [n: 13 (1.43)] (Figure 1). The sub-pulmonary type having 38% association with aortic valve regurgitation showed the highest probability of AR (Figure 2).

One of the complications accompanying VSD is pulmonary artery hypertension that was seen in 254 (28%) of our patients, with 129 (36%) cases being severe, 115 (33%) mild, 95 (27%) moderate, and 15 (4%) supra-systemic.

Despite high prevalence of pulmonary artery hypertension, the Eisenmenger syndrome (irreversible cases of PH) was found in only 6 (0.5%) patients. Another complication of VSD is AR, which was seen in 84 (9%) of our patients of whom 26 (30.95%) were trivial, 46 (54.76%) were mild, and 12 (14.28%) were moderate.

Another acyanotic heart defect was observed in 31% of patients with VSD, having the most common association with ASD, followed by patent ductus arteriosus (PDA), AVSD, and coarctation of the aorta (COA) (Figure 3).

Moreover, 17 cases of VSD were reported in patients with dextrocardia, which showed association with a prevalence of 1.8%. Cyanotic heart defect cases were found in 17% of VSD patients, the most common case being tetralogy Fallot [n: 67 (7.3%)]. Other cases were much less common, and a total of 89 (9.8%) patients had acyanotic heart defects other than TOF. Among cyanotic heart defect cases, 30 single ventricle cases were also found with different anatomies.

Complex cases such as Double Outlet Right Ventricle (DORV) were detected in 45 patients and L or D malposed great artery was observed in 34 patients, which were associated with a variety of anatomies. These two pathologies may have been associated with some other diseases. For example, the patient may have been suffering from tricuspid DORV plus L-malposed great arteries and interrupted aortic arch, or the patient may have been developing DORV plus L malposed great artery and Interrupted arch.

In cases of heterotaxia, the mentioned pathologies become extremely diverse and complicated and it does not seem worthwhile to list them all because they are uncommon, and there is also a large statistical overlap due to their combination with other pathologies.

**Discussion**


VSD is the most common CHD that is far too costly for the families and the government on a yearly basis, while its early diagnosis can significantly reduce the costs and prevent its life-threatening complications for the patient.

The most common type of VSD is perimembranous type; and in the present study, it was discovered that 55.97% of the patients had perimembranous. Our results were in

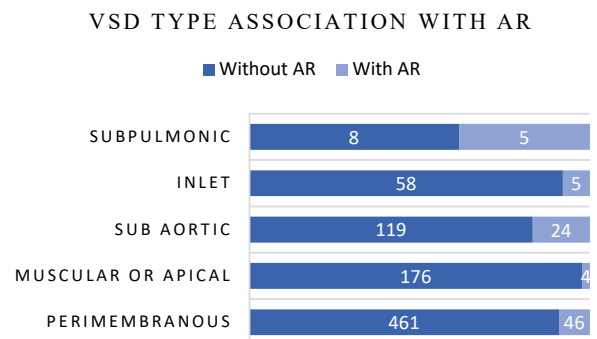
line with the findings from a study by Behjati-Ardakani et al in Iran where the highest prevalence (65.13%) was determined for perimembranous type.<sup>10</sup> Also, Shahid et al identified perimembranous type as the most common type of VSD (70%).<sup>11</sup>

Since our study results are consistent with the findings from other available researches and scientific evidence, it is recommended that more studies be conducted on patients with perimembranous VSDs to address the issues concerning this disease and develop methods for early diagnosing and treating it with the aim of avoiding its long-term complications and consequences.

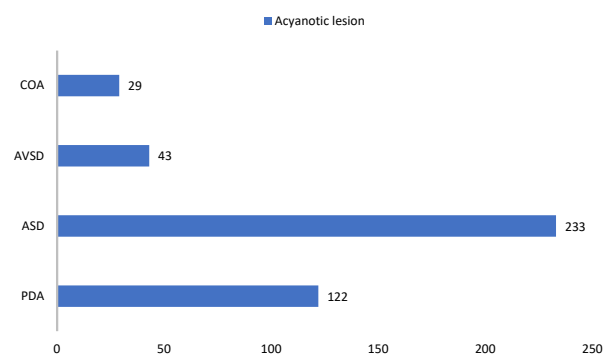
Our study results showed that 12% of patients with a



**Figure 1.** Types of Ventricular Septal Defect Based on Aortic Regurgitation.



**Figure 2.** Types of Ventricular Septal Defect Based on Aortic Regurgitation.



**Figure 3.** Percentage of Acyanotic Heart Defects in Patients With Ventricular Septal Defect.

*Archive of SID*

mean age of 31.8 months had VSD. The results from other studies in Iran, on the other hand, reported a prevalence of 27% and 28.4% in the center and southeast of the country, respectively.<sup>12,13</sup>

In a study carried out in China, the prevalence of VSD was reported to be 36.7% among patients with heart failure.<sup>14</sup> The reason for the low prevalence in our study could be explained by the fact that not all patients (n: 7,458) had heart failure and, moreover, some patients had normal echocardiography.

Another indicator studied in the present study was VSD-associated complications including PH and AR, which had a prevalence of 28% and 9% among the patients, respectively. In a similar study by Chauldhry et al, the prevalence of the given complications were determined to be 22.4% and 5.2%, respectively.<sup>15</sup> In another study carried out in the Heart Center of Lahore Hospital, the prevalence of PH and AR were found to be 48.2% and 9.85%, respectively.<sup>11</sup>

The PH differences observed in different studies conducted in different countries could be attributed to the various methods of follow-up towards the study populations. In addition, the difference in the time of patients' referral plays an important role in occurrence of PH. The incidence of AR in a high percentage of sub-pulmonary VSD patients indicates that these patients should be given a priority over other patients when treating this defect.

The presence of acyanotic heart defects in patients with VSD was another feature examined in the present study. Our study demonstrated that 24.61% of VSD patients had ASD, and 13.46% of them had PDA. In another study done in India, it was detected that 15.74% of VSD patients had ASD and 6.94% of them had PDA.<sup>16</sup>

The discrepancy found between the results from two studies could be attributed to the methods ASD and PDA were counted in the two studies. PDA is much more common in preterm patients, and ASD in small sizes may be considered the patent foramen ovale (PFO). The time of the first echocardiography is also important because both mentioned defects may be closed spontaneously.

Cyanotic heart defects had a similar prevalence rate as reported by other researchers, and according to the hypothesis of this study, TOF was the most prevalent defect. This finding was consistent with the results from a study by Kara et al.<sup>16,17</sup>

Given the consistency of the research findings, it is recommended that raising awareness about this disease as one of the most common cyanotic heart defects should be given a special attention by pediatricians and general practitioners.

Due to the prevalence of this disease among patients, it is important for medical students to receive a special and focused training in timely diagnosing it. Fortunately, Eisenmenger syndrome is not very common in cases of isolated defect; however, training pediatricians and GPs can prove highly effective in reducing these cases.

Although this study is the first one to present a database of CHDs in Fars province, it faced some problems and limitations regarding the presentation of the database. Firstly, some fields in the database had not been completely filled out, and an attempt was made to create the best situation for the presentation of data by examining other echocardiography fields as well as other electronic records of the patients. Secondly and as for some infants, there was a duplicate record due to the name changes and lack of national identification codes; in order for addressing this limitation, other characteristics of the infants such as father's name and birthdate were examined, and duplicate records were removed as much as possible.

Given the facts that the clinic under study is a referral ward for pediatric heart diseases and most patients are referred to this ward and visited by faculty members, highly accurate statistics on CHD can be compiled by setting up an integrated system. The results may also be used to improve education and macro-planning. To this end, close cooperation and complete filling out of echocardiography forms are reasonably required.

Therefore, it is necessary to refer all cases with history of CHD to a cardiac care registry office in order for obtaining important family information such as birth weight, birth head circumference, history of consanguineous marriage, history of other congenital anomalies, and the date of first diagnosis of the defect. This office can play a key role in completing the data and facilitating data collection and analysis such as survival data. In the present study, some information such as diagnosis time, data survival, and surgical outcomes was not utterly reliable due to the nonexistence of the registry office.

### Conclusion

Overall, it was concluded that the prevalence of VSD as the most common CHD was not high in Shiraz, and the number of incurable (Eisenmenger syndrome) cases was low. The types of VSD and its complications in study population were not significantly different from those in other populations. However, it is suggested that more cardiology centers be established to provide early diagnostic practices and standard initial treatment.

### Ethical Approval

The protocol of this study was approved by the Ethics Committee of Shiraz University of Medical Sciences (code: IR.SUMS.MED.REC.1398.246).

### Conflict of Interest Disclosures

The authors declare that there is *no conflict of interests*.

### Acknowledgement

We would like to thank the Vice Chancellor for Research and Technology of Shiraz University of Medical Sciences for the financial support, the staff of Children's Heart Clinic of Imam Reza (PBUH) Clinic for their close cooperation, and the participants for their voluntary participation in the study.

1. Huang SY, Chao AS, Kao CC, Lin CH, Hsieh CC. The outcome of prenatally diagnosed isolated fetal ventricular septal defect. *J Med Ultrasound*. 2017;25(2):71-5. doi: 10.1016/j.jmu.2017.05.005.
2. Soto B, Becker AE, Moulart AJ, Lie JT, Anderson RH. Classification of ventricular septal defects. *Br Heart J*. 1980;43(3):332-43. doi: 10.1136/hrt.43.3.332.
3. Gumbiner C, Takao A. Ventricular septal defect. In: Garson A, Bricker JT, Neish SR, eds. *The Science and Practice of Pediatric Cardiology*. Philadelphia: Williams & Wilkins; 1998. p. 1119-40.
4. Van Praagh R, Geva T, Kreutzer J. Ventricular septal defects: how shall we describe, name and classify them? *J Am Coll Cardiol*. 1989;14(5):1298-9. doi: 10.1016/0735-1097(89)90431-2.
5. Penny DJ, Vick GW 3rd. Ventricular septal defect. *Lancet*. 2011;377(9771):1103-12. doi: 10.1016/s0140-6736(10)61339-6.
6. Miller RH, Schiebler GL, Grumbar P, Krovetz LJ. Relation of hemodynamics to height and weight percentiles in children with ventricular septal defects. *Am Heart J*. 1969;78(4):523-9. doi: 10.1016/0002-8703(69)90487-6.
7. Fyler DC, Rudolph AM, Wittenborg MH, Nadas AS. Ventricular septal defect in infants and children; a correlation of clinical, physiologic, and autopsy data. *Circulation*. 1958;18(5):833-51. doi: 10.1161/01.cir.18.5.833.
8. Perloff JK, Marelli A. *Perloff's Clinical Recognition of Congenital Heart Disease*. 6th ed. Philadelphia: Saunders, 2012. p. 576.
9. Evans JR, Rowe RD, Keith JD. Spontaneous closure of ventricular septal defects. *Circulation*. 1960;22:1044-54. doi: 10.1161/01.cir.22.6.1044.
10. Behjati-Ardakani M, Soltani MH, Dehghani-Firoozabadi R. The clinical course of ventricular septal defect. *J Mazandaran Univ Med Sci*. 2011;21(85):159-164. [Persian].
11. Shahid NA, Hyder SN, Hasan A. Frequency of types of ventricular septal defect in Cardiology Department of the Children Hospital & ICH, Lahore. *Pak J Med Health Sci*. 2016;10(3):909-12.
12. Amel-Shahbaz S, Behjati-Ardakani M, Namayandeh SM, Vafaenasab M, Andishmand A, Moghimi S, et al. The epidemiological aspects of congenital heart disease in central and southern district of Iran. *Adv Biomed Res*. 2014;3:233. doi: 10.4103/2277-9175.145732.
13. Nazari P, Davoodi M, Faramarzi M, Bahadoram M, Dorestan N. Prevalence of congenital heart disease: a single center experience in southwestern of Iran. *Glob J Health Sci*. 2016;8(10):56421. doi: 10.5539/gjhs.v8n10p288.
14. Zhao QM, Liu F, Wu L, Ma XJ, Niu C, Huang GY. Prevalence of congenital heart disease at live birth in China. *J Pediatr*. 2019;204:53-8. doi: 10.1016/j.jpeds.2018.08.040.
15. Chaudhry TA, Younas M, Baig A. Ventricular septal defect and associated complications. *J Pak Med Assoc*. 2011 Oct;61(10):1001-4.
16. Pate N, Jawed S, Nigar N, Junaid F, Wadood AA, Abdullah F. Frequency and pattern of congenital heart defects in a tertiary care cardiac hospital of Karachi. *Pak J Med Sci*. 2016;32(1):79-84. doi: 10.12669/pjms.321.9029.
17. Mostefa-Kara M, Houyel L, Bonnet D. Anatomy of the ventricular septal defect in congenital heart defects: a random association? *Orphanet J Rare Dis*. 2018;13(1):118. doi: 10.1186/s13023-018-0861-z.