



Radiological Findings From 101 Patients With Novel Coronavirus Disease 2019 (COVID-19) in Hamadan, West of Iran: Typical and Atypical Features

Farideh Gharekhanloo¹, Seyyed Hamid Hashemi², Fariba Keramat^{2,3}, Farzaneh Esna-Ashari⁴, Mojgan Mamani^{2,3}, Mohammad Mahdi Majzoubi², Saeed Bashirian⁵, Mahsa Gharekhanloo⁶, Salman Khazaei⁷

¹Department of Radiology, School of Medicine, Besat Hospital, Hamadan University of Medical Sciences, Hamadan, Iran

²Department of Infectious Diseases, Faculty of Medicine, Hamadan University of Medical Sciences, Hamadan, Iran

³Brucellosis Research Center, Hamadan University of Medical Sciences, Hamadan, Iran

⁴Department of Community Medicine, Hamadan University of Medical Sciences, Hamadan, Iran

⁵Social Determinants of Health Research Center, Hamadan University of Medical Sciences, Hamadan, Iran

⁶Faculty of Art and Architecture, Yazd University, Yazd, Iran

⁷Research Center for Health Sciences, Hamadan University of Medical Sciences, Hamadan, Iran

Abstract

Background and aims: Coronavirus disease 2019 (COVID-19) has spread widely throughout the world and become a pandemic disease. In this study, we decided to investigate the chest computed tomography (CT) findings in COVID-19 patients in Hamadan, west of Iran.

Methods: This cross-sectional study was conducted on 101 patients with confirmed COVID-19 infection from February to March 2020. Demographic, clinical, laboratory, and chest CT findings of identified COVID-19 patients were assessed.

Results: The mean age of the patients was 55.21 ± 14.08 years, and 54 (53.47%) of them were male. With regard to clinical manifestations, 82.18%, 72.28% and 54.46% of COVID-19 patients had dry cough, dyspnea, and fever, respectively. The right lower lobe was the most commonly and severely involved lobe (69%), followed by left lower lobe, right middle lobe, and lingual segment; however, the anterior segment of upper lobes showed the least involvement with abnormality in the late course of the disease. The most common pattern was ground glass opacity (GGO), but atypical patterns such as round pneumonia, moderate to severe pleural effusion, and segmental lobar consolidation were seen without evidence of mediastinal adenopathy, cavitation, or nodular lesion. Chest X-ray (CXR) was not a sensitive method as the first-line imaging method because 34.65% of them were normal.

Conclusion: CXR is not a sensitive method as the first-line imaging method (34.65% normal first CXR), but chest CT is a very sensitive and nonspecific modality for diagnosis of COVID-19. The lower lobe and posterior basal segments of the lungs are the most involved sites in most cases. About 12% showed atypical chest CT findings.

Keywords: Chest CT, COVID -19, Coronavirus, Chest radiograph, Iran

*Corresponding Author:

Salman Khazaei,
PhD; Research Center for
Health Sciences, Hamadan
University of Medical Sciences,
Hamadan, Iran.
Tel: +98-813-383-0548,
Email: salman.khazaei61@
gmail.com

Received: 5 May 2021
Accepted: 22 June 2021
ePublished: 29 Sep. 2021



Introduction

Coronavirus disease 2019 (COVID-19) infection was first detected in December 2019 in Wuhan, the capital of Hubei province of China and spread to a growing number of countries.¹ Alongside severe acute respiratory syndrome (SARS) and Middle East respiratory syndrome (MERS), COVID-19 is another common type of coronavirus that infects humans.² COVID-19 is transmitted through direct contact from human to human, mainly through respiratory droplets, and also through contact by the same mechanism as other common cold or influenza viruses.³ The symptoms of COVID-19 infection appear after an incubation period; studies so far suggest a mean incubation period of 5 days (range: 0–24 days).⁴ The most

common clinical symptoms of COVID-19 are fever, dry cough, dyspnea, muscle soreness, and fatigue.^{5,6} Some of the patients were reported to have headache or hemoptysis and some patients were relatively asymptomatic.^{7,8} Approximately 80% of COVID-19 infections are mild or asymptomatic, 15% are severe infections requiring oxygen, and 5% are critical infections requiring ventilation. Additionally, the mortality rate is approximately 3%.⁹ Older patients are more likely to have respiratory failure due to severe alveolar damage.¹⁰ Old age, male gender, and presence of comorbidities are high risk factors for poor prognosis of the disease.¹

Real-time polymerase chain reaction (RT-PCR) technique has high false negative rate and needs at least

Archive of SID

48 hours for determination, while chest CT has high sensitivity and gives the results in a small fraction of the time.^{11,12} Therefore, chest CT plays an important role in the early detection of chest abnormality in suspected cases. These features of CT images help physicians in rapid management, planning, initiation of treatment, isolation of patients, and determination of the severity of the disease. Previous studies showed that imaging plays an important role in follow up of COVID-19 patients.¹³ There are few studies on imaging of COVID-19 patients and the majority of them belong to China; therefore, we conducted this study to observe the imaging characteristics of the COVID-19 patients in Iran.

Materials and Methods**Study Design And Population Under Study**

This cross-sectional study was performed in Hamadan province, the west of Iran. A total of 101 patients with confirmed COVID-19 infection identified in all hospitals in the province affiliated to Hamadan University of Medical Sciences were enrolled in the study from February to March 2020 through census method. Hamadan province with an area of 19493 km² is located in the west of Iran and have a population of 1,758,268 (according to the national census held in 2016 by Statistical Center of Iran: <http://irandataportal.syr.edu/census/census-2016>)

Eligibility Criteria

All patients with COVID-19 infection confirmed by RT-PCR testing on nasopharyngeal swabs and throat swabs hospitalized in Sina hospital and underwent chest CT were included in the study.

Patients with positive RT-PCR results were included in the study and assessed. It should be noted that these patients have not been included in any study.

Data Collection Procedure and Instrument Tool

A checklist including demographic, clinical, laboratory and chest CT findings of identified COVID-19 patients were used for collecting data. Demographic and clinical data, including signs, symptoms and underlying diseases history, were obtained directly from the patients and when the patient was unable to respond due to a bad physical condition, the information was obtained from the physician or patient's medical records. Biochemical blood test results were gathered by referring to the patient's medical record.

Chest images of each patient were reviewed independently. All hospitalized patients underwent chest computed tomography (CT) at the first day of admission using a 16-channel multi-detector CT scanner (Somatom Emotion; Siemens Healthcare, Erlangen, Germany). CT Scans were obtained in supine position with full inspiration and without injection of contrast media. Acquisition parameters were as following characteristics: 170–200 MAs; 110 – 120 kVp; collimation 0.625–5 mm and pitch, 1.2. Images were reconstructed with slice

thickness 0.625–5 mm and reconstruction interval 1–3 mm sharp reconstruction kernel. All images were viewed with lung (width, 1500 HU; level, - 600 HU) and mediastinal window (width, 400 HU; level, 40 HU).

Two expert radiologists (with 11 and 20 years of experience in chest imaging, respectively) analyzed and reviewed all the chest radiographs and CT images on a picture archiving and communication system (PACS Marco) by consensus on controversial images. All images were evaluated for the presence of a lesion, location of the lesion, and patterns of lung abnormality such as ground glass opacity (GGO), patchy mix consolidation, reticular interlobular septal thickening, segment and lobe involvement, mostly and minimally involved lobe, presence or absence of pleural and pericardial effusion, lymphadenopathy cavitation, underlying lung disorder, presence or absence of reversed halo sign, and crazy paving appearance. GGO is defined as increased lung density without obscuration of vascular and bronchial margins due to partial filling of airspaces.¹⁴ Consolidation is increased lung density with obscuration of bronchial and vascular structure.¹⁴ Reversed halo sign is described as a central GGO surrounded by denser consolidation in the shape of a crescent or a ring. Crazy paving appearance is defined as interlobular septal thickening in the background of GGO. Peripheral pulmonary lesions are defined as lesions in the peripheral one-third of the lung in the transaxial plane.¹⁴

Statistical Analysis

For data analysis, we used descriptive statistics including mean (SD) for describing continuous variables and frequency and percentage for describing categorical variables arranged in the frequency table and chart. Data were analyzed using Stata 14 (StataCorp, College Station, TX, USA).

Results

A total of 101 COVID-19 patients with a mean age of 55.21 ± 14.08 years (range: 27–87 years) were investigated. Fifty-four (53.47%) patients were male. The age distribution of the patients is shown in [Figure 1](#).

Less than half of the patients (36, 35.64%) had underlying diseases, including cardiac disorder (15.84%), diabetes (8.91%), chronic obstructive pulmonary disease (3.96%), asthma (2.97%), hypertension (2.97%), and renal failure (0.99) ([Figure 2](#)).

The main clinical symptoms at the early stage of illness were dry cough in 83 cases (82.18%), dyspnea in 73 cases (72.28%), and fever in 55 cases (54.46%). Based on the laboratory results, 45 (44.5%) had lymphopenia and in the vast majority of them, C-reactive protein level was 2 plus. Clinical and laboratory findings of investigated patients are presented in [Table 1](#).

The most common CT features were GGO, interlobular septal thickening, and patchy consolidation in 64.35%, 33.66%, and 26.73% of the cases, respectively. Other CT features are shown in [Figure 3](#).

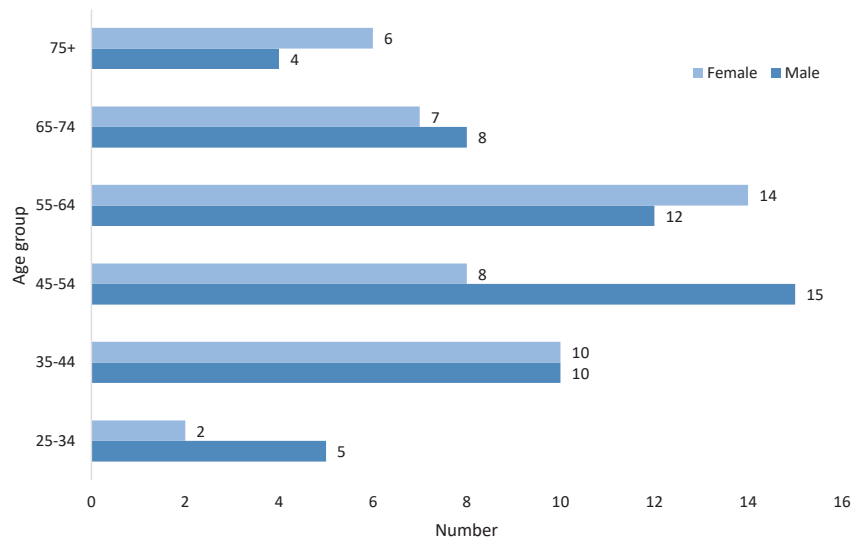


Figure 1. Age Distribution of COVID-19 Patients by Gender.

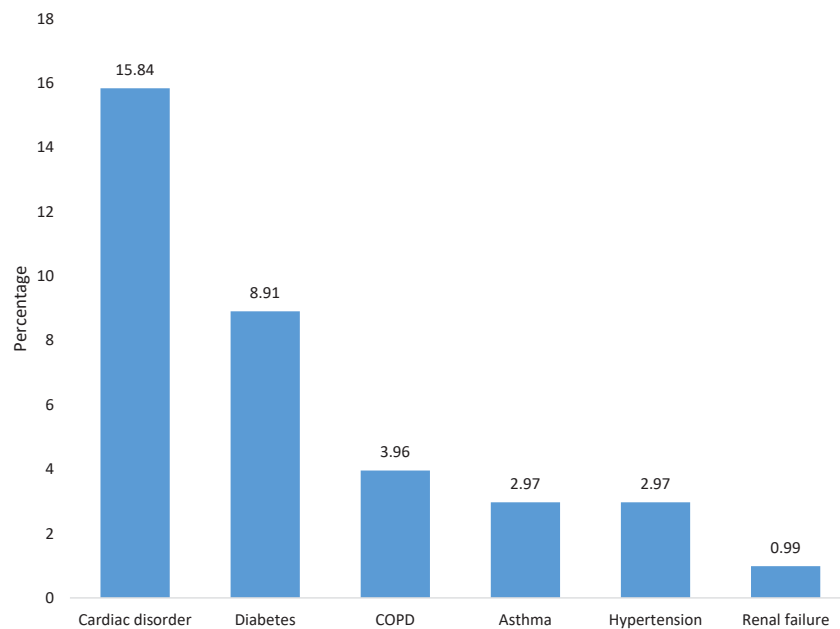


Figure 2. Frequency of Underlying Diseases in the COVID-19 Patients.

Findings at initial chest CT examination in the COVID-19 patients are presented in Table 2. Of the 101 patients, 99 patients (98.02%) had bilateral involvement, while two of them had unilateral involvement. Ninety-six patients (95.05%) had asymmetrical laterality and the right lobe was involved in 68.32% of them. At the first chest CT of the patients, the right upper, middle and, lower lobes were involved in 39 (32.67%), 13 (12.67%), and 69 (68.32%) cases, respectively. However, the left upper and lower lobes were involved in 33 (38.61%) and 58 (57.43%) cases, respectively. The most and least commonly involved sites were the right lower lobe and right middle lobe in 58 (57.43%) and 30 (29.70%) cases, respectively. With regard to CXR images, 35 (34.65%) patients had normal CXR at the first day of diagnosis. In relation to other radiographic

features of the patients, it can be noted that 10 (9.9%) cases had mild pleural thickening, 2 patients (1.98%) had pneumothorax, 6 of them (5.94%) had mild to moderate pleural effusion, and 2 (1.98%) patients had severe pleural effusion.

Discussion

COVID-19 is a novel coronavirus disease caused by SARS-CoV-2 that spread around the world. In the present study, 101 patients were enrolled. The mean age of the patients was 55.21 ± 14.08 years, ranging from 27 to 87 years. Thirty-six percent had underlying or coexisting medical disorders including diabetes, cardiac disease, hypertension, COPD, asthma, and end-stage renal disease. This is different from influenza pneumonia which involved

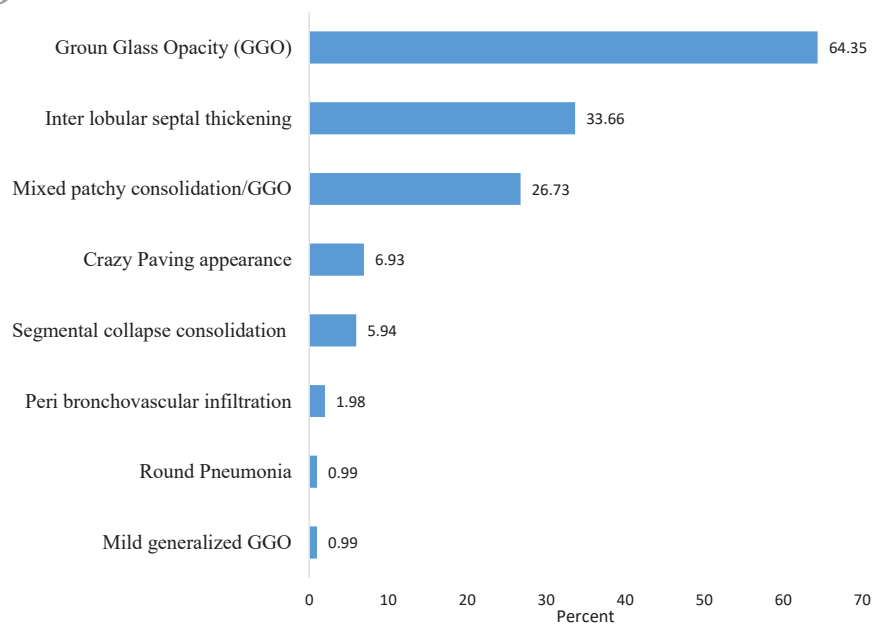


Figure 3. Chest CT Patterns of Lung Involvement in the COVID-19 Patients.

older patients with further underlying disorders.^{15,16}

The most common symptom was dry cough (83%), followed by dyspnea (73%). Only 55% of the patients had fever, and lymphopenia, anemia, and thrombocytopenia were seen in 45%, 17%, and 8% of the cases, respectively. Moreover, chest CT scan had a low rate of missed diagnosis of COVID-19 (3.9%) and should be considered as a rapid diagnostic tool.

In the study by Shan et al, the presence of ground glass opacities was reported in 15 asymptomatic patients and CT scan was suggested as a sensitive modality even in patients with false negative RT-PCR results and highly suspicious clinical findings.¹⁷ Considering the high false negative rate of RT-PCR^{18,19} and high sensitivity of CT scan (up to 98%),²⁰ chest CT scan is accepted as the first screening tool for diagnosis of Covid-19 pneumonia. Another imaging modality is chest X-ray; however, it is not as sensitive as chest CT in the evaluation of lung abnormality as the

first-line diagnostic tool in suspected cases. In the present study, about 35% of the patients showed normal CXR as the first-line imaging modality and 65% showed some nonspecific abnormal findings. According to the study conducted by Yoon et al, most Korean COVID-19 patients had normal chest X-ray or ambiguous findings,²¹ and chest radiographic abnormalities were seen only in 60% of Chinese COVID-19 patients. Yoon et al²¹ also emphasized that imaging findings are milder in COVID-19 than in two other similar viral infections (SARS and MERS-CoV pneumonia), and 33% of the COVID-19 cases had abnormal initial CXR while in the SARS and MERS-CoV infections, 78.3%–82.4% and 83.6% of initial CXRs were abnormal, respectively.²¹ Therefore, all clinicians should be aware of the limitations of CXR as the first-line imaging tool in the evaluation of COVID-19 pneumonia.

Based on the results of a study on 121 chest CT scans by Bernheim et al, 56% of the patients in the early stage (0-2 days after the onset of symptoms) had normal chest CT scan.² In this study, lung abnormality was seen in all the chest CT scans (100% of cases) that were performed 2-4 days after the onset of symptoms. CT findings of the patients were generally consistent with those of COVID-19 pneumonia patients in China.¹³

In the present study, two patients had unilateral right lung involvement (only in the right lower lobe), 98.02% showed bilateral lung involvement, and 95.05% of them had asymmetrical involvement. The predominant lung involvement was the right lung (69%), but in 27% of the patients, left lung involvement was dominant and 5% of them showed symmetrical abnormality in both lungs. In the study conducted by Bernheim et al, 20 (17%) patients had unilateral lung involvement, but the involvement of left and right lungs was separately seen in 7 and 13 patients, respectively.²

Table 1. Clinical and Laboratory Findings in the COVID-19 Patients

Variables	Characteristics	No. (%)
Signs and symptoms	Fever	55 (54.46)
	Dry cough	83 (82.18)
	Sore throat	4 (3.96)
	Dyspnea	73 (72.28)
Laboratory	Lymphopenia	45 (44.5)
	Thrombocytopenia	8 (7.92)
	Anemia	17 (16.83)
C-reactive protein	Negative	18 (17.82)
	+	61 (60.40)
	++	17 (16.83)
	+++	5 (4.95)

Table 2. Imaging Characteristics at the Initial Chest CT in the COVID-19 Patients

Variables	Characteristics	No. (%)
Lung involvement	Unilateral	2 (1.98)
	Bilateral	99 (98.02)
Laterality	Symmetrical	5 (4.95)
	Asymmetrical	96 (95.05)
Involved lung	Both lobe	5 (4.95)
	Right lobe	69 (68.32)
	Left lobe	27 (26.73)
Lung lobes involvement	Left lower lobe	58 (57.43)
	Left upper lobe	33 (38.61)
	Right upper lobe	39 (32.67)
	Right middle lobe	13 (12.87)
	Right lower lobe	69 (68.32)
	Lingual segment	12 (11.88)
	All	52 (51.49)
The most commonly involved sites	None	1 (0.99)
	Left lower lobe	29 (28.71)
	Left upper lobe	6 (5.94)
	Right upper lobe	9 (8.91)
	Right middle lobe	6 (5.94)
	Right lower lobe	58 (57.43)
	Lingual segment	3 (2.97)
The least commonly involved sites	None	6 (5.94)
	Left lower lobe	9 (8.91)
	Left upper lobe	12 (11.88)
	Right upper lobe	18 (17.82)
	Right middle lobe	30 (29.70)
	Right lower lobe	3 (2.97)
Lingual segment	28 (27.72)	

The hallmarks of novel coronavirus infection on images are bilateral and peripheral GGO and consolidative pulmonary opacities. However, in the study conducted by Bernheim et al, 22% of patients had no ground-glass opacity or consolidation,² while in our study, 55% of patients showed ground-glass opacity and 36% showed mixed GGO and patchy consolidation. In the pictorial review study by Ye et al, pure GGO (14-96%) and mixed GGO and consolidation (19%-59%) were reported²².

In this study, predominant abnormality was seen in the right lower lobe. Posterior, peripheral, and subpleural abnormalities were dominant features and anteriorly located segments and lobes such as right middle lobe, and lingual and anterior segments of upper and lower lobes showed less frequent and severe abnormality. The abnormality of these lobes and segments was often seen in severe cases and later in the course of the disease. In another systematic review of imaging findings of COVID-19 pneumonia, GGO was mainly seen in the lower lobe and it was less frequently seen in the middle lobe.²³ However, in the present study, right lower lobe

abnormality was often identified early and was the first radiologic finding in COVID-19 pneumonia. In the study by Wu et al,²⁴ the most frequent pattern was GGO (91%), followed by consolidation (63%) and interlobular septal thickening (59%).

In fact, this peripheral GGO with or without mixed patchy consolidation is not characteristics of COVID-19 pneumonia. Patchy GGO and consolidation with a predominantly subpleural and/or peribronchial distribution and lower lobe predominance are the most common imaging features in organizing pneumonia in CXR and chest CT scan; however, they can be found in all lung zones,^{25,26} so the involvement of lungs in COVID-19 pneumonia is categorized as organizing pneumonia.

Most pulmonary lesions in the viral infection were seen with peripheral and posterior lung predominance, which is not a characteristic finding of COVID-19 pneumonia. Distribution of SARS and H1N1 is also peripherally located.^{27,28} In another study by Li and Xia on 53 patients, 51 confirmed cases of COVID-19 (with nucleic acid testing) and two proved cases of adenovirus, CT findings of COVID-19 overlap with the CT findings of adenovirus infection, and CT of one of the two patients with confirmed adenovirus infection showed ill-defined patchy GGOs with segmental and subpleural consolidations in both lungs.²⁹ Li and Xia²⁹ noted that the GGO and consolidation are common CT features of COVID-19, which are also found in SARS and MERS infections and some other studies emphasize the non-specificity of chest CT finding. According to the study by Koo et al, influenza pneumonia affects the lung with lower lobe predominance.³⁰ Wang et al also emphasized the right lower lobe predominance in H7N9 influenza pneumonia.¹⁵ This is a nonspecific pattern of organizing pneumonia as immune reaction and corticosteroids might suppress and remove this type of lung abnormality. However, there are differences in the CT manifestations of patients with influenza and COVID-19 pneumonia. Complete consolidation is less common in COVID-19 pneumonia patients. In the study by Wang et al, most patients with H7N9 pneumonia showed complete consolidation.¹⁵

Another point about the pattern of lung involvement is that chest CT scan manifestation is altered with the course and severity of the disease.^{18,19} In the present study, in mild cases and in the early stage of disease, GGO was the predominant pattern and later with the progression of the disease, the pattern was followed by crazy paving and consolidation in chest CT. In addition, Shi et al³¹ showed progression of GGO to bilateral diffuse consolidation from the first to the second week of the infection after symptom onset and peripheral and posterior lung involvements were seen in 78% and 67% of cases, respectively. In addition, most of the lesions were ill-defined, composed of consolidation and ground glass opacities, and lower lobe predominance was also seen. Moreover, a less common nodular pattern was bronchovascular bundle. In the study on 121 chest CT by Bernheim et al,² there was a correlation

Archive of SID

between the onset of clinical symptoms and the initial chest CT scans (0-2 days: early, 3-5 days: intermediate, and 3-12 days: late). Bilateral lung involvement was observed in 10 of the 36 early patients (28%), 25 of the 33 intermediate patients (78%), and 22 of the 25 late patients (88%).

Reticular thickening, also known as interlobular septal thickening, is seen due to interstitial lymphocyte infiltration.¹⁸ This is the second frequent lesion in COVID-19 pneumonia.^{24,31} In the present study, 33% of patients showed interlobular septal thickening. Another atypical and less common finding was pleural changes such as pleural thickening and pleural effusion. The former was more frequent, 32% versus 5%.³¹

In this study, pleural thickening was seen in 10% and mild to moderate pleural effusion was seen in 6%. Two cases in the end stage of the disease showed moderate to severe pleural effusion. Reversed halo sign was seen in 5% of the patients. In the studies conducted by Bernheim et al and Yoon et al, reversed halo sign was reported in 2 and 3% of COVID-19 patients, respectively.^{2,21} This sign was first described as a specific finding in cryptogenic organizing pneumonia; however, recently, it was believed that this sign might indicate organizing pneumonitis due to some viral or fungal infections such as COVID-19 pneumonia.³²

In this study, other less frequent and atypical findings were seen as follow: 5% of the cases showed crazy paving appearance mostly in severe cases, 5% of patients had only one lobe or segment involvement, with the appearance of segmental or lobar consolidation, one case had peribronchovascular infiltration, one case showed typical round pneumonia, and one patient had mild generalized GGO in the entire lung.

There was no case with significant lymphadenopathy, cavitation, nodular lesion, or bronchiectasis. Air bronchogram was seen only in case of consolidation, and pericardial effusion was seen in 5%. Additionally, 5% had hyperaeration, and in two cases, mild unilateral pneumothorax was seen.

There are some limitations in this study such as the retrospective design of the study and lack of follow-up chest CT scans after the recovery of patients. Therefore, it is recommended that further studies should be done in the future for better evaluation of lung involvement and proper management. Moreover, follow-up chest CT after completing the treatment should be considered. In the study conducted by Shan et al, a deep learning model was developed for automatic diagnosis of the infected lobes and segments using follow-up CT scans performed every 3-5 days during management.¹² In a study by Kay and Abbara,³³ it is recommended that other patterns of lung involvement should be considered for accurate diagnosis and atypical features of lung involvement in chest CT.

Conclusion

CXR is not a sensitive method as the first-line imaging method in the diagnosis of COVID-19 pneumonia (35% normal CXR). Chest CT scan is very sensitive but it is

nonspecific and non-characteristic. The right lower lobe, mostly posterior basal segment, is the most commonly involved lobe and the right middle lobe showed the least involvement. GGO, predominantly in the lower posterior and peripheral parts of the lungs, was the most common imaging feature which is compatible with non-specific organizing pneumonia and about 12% showed atypical imaging patterns.

Availability of Data and Materials

All supporting data is available through the corresponding author.

Ethic Approval

The protocol was approved by the Ethics Committee of Hamadan University of Medical Sciences, Iran (Ethics code: IR.UMSHA.REC.1399.001, Research ID: 9903061349). Written informed consent for the survey was obtained from all the patients.

Conflict of Interest Disclosures

The authors declared no conflict of interests.

Authors' Contributions

FG, SHH, FK, and SK developed the original idea and the protocol, abstracted and prepared the manuscript. SK, MG, FG, and SB participated in the study design and analyzed the data. SB, FEA, FG, MM, FK, and MMM contributed to study design and data gathering. All authors drafted the work. All authors read and approved the final manuscript.

Funding

Hamadan University of Medical Sciences financially supported this study. This funding source had no role in analysis and interpretation of data, writing of the manuscript, or submitting it for publication.

Acknowledgements

The authors would like to appreciate the Vice-chancellor of Research and Technology, Hamadan University of Medical Sciences for funding the study. Additionally, we would like to thank the medical staff of public hospitals of Hamadan Province for their kind collaboration.

References

1. Zhu N, Zhang D, Wang W, Li X, Yang B, Song J, et al. A novel coronavirus from patients with pneumonia in China, 2019. *N Engl J Med*. 2020;382(8):727-33. doi: 10.1056/NEJMoa2001017.
2. Bernheim A, Mei X, Huang M, Yang Y, Fayad ZA, Zhang N, et al. Chest CT findings in coronavirus disease-19 (COVID-19): relationship to duration of infection. *Radiology*. 2020;295(3):200463. doi: 10.1148/radiol.2020200463.
3. Hung LS. The SARS epidemic in Hong Kong: what lessons have we learned? *J R Soc Med*. 2003;96(8):374-8. doi: 10.1258/jrsm.96.8.374.
4. Li Q, Guan X, Wu P, Wang X, Zhou L, Tong Y, et al. Early transmission dynamics in Wuhan, China, of novel coronavirus-infected pneumonia. *N Engl J Med*. 2020;382(13):1199-207. doi: 10.1056/NEJMoa2001316.
5. Chen N, Zhou M, Dong X, Qu J, Gong F, Han Y, et al.

- Epidemiological and clinical characteristics of 99 cases of 2019 novel coronavirus pneumonia in Wuhan, China: a descriptive study. *Lancet*. 2020;395(10223):507-13. doi: 10.1016/s0140-6736(20)30211-7.
6. Hui DS, E IA, Madani TA, Ntoumi F, Kock R, Dar O, et al. The continuing 2019-nCoV epidemic threat of novel coronaviruses to global health - the latest 2019 novel coronavirus outbreak in Wuhan, China. *Int J Infect Dis*. 2020;91:264-6. doi: 10.1016/j.ijid.2020.01.009.
 7. Chan JF, Yuan S, Kok KH, To KK, Chu H, Yang J, et al. A familial cluster of pneumonia associated with the 2019 novel coronavirus indicating person-to-person transmission: a study of a family cluster. *Lancet*. 2020;395(10223):514-23. doi: 10.1016/s0140-6736(20)30154-9.
 8. Guan WJ, Ni ZY, Hu Y, Liang WH, Ou CQ, He JX, et al. Clinical characteristics of coronavirus disease 2019 in China. *N Engl J Med*. 2020;382(18):1708-20. doi: 10.1056/NEJMoa2002032.
 9. World Health Organization (WHO). Coronavirus Disease 2019 (COVID-19): Situation Report, 46. WHO; 2020.
 10. Wang D, Hu B, Hu C, Zhu F, Liu X, Zhang J, et al. Clinical characteristics of 138 hospitalized patients with 2019 novel coronavirus-infected pneumonia in Wuhan, China. *JAMA*. 2020;323(11):1061-9. doi: 10.1001/jama.2020.1585.
 11. Huang C, Wang Y, Li X, Ren L, Zhao J, Hu Y, et al. Clinical features of patients infected with 2019 novel coronavirus in Wuhan, China. *Lancet*. 2020;395(10223):497-506. doi: 10.1016/s0140-6736(20)30183-5.
 12. Narin A, Kaya C, Pamuk Z. Automatic detection of coronavirus disease (covid-19) using x-ray images and deep convolutional neural networks. *Pattern Analysis and Applications*. 2021 9:1-4.
 13. Chung M, Bernheim A, Mei X, Zhang N, Huang M, Zeng X, et al. CT imaging features of 2019 novel coronavirus (2019-nCoV). *Radiology*. 2020;295(1):202-7. doi: 10.1148/radiol.2020200230.
 14. Hansell DM, Bankier AA, MacMahon H, McLoud TC, Müller NL, Remy J. Fleischner Society: glossary of terms for thoracic imaging. *Radiology*. 2008;246(3):697-722. doi: 10.1148/radiol.2462070712.
 15. Wang Q, Zhang Z, Shi Y, Jiang Y. Emerging H7N9 influenza A (novel reassortant avian-origin) pneumonia: radiologic findings. *Radiology*. 2013;268(3):882-9. doi: 10.1148/radiol.13130988.
 16. Li H, Weng H, Lan C, Zhang H, Wang X, Pan J, et al. Comparison of patients with avian influenza A (H7N9) and influenza A (H1N1) complicated by acute respiratory distress syndrome. *Medicine (Baltimore)*. 2018;97(12):e0194. doi: 10.1097/md.00000000000010194.
 17. Shan F, Gao Y, Wang J, Shi W, Shi N, Han M, et al. Lung Infection Quantification of COVID-19 in CT Images with Deep Learning. *arXiv preprint arXiv:200304655*. 2020.
 18. Xie X, Zhong Z, Zhao W, Zheng C, Wang F, Liu J. Chest CT for typical coronavirus disease 2019 (COVID-19) pneumonia: relationship to negative RT-PCR testing. *Radiology*. 2020;296(2):E41-E5. doi: 10.1148/radiol.2020200343.
 19. Huang P, Liu T, Huang L, Liu H, Lei M, Xu W, et al. Use of chest CT in combination with negative RT-PCR assay for the 2019 novel coronavirus but high clinical suspicion. *Radiology*. 2020;295(1):22-3. doi: 10.1148/radiol.2020200330.
 20. Fang Y, Zhang H, Xie J, Lin M, Ying L, Pang P, et al. Sensitivity of chest CT for COVID-19: comparison to RT-PCR. *Radiology*. 2020;296(2):E115-E7. doi: 10.1148/radiol.2020200432.
 21. Yoon SH, Lee KH, Kim JY, Lee YK, Ko H, Kim KH, et al. Chest radiographic and CT findings of the 2019 novel coronavirus disease (COVID-19): analysis of nine patients treated in Korea. *Korean J Radiol*. 2020;21(4):494-500. doi: 10.3348/kjr.2020.0132.
 22. Ye Z, Zhang Y, Wang Y, Huang Z, Song B. Chest CT manifestations of new coronavirus disease 2019 (COVID-19): a pictorial review. *Eur Radiol*. 2020;30(8):4381-9. doi: 10.1007/s00330-020-06801-0.
 23. Salehi S, Abedi A, Balakrishnan S, Gholamrezaezhad A. Coronavirus disease 2019 (COVID-19): a systematic review of imaging findings in 919 patients. *AJR Am J Roentgenol*. 2020;215(1):87-93. doi: 10.2214/ajr.20.23034.
 24. Wu J, Wu X, Zeng W, Guo D, Fang Z, Chen L, et al. Chest CT findings in patients with coronavirus disease 2019 and its relationship with clinical features. *Invest Radiol*. 2020;55(5):257-61. doi: 10.1097/rli.0000000000000670.
 25. Lee KS, Kullnig P, Hartman TE, Müller NL. Cryptogenic organizing pneumonia: CT findings in 43 patients. *AJR Am J Roentgenol*. 1994;162(3):543-6. doi: 10.2214/ajr.162.3.8109493.
 26. Webb WR, Muller NL, Naidich DP. High-Resolution CT of the Lung. Lippincott Williams & Wilkins; 2014.
 27. Yuan Y, Tao XF, Shi YX, Liu SY, Chen JQ. Initial HRCT findings of novel influenza A (H1N1) infection. *Influenza Other Respir Viruses*. 2012;6(6):e114-9. doi: 10.1111/j.1750-2659.2012.00368.x.
 28. Wong KT, Antonio GE, Hui DS, Ho C, Chan PN, Ng WH, et al. Severe acute respiratory syndrome: thin-section computed tomography features, temporal changes, and clinicoradiologic correlation during the convalescent period. *J Comput Assist Tomogr*. 2004;28(6):790-5. doi: 10.1097/00004728-200411000-00010.
 29. Li Y, Xia L. Coronavirus disease 2019 (COVID-19): role of chest CT in diagnosis and management. *AJR Am J Roentgenol*. 2020;214(6):1280-6. doi: 10.2214/ajr.20.22954.
 30. Koo HJ, Lim S, Choe J, Choi SH, Sung H, Do KH. Radiographic and CT features of viral pneumonia. *Radiographics*. 2018;38(3):719-39. doi: 10.1148/rg.2018170048.
 31. Shi H, Han X, Jiang N, Cao Y, Alwalid O, Gu J, et al. Radiological findings from 81 patients with COVID-19 pneumonia in Wuhan, China: a descriptive study. *Lancet Infect Dis*. 2020;20(4):425-34. doi: 10.1016/s1473-3099(20)30086-4.
 32. Song F, Shi N, Shan F, Zhang Z, Shen J, Lu H, et al. Emerging 2019 novel coronavirus (2019-nCoV) pneumonia. *Radiology*. 2020;297(3):E346. doi: 10.1148/radiol.2020209021.
 33. Kay FU, Abbara S. The many faces of COVID-19: spectrum of imaging manifestations. *Radiol Cardiothorac Imaging*. 2020;2(1):e200037. doi: 10.1148/ryct.2020200037.