

Case Report:

Liponeurocytoma of the Cerebellopontine Angle: An Interesting Case Report and Literature Review



Seyed Ali Mousavinejad¹, Ahmad Jabbari¹, Mahmoud Dehghan^{1*}, Kaveh Ebrahimzadeh¹, Kasra Amin Kazemi², Jouan Taheri Talesh², Omidvar Rezaei¹

1. Skull Base Research Center, Loghman Hakim Hospital, Shahid Beheshti University of Medical Sciences, Tehran, Iran

2. Department of Neurosurgery, Ayat Allah Mousavi Hospital, Zanjan University of Medical Sciences, Zanjan, Iran



Citation: Mousavinejad A, Jabbari A, Dehghan M, Ebrahimzadeh K, Amin Kazemi K, Taheri Talesh J, Rezaei O. Liponeurocytoma of the Cerebellopontine Angle: An Case Report and Literature Review. Iran J Neurosurg. 2019; 5(3):147-154. <http://dx.doi.org/10.32598/irjns.5.3.8>

<http://dx.doi.org/10.32598/irjns.5.3.8>



Article info:

Received: 17 Jan 2019

Accepted: 03 May 2019

Available Online: 01 Jul 2019

Keywords:

Liponeurocytoma, Hearing loss, Cerebellopontine Angle (CPA), Ataxia

ABSTRACT

Background and Importance: Liponeurocytoma is a rare tumor of the CNS. Some of its prominent features include low neuronal proliferation with foci of lipomatous differentiation. So far, 70 reports on cases of brain liponeurocytoma have been published. Most of them were located in the cerebellar hemisphere, but only 7 cases of primary Cerebellopontine Angle (CPA) liponeurocytoma have been reported.

Case Presentation: We presented a 27-year-old woman with a 6-month progressive headache and dizziness. More recently, she developed progressive hearing loss and ataxia. Pre-operative MRI of the brain demonstrated a heterogeneous solid extra-axial lesion in the right CPA with hydrocephalus. The operation was performed via the retro sigmoid approach. Histopathological diagnosis was confirmed as liponeurocytoma. No radiotherapy was performed. The patient was followed up for two years. There were no signs of recurrence.

Conclusion: Liponeurocytoma is a rare tumor. In most of the cases, it is presented in the cerebellum, and the CPA as the primary location of this tumor is extremely uncommon. Typically, surgery is the treatment of choice for these lesions. If the tumor is subtotal, radiotherapy after operation and resection can also be advantageous.

* Corresponding Author:

Mahmoud Dehghan, MD.

Address: Skull Base Research Center, Loghman Hakim Hospital, Shahid Beheshti University of Medical Sciences, Tehran, Iran

Tel: +98 (917) 7626365

E-mail: m.d21.9.1356@gmail.com



Highlights

- Liponeurocytoma is a rare tumor of the CNS.
- Majority of these tumors present in the cerebellum, so primary Cerebellopontine Angle (CPA) location of liponeurocytoma is extremely uncommon.
- Surgery is the treatment of choice and radiotherapy can also be advantageous in subtotal resection.

Plain Language Summary

Liponeurocytomas are rare tumors of the brain, most of which are located in the cerebellum. Only few cases are located in Cerebellopontine Angle (CPA). Surgery is the treatment of choice for these lesions. If the removal of the tumor is incomplete, post-surgical radiotherapy can also be advantageous.

1. Background and Importance

Liponeurocytoma is a very rare tumor of the central nervous system with neuroectodermal origin which was reported by Bechtel et al. in 1978 as “lipomatous medulloblastoma” [1]. They reported specific characteristics for cerebellar liponeurocytoma tumors, such as mixed mesenchymal and neuroectodermal features in a 44-year-old male with brain lesions.

Various changes have been made in the classification of this tumor by the World Health Organization (WHO) between 2000 and 2016. In 2000, the tumor was classified in the group of neuronal tumors and was defined as WHO grade I, but cerebellar liponeurocytoma was upgraded to grade II of glioneuronal tumor in the new classification according to higher recurrence rate [2]. It is predominantly located in the posterior cranial fossa and characteristically emerging in adults. Lipidized medulloblastoma, lipomatous medulloblastoma and neurolipocytoma are different names that have been considered for this tumor in the past [3, 4]. Histopathological examination of the tumor cells presented lipidized cells are found between small neoplastic cells with focal lipomatous differentiation. Today, surgery is the treatment of choice for these lesions.

To date, about 70 cases of brain liponeurocytoma have been reported in the literature but Cerebellopontine Angle (CPA) liponeurocytoma has been reported only in 7 patients. Herein, we presented the clinical, radiological and histopathological features of a case of CPA liponeurocytoma and reviewed the literature for a better comprehension of this pathology.

2. Case Presentation

A 27-year-old woman referred to our clinic with a history of headache and dizziness for 6 months. She developed progressive hearing loss and ataxia. Through neurological examination, an ataxic gait was observed. It was deviated to the right side, closely linked to the mild dyadiachokinesia in the right side, revealing the right sensorineural hearing loss. MRI of the brain demonstrated a 3.5×4×2 cm heterogeneous solid extra-axial lesion, centered in the right CPA. The tumor compressed the brainstem, the right cerebellar hemisphere, and the fourth ventricle, causing hydrocephalus. But no invasion and peritumoral edema were observed in these areas. The lesion was hypointense in T1-weighted MRI sequences with heterogeneous contrast enhancement and hyperintense in T2-weighted MRI sequences (Figure 1).

A right lateral suboccipital retro sigmoid approach was performed with the patient in a lateral decubitus position. After the dural opening, the cerebellum gently retracted, and cisterns were opened to drain the Cerebrospinal Fluid (CSF). The tumor was internally decompressed with an ultrasonic aspirator. It was dissected from the cerebellum, brainstem and other inflicted areas. The seventh and eighth cranial nerves and the Posterior-Inferior Cerebellar Artery (PICA) were also affected, but they were removed with ease. Complete microsurgical resection was achieved. Two weeks after the tumor resection, the patient underwent shunt placement due to hydrocephalus. After the total resection, the patient did not receive radiation therapy. She did not present any clinical or radiological signs of progression on the last follow-up two years after the surgery.

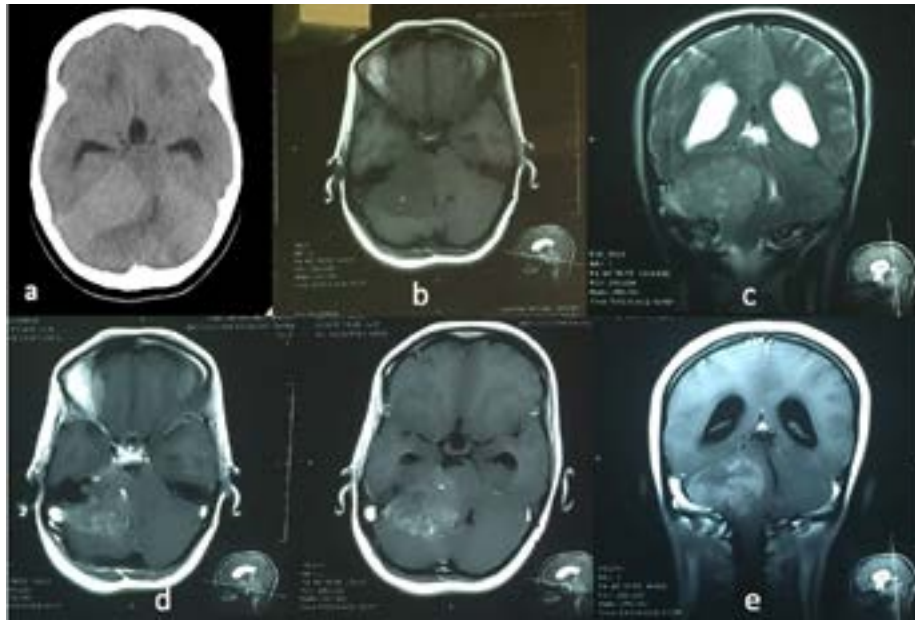


Figure 1. Computed tomography scans

A. An isodense ill-defined lesion of the right Cerebellopontine Angle (CPA); B. The lesion showing an isointensity on T1-weighted imaging and; C. T2-weighted imaging; D,E. A light, diffuse contrast enhancement on axial and coronal T1-weighted imaging with contrast.

Histopathological report

In histopathological findings, hematoxylin and eosin-stained paraffin sections revealed a predominant cellular tumor with a compact growth, tumor cells mainly include light eosinophilic with clear cytoplasm in some areas in addition to round to oval nuclei and smaller nucleoli (Figure 2). No necrosis and microvascular proliferation and mitosis were seen. On immunohistochem-

istry staining profile, the neurocytic tumor cells were strongly positive for synaptophysin which showed their neuronal lineage, and negative for glial fibrillary acidic (GFAP) and epithelial membrane antigen. Immunostaining for Ki-67, a marker of proliferation, showed a nuclear labeling index of 4%-5%. Thus, the diagnosis of cerebellar liponeurocytoma was determined (Figure 2). There was no recurrence within the two-year follow-up on MRI. The patient had no complaint or symptoms.

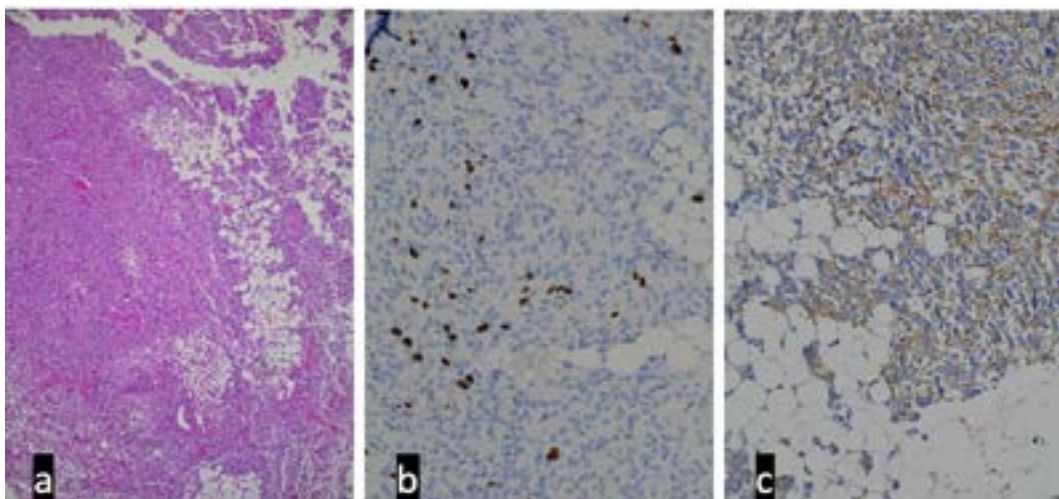


Figure 2. Slide showing biphasic neoplasm with admixture of neurocytes and lipidized cells

A. The neurocytes are arranged in densely cellular sheets of monotonous cells with scanty cytoplasm, rounded to oval nuclei, salt and pepper chromatin; B. IHC staining for GFAP shows negative reaction in tumoral cells; C. IHC staining for synaptophysin showing positive reaction in tumoral cells.

3. Discussion

Cerebellar liponeurocytoma is a rare tumor of CNS, and it was upgraded to grade II of glioneuronal tumor according to the new classification of WHO in 2016 [2]. The exact origin of cerebellar liponeurocytomas remains unclear. Because of some morphological relationships to embryonal neoplasm, cerebellar liponeurocytoma was primarily called lipomatous medulloblastoma. As its name implies, it is observed in the cerebellum, but two cases of supra-tentorial extension from cerebellar liponeurocytoma [5, 6] and spinal extension to the C1-C2 space from cerebellar liponeurocytoma have been reported [7, 8]. According to our best knowledge, about 70 cases of liponeurocytoma exist in the literature, while only 7 cases of CPA liponeurocytoma have been reported so far, and our case is the eighth case of CPA liponeurocytoma (Table 1).

Like the cerebellum liponeurocytoma in the CPA tumors, the average age of the onset of this tumor is between the third to fifth decades of life with equal preva-

lence in men and women [9]. In the study of 7 cases of liponeurocytoma, 4 patients were male and 3 were female [3, 7, 9-12]. Our patient was a 27-year-old woman. The interval between the onset of symptoms and the diagnosis of lesion in patients with CPA liponeurocytoma is, on average, 17 months, from 2 weeks to 2 years. This period in our patient was 3 months.

CPA liponeurocytoma usually shows the symptoms of cranial nerve involvement, cerebellar lesions or symptoms of hydrocephalus. In 4 patients, hearing impairment was observed when diagnosing the disease. Hydrocephalus was observed in 2 patients with CPA liponeurocytoma. In our patient's imaging, we also observed hydrocephalus, which did not recover after the resection of the tumor in the follow-up period; thus, a shunt was embedded in the patient 2 weeks after the resection of the tumor.

Currently, there is no radiological pathognomonic marker for the diagnosis of this tumor, and the tumor is present in CT as an isodense lesion [13]. MRI findings

Table 1. Published Cases of CPA Liponeurocytomas in the Literature

Reference Cases	Sex	Age	Symptoms	Location	Time to Presentation	Extension of Resection	Postoperative Adjuvant Radiotherapy	Follow-up	Recurrence
Soylemezoglu, 1996 [9]	Female	59	Dizziness, Headache	Left CPA	3 w	GTR	Yes	60 mon	No
	Male	53	Hearing loss Vertigo, ataxia,	Left CPA	6 y	GTR	No	10 y	Yes
Alleyne, 1998 [10]	Male	66	Gait ataxia, dizziness, ringing in both ears	Left CPA	2 y	GTR	Yes	NA mon	N/A
Alkadhi, 2001 [7]	Male	53	Vertigo, progressive ataxia, hearing loss, tinnitus	RT CPA	4 mon	GTR	No	15 mon	No
Patel, 2009 [11]	Male	40	Headache	RT CPA	1 y	GTR	No	36 mon	No
Oudrhiri, 2014 [3]	Female	64	Headache, nausea	RT CPA	7 mon	GTR	No	24 mon	No
Chiaramon, 2018 [12]	Female	35	Hearing loss	RT CPA	2 w	GTR	No	48 mon	No
Our case	Female	27	Hearing loss, headache, ataxia	Left CPA	3 mon	GTR	No	24 mon	No



can be different depending on the distribution and proportion of lipidized tissue. In the MRI view, the tumor is viewed as isointensity on T1-weighted imaging, heterogeneous intensity on T2-weighted imaging, and high intensity on diffusion-weighted imaging. As in the case of cerebellum liponeurocytoma, these lesions do not show significant enhancement in MRI with injections [14-16].

In a study, mild tumor enhancement was observed in MRI with injection only in 4 out of 7 patients with CPA. Edema around the tumor in these lesions is usually absent or very small [17]. This neoplasm must be distinguished from CPA medulloblastoma and ependymomas. Unclear clinical and radiological features of the tumor make differential diagnosis burdensome. Therefore, pathological considerations and immunohistochemistry of liponeurocytoma are critical to diagnosing and distinguishing it from other tumors.

In histological analysis, foamy histiocytes and primitive neuroectodermal cells may manifest in classic medulloblastoma. A high proliferative index conveys the malignant tumor existing in medulloblastoma. Cerebellar liponeurocytoma frequently shows a TP53 missense mutation which is more common than that of medulloblastoma plus the absence of isochromosome 17q (the genetic indication of this brain tumor) [18].

Liponeurocytomas are neuroectodermal tumors in which many lipidized cells resembling mature adipocytes are in cluster forms or dispersed between small neuronal and glial cells. Neuronal differentiation is usually positive for immunocytochemistry neuronal markers (synaptophysin; MAP-2). Mitoses, regions of vascular proliferation and necrosis are all rare. Proliferation index, has been usually low (<5%) in most reported cases in the literature, the Immunohistochemical Staining (IHC) indicated both neuronal and glial differentiation: for example, positive for synaptophysin, NSE, and MAP-2, and focal expression of GFAP [15, 19, 20]. Complete tumor resection as soon as possible is the best therapeutic option, however, there is no agreement on usage of postsurgical radiotherapy for liponeurocytomas, and its role in preventing the recurrence of them is under debate [21, 22].

In a study, tumor recurrence was observed in 50% of the patients with cerebellar liponeurocytoma who had not received radiotherapy following tumor surgery, but no tumor recurrence was reported in patients undergoing radiotherapy after surgery [23]. According to various studies, high Ki-67 positive cells (more than 10%) and subtotal tumor resection of the tumor are two main risk factors for tumor recurrence [6, 23].

In 8 patients with CPA liponeurocytoma, total tumor resection was performed in all of them. This represents the benign behavior of this tumor which showed no significant adhesion and invasion of the cranial nerves and vascular architecture. The easy and complete isolation of the tumor from these vital elements is also a factor confirming the benign nature of this tumor. In these 8 cases, only 2 patients were treated with radiotherapy after surgery.

In 6 other follow-up patients, only 2 of these patients had recurrence of the tumor 10 years after surgery, who underwent a reoperation. In patients with incomplete removal of the tumor, adjuvant postoperative radiotherapy seems to be advantageous leading to higher tumor-free survival. Thus, long-term close follow-up with constant regular imaging are recommended in course of treatment of these patients.

In this study, the treatment strategy for the present patient was surgery and close follow-up. Total resection was performed according to intraoperative observations and by post-operative MRI. Besides, the Ki-67 was low. Radiotherapy was not suggested, and close observation continued during the follow-up for the two consecutive years. There were no signs of recurrence of the lesion.

4. Conclusion

Our patient is the eighth case among all CPA liponeurocytomas recorded in the literature, suggesting that, especially when lipid content is visible in the imaging, the liponeurocytoma should be highlighted in the differential diagnosis of CPA tumors. Treatment of CPA is merely surgical with the goal of complete elimination. The role of postoperative radiotherapy treatments is still controversial.

Ethical Considerations

Compliance with ethical guidelines

All ethical principles were considered in this article. The participants were informed about the purpose of the research and its implementation stages; they were also assured about the confidentiality of their information. Moreover, they were allowed to leave the study whenever they wish, and if desired, the results of the research would be available to them.

Funding

This research did not receive any specific grant from funding agencies in the public, commercial, or not-for-profit sectors.

Authors' contributions

Conceptualization and methodology: Ahmad Jabbari and Mahmoud Dehghan; Data collection: Mahmood Dehghan; Drafting the article: Seyed Ali Mousavinejad and Mahmood Dehghan; Critically revising the article and reviewing the submitted version of manuscript: All authors.

Conflict of interest

The authors declared no conflict of interest.

References

- [1] Bechtel JT, Patton JM, Takei Y. Mixed mesenchymal and neuroectodermal tumor of the cerebellum. *Acta Neuropathologica*. 1978; 41(3):261-3. [DOI:10.1007/BF00690447] [PMID]
- [2] Louis DN, Perry A, Reifenberger G, Von Deimling A, Figarella-Branger D, Cavenee WK, et al. The 2016 World Health Organization classification of tumors of the central nervous system: A summary. *Acta Neuropathologica*. 2016; 131(6):803-20. [DOI:10.1007/s00401-016-1545-1] [PMID]
- [3] Oudrhiri MY, Raouzi N, El Kacemi I, El Fatemi N, Gana R, Maaqili MR, et al. Understanding cerebellar liponeurocytomas: Case report and literature review. *Case Reports in Neurological Medicine*. 2014; 2014:186826. [DOI:10.1155/2014/186826] [PMID] [PMCID]
- [4] Konovalov AN, Konovalov NA, Pronin IN, Shishkina LV, Zolotova LI, Yakovlenko YG, et al. [Multiple primary liponeurocytoma of the central nervous system (Russian)]. *Zhurnal Voprosy Neurokhirurgii Imeni N. N. Burdenko*. 2015; 79(2):87-96. [DOI:10.17116/neiro201579287-96] [PMID]
- [5] Anghileri E, Eoli M, Pattera R, Ferroli P, Pollo B, Cuccarini V, et al. FABP4 is a candidate marker of cerebellar liponeurocytomas. *Journal of Neuro-Oncology*. 2012; 108(3):513-9. [DOI:10.1007/s11060-012-0853-0] [PMID]
- [6] Limaiem F, Bellil S, Chelly I, Bellil K, Mekni A, Jemel H, et al. Recurrent cerebellar liponeurocytoma with supratentorial extension. *Canadian Journal of Neurological Sciences*. 2009; 36(5):662-5. [DOI:10.1017/S0317167100008222] [PMID]
- [7] Alkadhi H, Keller M, Brandner S, Yonekawa Y, Kollias SS. Neuroimaging of cerebellar liponeurocytoma. Case report. *Journal of Neurosurgery*. 2001; 95(2):324-31. [DOI:10.3171/jns.2001.95.2.0324] [PMID]
- [8] Kachhara R, Bhattacharya RN, Nair S, Radhakrishnan VV. Liponeurocytoma of the cerebellum: A case report. *Neurology India*. 2003; 51(2):274-6. <http://www.neurologyindia.com/text.asp?2003/51/2/274/1108>
- [9] Soylemezoglu F, Soffer D, Onol B, Schwechheimer K, Kleihues P. Lipomatous medulloblastoma in adults: A distinct clinicopathological entity. *The American Journal of Surgical Pathology*. 1996; 20(4):413-18. [DOI:10.1097/0000478-199604000-00003] [PMID]
- [10] Alleyne JC, Hunter S, Olson JJ, Barrow DL. Lipomatous glioneurocytoma of the posterior fossa with divergent differentiation: Case report. *Neurosurgery*. 1998; 42(3):639-43. [DOI:10.1097/00006123-199803000-00035] [PMID]
- [11] Patel N, Fallah A, Provias J, Jha NK. Cerebellar liponeurocytoma. *Canadian Journal of Surgery*. 2009; 52(4):E117-E9. [PMID] [PMCID]
- [12] Chiaramonte C, Rabaste S, Jacquesson T, Meyronet D, Cotton F, Jouanneau E, et al. Liponeurocytoma of the Cerebellopontine Angle. *World Neurosurgery*. 2018; 112:18-24. [DOI:10.1016/j.wneu.2018.01.012] [PMID]
- [13] Giangaspero F, Cenacchi G, Roncaroli F, Rigobello L, Manetto V, Gambacorta M, et al. Medulloctoma (lipidized medulloblastoma): A cerebellar neoplasm of adults with favorable prognosis. *The American Journal of Surgical Pathology*. 1996; 20(6):656-64. [DOI:10.1097/0000478-199606000-00002] [PMID]
- [14] Guan J, Geng Y, Cheng Y, Guo Y, Wu R. Magnetic resonance imaging of cerebellar liponeurocytoma: A case report and review of the literature. *The Neuroradiology Journal*. 2012; 25(3):331-6. [DOI:10.1177/197140091202500308] [PMID]
- [15] Kuchelmeister K, Nestler U, Siekmann R, Schachenmayr W. Liponeurocytoma of the left lateral ventricle. *Clinical Neuro-pathology*. 2006; 25(2):86-94. [PMID]
- [16] Akhaddar A, Zrara I, Gazzaz M, El Moustarchid B, Benomar S, Boucetta M. Cerebellar liponeurocytoma (lipomatous medulloblastoma). *Journal of Neuroradiologie (Journal de Neuroradiologie)*. 2003; 30(2):121-6. <http://europepmc.org/article/med/12717299>
- [17] Horstmann S, Perry A, Reifenberger G, Giangaspero F, Huang H, Hara A, et al. Genetic and expression profiles of cerebellar liponeurocytomas. *Brain Pathology*. 2004; 14(3):281-9. [DOI:10.1111/j.1750-3639.2004.tb00065.x] [PMID]
- [18] Jouveta A, Lellouch-Tubiana A, Boddaert N, Zerah M, Champier J, Fèvre-Montange M. Fourth ventricle neurocytoma with lipomatous and ependymal differentiation. *Acta Neuropathologica*. 2005; 109(3):346-51. [DOI:10.1007/s00401-004-0963-7] [PMID]
- [19] Gupta K, Salunke P, Kalra I, Vasishta R. Central liponeurocytoma: Case report and review of literature. *Clinical Neuro-pathology*. 2011; 30(2):80-5. [DOI:10.5414/NPP30080] [PMID]
- [20] Nishimoto T, Kaya B. Cerebellar liponeurocytoma. *Archives of Pathology & Laboratory Medicine*. 2012; 136(8):965-9. [DOI:10.5858/arpa.2011-0337-RS] [PMID]
- [21] Châtillon C, Guiot M, Roberge D, Leblanc R. Cerebellar liponeurocytoma with high proliferation index: Treatment options. *Canadian Journal of Neurological Sciences*. 2009; 36(5):658-61. [DOI:10.1017/S0317167100008210] [PMID]
- [22] Jackson TR, Regine WF, Wilson D, Davis DG. Cerebellar liponeurocytoma: Case report and review of the literature.



Journal of Neurosurgery. 2001; 95(4):700-3. [DOI:10.3171/jns.2001.95.4.0700] [PMID]

- [23] Radke J, Gehlhaar C, Lenze D, Capper D, Bock A, Heppner FL, et al. The evolution of the anaplastic cerebellar liponeurocytoma: Case report and review of the literature. *Clinical Neuropathology*. 2015; 34:19-25. [DOI:10.5414/NP300783] [PMID]