

Research Paper: Risk of Dependency Following Microsurgical Clipping in Good Grade Patients With Ruptured Anterior Circulation Aneurysms



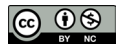Sundus Ali^{1,2*}, Fauzia Sajjad¹, Asif Shabbir¹, Akmal Azeemi¹

1. Punjab Institute of Neurosciences, Lahore, Pakistan.
2. Department of Neurosurgery, King Edward Medical University/Mayo Hospital, Lahore, Pakistan.



Citation: Ali S, Sajjad F, Shabbir A, Azeemi A. Risk of Dependency Following Microsurgical Clipping in Good Grade Patients with Ruptured Anterior Circulation Aneurysms. Iran J Neurosurg. 2021; 7(1):49-56. <http://dx.doi.org/10.32598/irjns.7.1.6>

doi: <http://dx.doi.org/10.32598/irjns.7.1.6>



Article info:

Received: 10 Sep 2020
Accepted: 02 Dec 2020
Available Online: 01 Jan 2021

Keywords:

Intracranial Aneurysm, Clips, Surgical, Dependence, Anterior Circulation

ABSTRACT

Background and Aim: Most good grade (WFNS I and II) patients who undergo microsurgical clipping achieve a favorable outcome. However, some independent patients before surgery face unfavorable outcomes after the operation, signifying the impact of microsurgical clipping. This study aimed to identify the risk of developing dependency in patients without previous neurological deficits.

Methods and Materials/Patients: We reviewed 50 consecutive good grade patients with ruptured anterior circulation aneurysms who underwent microsurgical clipping between May 2017 and May 2020 in the Department of Neurosurgery, Punjab Institute of Neurosciences, Lahore, Pakistan. The clinical outcome at discharge and three months follow-up was assessed using the Glasgow Outcome Scale (GOS).

Results: In this study, seven patients (14%) became dependent (GOS II and III) following clipping. Of whom, five patients (10%) suffered surgical insult in the form of intraoperative rupture (4%), post-op infarct (4%), and direct brain damage (2%).

Conclusion: Patients without neurologic deficit pre-operatively still suffer unfavorable outcomes mainly due to operative complications. Vascular injuries remain the main cause of morbidity-producing dependency. Therefore, all surgical techniques must minimize the risk to vessels, both during dissection and at clip placement.

* Corresponding Author:

Sundus Ali, FCPS, FRCSEd.

Address: Department of Neurosurgery, King Edward Medical University/Mayo Hospital, Lahore, Pakistan

Tel: +92 (32) 14519497

E-mail: sundusunn@gmail.com



Highlights

- Microsurgical clipping of ruptured anterior circulation aneurysms in good grade patients is generally safe, but almost 10% of them were rendered dependent due to surgical insult alone.
- A direct vascular injury like intraoperative rupture resulting from faulty clip placement was the culprit in 4%, while another 4% suffered from inadvertent parent vessel inclusion in the clip.
- The use of rigid retractors was faced with direct brain damage leading to brain contusion in 2% of cases emphasizing dynamic retraction as a safer option.

Plain Language Summary

Bulging or ballooning of the artery due to weakness in the vessel wall that supplies blood to the brain is termed “cerebral aneurysm”. The weakness of the vessel wall is prone to rupture, leading to blood spreading in subarachnoid space, which may extend to adjacent parenchyma and/or ventricles and can be life-threatening. The carotid artery and vertebral artery on each side are the chief vessels supplying blood to the brain. The carotid system is referred to as anterior circulation, while the vertebral system makes posterior circulation. The affected patients are usually in their fourth to sixth decade of life with a female preponderance. Acute rupture calls for intensive care admission, stabilization, and assessment regarding the severity of the bleeding. This assessment involves clinical examination as well as imaging like brain scan and angiography of brain vessels. Patients are then graded according to their clinical well-being as good, bad, or worse. Cerebral angiography helps define that whether the affected vessel belongs to anterior or posterior circulation. It also provides a roadmap to select the treatment modality best suited for an individual case. Both open surgery and endovascular treatment options exist for most cases. Although open surgery is invasive, clipping the neck of an aneurysm is the definitive treatment. Good-grade patients of anterior circulation ruptured aneurysms, who have no pre-operative focal neurological deficits (WFNS I & II), are expected to stay independent following clipping, but oftentimes they do not. Here, we aim to look at the surgical risk factors leading to developing dependency in previously independent patients, thereby focusing only on the impact of surgical expertise available in a resource-limited setup. Vascular injuries in the form of parent vessel occlusion leading to early infarct, intraoperative rupture, and direct brain damage due to rigid retractor were the culprits.

1. Introduction

Cerebral aneurysms are the most frequent cause of spontaneous Subarachnoid Hemorrhage (SAH), ranging from 1.1 to 92.3 per 100000 people per year [1, 2]. The incidence increases with age, and approximately 80% of cases occur in people aged 40-65 years, with a preference for women (3:2) [3]. Risk factors for rupture of an aneurysm are age, female gender, hypertension, substance abuse (cigarette, cocaine), pregnancy, and oral contraceptive pills [1-3]. Approximately 85% of intracranial aneurysms occur in the anterior circulation [1, 4, 5]. More than a third arises from the Anterior communicating Artery (AcoA) complex, while Internal Carotid-Post Communicating junction (IC-PC) is the next most common site. The Middle Cerebral Artery (MCA) accounts for about 20% and usually occur at a bifurcation or trifurcation [1, 4].

SAH has high mortality and morbidity, with 10%-15% dying before reaching the hospital, while overall mortality is

45% in the first 30 days [1]. Among patients surviving initial hemorrhage, re-bleeding is a significant risk in 15%-20% in the first two weeks if not treated surgically. Vasospasm kills 7% and leaves another 7% dependant [1, 6]. The clinical status of patients, which is graded by the WFNS (World Federation of Neurological Surgeons) scale, directly correlates with patient outcome. The higher age of the patient is another nasty prognostic factor in addition to preexisting comorbidities [7].

Computerized Tomography (CT) is the first line of investigation. Digital Subtraction Angiography (DSA) has remained the gold standard giving anatomical details of an aneurysm besides assessing primary feeding arteries and collaterals. CT Angiogram (CTA) is as safe and effective as DSA in 97% of the cases as a sole imaging study [1]. Among treatment strategies, microsurgical clipping, and endovascular coiling, are considered equivalent [8], with microsurgical clipping more widely practiced in developing countries being cost-effective [9].



The impact of clipping on the outcome of patients with no pre-operative neurological deficit is yet to be determined. Butlers et al. studied 200 good-grade patients who underwent microsurgical clipping, and reported 9.6% as dependant at three months follow-up [10].

There is no local study available showing the impact of clipping on the neurological functions of those who survived after the treatment. Thus, the present study is designed to evaluate the clinical outcome of microsurgical clipping regarding morbidity in terms of dependency. This study will add to existing knowledge by providing statistics in our society and comparing them with international data. This study will also set a ground to devise a proper neurovascular training protocol for junior doctors in developing countries to improve their surgical skills by developing low-cost animal labs at the minimum [11]. We aim to identify the risk factors leading to dependency following microsurgical clipping in good-grade patients with ruptured anterior circulation aneurysms.

2. Methods and Materials/Patients

This study was conducted at the Department of Neurosurgery, Punjab institute of Neurosciences, Lahore, Pakistan, from May 2017 to May 2020. In this descriptive case series, 50 patients were selected by the non-probability, purposive sampling method. All good-grade patients (WFNS grade 1 and 2) of 18-65 years old, irrespective of sex, presented with spontaneous SAH due to ruptured anterior circulation aneurysms (confirmed by 4-vessel angiography) were included. Patients who were not fit for surgery due to comorbidities like uncontrolled hypertension, diabetes, or ischemic heart disease were excluded.

After taking informed consent, all patients underwent microsurgical clipping under general anesthesia throughpterional craniotomy by the same surgical team. All patients were operated on after day 14 taking the day of hemorrhage as day 0. Operative notes, post-op neurological status, and imaging were reviewed. Post-op deficits were divided into surgical and non-surgical. Any deficit occurring immediately following surgery that is not attributable to vasospasm, hydrocephalus, or other medical deterioration was labeled as surgical, while the presence of any of these was labeled as non-surgical. At discharge, the neurological status of the patients in terms of the Glasgow Outcome Scale (GOS) was prepared. The patients were followed in the outpatient clinic at one month and three months intervals in terms of GOS. Patients with GOS II and III were labeled as dependent. Assessment at the end of 3 months was taken as the final score.

Data analysis

Statistical analysis of data was done using SPSS v. 22. All the variables were identified. Demographic variables of the patients were analyzed using simple descriptive statistics. The Mean±SD were calculated for age. Frequency and percentages were determined for qualitative variables, i.e., gender, clinical grade, and dependency. Data were stratified for age to address the effect of the modifiers.

3. Results

In this study, the minimum and maximum age of presentation were 18 and 65 years, respectively. The mean age of the patients was 48.32 years. The majority presented during the fourth decade, i.e., 36% (18/50), followed by the fifth decade 28% (14/50). Presentation of MCA aneurysms was relatively earlier compared to IC-PC and AcoA aneurysms. About 33% of MCA aneurysms presented in the second decade.

We had a female preponderance of 56% (28/50), especially females during the fifth decade were affected more than males in a ratio of 3:1. Regarding the distribution of aneurysms, AcoA aneurysms were found more frequently (16/50) in males than females (14/50), while in MCA aneurysms, the ratio was equal (1:1). All IC-PC aneurysms (8/50) were found in female patients only. The distribution of aneurysms according to age and gender is depicted in [Figure 1](#).

[Figure 2](#) shows the outcome in terms of GOS after surgery, at one month and three months. We had gross mortality of 8% (4/50) while seven patients (14%) were rendered dependent (GOS II and III) following clipping. Out of this, five patients (10%) suffered surgical insult in the form of intraoperative rupture (4%), post-op infarct (4%), and direct brain damage manifesting as a contusion (2%) ([Figure 3](#)).

4. Discussion

This study was conducted to identify the frequency and causes of dependency in patients with good-grade aneurysmal SAH undergoing surgical repair, which, by definition, had no pre-operative focal neurological deficits complicating the assessment of outcome. We included 50 consecutive good-grade patients with ruptured aneurysms of anterior circulation over three years. All patients underwent microsurgical clipping at Punjab Institute of Neurosciences, Lahore, Pakistan, which is considered a relatively high volume center for such cases.

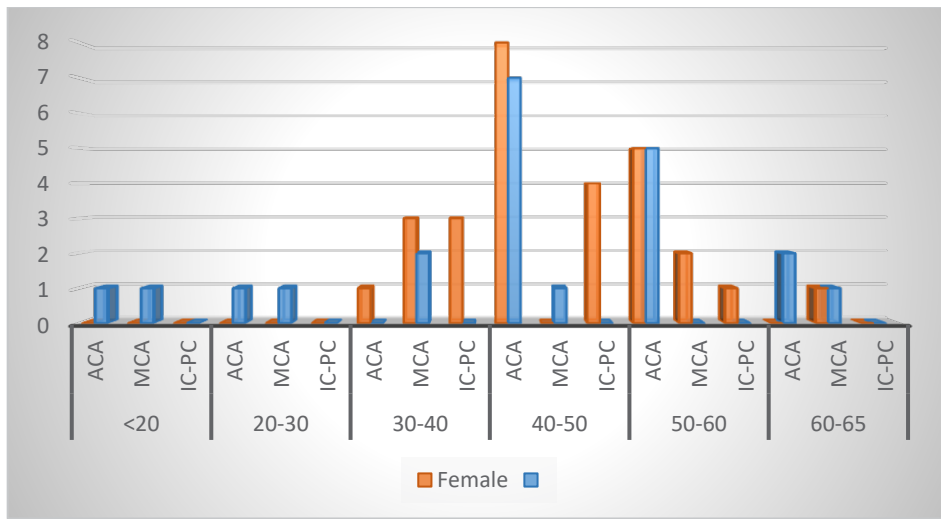


Figure 1. Graphical depiction of age, gender, and location of the aneurysm



Regarding the surgical outcome of ruptured aneurysms, many large series are available addressing the effect of grade, the timing of surgery, and the effect of intraoperative hypothermia [12-15]. But fewer reports are explicitly directed to the complications occurring during surgery, which are too complicated by including poor-grade patients [16, 17]. However, some comparisons can be drawn by the breakdown of patients into subgroups. To the best of our knowledge, Butlers et al. were the only researchers documenting the surgical outcome of good-grade patients [10]. However, a minority of their cases were of posterior circulation aneurysms. So for practical purposes, we compared our results to the relevant subgroups of the significant studies documenting the outcomes of clipping, as depicted in Table 1.

At three months follow-up, we had 78% (39/50) patients labeled as independent; this is comparable to the International Cooperative Study on Timing of Aneurysm Surgery reported a 79% rate of independence among good-grade patients [12]. Butlers et al. reported 88.9% good outcome in patients with grade 1 and 2 at three months follow-up [10]. Four patients died in our study (8%). In three out of four patients, death occurred due to operative complications. One case of operative mortality is illustrated in Figure 1. Pulmonary embolism was found to be the non-surgical cause of mortality in one patient.

Seven patients (14%) became dependant following surgical intervention at our place. Butlers et al. reported

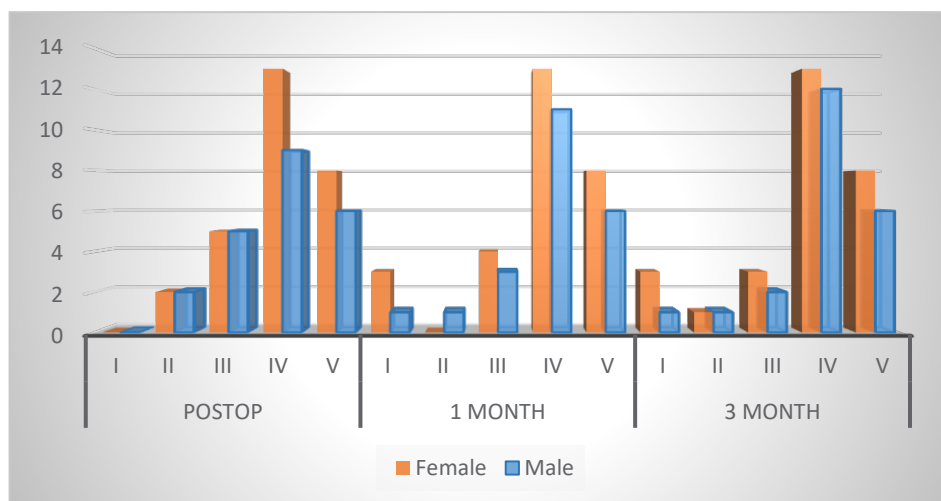


Figure 2. The outcome based on the Glasgow Outcome Scale (GOS), graded from I to V



II and III are termed as dependent, IV and V as independent. A score at three months is taken as final in this study.

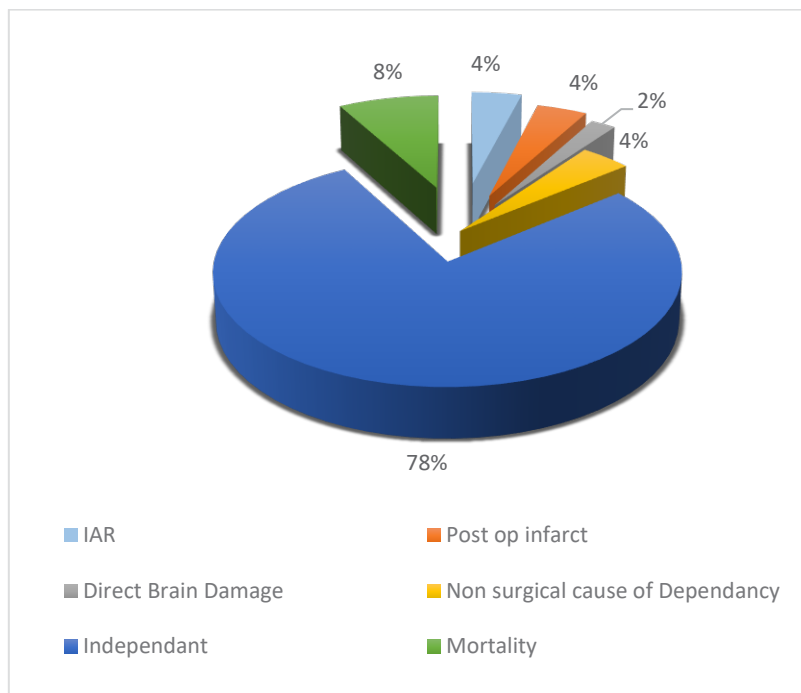


Figure 3. Breakdown of surgical and non-surgical causes of dependency

an 11.1% poor outcome among 200 patients who underwent microsurgical clipping. Out of them, 9.6% were dependant at three months follow-up [10] (as depicted in Figure 4 and Figure 5).

Out of seven, five patients (10%) were rendered dependant due to operative insult. Two patients suffered intraoperative aneurysm rupture, and two patients had post-op infarct while one patient had direct brain damage due to retractor.

Intraoperative Rupture (IAR) is defined as rupture which occurs before securing the parent arteries or the neck of the aneurysm and is out of control, at least temporarily. It can occur anytime between the induction of anesthesia and the final clipping. IAR is the most dramatic and potentially devastating complication of aneurysm surgery. In our series, 4% (2/50) ruptured intraoperatively while Butlers et al. reported 3.5%, a result comparable to ours [10]. Lawton reported a 6.6% rupture rate when reviewed the effect of neurosurgeon's experience on the outcome of IAR [18]. Overall, the rupture rates during surgery vary from 6% to 11.7% in

Table 1. Comparing with relevant subgroups in other studies

Variables	ISAT [13]	IHAST [14]	Wester [16]	Mclaughlin [17]	Butlers [10]	Current	
Group characteristics	Anterior circulation (%)	97.3	95	96.6	95.7	96.5	100
	Good grade (%)	87.9	95	48.7	52.2	100	100
Outcome	IAR (%)	UNK ^a	12.5	3.6	5.9	3.5	4
	Infarct (%)	UNK ^a	11.1	1.6	UNK ^d	UNK ^d	6
	Dependant (%)	18.5 ^b	16.8	17.9	18.0	9.6	14
	Operative mortality (%)	UNK ^c	12	UNK ^c	0.7	1.5	6

ISAT: International Subarachnoid Aneurysm Trial; IHAST: Intraoperative Hypothermia for Aneurysm Surgery Trial; IAR: Intraoperative Rupture; UNK: Unknown; ^aBreakdown of surgical complications is not available; ^bAdjusted for good grade patients; IAR: Intraoperative Rupture; UNK: Unknown; ^cNumber of deaths due to surgical complications has not been mentioned; ^dAmong vascular complications, no specific mention of the infarct is found.



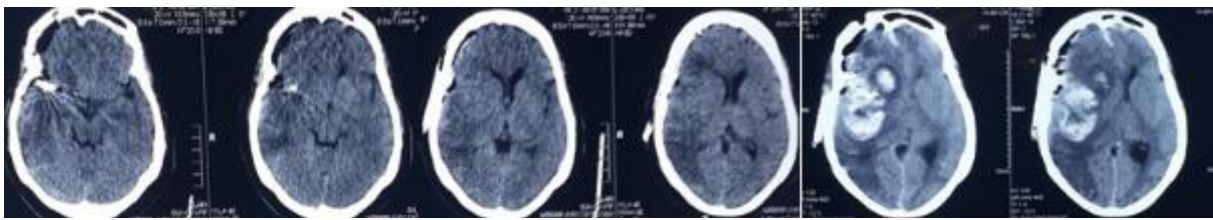


Figure 4. Post-op CT of a 50-year-old female following MCA bifurcation aneurysm clipping, depicting early infarct progressing to hemorrhagic one leading to the dismal outcome

the literature [19-21]. It is clear that although IAR is an unavoidable danger during aneurysm surgery, adequate exposure, sharp dissection, proximal control, and use of temporary clips are the primary means of avoiding intraoperative rupture [12, 20, 21]. Both cases in our series were MCA aneurysms, and rupture occurred in the predissection phase. We employed a double suction technique and temporary clips to rescue.

The other cause of the vascular complications of surgery is cerebral infarction. The post-op infarct rate was 6% (3/50) in our series. One such case is illustrated in Figure 2. Kraysenbuhl et al. reported a post-operative infarct rate of 27% in ruptured aneurysms [22]. Causes of early post-op infarct have been reported due to operative insult, whether permanent clipping of the parent or perforating artery or prolonged (>10 minutes) temporary clipping [23]. Infarcts on the first post-operative day had a worse prognosis than those caused by delayed ischemia [24].

Two patients (4%) in the earlier part of the study suffered direct brain damage due to the use of rigid retractors. Following this, we focused on surgical adjuncts like skull base bony removal, dynamic retraction, and CSF drainage before or after opening dura and found it helpful to minimize or, in some cases, eliminate brain retraction. Butlers et al. reported 1% incidence in their series [10].

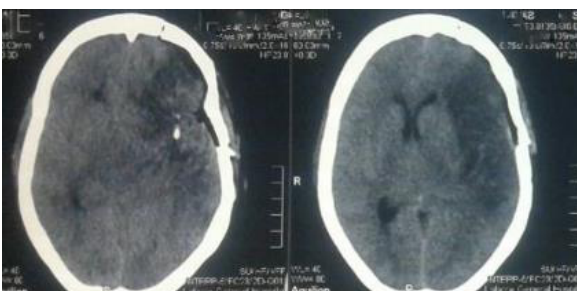

Figure 5. Post-op CT of a 45-year-old male following MCA bifurcation clipping but rendered dependent due to MCA infarct

Two patients (4%) had dependency due to non-operative insult. One had post-op acute hydrocephalus and multiple subcortical infarcts, while the other suffered an accidental fall from bed resulting in acute subdural hematoma.

The overall incidence of hydrocephalus in our series was 8% (4/50). All patients had to communicate hydrocephalus. Ventriculo-Peritoneal (VP) shunt was done in three cases, while one required External Ventricular Drain (EVD). Two patients proceeded with a favorable outcome while one became dependant, and one died. Lin et al. showed that less than 10% of patients required shunting post-operatively [25]. The incidence of hydrocephalus was higher for patients with anterior communicating artery aneurysm than for patients with aneurysms at other locations [26].

5. Conclusion

Patients without neurological deficit pre-operatively still suffer unfavorable outcomes mainly due to operative insults. Vascular injuries remain the main cause of morbidity-producing dependency. Therefore, all surgical techniques must minimize the risk to vessels, both during dissection and at clip placement.

Ethical Considerations

Compliance with ethical guidelines

Informed consent was taken from all participants. This study was approved by IRB, Lahore General Hospital/ Post Graduate Medical Institute, Lahore (IRB No.: 00-03-21). The study protocol conforms to the ethical guidelines of the 1975 Declaration of Helsinki (<http://www.wma.net/en/30publications/10policies/b3/index.html>).

Funding

This research did not receive any grant from funding agencies in the public, commercial, or non-profit sectors.

Authors' contributions

Study conception and design: Sundus Ali, Fauzia Sajjad, and Akmal Azeemi; Data collection: Sundus Ali and Fauzia Sajjad; Data analysis and interpretation: Sundus Ali, Fauzia Sajjad, and Asif Shabbir; Drafting the article: Sundus Ali and Fauzia Sajjad; Critically revising the article: Sundus Ali and Akmal Azeemi; Reviewing submitted version of manuscript, approving the final version of the manuscript: All authors.

Conflict of interest

The authors declared no conflict of interest.

References

- [1] Greenberg MS. Introduction to SAH. In: Greenberg MS, editoe. Handbook of Neurosurgery. 7th ed. New York: Thieme; 2010. pp. 1035-70. <https://books.google.com/books?id=0TC9Cns4Qz8C&dq>
- [2] Grieve JP, Kitchen ND. Aneurysmal subarachnoid hemorrhage. In: Moore AJ, Newell DW, editors. Neurosurgery: Principles and Practice. London: Springer; 2005. pp. 315-27 [DOI:10.1007/1-84628-051-6_18]
- [3] Becske T. Subarachnoid hemorrhage [Internet]. 2018 [Updated 2018 December 7]. Available from: <http://emedicine.medscape.com/article/1164341-overview#a0156>
- [4] Sekhar LN, Heros RC. Origin, growth, and rupture of saccular aneurysms: A review. Neurosurgery. 1988; 8(2):248-60. [DOI:10.1227/00006123-198102000-00020] [PMID]
- [5] Raftopoulos C. Surgical management of intracranial aneurysms of the anterior circulation. In: Sindou M, editor. Practical Handbook of Neurosurgery. Berlin: Springer; 2009. pp. 257-69. [DOI:10.1007/978-3-211-84820-3_17]
- [6] Bederson JB, Connolly Jr ES, Batjer HH, Dacey RG, Dion JE, Diringer MN, et al. Guidelines for the management of aneurysmal subarachnoid hemorrhage: A statement for healthcare professionals from a special writing group of the Stroke Council, American Heart Association. Stroke 2009; 40(3):994-1025. [DOI:10.1161/STROKEAHA.108.191395] [PMID]
- [7] Rosengart AJ, Schultheiss KE, Tolentino J, Macdonald RL. Prognostic factors for outcome in patients with aneurysmal subarachnoid hemorrhage. Stroke. 2007; 38(8):2315-21. [DOI:10.1161/STROKEAHA.107.484360] [PMID]
- [8] Bakker NA, Metzemaekers JDM, Goren RJM, Mooij JJA, Van Dijk JMC, et al. International subarachnoid aneurysm trial 2009: Endovascular coiling of ruptured intracranial aneurysms has no significant advantage over neurosurgical clipping. Neurosurgery. 2010; 66(5):961-2. [DOI:10.1227/01.NEU.0000368152.67151.73] [PMID]
- [9] Tahir MZ, Enam SA, Ali RP, Bhatti A, ul Haq T. Cost-effectiveness of Clipping Versus Coiling of intracranial aneurysms of the SAH in a developing country— a prospective study. Surgical Neurology. 2009; 72(4):355-60. [DOI:10.1016/j.surneu.2008.11.003] [PMID]
- [10] Bulters DO, Santarius T, Chia HL, Parker RA, Trivedi R, Kirkpatrick PJ, et al. Causes of neurological deficits following clipping of 200 consecutive ruptured aneurysms in patients with good-grade aneurysmal subarachnoid haemorrhage. Acta Neurochirurgica. 2011; 153(2):295-303. [DOI:10.1007/s00701-010-0896-y] [PMID]
- [11] Rahmanian A, Derakhshan N, Eisaei M, Tanideh N, Koohi-Hosseiniabadi O. Microsurgical training curriculum for neurosurgery residents in Southern Iran. Iranian Journal of Neurosurgery. 2020; 6(3):165-8. [DOI:10.32598/irjns.6.3.9]
- [12] Kassel NF, Torner JC, Haley Jr EC, Jane JA, Adams HP, Kongable GL. The international cooperative study on the timing of aneurysm surgery: Part 1. Overall management results. Journal of Neurosurgery. 1990; 73(1):18-36. [DOI:10.3171/jns.1990.73.1.0018] [PMID]
- [13] Molyneux A, Kerr R, Stratton I, Sandercock P, Clarke M, Shrimpton J, et al. International Subarachnoid Aneurysm Trial (ISAT) of neurosurgical clipping versus endovascular coiling in 2143 patients with ruptured intracranial aneurysms: A randomised trial. Lancet. 2002; 360(9342):1267-74. [DOI:10.1016/S0140-6736(02)11314-6]
- [14] Todd MM, Hindman BJ, Clarke WR, Torner JC, Intraoperative Hypothermia for Aneurysm Surgery Trial (IHAST) Investigators. Mild intraoperative hypothermia during surgery for intracranial aneurysm. The New England Journal of Medicine. 2005; 352(2):135-45. [DOI:10.1056/NEJMoa040975] [PMID]
- [15] Alijani B, Emamhadi M, Yosefzadeh Chabok S, Jafari S, Naseri A. Surgical protocol and outcome of 60 cases with intracranial aneurysm. Iranian Journal of Neurosurgery. 2018; 4(2):75-82. [DOI:10.32598/irjns.4.2.75]
- [16] Wester K. Lessons learned by personal failures in aneurysm surgery: What went wrong, and why? Acta Neurochirurgica. 2009; 151(9):1013-24. [DOI:10.1007/s00701-009-0452-9] [PMID]
- [17] McLaughlin N, Bojanowski MW. Early surgery-related complications after aneurysm clip placement: An analysis of causes and patient outcomes. Journal of Neurosurgery. 2004; 101(4):600-6. [DOI:10.3171/jns.2004.101.4.0600] [PMID]
- [18] Lawton MT, Du R. Effect of the neurosurgeon's surgical experience on outcomes from intraoperative aneurysmal rupture. Neurosurgery. 2005; 57(1):9-15. [DOI:10.1227/01.NEU.0000163082.20941.EF] [PMID]
- [19] Houkin K, Kuroda S, Takahashi A, Takikawa S, Ishikawa T, Yoshimoto T, et al. Intra-operative premature rupture of the cerebral aneurysms. Analysis of the causes and management. Acta Neurochirurgica. 1999; 141(12):1255-63. [DOI:10.1007/s007010050428] [PMID]
- [20] Kheireddin AS, Filatov IM, Belousova OB, Pilipenko IV, Zolotukhin SP, Sazonov IA, et al. [Intraoperative rupture of cerebral aneurysm: Incidence and risk factors (Russian)]. Zhurnal Voprosy Neurokhirurgii Imeni N. N. Burdenko. 2007; (4):33-8. [PMID]



- [21] Leipzig TJ, Morgan J, Horner TG, Payner T, Redelman K, Johnson CS. Analysis of intraoperative rupture in the surgical treatment of 1694 saccular aneurysms. *Neurosurgery*. 2005; 56(3):455-68. [DOI:10.1227/01.NEU.0000154697.75300.C2] [PMID]
- [22] Krayenbühl N, Erdem E, Oinas M, Krisht AF. Symptomatic and silent ischemia associated with microsurgical clipping of intracranial aneurysms evaluation with diffusion-weighted MRI. *Stroke* 2009; 40(1):129-33. [DOI:10.1161/STROKEA-HA.108.524777] [PMID]
- [23] Juvela S, Siironen J, Varis J, Poussa K, Porras M. Risk factors for ischemic lesions following aneurysmal subarachnoid hemorrhage. *Journal of Neurosurgery*. 2005; 102(2):194-201. [DOI:10.3171/jns.2005.102.2.0194] [PMID]
- [24] Siironen J, Porras M, Varis J, Poussa K, Hernesniemi J, Juvela S. Early ischemic lesion on computed tomography: Predictor of poor outcome among survivors of aneurysmal subarachnoid hemorrhage. *Journal of Neurosurgery*. 2007; 107(6):1074-9. [DOI:10.3171/JNS-07/12/1074] [PMID]
- [25] Lin CL, Kwan AL, Howng SL. Acute hydrocephalus and chronic hydrocephalus with the need of postoperative shunting after aneurysmal subarachnoid hemorrhage. *The Kaohsiung Journal of Medical Sciences*. 1999; 15(3):137-45. [PMID]
- [26] Yasargil MG. Anterior cerebral and anterior communicating artery aneurysms. In: Yasargil MG, editor. *Microneurosurgery: Clinical Considerations, Surgery of the Intracranial Aneurysms and Results*. Vol II. New York: Thieme; 1984. https://books.google.com/books?id=_5wdWjqM3xcC&dq