

## Case Series:

# Non-traumatic Causes of Brown-sequard Syndrome: A Case Series and Clinical Update With Systematic Review



Vaner Köksal<sup>1\*</sup>, Mahmoud Osama<sup>2</sup>, Mohammed Ali Alvi<sup>3</sup>

1. Department of Neurosurgery, Samsun Health Practices and Research Center, University of Samsun, Samsun, Turkey
2. Faculty of Medicine, Zagazig University, Zagazig, Egypt
3. Mayo Clinic Neuro-Informatics Laboratory, Mayo Clinic, Rochester, Minnesota, USA

Use your device to scan  
and read the article online



**Citation:** Köksal V, Osama M, Alvi MA. Non-traumatic Causes of Brown-sequard Syndrome: A Case Series and Clinical Update With Systematic Review. *Iran J Neurosurg.* 2021; 7(2):92-106. <http://dx.doi.org/10.32598/irjns.7.2.3>

 <http://dx.doi.org/10.32598/irjns.7.2.3>



### Article info:

**Received:** 10 Jan 2021

**Accepted:** 06 Mar 2021

**Available Online:** 01 Apr 2021

### Keywords:

Brown-sequard syndrome,  
Spinal cord, Spinal epidural  
hematoma, Spinal stenosis,  
Disc herniation

## ABSTRACT

**Background and Importance:** Brown-Sequard Syndrome (BSS) is a rare neurological condition resulting from a hemisection injury to or unilateral compression on the spinal cord. The common causes of BSS that are amenable to be treated surgically can be divided into traumatic and non-traumatic injuries. Traumatic injuries are often reported as the main cause of BSS. However, non-traumatic injuries of the spinal cord are more seen in recent years. This study aims to classify and update surgically treatable causes of BSS.

**Case Presentation:** Retrospective data of 17 patients operated for BSS between 2008 and 2020 were included. The long-term outcomes of these patients were evaluated. In addition, a comprehensive search in PubMed, Scopus, and CINAHL was conducted for the retrieval of all relevant studies.

**Results:** Magnetic Resonance Image (MRI) of our patients revealed Cervical Disc Herniation (CDH), spinal canal stenosis with cervical spondylosis, epidural hematoma, and ossification of the posterior longitudinal ligament. The postoperative outcomes of our cases ranged from partial to complete recovery. While the patients with acute epidural hemorrhage achieved complete recovery after surgery, neurological deficits in the other patients, especially those with severe cervical spinal canal stenosis, persisted despite adequate surgical decompression. The systematic literature review revealed that CDH is the most common non-traumatic surgically treatable cause of BSS, followed by spinal cord herniation and spinal epidural hematoma.

**Conclusion:** Non-traumatic injuries of the spinal cord accompanied by narrowed cervical spinal canal pathologies are prominent surgically treatable causes of BSS. Contrary to the definition made 100 years ago, BSS can occur spontaneously due to underlying pathologies rather than major traumatic injuries.

### \*Corresponding Author:

**Vaner Köksal, MD.**

**Address:** Department of Neurosurgery, Samsun Health Practices and Research Center, University of Samsun, Samsun, Turkey

**Tel:** +90 (505) 5212361

**E-mail:** vanerkoksal@hotmail.com



## Highlights

- An update on the Brown-Sequard Syndrome (BSS) described a century ago is considered.
- Contrary to popular belief, major traumas are not the most common cause of BSS today.

## Plain Language Summary

In our aging process, we can usually notice the change in our neck spine too late. In particular, it may not give any symptoms due to long-term compression of the spinal cord tissue. As with lumbar hernia, complaints of numbness in the hands or arms may occur first without experiencing pain complaints. For these reasons, the patient may not have any complaints until the neck spinal cord is compressed. Challenging physical activities in our daily life can easily affect the previously narrowed cervical spine, and a severe clinical picture may begin. This article has tried to emphasize the typical—characteristics of such patients.

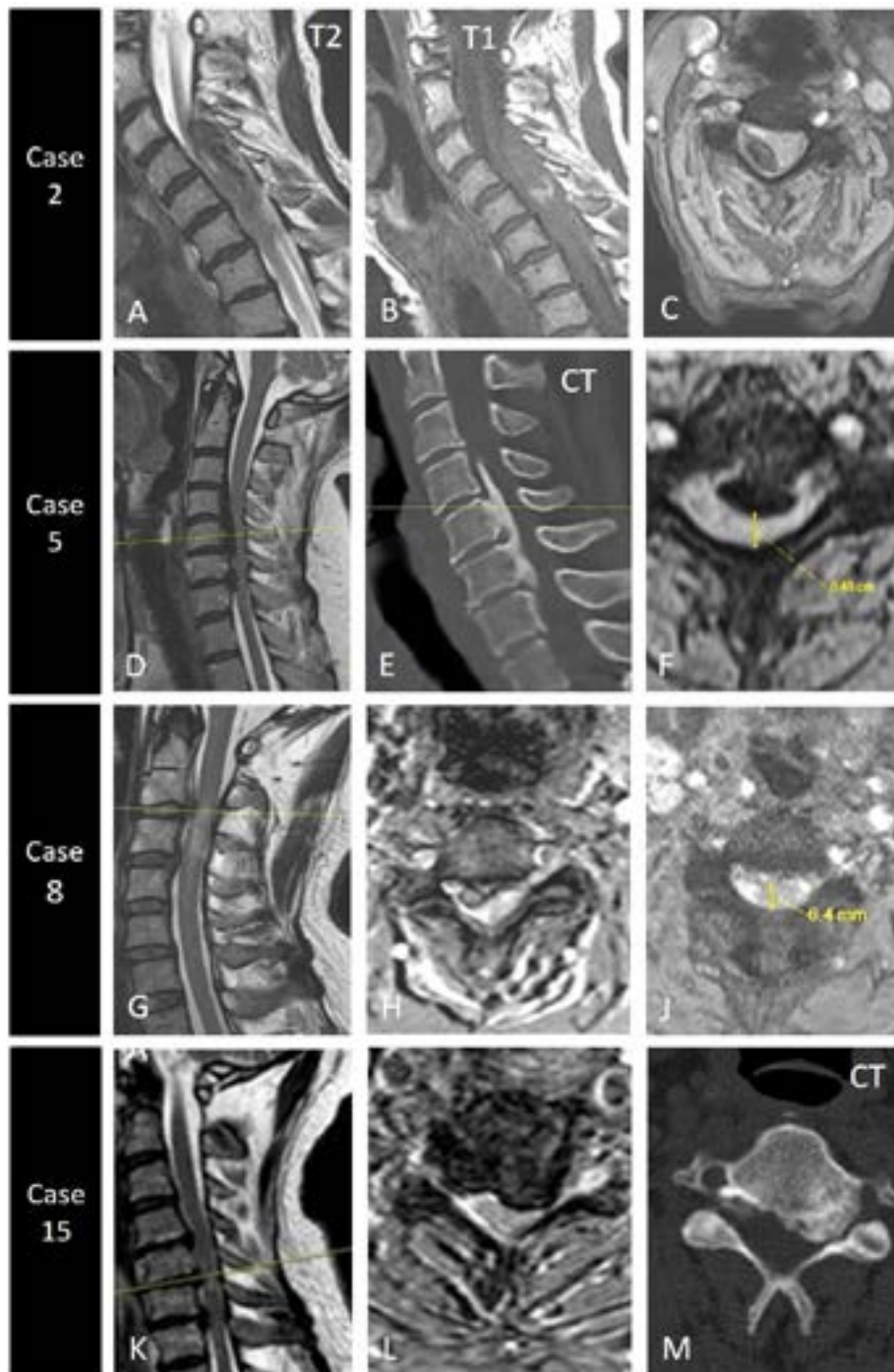
### 1. Background and Importance

**B**rown-Sequard Syndrome (BSS), first described in 1846 by Charles-Edouard Brown-Séquard, is a rare neurological syndrome that evolves due to a hemisection injury to or unilateral compression on the spinal cord. As a result of interruption of both ascending spinothalamic and descending corticospinal tracts, a constellation of symptoms and signs appears, including ipsilateral loss of motor function (presenting as hemiplegia or hemiparesis), proprioception, vibration, and fine touch sensation, and contralateral loss of temperature and pain sensation. In addition, there is an ipsilateral loss of all sensations and motor functions at the level of the lesion [1]. Etiologies of BSS include surgically treatable (traumatic and non-traumatic injuries) and medically treatable causes. Traumatic injuries were often reported as the main surgical causes of BSS. However, non-traumatic etiologies have been more frequent in recent years, as reported in the literature. Surgically treatable non-traumatic etiologies of BSS include Cervical intervertebral Disc Herniation (CiDH), Spinal Cord Herniation (SCH), spinal canal stenosis with cervical spondylosis, primary and secondary tumors, spinal stenosis, Ossified Posterior Longitudinal Ligament (OPLL), intramedullary cystic diseases, some infectious diseases, such as spinal cysticercosis [2, 3] and syphilitic gumma [4], as well as rare conditions, such as cervical synovial cyst [5], and Kirschner wire after clavicular osteosynthesis [6]. Early surgical interventions performed for these pathologies have a great impact on the prognosis of patients. Herein, we present a case series of surgically treatable non-traumatic causes of BSS along with a systematic review of the literature. We aimed to raise awareness that there are

more non-traumatic causes of BSS. This work has been reported with preferred items for systematic review and meta-analysis PRISMA guidelines which is an evidence-based minimum set of items for reporting in systematic reviews and meta-analyses [7].

### 2. Case Presentation

Seventeen patients were admitted to our clinic in the Department of Neurosurgery, University of Health Sciences-Samsun Health Practices and Research Center, Samsun, Turkey, between 2008 and 2020. They presented the aforementioned clinical picture of BSS. The patients consisted of 12 men (70.6%) and 5 women (29.4%). The age of the patients ranged from 48 to 85 years (mean= 65 years). The etiologies of BSS in these patients as revealed by cervical Magnetic Resonance Image (MRI) were as follows: 6 cases were produced by CDH alone (35.3%), 5 patients by OPLL (29.4%), 1 patient by spinal canal stenosis with cervical spondylosis (5.9%), 3 patients by epidural hematoma (17.6%), and 2 patients by cervical spinal stenosis (11.8%) (Table 1; Figure 1). All patients with disc herniation and spinal canal stenosis with cervical spondylosis denied any history of major traumas. In most patients, the symptoms were observed during their daily activities. Few of them had a history of minor traumas in the form of falling at the same level [8]. Written consent was taken from the patients for performing the appropriate surgical intervention. According to the diagnosis, the patients underwent the following surgical interventions: anterior cervical discectomy for CDH, anterior oblique corpectomy for OPLL, posterior hemilaminectomy for epidural hematoma, and total posterior laminectomy for spinal stenosis and some cases of CDH (Table 1). In addition to



**Figure 1.** **Case 2:** A: T2 sagittal MRI shows a hypointense lesion occupying a space in the spinal canal between C5-7; Section B: T1 sagittal MRI shows a hyperintense intradural lesion indicating presence of bleeding (epidural hematoma); C: T2 axial MRI displays a hypointense lesion for a typical epidural hematoma. **Case 5:** D: T2 sagittal MRI demonstrates a narrow spinal canal and hypertrophied Posterior Longitudinal Ligament (PLL); E: Computed Tomography (CT) section shows OPLL between C5-7; F: T2 axial MRI shows severe stenosis in the left half of the cervical spinal canal; **Case 8:** G: T2 sagittal MRI shows a hyperintense lesion for acute C2-3 Cervical intervertebral Disc Herniation (CIDH) and edema in the Spinal Cord (SC); H: T2 axial MRI demonstrates CIDH in front of the right foramen; J: Narrow spinal canal diameter in the right side C5-6. **Case 15:** K: T2 sagittal MRI shows narrowing and myelomalacia in the SC; L: CIDH or OPLL filling the left side of the spinal canal; M: A CT section shows a calcified CIDH. BSS occurred in these 4 patients without major trauma. The patients were presented to the emergency room with BSS after a daily activity, especially case 5 and 15. It is understood that the anatomical change narrows the cervical spinal canal in the chronic processes. The spinal tracts tolerate until the last moment. In all cases, there were no apparent painful radicular complaints in their background.



**Table 1.** The demographic data of our 17 patients

Case No.	Patient (Age/Sex)	Diagnosis	Surgical Intervention	Outcome
1	57/M	C3/C4/C5 cervical spondylosis and stenosis	Posterior total laminectomy	IR
2	85/F	C4/C5/C6 Rt-sided epidural hematoma	Posterior hemilaminectomy	IR
3	56/M	C7/T1/T2 epidural hematoma	Posterior hemilaminectomy	IR
4	60/M	C3/C4 acute Lt-sided CDH	Anterior cervical discectomy	CR
5	67/M	C4/C5/C6 OPLL + stenosis	Anterior oblique corpectomy	IR
6	54/F	C4/C5 acute Lt-sided CDH	Anterior cervical discectomy	CR
7	81/M	C5/C6 calcified CHD	Anterior cervical discectomy	IR
8	64/M	C2/C3 acute Rt-sided CDH	Anterior cervical discectomy	CR
9	78/F	C6/C7 - T1 epidural hematoma	Posterior hemilaminectomy	CR
10	48/F	C5/C6 acute CDH	Anterior cervical discectomy	IR
11	59/M	C4/C5/C6 OPLL + lateral stenosis	Anterior oblique corpectomy	IR
12	69/M	C3/C4/C5/C6 OPLL + lateral stenosis	Anterior oblique corpectomy	IR
13	70/M	C3/C4/C5 calcified CDH + OPLL	Posterior total laminectomy	IR
14	68/M	C5/C6 acute CDH	Anterior cervical discectomy	IR
15	67/F	C5/C6/C7 calcified disc + stenosis	Anterior cervical discectomy	IR
16	58/M	C4/C5/C6 CDH + spinal stenosis	Posterior total laminectomy	IR



CR: Complete Recovery; IR: Incomplete Recovery; M: Male; F: Female

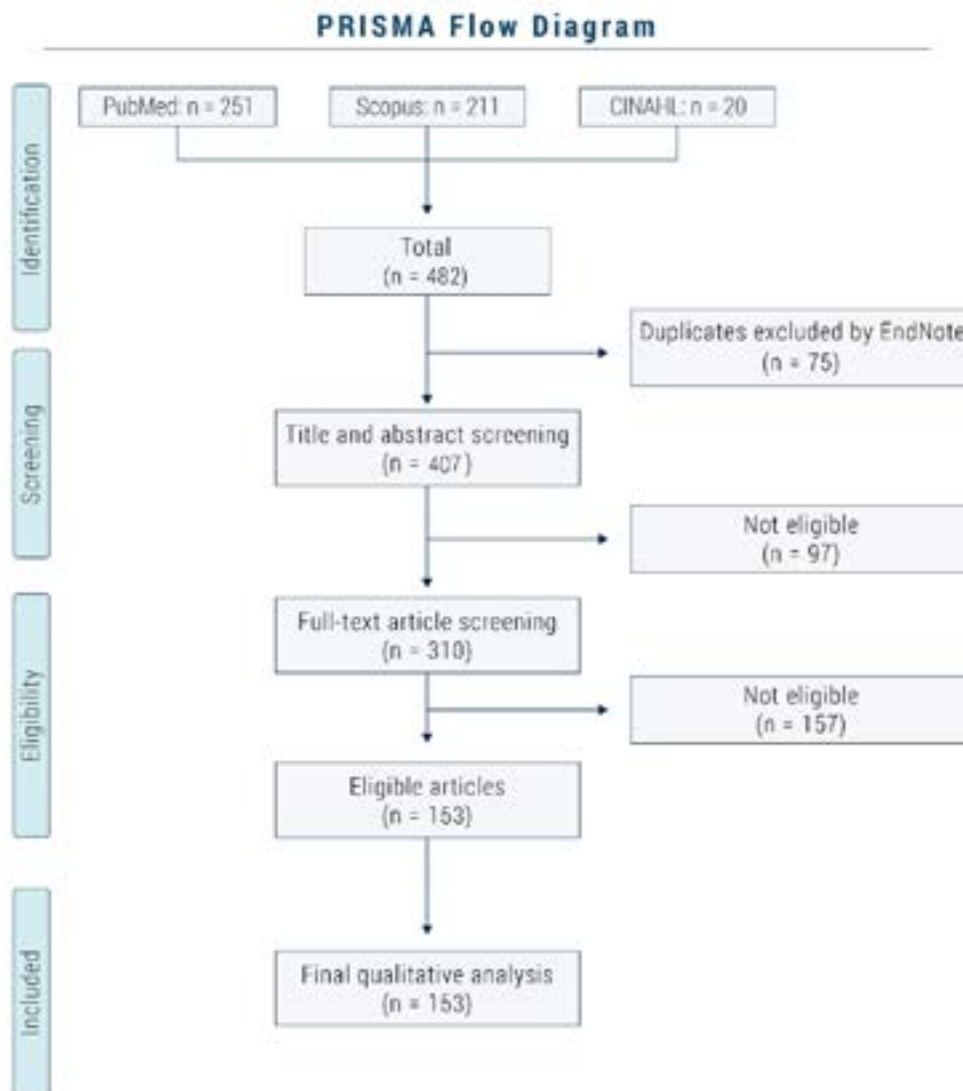
our cases, we systematically performed a comprehensive literature search in PubMed, Scopus, and CINAHL for retrieval of all relevant case series and case reports that reported surgically-treatable causes of BSS with the way of management and postoperative outcome for the past 20 years according to PRISMA guidelines [9], using the following keywords: “Brown-Sequard”, “Brown-Séquard”, “surgery”, “surgical intervention”, “operation”, “surgical approach”, “neurosurgery”, “case report”, “report”, and “case series”. The search results were checked for duplication, then underwent screening.

### 3. Results

Our patients were followed up for 2 to 3 years; their long-term outcomes post-operatively ranged from partial to complete recovery, as shown in Table 1. Four cases completely recovered, whereas 13 showed incomplete recovery in the form of sensory and motor deficits. In our cases, complete recovery was mainly associated with pa-

tients with acute CDH and epidural hematoma, whereas incomplete recovery was mainly associated with OPLL, lateral stenosis, calcified CDH, and spinal stenosis. Moreover, our patients’ outcomes showed that late surgical treatment after the occurrence of BSS did not have enough benefit, and poor neurological conditions persisted. The comprehensive search in the aforementioned databases yielded 482 case series and reports. Of these, 75 articles were excluded for deduplication, 97 articles because of title and abstract screening, and 157 articles because of full-text screening for reporting cases treated medically and conservatively. Finally, 153 articles were included for qualitative synthesis as demonstrated by the PRISMA flow chart (Figure 2) for estimating the frequency of each surgically treatable cause of BSS for the past 20 years. Of these 153 articles, 52 reported major traumatic injuries, and 101 reported micro- or non-traumatic injuries (Table 2). CDH was the most common surgically treatable non-traumatic cause for the past 20 years (frequency=28), followed by SCH (frequency=27),





**Figure 2.** PRISMA flow chart



micro- or non-traumatic epidural hematoma (frequency=14), and Intramedullary Spinal Cord Metastasis (ISCM) (frequency=6) (Figure 3, Table 2). Males were affected more often than females (males=59 cases; females=42 cases). The ages of the patients reported in these studies ranged from 7 to 86 years (mean=50 years; 95%CI: 47 to 53) (Figure 4, Table 2).

#### 4. Discussion

##### Surgically treatable etiologies of BSS

BSS may occur due to spontaneous non-traumatic causes, major traumatic injuries, or some infectious diseases. Many of these causes require conservative treatment, such as medical or rehabilitation therapy, and the others require surgical intervention. In recent years, BSS frequently occurs due to micro- or non-traumatic inju-

ries, such as CDH, SCH, epidural hematoma, OPLL, cervical canal stenosis, and benign and metastatic tumors, as noticed in our cases. We classified surgically treatable causes of BSS into two categories based on our case series and a comprehensive search in the literature: major traumatic injuries and micro- or non-traumatic injuries (Figure 5). Major traumatic injuries result from direct injuries to the spinal cord, including stab injuries (accounting for 26% of spinal cord injuries) [10], blunt traumas [11], gunshot [12], penetrating glass injuries [13], cervical vertebral dislocation, acute traumatic cervical disc herniation, and traumatic vertebral fracture. Major traumatic injuries are usually accompanied by Horner’s syndrome when traumas involve the cervical region [14] and usually require urgent surgical intervention for spinal cord decompression, removal of foreign objects, repair of the affected area, and preservation of the spinal



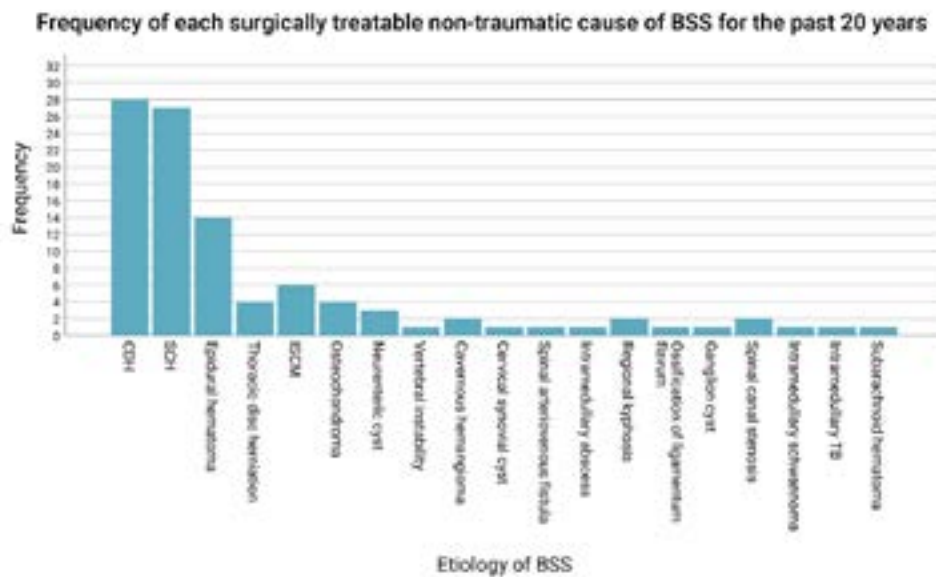


Figure 3. Frequency of each surgically treatable non-traumatic surgical cause since 2000



cord in its correct position. On the other hand, micro- or non-traumatic injuries result from trivial traumas, physical activities, or hyperextension [8]. The definitive diagnostic tool for such cases is MRI, which demonstrates the etiology and extension of the lesion. Micro- or non-traumatic injuries have been reported more frequently than before for the past 20 years. Based on the results from 153 case reports, there are 19 different surgically treatable non-traumatic etiologies that can result in BSS. CDH constitutes most of these causes as found in our cases [15, 16], followed by SCH, spinal epidural

hematoma, ISCM, and benign tumors (Figure 5). CDH occurs mainly due to minor traumatic events (the main cause of herniation) or develop progressively over a long period of time [17]. In addition to disc herniation, SCH has been also reported as a surgically treatable non-traumatic cause of BSS occurring as a result of pre-existing dural defects, unrecognized traumatic events, surgical intervention (iatrogenically), or rarely, congenital defects. However, this clinical entity was not present in our patients. Spinal epidural hematoma comes in the third place among non-traumatic causes of BSS. It may

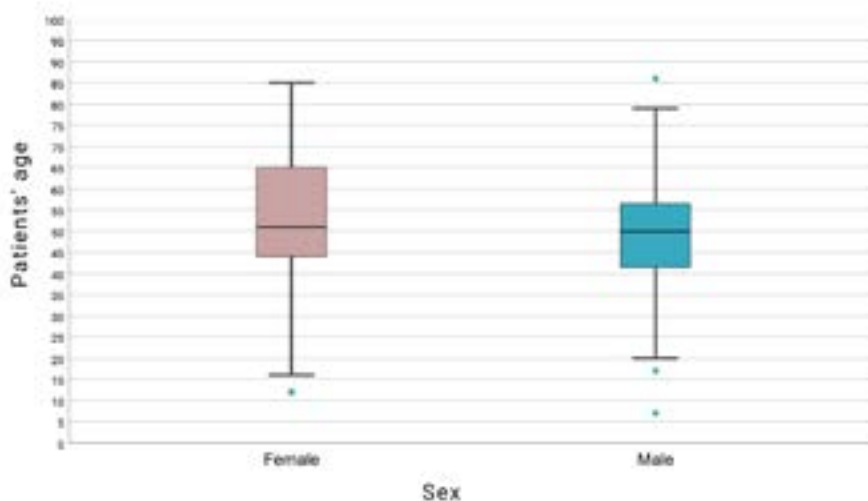
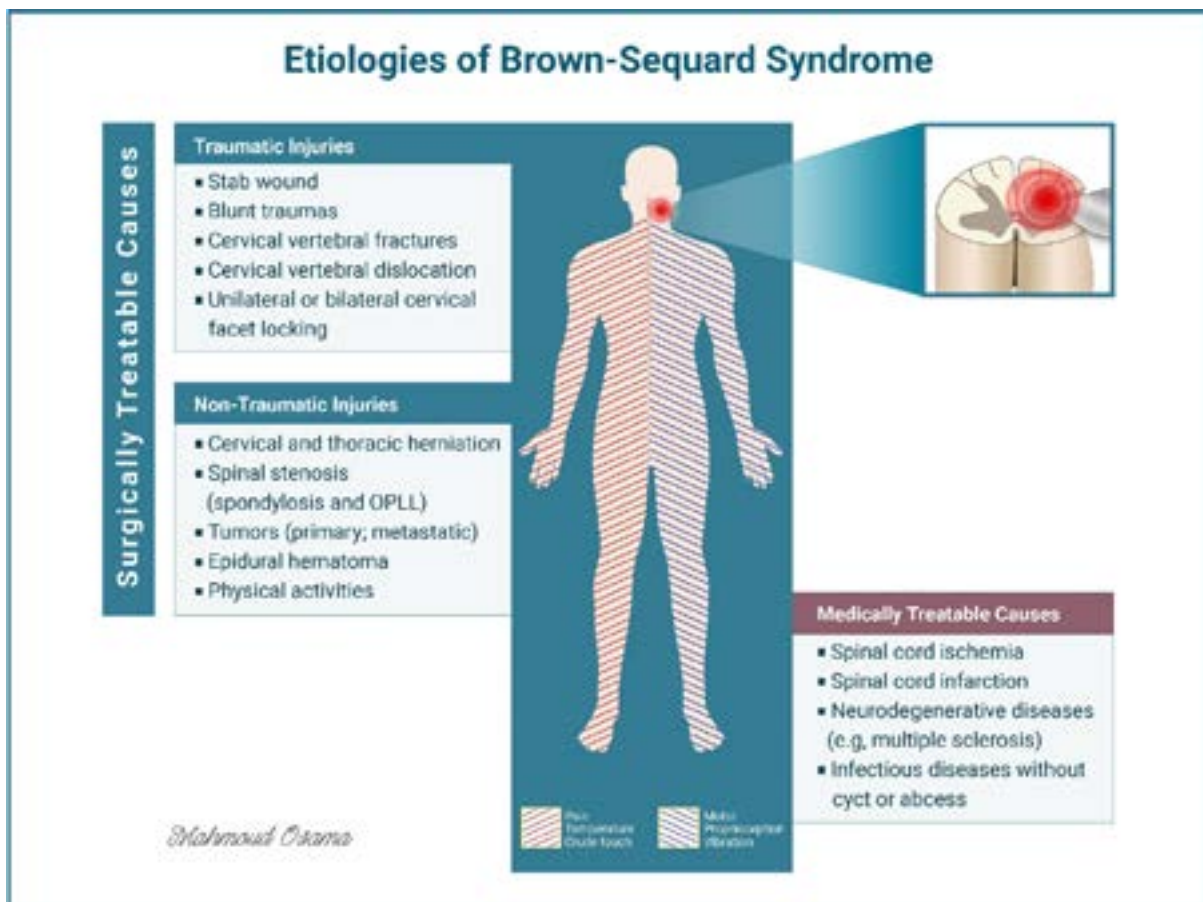


Figure 4. Box plot demonstrating the ages of each sex of the included studies for the past 20 years





**Figure 5.** This figure demonstrates surgically treatable and medically treatable etiologies of BSS



occur spontaneously or evolve secondarily due to minor traumas, vascular malformation, hemorrhagic diseases [18], anticoagulant therapy, hypertension, or pregnancy. The fourth most common non-traumatic cause of BSS is tumors, which can be classified into primary and metastatic. Primary tumors include cavernous hemangioma, schwannoma, meningioma and osteochondroma [19, 20]. Secondary metastasis from remote sites includes malignant mesothelioma [21], colonic carcinoma [22], squamous cell carcinoma of the maxillary sinus [23], and gastric adenocarcinoma [24], leading to intramedullary spinal cord metastasis. Spinal canal stenosis with cervical spondylosis and OPLL are forms of degenerative conditions that develop over the years and affect the vertebral column and surrounding ligaments [14]. Cervical spinal stenosis is the commonest form of spinal canal stenosis developing mainly from spinal canal stenosis with cervical spondylosis and OPLL and therefore requires surgical intervention for dilatation of the spinal canal and release of any compression on the spinal cord. BSS is produced by these conditions mainly due to compression on the spinal cord by bone spurs and degenerated intervertebral disc herniation [25]. Overlap

between some spinal canal pathologies is common in real life such as CDH, spinal canal stenosis with cervical spondylosis, and OPLL. Time of surgical intervention plays a vital role and has a great impact on the postoperative outcome; the earlier the intervention, the better the prognoses and postoperative outcomes. Therefore, most non-traumatic injuries have good prognosis after early surgical interventions and patients achieve complete recovery, except for ISCM and calcified CDH that carry moderate to bad prognosis [21, 26]. Other surgically treatable non-traumatic causes of BSS that have been reported rarely include neurenteric cyst, cervical synovial cyst, ganglion cyst, spinal arteriovenous fistula, intramedullary abscess, intramedullary tuberculosis, and regional kyphosis (Figure 3).

#### Overview of medically treatable etiologies of BSS

Non-surgical causes of BSS are treated conservatively without a need for surgical intervention. They include spinal cord ischemia and infarction, many infectious diseases, such as varicella virus infection, treated with acyclovir and steroid [27, 28], and neurodegenerative dis-

**Table 2.** The non-traumatic surgical causes of BSS reported for the past 20 years since 2002

Study	Year	Patient (Age/Sex)	Diagnosis	Surgical Approach	Outcome
Ding et al. [33]	2019	49/M	C6/C7 Spontaneous CDH	C6/7 discectomy; C6 corpectomy	CR
Neale et al. [34]	2019	61/F	T4 ISCH	T3/T4 laminectomy and medial facetectomy	IR
Gomez et al. [35]	2019	20/F	T4/T5 ISCH	Posterior approach	IR
Tyagi et al. [36]	2019	72/M	T4/T5 ISCH	T3 to T5 laminectomy	IR
Mathais el al. [37]	2018	78/M	C4 to T5 SSEH, prevailing in C5-C6	C3 to C7 Posterior cervical laminectomy	CR
Patel et al. [38]	2018	51/M	C3 to C5 SEEH	bilateral spinous process C4 laminectomy; Rt C3 and C5 hemilaminectomy	IR
Zeng et al. [39]	2018	57/M	C4/C5 Spontaneous CDH; C5/C6/C7 spondylosis	Subtotal ACCF	CR
Du et al. [40]	2018	16/F	T3/T4 intraspinal thoracic osteochondroma	Transpedicular approach + tumour excision	CR
Kida et al. [41]	2018	67/F	C3/C4 recurrent cervical neurenteric cyst	Anterior approach	CR
Ghali et al. [42]	2018	66/F	T5/T6 ISCH	T5/T6 laminectomy	CR
O'Neill et al. [43]	2017	49/F	C4/C5 ISCM from thyroid carcinoma	C4/C5 cervical laminoplasty + resection of the ISCM	CR
Lee et al. [44]	2017	50/F	C1/C2 instability (falling from a ladder)	C1/C2 arthrodesis with screws and rods.	IR
Baudracco et al. [45]	2017	45/F	C4/C5 spontaneous CDH	C4/C5 Anterior cervical corpectomy and fusion	CR
Baldvinsdottir et al. [46]	2017	67/M	T6/T7 extramedullary cavernous haemangioma	posterior laminectomy + en bloc excision	CR
Alkhamees et al. [47]	2016	50/F	T3 ISCH	Laminectomy + medial durotomy	IR
Delgado et al. [48]	2016	33/F	T7/T8 ISCH	T7/8 laminectomy	CR
Porto et al. [49]	2016	86/M	C4/C5 CHD; C3/C4 severe cervical stenosis	C3 to C5 ACDF	IR
Aiyer et al. [50]	2016	50/M	C3 Spinal cord herniation + Pseudomeningocele	C2-4 posterior cervical approach	CR
Guan et al. [51]	2015	53/M	C4/C5 calcified CDH; C5 posterior vertebral osteophyte.	C5 subtotal vertebrectomy and anterior reconstruction	IR
Ju et al. [52]	2015	33/F	T3/T4 ISCH	T3 total laminectomy	CR
Noguera et al. [53]	2015	43/M	C7/T1 intramedullary neurocysticercosis cyst	C6/C7/ T1 laminectomy	CR
De Souza et al. [54]	2014	66/F	T4 ventral spinal cord herniation	T4 laminectomy	IR
Ramdasi et al. [55]	2014	28/M	T2/T3 thoracic osteochondroma	T2/T3 laminectomy	CR
Witiw et al. [56]	2014	36/M	T8/T9 Thoracic disc herniation	Posterior surgical decompression and resection of the intradural disc	IR
Yamamoto et al. [57]	2014	62/M	C3 ISCM from Sarcomatoid Malignant Mesothelioma	C3 laminectomy; C4/C6 laminoplasty	IR
Kim et al. [58]	2014	64/M	C7/T1 extradural cervical synovial cyst; C4/C5/C6 osteophytes	C5/C6 laminoplasty; C7 laminectomy	IR
Kulkarni et al. [59]	2013	65/F	C3 to C5 epidural hematoma (minor trauma; sudden voluntary hyperextension of the neck)	C3/C4/C5 Open-door laminoplasty	CR
Bulsara et al. [60]	2013	51/F	C6 spinal arteriovenous fistulae	C5/C7 laminectomies; partial C5/6 facetectomy	CR
Sinha et al. [61]	2013	44/F	C2 to C5 intramedullary abscess (Streptococcus milleri)	C3/C5 laminectomy	IR
Ko et al. [62]	2013	30/M	T2-T3 SSEH	Laminectomy + hematoma evacuation	CR





Study	Year	Patient (Age/Sex)	Diagnosis	Surgical Approach	Outcome
Seon et al. [63]	2013	65/M	C3/C4/C5 Spontaneous epidural hematoma	C3 to C5 hemilaminectomy + hematoma evacuation	IR
Yoon et al. [64]	2012	59/F	C3 to C6 Spontaneous epidural hematoma	C3 to C6 hemilaminectomy + hematoma evacuation	CR
Yokoyama et al. [65]	2012	63/M	C3/C4 CDH + C4 to C7 severe canal stenosis	Decompression posterior cervical laminoplasty	CR
Roy et al. [66]	2012	65/F	C3-C4 SSEH	C3-C5 laminoplasty	CR
Lee et al. [67]	2012	32/M	C4-C5 facet area Cervical Osteochondroma (history of trivial trauma)	C4-C5 hemilaminectomy	IR
Aydin et al. [68]	2011	52/F	T4-T5 and T5-T6 ISCH	laminectomy	IR
Kansal et al. [69]	2011	45/M	C5/6 CDH	C5/6 anterior discectomy	IR
Urrutia et al. [70]	2011	51/M	C6-C7 CDH	C6 corpectomy	CR
Jost et al. [71]	2010	54/M	Regional kyphosis and large swollen paraspinal muscles impinging on the spinal cord (after posterior cervical decompression)	C4/C5 ACDF	CR
Choi et al. [72]	2009	31/M	C3-C4 CDH	C3-C4 microsurgical right-sided Smith-Robinson approach (through a transverse incision)	IR
Choi et al. [72]	2009	66/F	C5 to C7 CDH	C5 to C7 ACDF	CR
Laghmari et al. [73]	2009	79/M	C4-C5 CDH	C4 -C6 ACCF	CR
Kim et al. [74]	2009	28/M	C3-C4 CDH	C3-C4 ACDF	CR
Ulivieri et al. [75]	2009	35/M	T9-T10 spinal cord herniation	T9-T10 thoracic laminectomy	IR
Marshman et al. [76]	2009	48/F	T8 ISCH	T8 laminectomy	CR
Riaz et al. [77]	2009	63/M	C4 to C6 SSEH	C5-C6 laminectomy	CR
Han et al. [78]	2009	7/M	C7 Osteochondroma	C6/C7 partial hemilaminectomy + removal of the tumor	CR
Selviaridis et al. [79]	2009	51/M	T2-T3 SSCH	T2-T3 laminectomy	CR
Crowley et al. [80]	2008	74/M	T1-T2 ISCM from bladder carcinoma	Laminectomies + subtotal resection	IR
Uhl et al. [81]	2008	50/M	T2-T3 ISCH	T2-T3 dorsal foraminotomy	IR
So et al. [82]	2008	42/F	C4 to C7 epidural hematoma (neck extension)	C3 to C7 laminoplasty	CR
Sayer et al. [83]	2008	46/M	C3/C4 CDH	ACDF + iliac crest bone graft	CR
Riaz et al. [84]	2007	52/M	C6-C7 SSEH	C6-C7 laminectomy	CR
Noudel et al. [85]	2007	12/F	T11 intramedullary spinal cord cavernous angioma	T10 to T12 laminotomy	IR
Payer et al. [86]	2007	50/M	C6 to T8 Intradural pleural malignant mesothelioma	T4-T6 laminectomy; T5 costo-transverso-pediclectomy; T5 corpectomy	IR
Lee et al. [87]	2007	56/M	C5-C6 CDH	Anterior cervical foraminotomy	CR
Lee et al. [87]	2007	47/M	C5-C6 CDH	Anterior cervical foraminotomy	CR
Lee et al. [87]	2007	45/M	C5-C6 CDH	Anterior cervical foraminotomy	CR
Chen et al. [88]	2007	61/F	C4-C5 ossification of the ligamentum flavum	C3 to C7 laminectomy	CR
Cheng et al. [89]	2006	58/M	C6-C7 Ganglion cyst	C6-7 laminectomy + total removal of the cyst	CR

Study	Year	Patient (Age/Sex)	Diagnosis	Surgical Approach	Outcome
Ellger et al. [90]	2006	59/F	T2 ISCH	T2 posterior hemilaminectomy; T3 partial hemilaminectomy	IR
Sani et al. [91]	2005	75/F	C3 to C7 severe canal stenosis	Cervical laminectomy	IR
Kim et al. [92]	2005	72/F	T8-T9 Thoracic subpial intramedullary schwannoma	T8-T9 osteoplastic laminotomy	CR
Rivas et al. [93]	2004	49/M	T6-T7 SSCH	T6-T7 laminectomy	IR
Mastronardi et al. [94]	2004	#/M	C5-C6 CDH	ACDF	IR
Chang et al. [95]	2003	50/M	T7-T8 neurenteric cyst	Thoracic laminectomy	CR
Kobayashi et al. [96]	2003	64/M	C5-C6 CDH spondylosis	C5-C6 ACDF	CR
Kobayashi et al. [96]	2003	39/M	C2-C3 CDH spondylosis	C2-C3 ACDF	CR
Sagiuchi et al. [97]	2003	48/M	T7-T8 ISCH + calcified CDH	T7-T8 laminectomy	CR
Abe et al. [98]	2003	17/M	Cervical kyphosis secondary to neurofibromatosis (flattened spinal cord)	ACDF	CR
Cellerlin et al. [99]	2002	53/M	T8-T9 ISCH	T8-T9 laminectomy	IR
Cellerlin et al. [99]	2002	37/F	T4-T5 ISCH	T4-T5 costotransversectomy	CR



Abbreviations: CR: Complete Recovery; IR: Incomplete Recovery; ACCF: Anterior Cervical Corpectomy and Fusion; ACDF: Anterior Cervical Discectomy and Fusion; ISCH: Idiopathic Spinal Cord Herniation; ISCM: Intramedullary Spinal Cord Metastasis; SSCH: Spontaneous Spinal Cord Herniation; SSEH: Spontaneous Spinal Epidural Hematoma

eases, such as multiple sclerosis. Spinal cord ischemia, usually followed by infarction, occurs due to diminished blood supply to the spinal cord. The causes of blood supply cessation include compression on the blood vessels supplying the spinal cord by tumors or hernias, circulating thrombi, or iatrogenically following endovascular embolization of vertebral hemangioma [29-32]. The treatment is usually conservative with anticoagulation and antiplatelets [31].

## 5. Conclusion

Surgically treatable non-traumatic causes of BSS are more frequent than major traumatic injuries in recent years, as reported in the literature. CDH has been reported as the commonest surgically treatable non-traumatic surgical cause of BSS, followed by SCH, spinal epidural hematoma, ISCM, benign tumors, OPLL, and spinal canal stenosis with cervical spondylosis. Regarding the postoperative outcomes of our patients, the cases with acute epidural hemorrhage achieved complete recovery after surgery, whereas neurological deficits in the other cases, especially those with severe cervical spinal canal stenosis, persisted despite adequate surgical decompression.

## Ethical Considerations

### Compliance with ethical guidelines

Ethics approval Consent to participate written informed consent was obtained from the patients for publishing this article accompanied by the MRI images. Consent for publication Written informed consent was obtained from the patients for publishing this article accompanied by the MRI images.

### Funding

This research did not receive any grant from funding agencies in the public, commercial, or non-profit sectors.

### Authors' contributions

Data Collection: Mahmoud Osama, Vaner Köksal, Mohammed Ali Alvi; Data Analysis and Interpretation: Mahmoud Osama, Vaner Köksal, Mohammed Ali Alvi; Drafting the article: Mahmoud Osama, Vaner Köksal, Mohammed Ali Alvi; Critically revising the article: Mahmoud Osama, Vaner Köksal, Mohammed Ali Alvi; Reviewing submitted version of manuscript: Mahmoud Osama, Vaner Köksal, Mohammed Ali Alvi; Approving



the final version of the manuscript: Mahmoud Osama, Vaner Köksal, Mohammed Ali Alvi.

### Conflict of interest

The authors have no conflict of interest to declare.

### Acknowledgements

The authors would like to thank Mahmoud Osama for his drawings.

### References

- [1] Rengachary SS, Colen C, Guthikonda M. Charles-Edouard Brown-Sequard: An eccentric genius. *Neurosurgery*. 2008; 62(4):954-64. [DOI:10.1227/01.neu.0000318182.87664.1f] [PMID]
- [2] Rice B, Perera P. Intramedullary spinal neurocysticercosis presenting as Brown-Sequard Syndrome. *The Western Journal of Emergency Medicine*. 2012; 13(5):434-6. [DOI:10.5811/westjem.2011.10.6909] [PMID] [PMCID]
- [3] Salazar Noguera EM, Pineda Sic R, Escoto Solis F. Intramedullary spinal cord neurocysticercosis presenting as Brown-Sequard Syndrome. *BMC Neurology*. 2015; 15:1. [DOI:10.1186/s12883-014-0245-5] [PMID] [PMCID]
- [4] Huang YH, Shi QX, Xu MM, Chen CZ, Yang ML, Li JJ, et al. Spinal cord syphilitic gumma presenting with Brown-Sequard Syndrome: A case report and literature review. *Annals of Clinical & Laboratory Science*. 2019; 49(2):265-70. [PMID]
- [5] Kim SW, Ju CI, Kim HS, Kim YS. Brown-Sequard Syndrome caused by a cervical synovial cyst. *Journal of Korean Neurosurgical Society*. 2014; 55(4):215-7. [DOI:10.3340/jkns.2014.55.4.215] [PMID] [PMCID]
- [6] Loncán LI, Sempere DF, Ajuria JE. Brown-Sequard Syndrome caused by a Kirschner wire as a complication of clavicular osteosynthesis. *Spinal Cord*. 1998; 36(11):797-9. [DOI:10.1038/sj.sc.3100683] [PMID]
- [7] Agha RA, Borrelli MR, Farwana R, Koshy K, Fowler AJ, Orgill DP, et al. The PROCESS 2018 statement: Updating Consensus Preferred Reporting Of CasE Series in Surgery (PROCESS) guidelines. *International Journal of Surgery*. 2018; 60:279-82. [DOI:10.1016/j.ijsu.2018.10.031] [PMID]
- [8] Köksal V, Yavasi O. Controversies in the differential diagnosis of Brown-Sequard Syndrome due to cervical spinal disease from stroke: A case series. *Turkish Journal of Emergency Medicine*. 2017; 17(3):115-20. [DOI:10.1016/j.tjem.2017.05.002] [PMID] [PMCID]
- [9] Moher D, Liberati A, Tetzlaff J, Altman DG, The PRISMA Group. Preferred reporting items for systematic reviews and meta-analyses: The PRISMA statement. *PLoS Medicine*. 2009; 6(7):e1000097. [DOI:10.1371/journal.pmed.1000097] [PMID] [PMCID]
- [10] Velmahos GC, Degiannis E, Hart K, Souter I, Saadia R. Changing profiles in spinal cord injuries and risk factors influencing recovery after penetrating injuries. *The Journal of Trauma and Acute Care Surgery*. 1995; 38(3):334-7. [DOI:10.1097/00005373-199503000-00004] [PMID]
- [11] Sato M, Kuriyama A, Ohtomo R. Unilateral loss of thoracic motion after blunt trauma: A sign of acute Brown-Sequard Syndrome. *Clinical and Experimental Emergency Medicine*. 2019; 6(3):268-71. [DOI:10.15441/ceem.19.010] [PMID] [PMCID]
- [12] Rosario-Concepción RA, Pérez JC, Jiménez C, Frontera WR, López-Acevedo C. Delayed diagnosis of traumatic gunshot wound Brown-Sequard-Plus Syndrome due to associated brachial plexopathy. *Spinal Cord Series and Cases*. 2018; 4:44. [DOI:10.1038/s41394-018-0075-6] [PMID] [PMCID]
- [13] Komarowska M, Debek W, Wojnar JA, Hermanowicz A, Rogalski M. Brown-Sequard Syndrome in a 11-year-old girl due to penetrating glass injury to the thoracic spine. *European Journal of Orthopaedic Surgery & Traumatology*. 2013; 23(Suppl 2):S141-3. [DOI:10.1007/s00590-012-1050-8] [PMID] [PMCID]
- [14] Johnson S, Jones M, Zumsteg J. Brown-Sequard Syndrome without vascular injury associated with Horner's Syndrome after a stab injury to the neck. *The Journal of Spinal Cord Medicine*. 2016; 39(1):111-4. [DOI:10.1179/2045772314Y.0000000297] [PMID] [PMCID]
- [15] Porto GBF, Tan LA, Kasliwal MK, Traynelis VC. Progressive Brown-Séquard Syndrome: A rare manifestation of cervical disc herniation. *Journal of Clinical Neuroscience*. 2016; 29:196-8. [DOI:10.1016/j.jocn.2015.12.021] [PMID]
- [16] Karadag-Saygi E, Cubukcu-Aydoseli K, Aydoseli A, Akyuz G. Brown-Sequard Syndrome caused by cervical disc herniation: Case report and review. *Neurosurgery Quarterly*. 2010; 20(1):46-7. [DOI:10.1097/WNQ.0b013e3181d27625]
- [17] Guan D, Wang G, Clare M, Kuang Z. Brown-Sequard Syndrome produced by calcified herniated cervical disc and posterior vertebral osteophyte: Case report. *Journal of Orthopaedics*. 2015; 12(Suppl 2):S260-3. [DOI:10.1016/j.jor.2015.10.007] [PMID] [PMCID]
- [18] Futawatari K, Matsuoka S, Kowada M. [A case of spinal epidural hematoma associated with idiopathic thrombocytopenic purpura (Japanese)]. *No Shinkei Geka*. 1991; 19(12):1187-90. [PMID]
- [19] Ramdasi RV, Mahore A. Solitary thoracic osteochondroma presenting as Brown-Sequard Syndrome. *BMJ Case Reports*. 2014; 2014:bcr2014206656. [DOI:10.1136/bcr-2014-206656] [PMID] [PMCID]
- [20] Han IH, Kuh SU. Cervical osteochondroma presenting as Brown-Sequard Syndrome in a child with hereditary multiple exostosis. *Journal of Korean Neurosurgical Society*. 2009; 45(5):309-11. [DOI:10.3340/jkns.2009.45.5.309] [PMID] [PMCID]
- [21] Yamamoto J, Ueta K, Takenaka M, Takahashi M, Nishizawa S. Sarcomatoid malignant mesothelioma presenting with intramedullary spinal cord metastasis: A case report and literature review. *Global Spine Journal*. 2014; 4(2):115-9. [DOI:10.1055/s-0033-1361589] [PMID] [PMCID]
- [22] Kabbalo MA, Brennan DD, El Bassiouni M, Skehan SJ, Gupta RK. Intramedullary spinal cord metastasis from colonic carcinoma presenting as Brown-Sequard syndrome: A case report. *Journal of Medical Case Reports*. 2011; 5:342. [DOI:10.1186/1752-1947-5-342] [PMID] [PMCID]
- [23] Caillot A, Veyssièrè A, Ambroise B, Bénateau H. Spinal cord metastasis of squamous cell carcinoma of the max-



- illary sinus. *European Annals of Otorhinolaryngology, Head and Neck Diseases*. 2015; 132(2):97-9. [DOI:10.1016/j.anorl.2014.03.006] [PMID]
- [24] Pérez-Suárez J, Barrio-Fernández P, Ibáñez-Plágaro FJ, Ribas-Ariño T, Calvo-Calleja P, Mostaza-Saavedra AL. [Intramedullary spinal cord metastasis from gastric adenocarcinoma: Case report and review of literature (Spanish)]. *Neurocirugía*. 2016; 27(1):28-32. [DOI:10.1016/j.neucir.2015.06.005] [PMID]
- [25] Fujimoto A, Matsumura A, Maruno T, Yasuda S, Nose T. Cervical spondylosis with thoracic level Brown-Sequard Syndrome. *Journal of Clinical Neuroscience*. 2004; 11(8):898-901. [DOI:10.1016/j.jocn.2003.11.018] [PMID]
- [26] Yoon BH, Park KS, Jung SS, Park MS, Kim SM, Chung SY, et al. Spontaneous cervical epidural hematoma causing Brown-Sequard Syndrome. *Korean Journal of Spine*. 2012; 9(3):297-9. [DOI:10.14245/kjs.2012.9.3.297] [PMID] [PMCID]
- [27] Elsayed MAM, Aladil O, Elsadig SM, Ahmed MH, Noori SI. Challenging neurological presentations of varicella virus infections in Sudan: Clinical features, imaging and recommendations. *Journal of Family Medicine and Primary Care*. 2019; 8(6):2161-4. [DOI:10.4103/jfmpc.jfmpc\_183\_19] [PMID] [PMCID]
- [28] Bessho M, Nakajima H, Ito T, Kitaoka H. [Case of incomplete Brown-Sequard Syndrome after thoracic herpes zoster infection (Japanese)]. *Rinshō Shinkeigaku*. 2010; 50(3):175-7. [DOI:10.5692/clinicalneuro.50.175] [PMID]
- [29] Fernandez-Torron R, Palma JA, Riverol M, Irimia P, Martinez-Vila E. Brown-Sequard Syndrome after endovascular embolization of vertebral hemangioma. *Spinal Cord*. 2012; 50(8):636-7. [DOI:10.1038/sc.2012.3] [PMID]
- [30] Sharma K, Kamholz JA, Leira EC. Spinal cord infarction presenting as a Hemicord Syndrome: Report of 2 cases. *Journal of Stroke and Cerebrovascular Diseases*. 2018; 27(6):e107-9. [DOI:10.1016/j.jstrokecerebrovasdis.2018.01.003] [PMID]
- [31] Meng YY, Dou L, Wang CM, Kong DZ, Wei Y, Wu LS, et al. Spinal cord infarction presenting as Brown-Sequard Syndrome from spontaneous vertebral artery dissection: A case report and literature review. *BMC Neurology*. 2019; 19(1):321. [DOI:10.1186/s12883-019-1559-0] [PMID] [PMCID]
- [32] Astreimidis A, Finitis S, Mavropoulou X, Psoma E, Prassopoulos P. Acute partial Brown-Sequard Syndrome secondary to intraforaminal disc prolapse and spinal cord infarction. *Case Reports in Neurological Medicine*. 2019; 2019:7987038. [DOI:10.1155/2019/7987038] [PMID] [PMCID]
- [33] Ding Q, Yu L. Spontaneous cervical intradural disc herniation presenting with brown-sequard syndrome at C6-C7 level. *Journal of Orthopaedic Case Reports*. 2019; 9(2):30-3. [DOI:10.13107/jocr.2250-0685.1356]
- [34] Neale N, Ramayya A, Welch W. Surgical management of idiopathic thoracic spinal cord herniation. *World Neurosurgery*. 2019; 129:81-4. <https://www.sciencedirect.com/science/article/abs/pii/S1878875019314962>
- [35] Gomez-Amarillo D, Garcia-Baena C, Volcinschi-Moros D, Hakim F. Thoracic idiopathic spinal cord herniation in a young patient: a diagnostic and therapeutic challenge. *BMJ Case Reports CP*. 2019; 12(5):e227847. [DOI:10.1136/bcr-2018-227847]
- [36] Tyagi G, Prabhuraj AR, Bhat DI, Rao MB, Devi BI. Duplication of ventral dura as a cause of ventral herniation of spinal cord – a report of two cases and review of the literature. *World neurosurgery*. 2019; 126:346-53. <https://www.sciencedirect.com/science/article/abs/pii/S1878875019305662>
- [37] Mathais Q, Esnault P, Cruc M, Bernard C, Prunet B, Gailard PE. Spontaneous cervical spinal epidural hematoma associated with dabigatran. *World Neurosurgery*. 2018; 112:264-6. <https://www.sciencedirect.com/science/article/abs/pii/S1878875018302420>
- [38] Patel R, Kumar A, Nishizawa K, Kumar N. Hemiparesis in spontaneous spinal epidural haematoma: A potential stroke imitator. *Case Reports*. 2018; 2018:bcr-2017. [DOI:10.1136/bcr-2017-222686]
- [39] Zeng Y, Ren H, Wan J, Lu J, Zhong F, Deng S. Cervical disc herniation causing Brown-Sequard syndrome: Case report and review of literature (CARE-compliant). *Medicine*. 2018; 97(37):e12377. [DOI:10.1097/MD.00000000000012377] [PMID] [PMCID]
- [40] Du K, Lou Z, Zhang C, Guo P, Chen L, Wang B, et al. Transpedicular excision of a thoracic intraspinal osteochondroma in a patient with hereditary multiple exostoses and brown-sequard syndrome. *World Neurosurgery*. 2018; 111:94-8. <https://www.sciencedirect.com/science/article/abs/pii/S1878875017321708>
- [41] Kida K, Tani T, Kawazoe T, Hiroi M. A recurrent cervical neurenteric cyst treated anteriorly: safe, gross-total excision facilitated by prophylactic unilateral vertebral artery exposure, microdissection, and spinal cord monitoring—a case report and technical note. *Case Reports in Orthopedics*. 2018; 2018. [DOI:10.1155/2018/7620182]
- [42] Ghali MGZ, Srinivasan VM, Rao VY, Omeis I. Idiopathic thoracic spinal cord herniation. *Journal of Clinical Neuroscience*. 2018; 51:1-5. [DOI:10.1016/j.jocn.2017.10.090]
- [43] O'Neill AH, Phung TB, Lai LT. Intramedullary spinal cord metastasis from thyroid carcinoma: Case report and a systematic pooled analysis of the literature. *Journal of Clinical Neuroscience*. 2018; 49:7-15. <https://www.sciencedirect.com/science/article/abs/pii/S0967586817319653>
- [44] Lee DY, Jeong ST, Lee TH, Kim DH. Brown-Sequard syndrome caused by hyperextension in a patient with atlantoaxial subluxation due to an os odontoideum. *Acta Orthopaedica Et Traumatologica Turcica*. 2018; 52(3):240-3. <https://www.sciencedirect.com/science/article/pii/S1017995X17300391>
- [45] Baudracco I, Grahovac G, Russo VM. Spontaneous cervical intradural disc herniation presenting with Brown-Sequard and Horner's syndrome: lesson learned from a very unique case. *European Spine Journal*. 2017; 26(1):218-21. <https://link.springer.com/article/10.1007/s00586-017-5044-4>
- [46] Baldvinsdóttir B, Erlingsdóttir G, Kjartansson Ó, Ólafsson IH. Extramedullary cavernous hemangioma with intradural and extradural growth and clinical symptoms of Brown-Séquard syndrome: case report and review of the literature. *World Neurosurgery*. 2017; 98:881-e5. <https://www.sciencedirect.com/science/article/abs/pii/S1878875016311743>
- [47] Alkhamees A, Proust F. Idiopathic Spinal Cord Herniation: A Case Report. *International Journal of Health Sciences*. 2016; 10(4):592-5. [PMCID] [PMID]



- [48] Delgado-López PD, Gil-Polo C, Martín-Velasco V, Martín-Alonso J, Galacho-Harriero AM, Araus-Galdós E. Spinal cord herniation repair with microstaples: case report. *Journal of Neurosurgery: Spine*. 2017; 26(3):384-7. [DOI:10.3171/2016.8.SPINE16318]
- [49] Porto GB, Tan LA, Kasliwal MK, Traynelis VC. Progressive Brown-Séquard syndrome: a rare manifestation of cervical disc herniation. *Journal of Clinical Neuroscience*. 2016; 29:196-8. <https://www.sciencedirect.com/science/article/abs/pii/S0967586816000175>
- [50] Aiyer SN, Shetty AP, Kanna R, Maheswaran A, Rajasekaran S. Spinal cord herniation following cervical meningioma excision: a rare clinical entity and review of literature. *European Spine Journal*. 2016; 25(1):216-9. <https://link.springer.com/article/10.1007/s00586-016-4412-9>
- [51] Guan D, Wang G, Clare M, Kuang Z. Brown-Sequard syndrome produced by calcified herniated cervical disc and posterior vertebral osteophyte: Case report. *Journal of Orthopaedics*. 2015; 12:S260-3. <https://www.sciencedirect.com/science/article/abs/pii/S0972978X15001440>
- [52] Ju MW, Choi SW, Youm JY, Kwon HJ. Idiopathic spinal cord herniation presented as Brown-Sequard syndrome: a case report and surgical outcome. *Journal of Korean Neurosurgical Society*. 2015; 58(3):294. [DOI:10.3340/jkns.2015.58.3.294] [PMCID] [PMID]
- [53] Noguera EM, Sic RP, Solis FE. Intramedullary spinal cord neurocysticercosis presenting as Brown-Séquard syndrome. *BMC Neurology*. 2015; 15(1):1-4. <https://bmcneurol.biomedcentral.com/articles/10.1186/s12883-014-0245-5>
- [54] De Souza RB, De Aguiar GB, Daniel JW, Veiga JC. The pathophysiology, classification, treatment, and prognosis of a spontaneous thoracic spinal cord herniation: A case study with literature review. *Surgical Neurology International*. 2014; 5(Suppl 15):S564. [DOI:10.4103/2152-7806.148042] [PMCID] [PMID]
- [55] Ramdasi RV, Mahore A. Solitary thoracic osteochondroma presenting as Brown-Séquard syndrome. *BMJ Case Reports*. 2014; 2014:bcr2014206656. <https://casereports.bmj.com/content/2014/bcr-2014-206656.short>
- [56] Witw CD, Shamji MF. Brown-Séquard syndrome from herniation of a thoracic disc. *CMAJ*. 2014; 186(18):1395. [DOI:10.1503/cmaj.140117]
- [57] Yamamoto J, Ueta K, Takenaka M, Takahashi M, Nishizawa S. Sarcomatoid malignant mesothelioma presenting with intramedullary spinal cord metastasis: A case report and literature review. *Global Spine Journal*. 2014; 4(2):115-9. [DOI:10.1055/s-0033-1361589]
- [58] Kim SW, Ju CI, Kim HS, Kim YS. Brown-séquard syndrome caused by a cervical synovial cyst. *Journal of Korean Neurosurgical Society*. 2014; 55(4):215. [DOI:10.3340/jkns.2014.55.4.215] [PMCID] [PMID]
- [59] Kulkarni AG, Nag K, Shah S. Cervical epidural haematoma causing Brown-Sequard syndrome: a case report. *Journal of Orthopaedic Surgery*. 2013; 21(3):372-4. [DOI:10.1177/230949901302100322]
- [60] Bulsara KR, Hebert R, Gimbel D, Abbed K. Type I spinal arteriovenous fistulae exception: a case for reclassification. *Neurochirurgie*. 2013; 59(2):69-74. <https://www.sciencedirect.com/science/article/abs/pii/S0028377013000027>
- [61] Sinha P, Parekh T, Pal D. Intramedullary abscess of the upper cervical spinal cord. Unusual presentation and dilemmas of management: Case report. *Clinical Neurology and Neurosurgery*. 2013; 115(9):1845-50. [DOI:10.1016/j.clineuro.2013.01.008] [PMID]
- [62] Ko JI, Kim T, Jwa CS, Jang JY, Jeong KY, Suh GJ, Park T. Spontaneous spinal epidural hematoma presenting as Brown-Sequard syndrome. *The American Journal of Emergency Medicine*. 2013; 31(4):757-e3. [https://www.ajemjournal.com/article/S0735-6757\(12\)00599-2/fulltext](https://www.ajemjournal.com/article/S0735-6757(12)00599-2/fulltext)
- [63] Seon HJ, Song MK, Han JY, Choi IS, Lee SG. Spontaneous cervical epidural hematoma presenting as brown-sequard syndrome following repetitive korean traditional deep bows. *Annals of Rehabilitation Medicine*. 2013; 37(1):123-6. [DOI:10.5535/arm.2013.37.1.123]
- [64] Yoon BH, Park KS, Jung SS, Park MS, Kim SM, Chung SY, Chung JC, Kim HK. Spontaneous cervical epidural hematoma causing brown-sequard syndrome. *Korean Journal of Spine*. 2012; 9(3):297-99. [DOI:10.14245/kjs.2012.9.3.297]
- [65] Yokoyama K, Kawanishi M, Yamada M, Kuroiwa T. Cervical disc herniation manifesting as a Brown-Sequard syndrome. *Journal of Neurosciences in Rural Practice*. 2012; 3(02):182-3. [DOI:10.4103/0976-3147.98229]
- [66] Roy SP, Agrawal N. Brown Sequard syndrome secondary to a spontaneous cervical epidural hematoma-a rare entity. *Journal of Orthopaedic Case Reports*. 2012; 2(4):23-25. [PMCID] [PMID]
- [67] Lee JY, Im SB, Park KW, Shin DS. Subclinical cervical osteochondroma presenting as Brown-Séquard syndrome after trivial neck trauma. *Journal of Korean Neurosurgical Society*. 2012; 51(4):233-6. [DOI:10.3340/jkns.2012.51.4.233] [PMCID]
- [68] Aydin AL, Sasani M, Erhan B, Sasani H, Ozcan S, Ozer AF. Idiopathic spinal cord herniation at two separate zones of the thoracic spine: the first reported case and literature review. *The Spine Journal*. 2011; 11(8):e9-14. <https://www.sciencedirect.com/science/article/abs/pii/S152994301100475X>
- [69] Kansal R, Mahore A, Kukreja S. Cervical intradural disc herniation and cerebrospinal fluid leak. *Neurology India*. 2011; 59(3):447-50. <https://neurologyindia.com/article.asp?issn=0028-3886;year=2011;volume=59;issue=3;page=447;epage=450;aulast=Kansal>
- [70] Urrutia J, Fadic R. Cervical disc herniation producing acute Brown-Sequard syndrome: dynamic changes documented by intraoperative neuromonitoring. *European Spine Journal*. 2012; 21(4):418-21. <https://link.springer.com/article/10.1007/s00586-011-1881-8>
- [71] Jost PW, Marawar S, O'Leary PF. Paraspinal muscle impingement causing acute brown-sequard syndrome after posterior cervical decompression. *Spine*. 2010; 35(7):E260-3. [https://journals.lww.com/spinejournal/Abstract/2010/04010/Paraspinal\\_Muscle\\_Impingement\\_Causing\\_Acute.34.aspx](https://journals.lww.com/spinejournal/Abstract/2010/04010/Paraspinal_Muscle_Impingement_Causing_Acute.34.aspx)
- [72] Choi KB, Lee CD, Chung DJ, Lee SH. Cervical disc herniation as a cause of brown-séquard syndrome. *Journal of Korean Neurosurgical Society*. 2009; 46(5):505-10. [DOI:10.3340/jkns.2009.46.5.505]
- [73] Laghmari M, Blondel B, Metellus P, Bartoli M, Fuentes S, Pech-Gourg G, Adetchessi T, Dufour H, Branchereau A, Grisol F. Brown-Sequard-type myelopathy due to cervical disc



- herniation associated with severe carotid stenosis prompting rapid combined craniectomy and carotid endarterectomy under deep anticoagulant therapy. *The Spine Journal*. 2009; 9(11):e15-9. <https://www.sciencedirect.com/science/article/abs/pii/S1529943009003295>
- [74] Kim JT, Bong HJ, Chung DS, Park YS. Cervical disc herniation producing acute Brown-Sequard syndrome. *Journal of Korean Neurosurgical Society*. 2009; 45(5):312-4. [DOI:10.3340/jkns.2009.45.5.312]
- [75] Olivieri S, Olivieri G, Petrini C, D'Elia F, Cuneo GL, Cerese A. Thoracic spinal cord herniation: Case report and technical note. *Neurol Neurochir Pol*. 2009; 43(1):86-9. <https://www.researchgate.net/profile/Alfonso-Cerese/publication/>
- [76] Marshman LA, Hardwidge C, Ford-Dunn SC, Olney JS. Idiopathic spinal cord herniation: case report and review of the literature. *Neurosurgery*. 1999; 44(5):1129-33. <https://academic.oup.com/crawlpreservation/governor?content=%2fneurosurgery%2farticle-abstract%2f44%2f5%2f1129%2f2816842>
- [77] Riaz S, Jiang H, Fox R, Lavoie M, Mahood JK. Spontaneous spinal epidural hematoma causing Brown-Sequard syndrome: case report and review of the literature. *The Journal of Emergency Medicine*. 2007; 33(3):241-4. <https://www.sciencedirect.com/science/article/abs/pii/S0736467907001679>
- [78] Han IH, Kuh SU. Cervical osteochondroma presenting as brown-sequard syndrome in a child with hereditary multiple exostosis. *Journal of Korean Neurosurgical Society*. 2009; 45(5):309-11. [DOI:10.3340/jkns.2009.45.5.309] [PMCID] [PMID]
- [79] Selviaridis P, Balogiannis I, Foroglou N, Hatzisotiriou A, Patsalas I. Spontaneous spinal cord herniation: recurrence after 10 years. *The Spine Journal*. 2009; 9(3):e17-9. <https://www.sciencedirect.com/science/article/abs/pii/S1529943008001368>
- [80] Crowley RW, Sherman JH, Le BH, Jane Sr JA. Intramedullary spinal cord metastasis from bladder carcinoma: case report. *Neurosurgery*. 2008; 63(3):E611-2.81. <https://academic.oup.com/crawlpreservation/governor?>
- [81] Uhl E, Holtmannspötter M, Tonn JC. Improvement of Brown-Sequard syndrome after surgical repair of an idiopathic thoracic spinal cord herniation. *Journal of Neurology*. 2008; 255(1):125-6. [DOI:10.1007/s00415-008-0553-z]
- [82] So G, Debata A, Baba S, Tsunoda K, Suyama K, Nagata I. Spontaneous cervical epidural hematoma presenting with hemiparesis following neck extension: A case report. *No shinkei geka. Neurological Surgery*. 2008; 36(8):731-4. <https://europepmc.org/article/med/18700537>
- [83] Sayer FT, Vitali AM, Low HL, Paquette S, Honey CR. Brown-Sequard syndrome produced by C3-C4 cervical disc herniation: A case report and review of the literature. *Spine*. 2008; 33(9):E279-82. [https://journals.lww.com/spinejournal/Abstract/2008/04200/Brown\\_S\\_quard\\_Syndrome\\_Produced\\_by\\_C3\\_C4\\_Cervical.21.aspx](https://journals.lww.com/spinejournal/Abstract/2008/04200/Brown_S_quard_Syndrome_Produced_by_C3_C4_Cervical.21.aspx)
- [84] Riaz S, Jiang H, Fox R, Lavoie M, Mahood JK. Spontaneous spinal epidural hematoma causing Brown-Sequard syndrome: case report and review of the literature. *The Journal of Emergency Medicine*. 2007; 33(3):241-4. <https://www.sciencedirect.com/science/article/abs/pii/S0736467907001679>
- [85] Noudel R, Litré F, Vinchon M, Patey M, Rousseaux P. Intramedullary spinal cord cavernous angioma in children: case report and literature review. *Child's Nervous System*. 2008; 24(2):259-63. <https://link.springer.com/article/10.1007/s00381-007-0441-3>
- [86] Payer M, Von Briel T. Intradural pleural malignant mesothelioma. *Acta Neurochirurgica*. 2007; 149(10):1053-6. <https://link.springer.com/article/10.1007/s00701-007-1255-5>
- [87] Lee JK, Kim YS, Kim SH. Brown-Sequard syndrome produced by cervical disc herniation with complete neurologic recovery: report of three cases and review of the literature. *Spinal Cord*. 2007; 45(11):744-8. <https://www.nature.com/articles/3102025>
- [88] Chen PY, Lin CY, Tzaan WC, Chen HC. Brown-Sequard syndrome caused by ossification of the ligamentum flavum. *Journal of Clinical Neuroscience*. 2007; 14(9):887-90. <https://www.sciencedirect.com/science/article/abs/pii/S0967586806004012>
- [89] Cheng WY, Shen CC, Wen MC. Ganglion cyst of the cervical spine presenting with Brown-Sequard syndrome. *Journal of Clinical Neuroscience*. 2006; 13(10):1041-5. <https://www.sciencedirect.com/science/article/abs/pii/S0967586806004607>
- [90] Ellger T, Schul C, Heindel W, Evers S, Ringelstein EB. Idiopathic spinal cord herniation causing progressive Brown-Sequard syndrome. *Clinical Neurology and Neurosurgery*. 2006; 108(4):388-91. <https://www.sciencedirect.com/science/article/abs/pii/S0303846704001040>
- [91] Sani S, Boco T, Deutsch H. Cervical stenosis presenting with acute Brown-Sequard syndrome: Case report. *Spine*. 2005; 30(16):E481-3. [https://journals.lww.com/spinejournal/Abstract/2005/08150/Cervical\\_Stenosis\\_Presenting\\_With\\_Acute.25.aspx](https://journals.lww.com/spinejournal/Abstract/2005/08150/Cervical_Stenosis_Presenting_With_Acute.25.aspx)
- [92] Kim SD, Nakagawa H, Mizuno J, Inoue T. Thoracic subpial intramedullary schwannoma involving a ventral nerve root: A case report and review of the literature. *Surgical Neurology*. 2005; 63(4):389-93. <https://www.sciencedirect.com/science/article/abs/pii/S0090301904003969>
- [93] Rivas JJ, de la Lama A, Gonza Lez P, Ramos A, Zurdo M, Alday R. [Spontaneous spinal cord herniation]. *Neurocirugía (Astur)*. 2004; 15(5):484-9. <https://pubmed.ncbi.nlm.nih.gov/15558208/>
- [94] Mastrorandi L, Ruggeri A. Cervical disc herniation producing Brown-Sequard syndrome: case report. *Spine*. 2004; 29(2):E28-31. [https://journals.lww.com/spinejournal/Abstract/2004/01150/Cervical\\_Disc\\_Herniation\\_Producing\\_Brown\\_Sequard.24.aspx](https://journals.lww.com/spinejournal/Abstract/2004/01150/Cervical_Disc_Herniation_Producing_Brown_Sequard.24.aspx)
- [95] Chang IC. Thoracic neurenteric cyst in a middle aged adult presenting with Brown-Sequard syndrome. *Spine*. 2003; 28(24):E515-8. [https://journals.lww.com/spinejournal/Abstract/2003/12150/Thoracic\\_Neurenteric\\_Cyst\\_in\\_a\\_Middle\\_Aged\\_Adult.19.aspx](https://journals.lww.com/spinejournal/Abstract/2003/12150/Thoracic_Neurenteric_Cyst_in_a_Middle_Aged_Adult.19.aspx)
- [96] Kobayashi N, Asamoto S, Doi H, Sugiyama H. Brown-Sequard syndrome produced by cervical disc herniation: report of two cases and review of the literature. *The Spine Journal*. 2003; 3(6):530-3. <https://www.sciencedirect.com/science/article/abs/pii/S1529943003000780>
- [97] Sagiuchi T, Iida H, Tachibana S, Utsuki S, Tanaka R, Fujii K. Idiopathic spinal cord herniation associated with calcified thoracic disc extrusion—case report—. *Neurologia Medico-chirurgica*. 2003; 43(7):364-8. [https://www.jstage.jst.go.jp/article/nmc/43/7/43\\_7\\_364/\\_article/-char/ja/](https://www.jstage.jst.go.jp/article/nmc/43/7/43_7_364/_article/-char/ja/)