



Pancreatic Head Hydatid Cyst: An Unusual Case

Raheleh Jabini,¹ Elahe Skandari,² Kamran Ghaffarzadegan,³ and Mohammadreza Farzanehfar^{4,5,*}

¹Biotechnology Research Center, Mashhad University of Medical Sciences, Mashhad, IR Iran

²Internal Medicine Doctor, Mashhad, IR Iran

³Razavi Cancer Research Center, Research and Education Department, Razavi Hospital, Mashhad, Iran

⁴Gastroenterology and Hepatology Research Center, Mashhad University of Medical Sciences, Mashhad, IR Iran

⁵Department of Internal Medicine, Faculty of Medicine, Mashhad University of Medical Sciences, Mashhad, IR Iran

*Corresponding author: Dr. Mohammadreza Farzanehfar, Department of Internal Medicine, Faculty of Medicine, Mashhad University of Medical Sciences, P. O. Box 99199-91766, Mashhad, Iran. Tel: +98-5138012742, Fax: +98-5138453239, E-mail: farzanehfm@mums.ac.ir

Received 2017 May 22; Revised 2017 October 18; Accepted 2017 November 13.

Abstract

Introduction: Pancreatic hydatid cyst (PHC), a rare parasitic infectious disease, is caused by the larvae of *Echinococcus granulosus*. Common human organs affected by the hydatid cyst are the liver and lung, but it rarely involves other organs such as the pancreas.

Case Presentation: A rare case is reported of a patient with a pancreatic head hydatid cyst. The result of the patient's preliminary serological surveys was negative and the pancreatic lesion was suspected to be a pseudocyst or cystic pancreatic neoplasms. Following complete excision of the lesion, the pathological analysis of the surgical specimen confirmed hydatid disease.

Conclusions: Pancreatic hydatid cysts may be confused with more common lesions of the pancreas such as pseudocysts and cystic pancreatic neoplasms. Physicians should always consider this disease in the differential diagnosis, especially for patients from endemic areas.

Keywords: Pancreas, Hydatid Cyst, Case Report

1. Introduction

Pancreatic hydatid cyst (PHC) is a rare parasitic infectious disease caused by the larvae of *Echinococcus granulosus* (1). The liver is the most common site of involvement in hydatid disease, followed by the lung in endemic regions (2). However, involvement of the kidneys, bone, brain, and pancreas are rare (3). The current study describes the case of a man who presented abdominal pain and a pancreatic mass.

2. Case Presentation

For one week a 65-year-old male patient complained of vague abdominal pain especially in the epigastric region and occasional vomiting. He gave no history of jaundice, fever, weight loss, abdominal trauma, surgery, alcohol consumption, nor of any other particular disease. Physical examination revealed mild epigastric tenderness. Baseline haematological and biochemical tests were within normal ranges, including a complete blood count (CBC), erythrocyte sedimentation rate (ESR), liver function tests, serum amylase and lipase. There were no pathological findings of tumor markers. An abdominal ultrasound showed normal liver echogenicity. However, a well-demarcated mass

in the head region of the pancreas was detected, which was approximately 55 × 45 mm in size and contained fluid and scattered calcifications within the cyst wall. No other mass lesion was noted and the primary diagnosis was microcystic adenoma of the pancreas. An abdominal computed tomography (CT) scan revealed no liver lesion, but a hypodense lesion with marginal linear calcification and no contrast enhancement was observed mainly in the head of the pancreas (Figure 1). Thus, a diagnosis was made of a space-occupying lesion in the pancreatic head or a pseudocyst. The enzyme-linked immunoabsorbent assay (ELISA) test was negative. Because of factors such as the patient age and sex, the probability of malignancy was explored by an ultrasound-guided needle biopsy. The pathology report identified fibrosis, inflammation, severe eosinophilic infiltration, eosinophilic hyaline membrane and degeneration confirmed hydatid cyst. The patient underwent surgery for complete excision of the cyst. The final diagnosis of hydatid cyst disease was confirmed by pathological assessment of the surgical specimen (Figure 2).

3. Discussion

A pancreatic hydatid cyst is a rare and potentially fatal disease that affect a small percentage (0.2% - 2%) of the

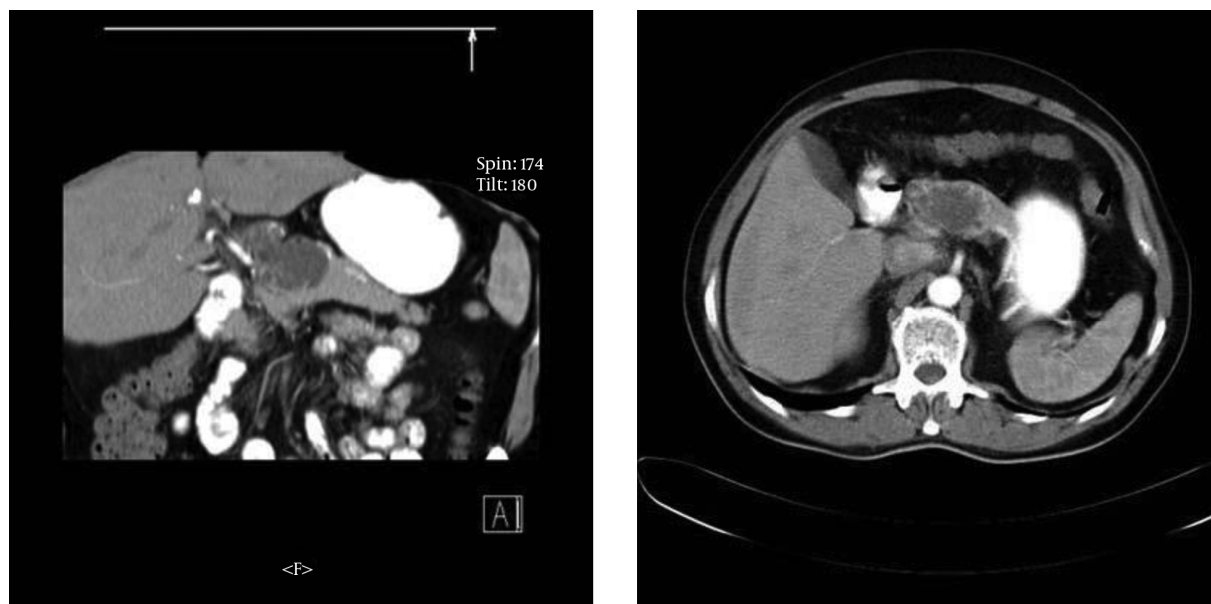


Figure 1. Abdominal CT Scan Showing a Lesion (Arrow) with a Well-Defined Margin in the Head of the Pancreas

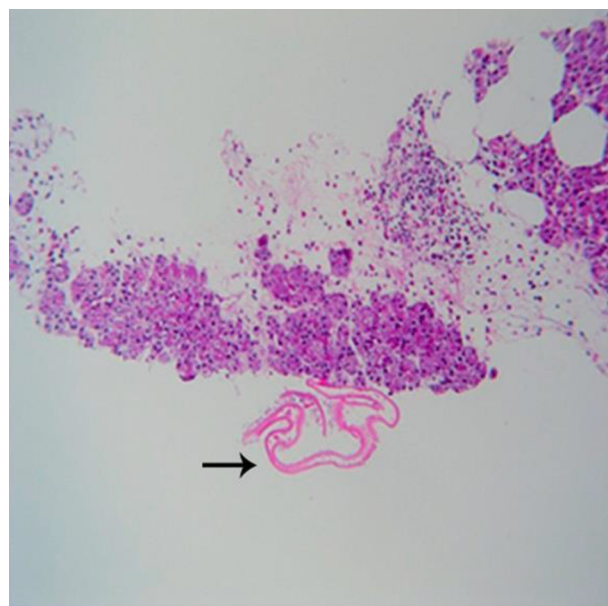


Figure 2. Laminated Membrane of a Hydatid Cyst in the Head of the Pancreas (Arrow), H&E, 100X

population, even in endemic areas (4). It is a parasitic disease common to humans and animals, with a long incubation period ranging from months to years (5). According to the one study in Iran, the distribution of hydatid cysts in differential bodily organs is as follows: liver 57.5%,

lung 30.3%, brain 9.99%, spleen 3.7%, kidney 2.3%, pancreas, spinal cord and retroperitoneum 1.5%, and thyroid, small bowel mesentery and glottal muscles 0.76%. Other organs, such as breast, are rarely involved (6). The presenting clinical features depend on the location of the cysts within the pancreas and the size of the lesions. Although pancreatic head hydatid cysts can present with obstructive jaundice, as reported by Yattoo et al. and Ahmed et al. the current study's case was asymptomatic and only a dull abdominal pain was reported (1, 7). The clinical features presented depend on the location and the size of the lesions. The methods widely used for the diagnosis of cystic visceral lesions include serological testing, histopathology, ultrasonography (USG), computed tomography, and magnetic resonance imaging (MRI) (1, 8). In spite of the high sensitivity of abdominal USG for diagnosing hydatid cysts, this method has a lower sensitivity in the case of PHC due to the retroperitoneal location and bowel gas space (9). The usage of imaging techniques to evaluate hydatidosis is more sensitive than serodiagnosis. However, serological tests may also be effective in the diagnosis of visceral hydatidosis. Similar to some other patients with pancreatic cystic lesions (7, 10, 11), the patient data of the present study showed that the eosinophil count is not a reliable marker. Even after several clinical evaluations, a confident diagnosis cannot be made in some cases and surgical excision is the appropriate treatment of this condition space (11). Hematogenous dissemination, local spread via pan-

creaticobiliary ducts, and peripancreatic lymphatic invasion can be sources of infection (8). Bile duct obstruction can occur due to a cyst's location in the pancreatic head region, thus resulting in obstructive jaundice. Recurrent episodes of acute pancreatitis or chronic pancreatitis may occur. However, when some patients are asymptomatic or only have dull abdominal pain, the cysts are often diagnosed accidentally during imaging techniques. Pancreatic hydatid cysts, without liver or lung involvement, are difficult to diagnose preoperatively. As a pancreatic hydatid cyst is a rare event and the initial presenting symptoms are nonspecific, alternative diagnoses may be considered. PHC may be confused with more common lesions of the pancreas, such as pseudocysts and cystic pancreatic neoplasms space (12). Physicians should always consider this in the differential diagnosis, especially for patients from endemic areas (1). The mainstay treatment of hydatid cysts is complete surgical resection. Depending on the location of the cyst in the pancreas, several techniques for surgical treatment have been described. Adjuvant medical therapy, with pre and postoperative albendazole and praziquantel, is used to sterilize the cyst and reduce the chance of anaphylaxis and recurrence (13).

Acknowledgments

The authors wish to thank the volunteers involved in the study, the laboratory staff, and all those who contributed in terms of time and effort.

Footnote

Conflict of Interest: The authors reported no financial interests nor potential conflict of interest.

References

1. Ahmed Z, Chhabra S, Massey A, Vij V, Yadav R, Bugalia R, et al. Primary hydatid cyst of pancreas, case report and review of literature. *Int J Surg Case Rep.* 2016;27:74-7. doi: [10.1016/j.ijscr.2016.07.054](https://doi.org/10.1016/j.ijscr.2016.07.054). [PubMed: 27552034].
2. Chautems R, Buhler L, Gold B, Chilcott M, Morel P, Mentha G. Long term results after complete or incomplete surgical resection of liver hydatid disease. *Swiss Med Wkly.* 2003;133(17-18):258-62. [PubMed: 12833196].
3. Sorogy ME, El-Hemaly M, Aboelenen A. Pancreatic body hydatid cyst: A case report. *Int J Surg Case Rep.* 2015;6C:68-70. doi: [10.1016/j.ijscr.2014.11.062](https://doi.org/10.1016/j.ijscr.2014.11.062). [PubMed: 25528027].
4. Moosavi SR, Kermany HK. Epigastric mass due to a hydatid cyst of the pancreas, a case report and review of the literature. *JOP.* 2007;8(2):232-4. doi: [10.1016/j.ijscr.2014.11.062](https://doi.org/10.1016/j.ijscr.2014.11.062). [PubMed: 17356249].
5. Isitmangil T, Sebit S, Tunc H, Gorur R, Erdik O, Kunter E, et al. Clinical experience of surgical therapy in 207 patients with thoracic hydatidosis over a 12-year-period. *Swiss Med Wkly.* 2002;132(37-38):548-52. [PubMed: 12508139].
6. Geramizadeh B. Unusual locations of the hydatid cyst: a review from iran. *Iran J Med Sci.* 2013;38(1):2-14. [PubMed: 23645952].
7. Yattoo GN, Khuroo MS, Zargar SA, Bhat FA, Sofi BA. Case report: Percutaneous drainage of the pancreatic head hydatid cyst with obstructive jaundice. *J Gastroenterol Hepatol.* 1999;14(9):931-4. [PubMed: 10535478].
8. Dar AM, Wani AA, Parray FQ, Malik AA, Wani I, Wani RA. Hydatid disease at unusual sites. *Int J Case Rep Imag.* 2012;3(6):1. doi: [10.5348/ijcri-2012-06-128-RA-1](https://doi.org/10.5348/ijcri-2012-06-128-RA-1).
9. Lewall DB, McCorkell SJ. Hepatic echinococcal cysts: sonographic appearance and classification. *Radiology.* 1985;155(3):773-5. doi: [10.1148/radiology.155.3.3890008](https://doi.org/10.1148/radiology.155.3.3890008). [PubMed: 3890008].
10. Mabrouk MB, Waad F, Malek B, Jaafar M, Fethia H, Ahlem S. Hydatid cyst of the pancreas, a report on ten cases. *JOP.* 2015;16(6):591-6.
11. Hernandez-Gonzalez A, Muro A, Barrera I, Ramos G, Orduna A, Siles-Lucas M. Usefulness of four different Echinococcus granulosus recombinant antigens for serodiagnosis of unilocular hydatid disease (UHD) and postsurgical follow-up of patients treated for UHD. *Clin Vaccine Immunol.* 2008;15(1):147-53. doi: [10.1128/CVI.00363-07](https://doi.org/10.1128/CVI.00363-07). [PubMed: 17989342].
12. Filippou D, Tselepis D, Filippou G, Papadopoulos V. Advances in liver echinococcosis: diagnosis and treatment. *Clin Gastroenterol Hepatol.* 2007;5(2):152-9. doi: [10.1016/j.cgh.2006.08.017](https://doi.org/10.1016/j.cgh.2006.08.017). [PubMed: 17157079].
13. Suryawanshi P, Khan AQ, Jatal S. Primary hydatid cyst of pancreas with acute pancreatitis. *Int J Surg Case Rep.* 2011;2(6):122-4. doi: [10.1016/j.ijscr.2011.02.011](https://doi.org/10.1016/j.ijscr.2011.02.011). [PubMed: 22096702].