

A 15 year review of the causes of thoracotomy in Amirkola children's hospital

Soheil Osia¹

Rosemina Molaie^{1*}

Abbas Hadipoor¹

¹ Amirkola children's hospital, Babol University of Medical Sciences, Amirkola, Iran

*Address for Corresponder: Dr. Rosemina Sadat Molaie, Amirkola children's hospital, Amirkola, Iran

(email: rosemina.mo@gmail.com)

How to cite this article:

Osia S, Molaie R, Hadipoor A. A 15 year review of the causes of thoracotomy in Amirkola children's hospital. Iranian Journal of Pediatric Surgery 2018; 4(1): 32-39.

DOI: <http://dx.doi.org/10.22037/irjps.v3i3.20987>

Abstract

Introduction: A wide spectrum of pathologies can cause thoracotomy in the pediatric population. The aim of this study was to determine the frequency of causes of thoracotomy in Amirkola Children's Hospital.

Materials and Methods: This cross sectional study was done on all patients that underwent thoracotomy in Amirkola Children's Hospital. All information was obtained from the patient medical records admitted between 2001- 2016. The causes of thoracotomy were considered.

Results: Overall 60 patients were studied. Esophageal atresia type C with 37 cases (61.7%) was the most common cause of thoracotomy among children. In the study of associated diseases, 5 cases (8.3%) of patients suffered from Imperforate Anus. 44 cases (88%) of infants and only 6 cases (12%) of non-infants had congenital anomalies, and all 4 patients (100%) of non-infants had mediastinal masses. Five cases (8.3%) of non-infants and only one case (16.7%) of infants underwent thoracotomy because of infectious disease ($p < 0.001$). No significant relationship was found between the causes of thoracotomy and gender ($p = 0.41$).

Conclusion: Based on the results of this study, esophageal atresia type C is the most common cause of thoracotomy in infants. Additionally, congenital anomalies in infants and the mediastinal mass and infectious disease were more common in children.

Keywords

- Thoracotomy
- Children
- Atresia
- Mediastinal Mass
- Congenital Anomalies

Introduction

Thoracotomy in children is an uncommon procedure. Overall four major groups of pediatric illnesses could be the cause of thoracotomy in children. Trauma, malignancies, congenital malformations and infections are the four major causes of thoracotomy in the pediatric population.^{1&2} In some institutes immunodeficiency and open biopsy of lung and mediastinum are also considered as causes of thoracotomy.³

Among these; malignancies are the most common reason for Thoracotomy in children. Basically primary lung cancers are rare in this population and secondary malignancies are five times more common than primary causes.⁴ Of all the primary tumors, pleuropulmonary blastomas make up 57% and carcinoid tumors 14% of all the primary tumors in the pediatrics.⁵

Of course in the mentioned study a wide range of primary and secondary tumors were present. It should be considered that various lung cancers common in adults are rare events in the pediatric population.

Another group of causes of thoracotomy are congenital malformations. The overall prevalence of congenital pulmonary malformations is estimated to be about 30-42 in 100000.⁶

Another group is throcaotomy due to infectious causes.

Other less common causes of thoracotomy include heart surgery, lung abscesses and chest traumas.⁷

At least seven different types of thoracotomy are present. The selection of the type of the procedure depends on the type and location of the pathology, the purpose of the surgery and the surgeon's experience. Other than open procedures, thoracoscopy is also widely used in the pediatric population.

In a study by Kanngiesser et al in 2004, metastasis from Wilms tumor, osteosarcoma and pulmonary presentation of lymphoma and leukemia were reported as the most common oncologic causes of thoracotomy in children¹. Also Egli et al reported

similar results as metastasis from wilms tumor and sarcomas for the most common secondary malignancies in pediatrics.⁸

In an article published by Colon in 2012, they reported a 10 year study of pulmonary anomalies in children. Eighty seven patients underwent thoracotomy in the course of the study, among them congenital cystic malformations made up 41%, bronchogenic cysts 19%, sequestration 13% and congenital lobar emphysema 12% of all the surgeries.⁹

In a comparison among immunocompromised and immunocompetent patients that was made by Tseng in 2001, thoracotomy was performed in 30 patients who had abscesses: resistant to medical treatment or patients who had fungal abscesses. Most of the patients requiring surgery for bacterial abscess were under 5 years old and the difference in type of abscess were the cause of different type of surgery in children with and without immunodeficiency.¹⁰

Eventually traumas are also one of the most common causes of thoracotomy in children.²

Since Amirkolla Children's Hospital is one of the major centers of pediatric surgery in north of Iran, we decided to collect statistical information on the prevalence and major cause of thoracotomy in the pediatric population so we could use this information to find the best method of prevention and to concentrate on the best way of treatment for these patients.

Materials and Methods

In this cross sectional study, all the patients who underwent thoracotomy in the Amirkola Children's Hospital were selected as research cases. Inclusion criteria was patient's who underwent thoracotomy during 2001-2016 and patient's who had incomplete files were excluded. Using the hospital archive, information was extracted from the patient's files. Age, sex, underlying disease, location of pathology and cause of thoracotomy were included in the study. The data was analyzed by SPSS V.22, T-test and Chi-square exam were used. P-value less than 0.05 was considered statistically significant.

Results

Overall 60 patients underwent thoracotomy. Forty one patients (68.3%) were male and 19 (31.7%) were female. The prevalence of causes of thoracotomy among the studied patients is shown in **Table 1**.

Among the 60 patients whom underwent thoracotomy, 37 (61.7%) cases were due to type C esophageal atresia and 5 (8.3%) cases were due to esophageal atresia without fistula.

Associated illnesses were also observed in 20 (33.3%) of our cases. It should be mentioned that some of the patients had more than one associated anomalies. **Table 2** shows associated anomalies in our patients.

Of all our cases, 45 patients were neonates (less than 1 month old) and 15 were more than 1 month. The following chart evaluates the relationship between congenital anomalies, mediastinal masses and infection among neonates and older patients and there appears to be a meaningful relationship (p -value <0.001) between the cause of thoracotomy and the patient's age **Figure 1**.

Congenital anomalies were the cause of thoracotomy in 44 of 45 cases of neonates and 6 of 15 older cases. Mediastinal masses were the cause in 4 patients who were all more than 1 month old.

Table 1- Frequency of underlying causes of thoracotomy

Causes of thoracotomy	N	%
Type C esophageal atresia	37	61.7
Esophageal atresia without fistula	5	8.3
Emphysema	4	6.7
Empyema	2	3.3
Type H esophageal atresia	2	3.3
Neuroblastoma	2	3.3
Hydatid Cyst	2	3.3
Esophageal stricture	1	1.7
Diaphragmatic paralysis	1	1.7
Esophageal perforation	1	1.7
Pulmonary Cyst	1	1.7
Pneumothorax	1	1.7
Teratoma	1	1.7
Total	60	100

Table 2- Frequency of associated anomalies

Associated Anomalies	N	%
Imperforated Anus	5	8.3
Patent ductus arteriosus	3	5
Kidney Agenesis	3	5
Pneumonia	2	3.3
Ventricular Septal Defect	2	3.3
Club foot	2	3.3
laryngomalacia	2	3.3
Duodenal Atresia	2	3.3
Polycystic Kidney Disease	1	1.7
Atelectasia	1	1.7
Congenital Vocal Cord Paralysis	1	1.7
Ventriculomegalia	1	1.7
Erb palsy	1	1.7
Dextrocardia/ situs inversus	1	1.7
Intraventricular hemorrhage	1	1.7
Hypoplastic Kidney	1	1.7
Atrial septal defect	1	1.7
no IVC	1	1.7
Meckel's Diverticula+ Hypertrophic Pyloric stenosis	1	1.7
Ambiguous genitalia	1	1.7

Only 1 neonate and 5 older patients underwent thoracotomy due to infectious disease.

The location of pathology in the 4 patients who had mediastinal masses were anterior mediastinum, the right lung, the left lung and the left pleura; each consisting of one case.

As for the site of infection in the six cases, one was

in the right lung, one in the right pleural space and four in the left lung.

In **Table 3**, the causes of thoracotomy were evaluated in different genders, where it does not appear to have any significant relation (P-value= 0.41).

The relationship between congenital anomalies,

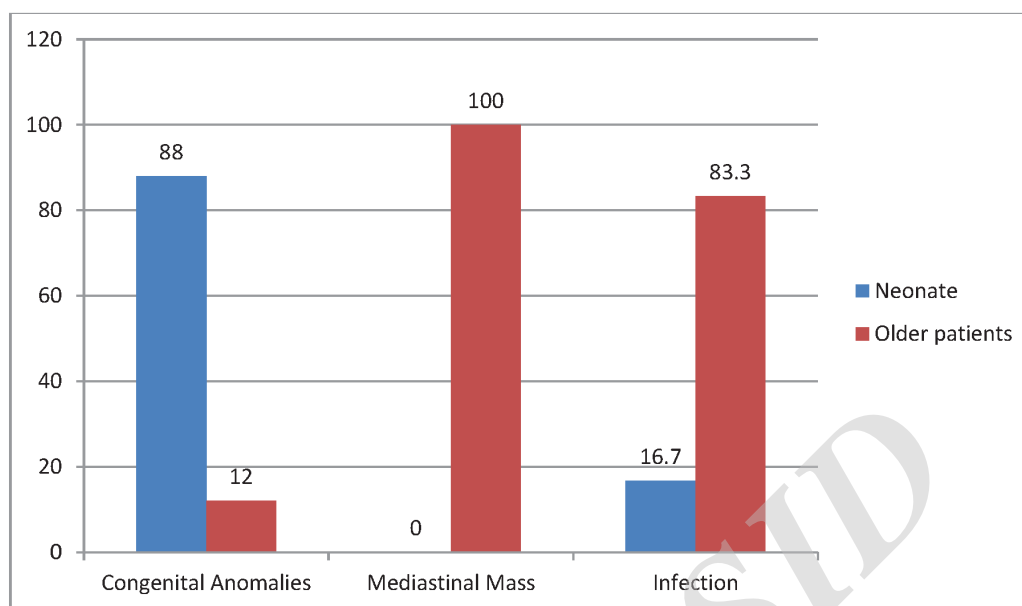


Figure 1: Frequency of different Etiologies for thoracotomy among neonates and older patients

mediastinal masses and infection were studied in both genders and between neonates and older patients. Thirty three cases (80.5%) of the male patients had congenital malformations, 2 cases (4.9%) mediastinal masses and 6 cases (14.6%) infection. On the other hand none of the female patients

had infection, 2 (10.5%) had mediastinal masses and 17 (89.5%) had congenital malformations. Despite our findings, no meaningful relationship was found between the patient's sex and infection as a cause of thoracotomy (P-value=0.2). Then again between these three causes of thoracotomy, a

Table 3- Causes of thoracotomy according to different genders

Causes of thoracotomy	Girl	Boy
	N (%)	N (%)
Empyema	-	2 (100)
Type C esophageal atresia	11 (29.7)	26 (70.3)
Esophageal stricture	-	1 (100)
Emphysema	1 (25)	3 (75)
Diaphragmatic paralysis	-	1 (100)
Type H esophageal atresia	2 (100)	-
Esophageal perforation	-	1 (100)
Esophageal atresia without fistula	3 (60)	2 (40)
Neuroblastoma	1 (50)	1 (50)
Pulmonary Cyst	1 (100)	-
Hydatid Cyst	-	2 (100)
Pneumothorax	-	1 (100)
Teratoma	-	1 (100)

significant relationship was found among neonates and older patients (P -value <0.001) where there was no mediastinal masses in neonates instead 44 cases (97.8%) of congenital malformations were found in them.

Discussion

The purpose of this study was to determine the frequency of the causes of thoracotomy in Amirkola Children's Hospital. Our analysis shows that type C esophageal atresia and esophageal atresia without fistula are the most common cause of thoracotomy in the admitted patients in Amirkola hospital. Also more than 80% of the neonates undergoing thoracotomy had a type of congenital malformation, whereas all the older patients in our study had mediastinal masses. Therefore it is safe to conclude that congenital malformations in neonates and mediastinal masses in older patients are much more common than other causes of thoracotomy.

Since respiratory complications after thoracotomy are common in neonates¹¹, studying the frequency of causes of this surgery can be helpful in post operative management.

In our study; as expected; type C esophageal atresia was the most common cause of thoracotomy. Esophageal atresia is a common congenital malformation of the esophagus which is caused by congenital interruption in the esophageal formation.¹² According to the literature, 1 in every 4000 neonates is involved.¹³ Type C esophageal atresia is composed of an obstructed upper esophagus with a distal trachoesophageal fistula whereas the second most common type is the nonfistulous type which the esophageal atresia has no fistula connecting it to the trachea.¹⁵

In a study by Delshad and colleague, 13 cases (86.6%) of their patients had type C esophageal atresia and only 2 cases (13.4%) had esophageal atresia without fistula.¹⁴ In our study 61.7% had type C and only 8.3% had atresia without fistula, which is similar to the findings of their study.

Mackinlay & colleagues found that the patient's who

underwent thoracotomy due to esophageal atresia, which had no other congenital malformation would have a favorable long term outcome.¹⁶ Overall the result of thoracotomy in patients with esophageal atresia is related to various other factors. Gupta et al in a study found that patients with congenital malformations and associated illnesses had longer recovery periods than other patients and also mentioned that continuous specialized care of these patients had a critical impact in the progress of their recovery.¹⁷

In 2007, Schmidt et al compared the result of type C esophageal atresia in very low birth rate patients and neonates weighing more than 1500g. They reported that the course of treatment and recovery in the very low birth weight patients with atresia had poorer prognosis compared to patients weighing 1500g or more.¹⁸

Early diagnoses, patient's weight, rapid transfer to a pediatric surgery referral center, associated malformations and the patient's management before & after surgery are related to the patient's morbidity and mortality.¹⁹

In our study mediastinal masses were found in four of our patients who were more than 1 month old. Thoracic masses in children mainly occur in the mediastinum and include a wide range from benign cysts to malignant tumors. Surgical resection is the preferred treatment of mediastinal masses and tumors and is possible via thoracotomy.²⁰ We found that neuroblastoma was the most common mediastinal mass. Overall among mediastinal masses, Cysts are uncommon and among mediastinal neoplasms, neurogenic tumors, hematopoietic & lymphatic malignancies and germ cell tumors are the most common mediastinal neoplasms in the pediatric population. Among the neurogenic tumors, neuroblastoma is the most common type^{21,22} which are exactly similar to our findings.

In a study by Zhurilo et al, they reported that in the pediatric population, mediastinal masses were more common in the anterior mediastinum and the frequency of malignancy of these masses was higher than adult patients. Also since the diameter

of the airways was smaller in children and were more flexible compared to adults, these lesions could result in acute respiratory emergencies and airway obstructions.²³ In our study; of 4 cases of mediastinal masses, one case was in the anterior mediastinum. In another study by Haghi on the location of mediastinal masses, 45% were located in the anterior mediastinum, 37% in the posterior and 18% in the middle mediastinum.²⁴

Kulevu et al reported that among the malignant lesions, lymphoma (70%), neurogenic tumors (20%) and thymoma and germ cell tumors (5%) were the most common.²⁵ Whereas in another study by Lam and colleagues, neurogenic tumors had higher frequencies similar to our study.²⁶ In our study neuroblastoma was the most common mass. This difference may be due to the sample size and ethnic characteristics.

There are different illnesses in infants which may require surgical treatment.²⁷ Mediastinal tumors constitute a large percentage of thoracic lesions in which surgery is a treatment option. Emphysema, pulmonary cysts and hydatid cysts are other thoracic lesions which have specific presentations which can be cured via thoracotomy.¹⁴ In our study, emphysema and mediastinal mass was found in 4

patients each (6.7%), hydatid cysts in 2 patients (3.3%) and lung cysts in one patient (1.7%).

Since associated conditions in esophageal atresia have an important role in the patient's morbidity and mortality, early diagnosis and timely management of these conditions would improve the prognosis of these patients. We also studied the associated conditions in our research. Forty cases (66.7%) had no associated illness but the remaining 20 cases (33.3%) had associated anomalies such as imperforated anus in 5 cases (8.3%), patent ductus arteriosus and renal agenesis each in 3 cases (5%). Other associated malformations with their frequencies are collected in **Table 2**.

The limitations of our study were the lack of the patient's symptoms and their follow up after surgery. Also we recommend further study in the patient's survival rate after thoracotomy.

Conclusion

According to our study, type C esophageal atresia is the most common cause of thoracotomy in neonates. Congenital malformations are more common in neonates and mediastinal mass and infections are more common in older patients.

References

1. Kanngiesser P, Florian L, Gisela H, et al: Thoracic surgery in children. *European journal of Cardio-thoracic surgery* 2005;28(1):50-5.
2. Wyttenbach R, Vock P, Tschappeler H: Cross-sectional imaging with CT and/or MRI of pediatric chest tumors. *European radiology* 1998;8(6):1040-6.
3. Hancock BJ, Di Lorenzo M, Youssef S, et al: Childhood primary pulmonary neoplasms. *Journal of pediatric surgery* 1993;28(9):1133-6.
4. Cohen MC, Kaschula RO: Primary pulmonary tumors in childhood: a review of 31 years' experience and the literature. *Pediatric pulmonology* 1992;14(4):222-32.
5. Dishop MK, Kuruvilla S: Primary and metastatic lung tumors in the pediatric population: a review and 25-year experience at a large children's hospital. *Archives of pathology & laboratory medicine* 2008;132(7):1079-103.
6. Costa Junior Ada S, Perfeito JA, Forte V: Surgical treatment of 60 patients with pulmonary malformations: what have we learned? *Jornal brasileiro de pneumologia: publicacao oficial da Sociedade Brasileira de Pneumologia e Tisiologia* 2008;34(9):661-6.
7. Laberge JM, Puligandla P, Flageole H: Asymptomatic congenital lung malformations. *Seminars in pediatric surgery* 2005;14(1):16-33.
8. Eggli KD, Newman B: Nodules, masses, and pseudomasses in the pediatric lung. *Radiologic clinics of North America* 1993;31(3):651-66.

- 9 .Colon N, Schlegel C, Pietsch J, et al: Congenital lung anomalies: can we postpone resection? *Journal of pediatric surgery* 2012;47(1):87-92.
- 10 .Tseng YL, Wu MH, Lin MY, et al: Surgery for lung abscess in immunocompetent and immunocompromised children. *Journal of pediatric surgery* 2001;36(3):470-3.
- 11 .Sistonen SJ, Pakarinen MP, Rintala RJ: Long-term results of esophageal atresia: Helsinki experience and review of literature. *Pediatric surgery international* 2011;27(11):1141.
- 12 .Margain L, Perez-Etchepare E, Varlet F, et al: Lower esophageal banding in extremely low birth weight infants with esophageal atresia and tracheoesophageal fistula is a life saving practice followed by a successful delayed primary thoracoscopy reconstruction. *Journal of Pediatric Surgery* 2015;50(3):489-92.
- 13 .Tavalla M, Akhlaghi L, Ourmazdi H, et al: Using Dot-ELISA method to study the prevalence of human hydatidosis in people referred to blood transfusion center in Tehran, 2005-2006. *Razi Journal of Medical Sciences* 2010;16(67):52-8.
- 14 .Delshad S, Farhood P, Nasiri S: Esophageal Replacement in Children: 18 Case Reports from Ali-Asghar Hospital. *Razi Journal of Medical Sciences* 2006;13(51):97-104.
- 15 .Brihaye P, Delpierre I, De Villé A, et al: Comprehensive management of congenital choanal atresia. *International Journal of Pediatric Otorhinolaryngology* 2017;98:9-18.
- 16 .MacKinlay GA: Esophageal atresia surgery in the 21st century. *Seminars in Pediatric Surgery* 2009;18(1):20-2.
- 17 .Gupta DK, Sharma S: Esophageal atresia: the total care in a high-risk population. *Seminars in Pediatric Surgery* 2008;17(4):236-43.
- 18 .Schmidt A, Obermayr F, Lieber J, et al: Outcome of primary repair in extremely and very low-birth-weight infants with esophageal atresia/distal tracheoesophageal fistula. *Journal of Pediatric Surgery* 2017;52(10):1567-70.
- 19 .Polonkai E, Nagy A, Csízy I, et al: Pyloric atresia associated with Dieulafoy lesion and gastric dysmotility in a neonate. *Journal of Pediatric Surgery* 2011;46(10):e19-e23.
- 20 .Pham NMH, Alexander PMA, Chow CW, et al: Anterior Mediastinal Lymphangioma in an Infant: Diagnosis and Surgical Management. *Heart, Lung and Circulation* 2012;21(5):289-91.
- 21 .Haller Jr JA, Shermeta DW, Donahoo JS, et al: Life-Threatening Respiratory Distress from Mediastinal Masses in Infants. *The Annals of Thoracic Surgery* 1975;19(4):364-70.
- 22 .Gupta S, Prasad G, Kundu R, et al: On table extubation after emergency thoracotomy for mediastinal mass in a neonate. *Journal of Clinical Anesthesia* 1975;19(4):364-70.
- 23 .Zhurilo I, Kononuchenko V, Litovka V, et al: Mediastinal tumors and tumor-like formations in children. *Klinichna khirurgiia/ Ministerstvo okhorony zdorov'ia Ukrainy, Naukove tovarystvo khirurhiv Ukrainy* 2001(9):44-7.
- 24 .Haglti Z, Bagheri R: The study of 22 cases of mediastinal tumors in children with acute respiratory manifestation 2005.
- 25 .Kuleva S, Kolygin B: Malignant mediastinal neoplasms in children. *Vestnik khirurgii imeni II Grekova* 2003;162(2):46-8.
- 26 .Lam J, Chui C, Jacobsen A, et al: When is a mediastinal mass critical in a child? An analysis of 29 patients. *Pediatric surgery international* 2004;20(3):180-4.
- 27 .Li G, Su J, Fan X, et al: Safety and Efficacy of Ventricular Septal Defect Repair Using a Cosmetic Shorter Right Lateral Thoracotomy on Infants Weighing Less than 5 kg. *Heart, Lung and Circulation* 2015;24(9):898-904.