

ORIGINAL RESEARCH ARTICLE

Toxicopathological examinations after repeated intraperitoneal administration of silver nanoparticles in the Wistar rat model

Ehsan Zayerzadeh^{1*}, Meisam Shabani², Mohammad Kazem Koohi³

¹ Department of Biology, Faculty of Food Industry and Agriculture, Standard Research Institute, Karaj, Iran.

² Faculty of Chemistry and Petrochemical Engineering, Standard Research Institute, Karaj, Iran

³ Department of Basic Sciences, Faculty of Veterinary Medicine, University of Tehran, Tehran, Iran.

ARTICLE INFO

Article History:

Received 21 November 2017

Accepted 4 January 2018

Published 15 February 2018

Keywords:

In Vivo

Nanosilver Particles

Pathology

Toxicity

Wistar Rats

ABSTRACT

Objective(s): Due to wide range of medical applications as bactericidal agents, nanosilver particles (NSPs) are manufactured worldwide in large quantities. However, potential toxicity impacts of NSPs in humans and animals still remain poorly understood. The objective of this study was to investigate clinical observations, mortality and pathological changes in rats following intraperitoneal administration of different doses of NSPs.

Methods: In this study, rats were administered intraperitoneally over a period of 5 days with repeated doses at different dose levels (20, 80, 320 mg/kg) of NSPs (20 nm). Rats were euthanized 14 days after the treatment. Animal mortality, clinical sings, food intake and body weight were evaluated. Histopathology was performed on heart, lung, liver and kidneys of experimented animals.

Results: There was a significant decrease in the body weight of animals in high dose group following fourteen days of exposure. Also, there was significant decrease in food intake during the treatment period in high dose group. Histological tissue sections indicated that NSPs induced multi-organ pathological lesions including severe alveolar edema, hemorrhage and inflammation in lungs, myocytolysis, congestion and edema in heart, inflammation and congestion in kidney and liver.

Conclusions: The results obtained two weeks following intraperitoneal injection indicate that the administration of high doses of NSPs could induce histopathological complications in heart, lung, liver and kidneys in rats. No significant pathological effects were observed in low and intermediate doses. More toxicological investigations are needed in relation of the application of NSPs with their potential threat as a medical tool.

How to cite this article

Zayerzadeh E, Shabani M, Koohi MK. Toxicopathological examinations after repeated intraperitoneal administration of silver nanoparticles in the Wistar rat model. *Nanomed Res J*, 2018; 3(1): 51-57. DOI: 10.22034/nmrj.2018.01.008

INTRODUCTION

The antibacterial properties of nanosilver particles (NSPs) have resulted in the widespread use of these nanoparticles in cosmetics, clothes, rinse, nursing bottles, filters, kitchen utensils, toys, and even in food products. They are also used in medical products, including wound dressings, cardiac catheters, surgical instruments and bone prosthesis. These nanoparticles have unique chemical, physical and biological properties because of high surface

area to volume ratio [1-7]. These properties of NSPs may induce unique bioactivity and adverse effects to human health. These nanoparticles with regard to their applications were administered with different routes such as oral, intraperitoneal, dermal and intravenous [8-10]. Hence, human and animal exposure to NSPs is inevitable. This is a general concern in nanotoxicology about these nanoparticles and more extensive researches are required for producing meaningful results

* Corresponding Author Email: zayerzadeh@standard.ac.ir

for supporting NSPs safety. However, despite such widespread use of these products, potential toxicity of NSPs still remains controversial. The most of toxicity investigations on NSPs have been done on bacteria, cell lines and non-mammalian animal species. These *in vitro* investigations disclosed clear mechanisms of NSPs toxicity, such as ROS production, with subsequent oxidative stress; interaction with cellular proteins and enzymes inducing some complications [11]. These mechanisms finally lead to cytokine generation, cellular damage, and finally apoptosis or necrosis [12]. However, the *in vivo* toxicity of NSPs has been analyzed in a wide range of investigations. Previous studies demonstrated that NSPs may have adverse effects on the lungs, liver, intestine and immune systems, following single or repeated administration with various routes of exposure [13-15]. In contrast, some other studies indicated no relevant toxic effects in these organs [16-19]. These contradictory findings may depend on the high variability of the tested NSPs properties such as source, size, dispersion state and concentration. In addition, the animal species, sex, age, and different experimental designs may have affected on results of the investigation [17]. However, there is still a lack of consistent and reliable data about pathological complications that may be induced by different sizes of NSPs in laboratory animals. Up to our knowledge, there is no study about toxicopathological effects of this size (20 nm) of NSPs that was produced in Iran in the Wistar rat model with intraperitoneal injection route. Hence, in the present study here, we characterized NSPs before use and evaluated clinical observations,

mortality and pathotoxicological complications of NSPs following intraperitoneal injection at different doses in experimentally rats.

MATERIALS AND METHODS

Nanoparticles

Nanosilver particles produced by the chemical vapor deposition (CVD) method, with an average diameter 20 nm (purity = 99.99%) were purchased from Iranian Nanomaterials Pishgaman Company and used in the present study without further purification or sieving (Fig. 1).

Animals and housing conditions

Twenty-four male Wistar rats were used in this study. They were obtained from Razi Vaccine and Serum Research Institute and allowed to acclimate for one week before treatment. They were maintained in a controlled atmosphere with a 12 hour light/dark cycle, a temperature of $22 \pm 3^\circ\text{C}$ and $60 \pm 10\%$ relative humidity. Sterile standard pellet diet for the rats and fresh tap water were available *ad libitum*. All animals were taken care in according to the advice of the animal care committee of the Tehran University based on the 'Guide for Care and Use of Laboratory Animals' (NIH US publication 86-23, revised 1985)

Experimental design

Nanosilver particles were suspended in a sterile saline solution containing 1% Tween-80 and were dispersed about 30 min by an ultrasonic liquid processor at 4°C and 30% amplitude to read pulses. Twenty-four rats were randomly divided into four groups, six for each group. One group was selected




Fig. 1. Scanning electron microscope (SEM) image of NSPs.

as the control group, and the rest groups were used as experimental groups. Rats were injected intraperitoneally over a period of 5 days with repeated doses at different dose levels (20, 80, 320 mg/kg) of NSPs.

Histopathology

Organs including heart, lungs, liver and kidneys extracted from animals were immersed in 10% buffered formalin for two days. Then, they transversely sectioned in 3–4 mm slices. Samples were dehydrated in a graded series of alcohol and xylene. After that, they were embedded in paraffin. Multiple slices were produced and stained by hematoxylin and eosin stains. Sections were observed and photographed by a light microscope (Nikon E 200 Japan).

Statistical Analyses

All data are expressed as mean \pm SD. The mean of all parameters between groups was compared using the Student's t-test. Data were analyzed using the SPSS software (version 19) and a $p < 0.05$ is considered statistically significant.

RESULTS AND DISCUSSION

Silver nanoparticles have many applications in diverse biotechnology fields. These nanoparticles have extensive antibacterial effects on a range of bacteria and antibiotic-resistant bacteria strains [20]. Antibacterial efficacy of NSPs depends on their size and concentration. Nanosilver is also a potent antifungal agent against an extensive spectrum of fungi [21]. NSPs are also an antiviral agent [22, 23]. NSPs also display anti-inflammatory properties in both animal models and in the clinic [24]. In contrast with NSPs benefits, they may have potential toxicities at some concentrations and can induce different health problems if used incorrectly. The toxicological database and the potential for probable adverse effects in humans and the environment have not yet been established

for NSPs. Therefore, it is so important to address the biosafety of NSPs in human and animal health. In our study, some indexes including eating, drinking and physical activity were decreased in the 320 mg/kg dose group. However, mortality was not observed in any groups. The behavior of the animals in the other groups was normal throughout the investigation. Body weight of the fourth group of experimented animals with NSPs was significantly decreased in comparison with control group. On the other hand, body weight of the second and third groups of experimented rats with NSPs did not show any significant change in comparison with control group (table 1). The histological examination of the heart, lungs, liver and kidneys in the control group following treatment revealed no observable changes. In the fourth group of animals, intraperitoneal administration of NSPs induced multi-organs histopathological lesions such as severe alveolar edema, hemorrhage and inflammation in lungs, myocytolysis, congestion and edema in heart, congestion and inflammation in kidneys and liver. However, there were not observed any significant histopathological abnormalities in the second and third groups (Fig. 2). Two factors can induce pulmonary edema, including a cardiogenic factor due to dysfunction of the left ventricle and a non-cardiogenic factor related to inflammatory response. In agreement with our results, Sarhan and Hussein reported intraperitoneal injection of silver nanoparticles (2000 mg/kg) in albino rats induced pathological complications such as renal tubules vacuolization and mitochondrial destruction in kidneys and swollen hepatocytes and accumulation of fat globules in the nucleoplasm and cytoplasm in liver [25]. Previous epidemiological and nanotoxicology studies demonstrated that NSPs can transcytose epithelial/endothelial cells into the systemic circulation to reach target tissues such as liver and kidney. Findings of these investigations also demonstrated that NSPs are capable of generating

Table 1. Body weight following intraperitoneal injection of NSPs (20, 80, 320 mg/kg) in rats.

Study Groups	Initial body weight (g)	Final body weight (g)	Body weight difference (g)
First	201 \pm 22	248 \pm 23	47
Second	198 \pm 21	247 \pm 22	49
Third	203 \pm 20	251 \pm 24	48
Fourth	199 \pm 19	223 \pm 21*	24

Mean values (standard deviation) are shown for the six animals in each group, *significant difference ($p < 0.05$) in comparison with control (first) group.

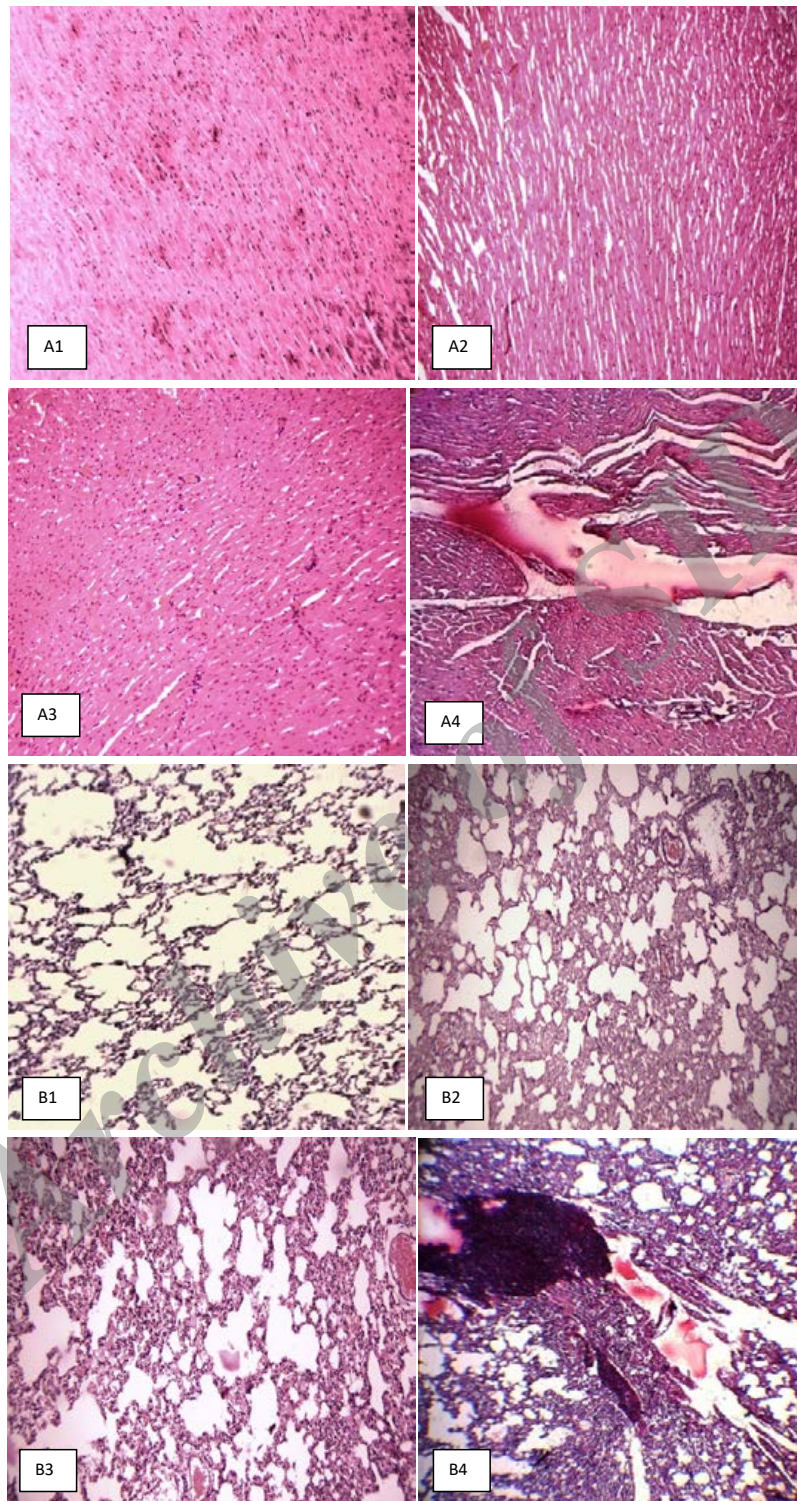


Fig. 2. Photomicrographs of heart, lung, liver and kidney sections obtained from rats exposed to different concentrations of NSPs. (A1, B1, C1, D1) control rats , (A2, B2, C2, D2) rats received 20 mg/kg of NSPs, (A3, B3, C3, D3) rats received 80 mg/kg of NSPs and (A4, B4, C4, D4) rats received 320 mg/kg of NSPs. Panels (A1, A2, A3): normal heart, A4: congestion, myocytolysis and edema in heart. Panels (B1, B2, B3): normal lung, B4: severe alveolar edema, hemorrhage and inflammation in lungs, Panels (C1, C2, C3): normal liver, C4: congestion and inflammation in liver. Panels (D1, D2, D3): normal kidney, D4: congestion and inflammation in kidney. (Staining with hematoxylin and eosin). Magnification: 100 x for panels.

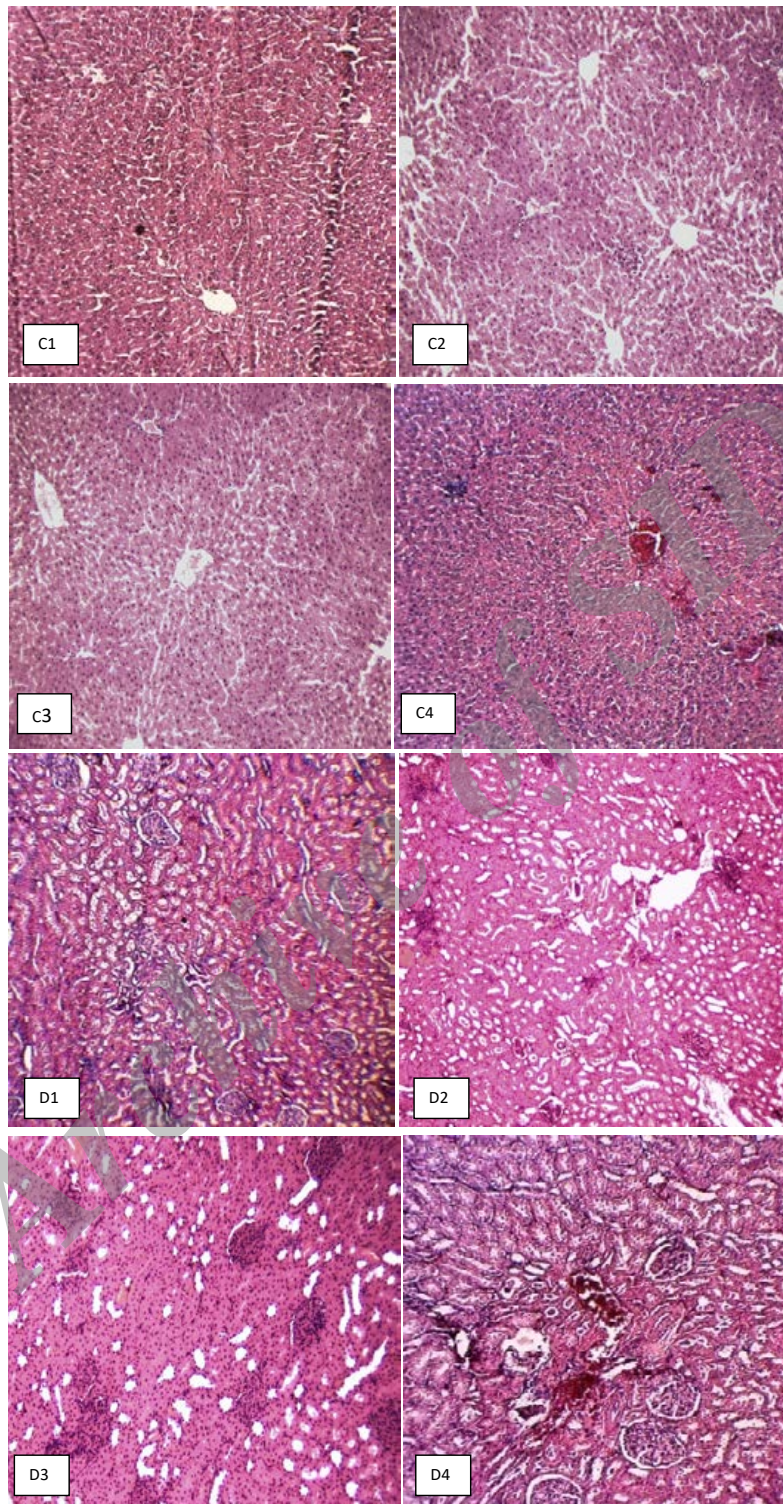


Fig. 2. Photomicrographs of heart, lung, liver and kidney sections obtained from rats exposed to different concentrations of NSPs. (A1, B1, C1, D1) control rats , (A2, B2, C2, D2) rats received 20 mg/kg of NSPs, (A3, B3, C3, D3) rats received 80 mg/kg of NSPs and (A4, B4, C4, D4) rats received 320 mg/kg of NSPs. Panels (A1, A2, A3): normal heart, A4: congestion, myocytolysis and edema in heart. Panels (B1, B2, B3): normal lung, B4: severe alveolar edema, hemorrhage and inflammation in lungs, Panels (C1, C2, C3): normal liver, C4: congestion and inflammation in liver. Panels (D1, D2, D3): normal kidney, D4: congestion and inflammation in kidney. (Staining with hematoxylin and eosin). Magnification: 100 x for panels.

reactive oxygen species, which have been related to inflammatory lung diseases and cardiac complications [26]. Sung et al also demonstrated that inhaled silver nanoparticles induced lung inflammation. They also reported that the target organs for silver nanoparticles were the liver and lungs in a subchronic inhalation investigation [27]. These results are consistent with our results. Inhalation and instillation experiments in rats demonstrated that low concentration of nanosilver appeared in the lung and was finally entered to the blood and other organs including heart, liver and kidney [28]. Myocytolysis is a specific pathologic marker of congestive heart failure without relation to coronary blood flow, myocardial hypoxia and myocardial fibrosis [29]. Previous study has shown that carbon nanotubes can also induce histopathological changes in heart and lungs following oral administration in rats [30]. Findings of our investigation have shown no NSPs accumulation in heart, liver, lungs and kidneys of experimented animals. In a recent oral toxicity study of rats, in contrast with our results, Kim et al discovered that silver nanoparticles appeared in blood, liver, lungs, kidneys, stomach, testes, and brain at different doses exposure after 28 days [14]. Inflammation and congestion, in the kidneys and livers of animals in the fourth group of our study were observed. In consistent with our findings, Recordati et al reported administration of NSPs to mice was induced severe hepatocellular necrosis and hemorrhage, multifocal peribiliary micro hemorrhages, occasional portal vein endothelial damage. In this study, periportal coagulative necrosis, scattered hepatic single cell necrosis, and gall bladder severe mural and intraluminal gall bladder hemorrhage were observed following 40 nm NSPs exposure only in one out of six treated mice. No relevant pathological complications were seen in examined organs of NSPs -treated mice, and control mice [31]. There is a hypothesis that cardiac impacts are an outcome of pulmonary inflammation, which interferes with coagulability and stability of atheromatous plaques. The NSPs may also have impacts on cardiac physiology if they enter to the bloodstream. The possibility of transferring of particles by blood to the heart can induce cardiac direct impacts [32-34] Combined with our findings; it can be concluded NSPs can induce heart and lung injury via directly or indirectly (oxidative stress) mechanisms [35].

CONCLUSION

The toxicity of NSPs is a controversial issue in the nanotoxicology science. In summary, two weeks after five days intraperitoneal injection of different doses of NSPs, clinical observations, animal mortality and histopathology were evaluated. Our study demonstrated that five days intraperitoneal injection of 320 mg/kg NSPs induced clinical abnormalities including decreased body weight, decreased food and water intake and decreased physical activity but no mortality in the Wistar rats. NSPs injection also induced histopathological complications such as hemorrhage and inflammation in vital organs. However, NSPs high doses may be toxic for humans and animals. However, more nanotoxicological investigations need to clear essential mechanisms of pathological changes following exposure with NSPs.

ACKNOWLEDGEMENT

This work was financed by Standard Research Institute.

CONFLICT OF INTEREST

The authors declare that there are no conflicts of interest regarding the publication of this manuscript.

REFERENCES

1. Sondi I, Salopek-Sondi B. Silver nanoparticles as antimicrobial agent: a case study on *E. coli* as a model for Gram-negative bacteria. *Journal of Colloid and Interface Science*. 2004;275(1):177-82.
2. Cho K-H, Park J-E, Osaka T, Park S-G. The study of antimicrobial activity and preservative effects of nanosilver ingredient. *Electrochimica Acta*. 2005;51(5):956-60.
3. Li P, Li J, Wu C, Wu Q, Li J. Synergistic antibacterial effects of β -lactam antibiotic combined with silver nanoparticles. *Nanotechnology*. 2005;16(9):1912-7.
4. Morones JR, Elechiguerra JL, Camacho A, Holt K, Kouri JB, Ramirez JT, et al. The bactericidal effect of silver nanoparticles. *Nanotechnology*. 2005;16(10):2346-53.
5. Ji JH, Bae G-N, Yun SH, Jung JH, Noh HS, Kim SS. Evaluation of a Silver Nanoparticle Generator Using a Small Ceramic Heater for Inactivation of *S. epidermidis* Bioaerosols. *Aerosol Science and Technology*. 2007;41(8):786-93.
6. Maynard AD: *Nanotechnology: A Research Strategy for Addressing Risk* Washington DC: Wood row Wilson International Center for Scholars 2006.
7. KISTI (Korea Institute of Science and Technology Information): The present status of Korean nanotechnology industrialization. *Nano Weekly* 210 Seoul, Korea: KISTI 2006.
8. Chen X, Schluesener HJ. Nanosilver: A nanoproduct in medical application. *Toxicology Letters*. 2008;176(1):1-12.
9. Samuel U, Guggenbichler JP. Prevention of catheter-related infections: the potential of a new nano-silver impregnated

- catheter. *International Journal of Antimicrobial Agents*. 2004;23:75-8.
10. Ahamed M, ALSalhi MS, Siddiqui MKJ. Silver nanoparticle applications and human health. *Clinica Chimica Acta*. 2010;411(23-24):1841-8.
 11. Völker C, Oetken M, Oehlmann J. The biological effects and possible modes of action of nanosilver. *Rev Environ Contam Toxicol*. 2013; 223: 81–106.
 12. Hsin YH, Chen CF, Huang S, Shih TS, Lai PS, Chueh PJ. The apoptotic effect of nanosilver is mediated by a ROS- and JNK-dependent mechanism involving the mitochondrial pathway in NIH3T3 cells. *Toxicol Lett*. 2008;179:130–9.
 13. Park E-J, Bae E, Yi J, Kim Y, Choi K, Lee SH, *et al*. Repeated-dose toxicity and inflammatory responses in mice by oral administration of silver nanoparticles. *Environmental Toxicology and Pharmacology*. 2010;30(2):162-8.
 14. De Jong WH, Van Der Ven LTM, Sleijffers A, Park MVDZ, Jansen EHJM, Van Loveren H, *et al*. Systemic and immunotoxicity of silver nanoparticles in an intravenous 28 days repeated dose toxicity study in rats. *Biomaterials*. 2013;34(33):8333-43.
 15. Shahare B, Yashpal M. Toxic effects of repeated oral exposure of silver nanoparticles on small intestine mucosa of mice. *Toxicology Mechanisms and Methods*. 2013;23(3):161-7.
 16. Stebounova LV, Adamcakova-Dodd A, Kim J, Park H, O'Shaughnessy PT, Grassian VH, *et al*. Nanosilver induces minimal lung toxicity or inflammation in a subacute murine inhalation model. *Particle and Fibre Toxicology*. 2011;8(1):5.
 17. van der Zande M, Vandebriel RJ, Van Doren E, Kramer E, Herrera Rivera Z, Serrano-Rojero CS, *et al*. Distribution, Elimination, and Toxicity of Silver Nanoparticles and Silver Ions in Rats after 28-Day Oral Exposure. *ACS Nano*. 2012;6(8):7427-42.
 18. Hadrup N, Loeschner K, Bergström A, Wilcks A, Gao X, Vogel U, *et al*. Subacute oral toxicity investigation of nanoparticulate and ionic silver in rats. *Arch Toxicol*. 2012;86:543–551.
 19. Gaiser BK, Fernandes TF, Jepson MA, Lead JR, Tyler CR, Baalousha M, *et al*. Interspecies comparisons on the uptake and toxicity of silver and cerium dioxide nanoparticles. *Environ Toxicol Chem*. 2012;31:144–154.
 20. Kim JS, Kuk E, Yu KN, Kim J-H, Park SJ, Lee HJ, *et al*. Antimicrobial effects of silver nanoparticles. *Nanomedicine: Nanotechnology, Biology and Medicine*. 2007;3(1):95-101.
 21. Kim KJ, Sung WS, Moon SK, Choi JS, Kim JG, Lee DG. Antifungal effect of silver nanoparticles on dermatophytes. *J Microbiol Biotechnol*. 2008;18(8):1482–1484.
 22. Sun RW-Y, Chen R, Chung NPY, Ho C-M, Lin C-LS, Che C-M. Silver nanoparticles fabricated in Hepes buffer exhibit cytoprotective activities toward HIV-1 infected cells. *Chemical Communications*. 2005(40):5059.
 23. Lu L, Sun RW, Chen R, *et al*. Silver nanoparticles inhibit hepatitis B virus replication. *Antivir Ther*. 2008;13 (2): 253–262.
 24. Nadworny PL, Wang J, Tredget EE, Burrell RE. Anti-inflammatory activity of nanocrystalline silver in a porcine contact dermatitis model. *Nanomedicine: Nanotechnology, Biology and Medicine*. 2008;4(3):241-51.
 25. Hussein R, Sarhan O. Effects of intraperitoneally injected silver nanoparticles on histological structures and blood parameters in the albino rat. *International Journal of Nanomedicine*. 2014:1505.
 26. Johnston HJ, Hutchison G, Christensen FM, Peters S, Hankin S, Stone V. A review of the in vivo and in vitro toxicity of silver and gold particulates: Particle attributes and biological mechanisms responsible for the observed toxicity. *Critical Reviews in Toxicology*. 2010;40(4):328-46.
 27. Sung JH, Ji JH, Park JD, Yoon JU, Kim DS, Jeon KS, Song MY, Jeong J, Han BS, Han JH, Chung YH, Chang HK, Lee JH, Cho MH, Kelman BJ, Yu IJ. Subchronic inhalation toxicity of silver nanoparticles. *Toxicol Sci*. 2009; 108(2):452-61.
 28. Takenaka S, Karg E, Roth C, Schulz H, Ziesenis A, Heinzmann U, *et al*. Pulmonary and Systemic Distribution of Inhaled Ultrafine Silver Particles in Rats. *Environmental Health Perspectives*. 2001;109(s4):547-51.
 29. Turillazzi E, Baroldi G, Silver MD, Parolini M, Pomara C, Fineschi V. A systematic study of a myocardial lesion: Colliquative myocytolysis. *International Journal of Cardiology*. 2005;104(2):152-7.
 30. Zayerzadeh E, Fardipour A, Shabani M, Koohi MK. Evaluation of Cardiopulmonary Toxicity Following Oral Administration of Multi-walled Carbon Nanotubes in Wistar Rats. *Nanomed Res J*. 2016; 1(1): 47-51.
 31. Recordati C, De Maglie M, Bianchessi S, Argenti S, Cella C, Mattiello S, Cubadda F, *et al*. Tissue distribution and acute toxicity of silver after single intravenous administration in mice: nano-specific and size-dependent effects. *Part Fibre Toxicol*. 2016; 13: 12.
 32. Evans S-A, Al-Mosawi A, Adams RA, BéruBé KA. Inflammation, Edema, and Peripheral Blood Changes in Lung-Compromised Rats after Instillation with Combustion-Derived and Manufactured Nanoparticles. *Experimental Lung Research*. 2006;32(8):363-78.
 33. Nemmar A. Passage of Inhaled Particles Into the Blood Circulation in Humans. *Circulation*. 2002;105(4):411-4.
 34. Nemmar A. Possible mechanisms of the cardiovascular effects of inhaled particles: systemic translocation and prothrombotic effects. *Toxicology Letters*. 2004;149(1-3):243-53.
 35. Xing M, Ge L, Wang M, Li Q, Li X, Ouyang J. Nanosilver particles in medical applications: synthesis, performance, and toxicity. *International Journal of Nanomedicine*. 2014:2399.