



# Predictors of Kyphosis Progression after the Conservative Treatment of Osteoporotic Vertebral Compression Fracture

Hassan Ghandhari,<sup>1</sup> Ebrahim Ameri,<sup>1</sup> Mozhdeh Zabihyeganeh,<sup>1</sup> Mehdi Mohammadpour,<sup>1</sup> and Javad Aghamohammadi<sup>1,\*</sup>

<sup>1</sup>Bone and Joint Reconstruction Research Center, Shafa Orthopedic Hospital, Iran University of Medical Sciences, Tehran, IR Iran

\*Corresponding author: Javad Aghamohammadi, Shafa Orthopedic Hospital, Baharestan Square, Tehran, IR Iran. Tel: +98-21335420008, Fax: +98-2133542020, E-mail: javad.aghamohammadi67@gmail.com

Received 2018 April 28; Revised 2018 May 19; Accepted 2018 May 21.

## Abstract

**Background:** In the patients with osteoporotic vertebral compression fracture (OVCF) treated conservatively, significant progression of the local kyphosis due to an impaired healing leads to reduction in the quality of life. Thus, it is of critical value to identify the predictors of this major complication.

**Objectives:** The current prospective cohort study aimed at evaluating the predictors of progression in the local kyphosis in a series of patients with acute OVCF undergoing conservative treatment.

**Methods:** Eligible patients with OVCF were identified and local kyphosis progression was evaluated after four months of conservative treatment. Demographic characteristics such as gender, age, and body mass index (BMI), as well as radiographic characteristics such as the location of fracture, bone mineral density (BMD), and serum 25 (OH) vitamin D level were compared between the patients with local kyphosis angle (LKA) progressed  $\geq 30^\circ$  (group A) and the patients with LKA remained  $< 30^\circ$  (group B).

**Results:** From a total of 60 patients with OVCF, LKA progressed  $\geq 30^\circ$  in 19 patients (31.7%). The mean change of LKA was  $16.2^\circ \pm 7.2^\circ$  in group A and  $1.92^\circ \pm 2.7^\circ$  in group B ( $P < 0.001$ ). Higher age, lower BMI, and lower spinal BMD were significantly associated with LKA progression  $\geq 30^\circ$  ( $P = 0.013$ ,  $P < 0.001$ , and  $P = 0.037$ , respectively). The involvement of thoracolumbar junction (T11-L1) was more frequent in group A ( $P = 0.049$ ). Anterior cortical wall fracture was more frequent in group A as well ( $P = 0.007$ ). After adjustment of confounding factors, the association of LKA progression with the age, BMI, and the level of fractured vertebra still remained significant.

**Conclusions:** Significant progression of LKA following conservative treatment of OVCF is correlated with the level of fractured vertebra, BMI, and age of the patients. These factors could be used to select patients most benefit from conservative treatment.

**Keywords:** Osteoporotic Vertebral Compression Fracture, Conservative Treatment, Kyphosis, Risk Factor

## 1. Background

Osteoporotic vertebral compression fracture (OVCF) is considered as the most common fragility fracture (1). The incidence of OVCF increases as the population ages (2).

Management of OVCF includes conservative or surgical interventions. Surgical treatment of OVCF consists of open or minimally invasive surgery (balloon kyphoplasty and vertebroplasty) (3). Open surgery usually entails extensive dissections and anesthesia, which put the patients at risk of threatening conditions particularly in the elderly (4). Kyphoplasty and vertebroplasty can be also complicated with the fracture of sternum, ribs, transverse process, and pedicles. Leakage of cement into the spinal canal and foraminal area might be added to these complications (5, 6).

In this scenario, conservative treatment is considered as the mainstay of treatment in a selected group of patients (7). Even so, healing impairs in one-third of the patients following the conservative management of acute OVCF. In this subset of patients, progressive kyphotic deformity may occur (8). As a result of this deformity, the knees bend and the pelvis tilt moves forward to counteract the forward bend of the spine, which gives rise to muscle spasm and fatigue, reduction in gait velocity, gait disturbances, and consequently an increased risk of falling down and additional fractures (9). Kyphotic deformity can also compress the abdomen, resulting in a loss of appetite, distension, eructation, and constipation (10). Furthermore, kyphotic deformity in the thoracic spine reduces the pulmonary function, especially in patients with co-existing

lung disease (11).

Due to a high rate of complications following the surgical intervention, in addition to economic burden of osteoporotic fracture for the affected society, it is of critical value to identify the patients most benefit from conservative treatment.

For this purpose, attempts are made to determine the role of potential factors affecting the results of conservative treatment in such patients.

## 2. Objectives

Since progressive kyphotic deformity is one of the most significant complications of conservatively treated OVCF, the current study aimed at prospectively evaluating the progression of local kyphosis in a cohort study on patients with OVCF undergoing conservative treatment, and comparing the characteristics of patients that developed significant segmental kyphotic deformity ( $\geq 30^\circ$ ) with those of the ones that did not.

## 3. Methods

In the current prospective study, patients with acute OVCF (with the pattern of compression wedge fracture) admitted to Shafa hospital from May 2016 to December 2017 were assessed for inclusion criteria. The diagnosis of OVCF was confirmed based on the history of injury, as well as physical and radiologic examinations. Inclusion criteria consisted of: age above 50 years, acute phase of injury (less than three weeks from the initiation of back pain following minor trauma such as lifting, forward bending, sitting, and sneezing or without trauma), conservative treatment, and a follow-up period of four months. Exclusion criteria consisted of: the presence of neurologic deficit, pathologic fracture, baseline Cobb angle of  $\geq 30^\circ$ , involvement of posterior ligament, lack of compliance with brace, and history of other interventions such as surgery and osteoporosis treatment. From a total of 98 cases with acute OVCF identified as eligible to be included in the study, 13 patients previously received different treatments (bisphosphonates or teriparatide) were excluded from the study. Moreover, continuous pain led to the surgical intervention in two patients even lacking the progression of kyphosis to  $\geq 30^\circ$ . These patients were excluded from the study as well. The remaining 83 patients were prospectively followed. Loss of adequate follow-up led to the further exclusion of 23 patients. Consequently, 60 patients were evaluated at the final analysis.

Clinical and demographic characteristics of patients including gender, age, history of OVCF, and body mass index (BMI) were recorded at the initiation of the study. Plain

radiograph, bone mineral density (BMD), magnetic resonance imaging (MRI), computed tomography (CT) scanning, and test of blood 25 (OH) vitamin D level were performed on all patients in the beginning of the study as well. Baseline local kyphosis angle (LKA) was measured using the Cobb method between superior and inferior vertebra of affected level on standing lateral radiograph of affected vertebra (Figure 1). OVCF was classified as: superior endplate, inferior endplate, and anterior cortical wall fracture (Figure 2).

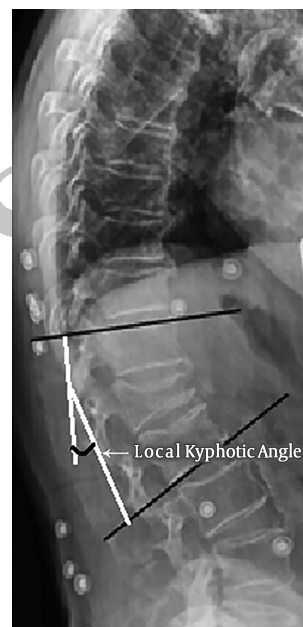

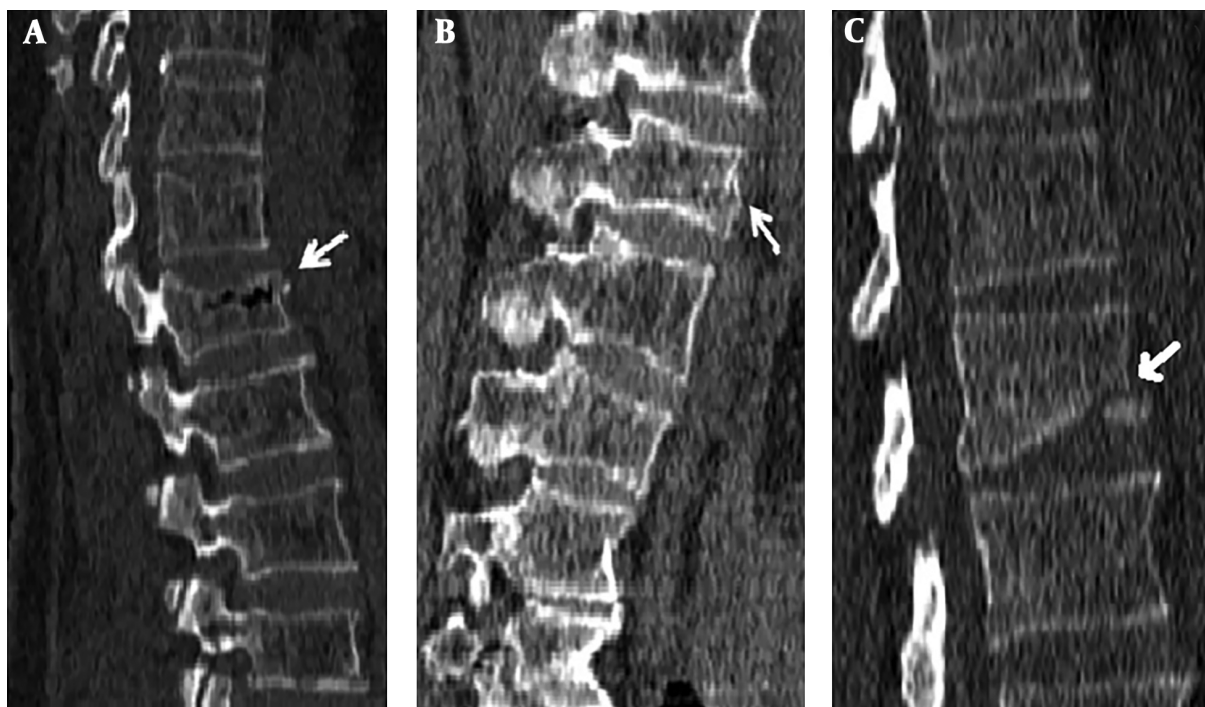
Figure 1. Measurement of local kyphosis, using the Cobb method between superior and inferior vertebrae of the affected vertebra

All patients received conservative treatment including analgesic drug therapy (acetaminophen 500 mg tablets, twice daily), calcium-D supplement (orally, daily), and back brace (Jewett brace). The indications for conservative management of OVCF were initial kyphosis of  $< 30^\circ$  and intact posterior ligament.

Kyphosis progression was monitored on the standing lateral spine radiography at the week 2 and monthly afterwards (Figure 3). At the 4th month of follow-up, LKA was re-assessed using the same method. The clinical, demographic, laboratory, and radiographic characteristics of patients with LKA progressed to  $\geq 30^\circ$  (group A) were compared with those of the patients with LKA  $< 30^\circ$  (group B).

The current study was approved by institutional review board of the local university and written consent was obtained from patients before enrollment.

Statistical analysis



**Figure 2.** Classification of OVCF based on its location on the vertebra: (A) Superior end-plate fracture; (B) Anterior cortical wall fracture; (C) Inferior end-plate fracture

SPSS version 16 was used for all statistical evaluations. Descriptive statistics were expressed as mean  $\pm$  standard deviations (SD) or number and percentage. Mean differences of variables between the two groups were assessed using independent samples t-test or the Mann-Whitney U test. Chi-square test was used to determine the significant association between the two categorical variables. Potential correlations were evaluated using the Pearson or the Spearman correlation coefficient test. In order to control the effect of potential confounders, independent variables that had a significant association with kyphosis severity were included in a logistic regression model. P-values  $< 0.05$  were regarded significant.

#### 4. Results

From a total of 60 patients with OVCF, LKA progressed to  $\geq 30^\circ$  in 19 patients (group A) and remained below the  $30^\circ$  in the remaining 41 patients (group B) after four months. The thoracolumbar junction (T11-L1) was the most common location of OVCF in the current study population, primarily T12 and L1 in group A and B, respectively. The characteristics of the two study groups are compared in Table 1.

In group A, the mean baseline LKA was  $19^\circ \pm 7^\circ$  (ranging from  $5^\circ$  to  $27^\circ$ ), which progressed to  $35.6^\circ \pm 3.2^\circ$  at the final

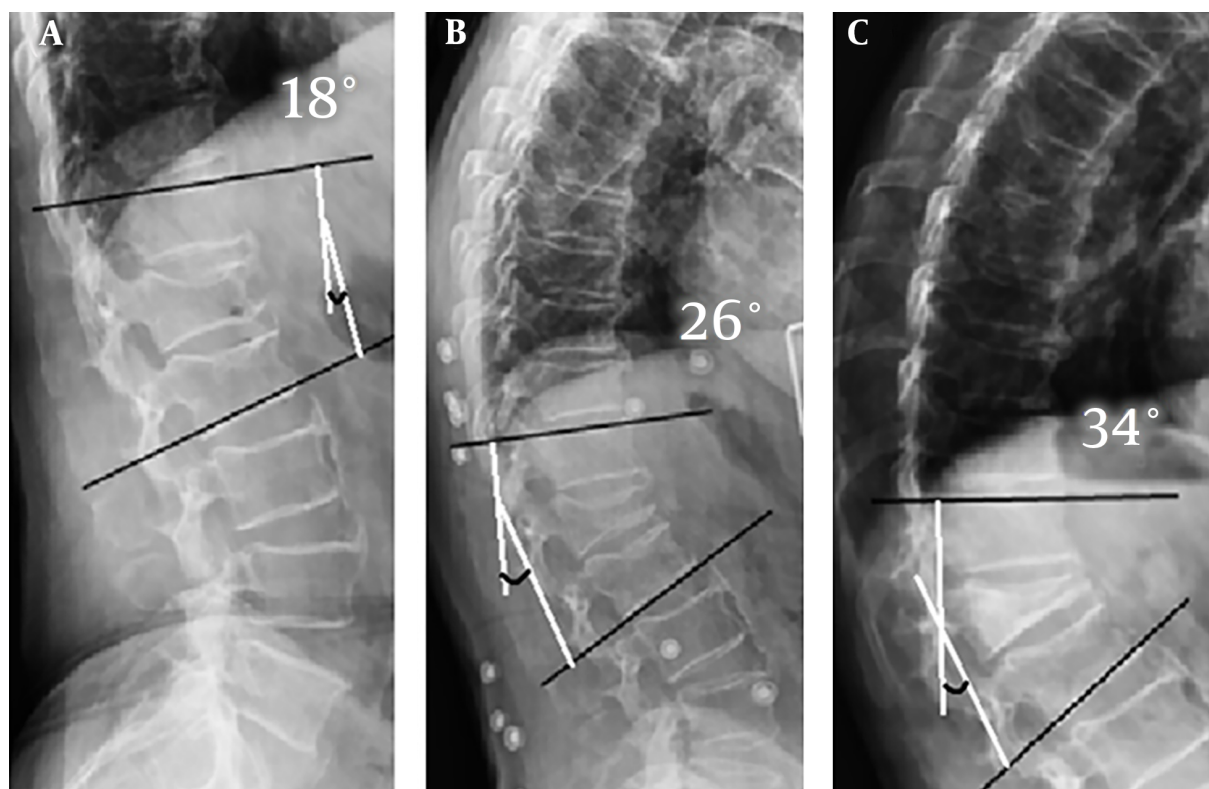
evaluation. In group B, the mean baseline LKA was  $8.2^\circ \pm 6.9^\circ$  and progressed to  $10.2^\circ \pm 6.9^\circ$  at the final assessment. The amount of LKA progression was significantly different in the two study groups ( $P < 0.001$ ).

A remarkable difference was observed between the mean age of the two study groups; therefore, the mean age of the patients was 8.3 years higher in group A ( $P = 0.013$ ). A significant correlation was also observed between the age of the patients and kyphosis progression ( $r = 0.345$ ,  $P = 0.05$ ).

The mean BMI was also significantly different between the two study groups. In this respect, a considerably lower BMI was observed in the patients of group A ( $P < 0.001$ ). A significant negative correlation was observed between the BMI values of the patients and kyphosis progression ( $r = -0.407$ ,  $P = 0.001$ ).

The mean of spine BMD was significantly lower in group A in comparison with group B ( $P = 0.037$ ). Nevertheless, no significant difference was observed between the BMD of femoral in the two study groups ( $P = 0.83$ ).

Thoracolumbar junction fracture was significantly more frequent in the patients of group A (18 out of 19 patients) ( $P = 0.049$ ). The incidence of anterior cortical wall fracture was also remarkably higher in group A compared to group B ( $P = 0.007$ ). Previous osteoporotic fracture was



**Figure 3.** Progression of kyphosis to  $\geq 30^\circ$  in an OVCF patient following the conservative management: (A) Baseline standing lateral radiography; (B) Standing lateral radiography, one month after the start of treatment; (C) Standing lateral radiography of final follow-up (four months after the start of conservative treatment)

recorded in four patients that presented with LKA progression. LKA progressed to  $\geq 30^\circ$  in all of these four patients ( $P < 0.008$ ).

No significant difference was observed between the two study groups in terms of the gender distribution ( $P = 0.47$ ) and serum 25 (OH) vitamin D level ( $P = 0.67$ ).

After adjusting the kyphosis progression with age, BMI, BMD, and fracture location, it was observed that age, BMI, and fracture of thoracolumbar junction still remained as significant predictors for kyphosis progression to  $\geq 30^\circ$  ( $P = 0.02$ ,  $P = 0.009$ ,  $P = 0.05$ , respectively).

## 5. Discussion

Segmental kyphotic deformity might occur following the failure of conservative management of OVCF and considerably affect the quality of life of the affected patients (8, 12, 13). Due to the significant importance of these complications, many recent investigations are devoted to the identification of potential risk factors for this complication (13). Indeed, if the patient's response to conservative treatment can be predicted at the acute phase of fracture,

surgical therapeutic options might be considered to avoid major complications of conservative approach (13). Due to this reason, the current study aimed at evaluating the risk factors, which might determine the need for early surgical intervention. According to the current study results, higher age, lower BMI, smaller spinal BMD, thoracolumbar junction fracture, and anterior wall fracture were associated with progression of LKA to  $\geq 30^\circ$ .

Aging is considered as a risk factor for osteoporosis; therefore, the density of bones starts to decrease after the age of 40 years (14). Lower BMI is also associated with increased risk of osteoporosis (15). Today, it is well-acknowledged that BMD alone is not a reliable predictor of osteoporotic fracture and the role of other factors such as age and BMI simultaneously contributes as a corrected BMD (15). Considering the kyphotic deformity as the subsidence of the vertebral body, its association with BMI, BMD, and age of the patients could be justified.

Ha et al., prospectively investigated related clinical and radiological risk factors of progressive collapse following the conservative management of acute OVCF in 75 patients and at the end of six months. According to their results,

**Table 1.** Comparison of the Characteristics of the Patients in the Two Study Groups

Variable	Group A Kyphosis $\geq 30^\circ$ (N = 19)	Group B Kyphosis $< 30^\circ$ (N = 41)	P-Value
Age (y)	72.5 $\pm$ 12.7	64.2 $\pm$ 11.1	0.013 <sup>a</sup>
<b>Gender</b>			
Male	6 (31.6)	15 (36.6)	0.77
Female	13 (68.4)	26 (63.4)	
<b>Thoracolumbar junction fracture</b>			
Yes	18 (94.7)	30 (73.2)	0.049 <sup>a</sup>
No	1 (5.3)	11 (26.8)	
<b>Kyphosis progression (<math>^\circ</math>)</b>	16.2 $\pm$ 7.2	1.92 $\pm$ 2.7	$< 0.001^a$
<b>BMI (kg/m<sup>2</sup>)</b>	22.4 $\pm$ 4.66	27.8 $\pm$ 4.99	$< 0.001^a$
<b>Femoral neck BMD (g/cm<sup>2</sup>)</b>	0.57 $\pm$ 0.13	0.57 $\pm$ 0.11	0.837
<b>Spine BMD (g/cm<sup>2</sup>)</b>	0.66 $\pm$ 0.13	0.74 $\pm$ 0.14	0.037 <sup>a</sup>
<b>Superior endplate fracture (n)</b>	15	34	0.711
<b>Inferior endplate fracture (n)</b>	1	9	0.107
<b>Anterior cortical wall fracture (n)</b>	9	5	0.007 <sup>a</sup>
<b>25 (OH)vitD level (ng/mL)</b>	26.86 $\pm$ 21.1	29.48 $\pm$ 22.47	0.67
<b>Previous OVCF (n)</b>	4	0	0.008 <sup>a</sup>

Abbreviations: BMI: body mass index; BMD: bone mineral density; OVCF: osteoporotic vertebral compression fracture.

<sup>a</sup> Data are expressed as mean  $\pm$  SD or number (%). P < 0.05 is considered the level of significance.

the increase of  $\geq 10^\circ$  in kyphotic angle was associated with worse clinical results. Moreover, involvement of the posterior vertebral wall was associated with progressive collapse in their patients. They did not observe any significant association between BMD (T-score)/BMI/age and  $\geq 10^\circ$  progression in kyphosis angle, which was in contrast to the current study results. However, it should be noted that the study by Ha et al., was different from the current study in some aspects. First, in the study by Ha et al., the patients were divided into two groups based on the change of kyphosis angle:  $\geq 10^\circ$  progression and  $< 10^\circ$  progression. Second, in contrast to the current study, they used standard deviation of BMD (T-score) for their evaluations (16). Thus, further matched studies are needed to more accurately evaluate the role of BMD, BMI, and age of the patients in the progression of kyphosis following the conservative management of OVCF.

Patil et al., retrospectively evaluated the radiological predictors of kyphotic deformity in immediate post-injury image of 64 patients with OVCF that developed significant segmental kyphotic deformity ( $> 30^\circ$ ) at final follow-up and compared them with those of the patients that did not. At a mean follow-up period of 27.5 months, thoracolumbar junction and superior endplate fractures were probably at the highest risk of segmental kyphotic deformity. Although anterior cortical wall fracture was more frequent in patients with kyphotic deformity of  $> 30^\circ$  in the study by Patil et al., this association was not statistically significant. Due to this reason, they introduced anterior cortical wall fracture as a minor risk factor of segmen-

tal kyphosis progression (12). One possible explanation for the higher frequency of anterior cortical wall fracture in patients with segmental kyphotic deformity could be the damage of blood vessels of the anterior part of vertebra following the fracture and subsequent osteonecrosis of the vertebra (17).

The current study had some weak-points, which should be mentioned. The main weakness of the current study was the small sample size, especially in group A, which might have adversely affected the power of statistical analysis. Moreover, the follow-up period of the study was relatively short, while long-term follow-up would have resulted in more valuable information.

Altogether, higher age, lower BMI, and fracture of thoracolumbar junction could be considered as the risk factors for the progression of kyphosis of  $\geq 30^\circ$  following the conservative management of OVCF. These factors could be used to identify the patients benefit the most from conservative treatment.

## References

- Melton LJ, Kan SH, Frye MA, Wahner HW, O'Fallon W, Riggs B. Epidemiology of Vertebral Fractures in Women. *American Journal of Epidemiology*. 1989;129(5):1000-11. doi: 10.1093/oxfordjournals.aje.a115204.
- Center JR, Nguyen TV, Schneider D, Sambrook PN, Eisman JA. Mortality after all major types of osteoporotic fracture in men and women: an observational study. *Lancet*. 1999;353(9156):878-82. doi: 10.1016/S0140-6736(98)09075-8. [PubMed: 10093980].
- Guo JB, Zhu Y, Chen BL, Xie B, Zhang WY, Yang YJ, et al. Surgical versus non-surgical treatment for vertebral compression fracture with osteopenia: a systematic review and meta-analysis. *PLoS*

- One. 2015;**10**(5). e0127145. doi: [10.1371/journal.pone.0127145](https://doi.org/10.1371/journal.pone.0127145). [PubMed: [26020950](https://pubmed.ncbi.nlm.nih.gov/26020950/)]. [PubMed Central: [PMC4447413](https://pubmed.ncbi.nlm.nih.gov/PMC4447413/)].
4. Vedantam R. Management of osteoporotic vertebral compression fractures: a review. *Am J Clin Med Fall*. 2009;**6**(4):14–8.
  5. Mathis JM, Ortiz AO, Zoarski GH. Vertebroplasty versus kyphoplasty: a comparison and contrast. *AJNR Am J Neuroradiol*. 2004;**25**(5):840–5. [PubMed: [15140732](https://pubmed.ncbi.nlm.nih.gov/15140732/)].
  6. Robinson Y, Tschoke SK, Stahel PF, Kayser R, Heyde CE. Complications and safety aspects of kyphoplasty for osteoporotic vertebral fractures: a prospective follow-up study in 102 consecutive patients. *Patient Saf Surg*. 2008;**2**:2. doi: [10.1186/1754-9493-2-2](https://doi.org/10.1186/1754-9493-2-2). [PubMed: [18271950](https://pubmed.ncbi.nlm.nih.gov/18271950/)]. [PubMed Central: [PMC2248169](https://pubmed.ncbi.nlm.nih.gov/PMC2248169/)].
  7. McConnell CJ, Wippold F2, Ray CJ, Weissman BN, Angevine PD, Fries IB, et al. ACR appropriateness criteria management of vertebral compression fractures. *J Am Coll Radiol*. 2014;**11**(8):757–63. doi: [10.1016/j.jacr.2014.04.011](https://doi.org/10.1016/j.jacr.2014.04.011). [PubMed: [24935074](https://pubmed.ncbi.nlm.nih.gov/24935074/)].
  8. Belmont PJ, Polly DJ, Cunningham BW, Klemme WR. The effects of hook pattern and kyphotic angulation on mechanical strength and apical rod strain in a long-segment posterior construct using a synthetic model. *Spine (Phila Pa 1976)*. 2001;**26**(6):627–35. [PubMed: [11305279](https://pubmed.ncbi.nlm.nih.gov/11305279/)].
  9. Gold DT. The clinical impact of vertebral fractures: Quality of life in women with osteoporosis. *Bone*. 1996;**18**(3):S185–9. doi: [10.1016/8756-3282\(95\)00500-5](https://doi.org/10.1016/8756-3282(95)00500-5).
  10. Old JL, Calvert M. Vertebral compression fractures in the elderly. *Am Fam Physician*. 2004;**69**(1):111–6. [PubMed: [14727827](https://pubmed.ncbi.nlm.nih.gov/14727827/)].
  11. Leech JA, Dulberg C, Kellie S, Pattee L, Gay J. Relationship of lung function to severity of osteoporosis in women. *Am Rev Respir Dis*. 1990;**141**(1):68–71. doi: [10.1164/ajrccm/141.1.68](https://doi.org/10.1164/ajrccm/141.1.68). [PubMed: [2297189](https://pubmed.ncbi.nlm.nih.gov/2297189/)].
  12. Patil S, Nene AM. Predictors of kyphotic deformity in osteoporotic vertebral compression fractures: a radiological study. *Eur Spine J*. 2014;**23**(12):2737–42. doi: [10.1007/s00586-014-3457-x](https://doi.org/10.1007/s00586-014-3457-x). [PubMed: [25011583](https://pubmed.ncbi.nlm.nih.gov/25011583/)].
  13. Muratore M, Ferrera A, Masse A, Bistolfi A. Osteoporotic vertebral fractures: predictive factors for conservative treatment failure. A systematic review. *Eur Spine J*. 2017. doi: [10.1007/s00586-017-5340-z](https://doi.org/10.1007/s00586-017-5340-z). [PubMed: [29030703](https://pubmed.ncbi.nlm.nih.gov/29030703/)].
  14. Wong CC, McGirt MJ. Vertebral compression fractures: a review of current management and multimodal therapy. *J Multidiscip Healthc*. 2013;**6**:205–14. doi: [10.2147/JMDH.S31659](https://doi.org/10.2147/JMDH.S31659). [PubMed: [23818797](https://pubmed.ncbi.nlm.nih.gov/23818797/)]. [PubMed Central: [PMC3693826](https://pubmed.ncbi.nlm.nih.gov/PMC3693826/)].
  15. Compston JE. Bone density: BMC, BMD, or corrected BMD? *Bone*. 1995;**16**(1):5–7. doi: [10.1016/8756-3282\(95\)80004-a](https://doi.org/10.1016/8756-3282(95)80004-a).
  16. Ha KY, Kim YH. Risk factors affecting progressive collapse of acute osteoporotic spinal fractures. *Osteoporos Int*. 2013;**24**(4):1207–13. doi: [10.1007/s00198-012-2065-z](https://doi.org/10.1007/s00198-012-2065-z). [PubMed: [22752072](https://pubmed.ncbi.nlm.nih.gov/22752072/)].
  17. Ryu CW, Han H, Lee YM, Lim MK. The intravertebral cleft in benign vertebral compression fracture: the diagnostic performance of non-enhanced MRI and fat-suppressed contrast-enhanced MRI. *Br J Radiol*. 2009;**82**(984):976–81. doi: [10.1259/bjr/57527063](https://doi.org/10.1259/bjr/57527063). [PubMed: [19581311](https://pubmed.ncbi.nlm.nih.gov/19581311/)]. [PubMed Central: [PMC3473379](https://pubmed.ncbi.nlm.nih.gov/PMC3473379/)].