



# Management of Intra-Articular Fractures of the Calcaneus: Introducing a New Locking Plate

Bijan Valiollahi<sup>1,\*</sup> and Mostafa Salariyeh<sup>1</sup>

<sup>1</sup>Bone and Joint Reconstruction Research Center, Shafa Orthopedic Hospital, Iran University of Medical Sciences, Tehran, Iran

\*Corresponding author: Bone and Joint Reconstruction Research Center, Shafa Orthopedic Hospital, Iran University of Medical Sciences, Tehran, Iran. Email: bijan.valiollahi@gmail.com

Received 2016 October 31; Revised 2018 September 22; Accepted 2018 September 27.

**Keywords:** Calcaneus Fracture, New Plate, Sinus Tarsal Approach

## Dear Editor,

Fracture of the calcaneus is usually a challenging problem for orthopedic surgeons and patients. Calcaneal fractures are the most common of tarsal bone fractures, and most of them are displaced intra-articular (nearly 75%) fractures, usually resulting from falling or motor vehicle accidents (1).

Most patients with calcaneal fractures are usually young men in their prime working years, which results in a significant loss of economic productivity. Although surgical techniques and fixation implants have generally improved functional outcomes, there is vast controversy as to the management of these highly complex injuries.

Displaced intra-articular fractures of the calcaneus are usually due to high-energy trauma. In displaced intra-articular calcaneal fracture, calcaneus height is reduced in such a way that leads to a short and wide heel. This is usually associated with varus malalignment of the calcaneal tuberosity (1). This loss of height leads to a decreased Bohler's angle, thus, normal talus declination is diminished resulting in a more horizontal talus, which may decrease dorsiflexion of the ankle. As the superolateral fragment of the posterior facet is collapsed downward, the thin lateral wall protrudes laterally just posterior to the crucial angle of Gissane and may entrap the peroneal tendons against the lateral malleolus. In some cases, a vigorous contracture of the peroneal tendons may avulse the tendon sheath from the fibula, leading to an avulsion fracture of the lateral malleolus and subluxation or complete dislocation of the peroneal tendons.

The anterior process usually displaces in an upward direction leading to a limited subtalar joint motion directly by impinging against the lateral process of the talus. Accordingly, operative treatment is generally indicated for

displaced intra-articular fractures involving the posterior facet and is ideally performed within three weeks of injury. Beyond this time, separation of the fragments becomes more challenging. To achieve an adequate reduction, surgery must be performed after soft tissue swelling diminishes (2).

Full diminishing of soft tissue edema is demonstrated by a positive wrinkle test, indicating that surgical intervention may be performed safely. For the extensile lateral approach, a good skin with positive wrinkle test is needed. Concerns about high wound complication rates in the extensile lateral approach have prompted some to improve minimally invasive approaches to treating intra-articular calcaneal fractures (3).

In the minimally invasive approach, a suitable plate for definitive fixation is required. Therefore, we started straight sinus tarsal approach for open reduction and internal fixation of intra-articular fracture of the calcaneus since early 2014 in sanders II and III.

A 4 to 5 cm-long incision was made from the tip of the lateral malleolus to the calcaneocuboid joint towards the base of the fourth metatarsal bone. Then, we released peroneal tendon and the fragments were released from soft tissues, and the impacted posterolateral fragment was elevated to access the impacted medial wall. Afterwards, we corrected the Gissane angle with temporary pins No. 1.5 from the 4th metatarsal to calcaneus bone and we checked it with C-ARM. Then, reduction of the fragments became possible, and they were fixed temporarily with Kirschner wires No. 1.5. We used distractor with a pin (No. 2) in talus body and calcaneal tuberosity to see subtalar joint more clearly and help to reduce fragments by ligamentolysis and correction of Bohler's ankle. For a definitive fixation, we designed a new plate (2.7 mm locking anatomi-



Figure 1. 2.7-mm locking Bijan calcaneal plate

cal Bijan calcaneal titanium plate, regist No.88829; Figure 1), and we applied this plate for this sinus tarsal approach (Figure 2). This new plate is anatomical with a thickness of 1.8 mm, 11 holes (10 locking 2.7-mm screws and one compression screw), and three limbs for fixation of the three main fragments. For the posterior part of the plate, we performed percutaneous screw fixation. With this anatomical low-profile plate, minimal invasive approach can be used for all calcaneal fractures (more in sanders II and III).

We have applied this plate for 43 patients, and we were successful in fixing the three main fragments (i.e., post tuberosity, lateral fragment, and post facet) without any skin problems (Figure 3). Mostly, operations were performed within 1 - 7 days of injury. In future, further results will be coming out.

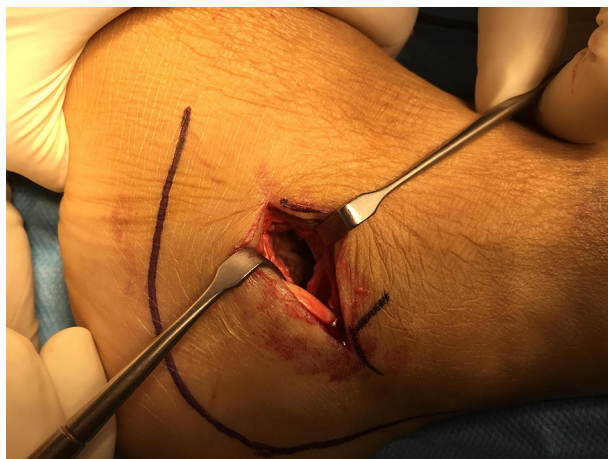


Figure 2. Sinus tarsi approach

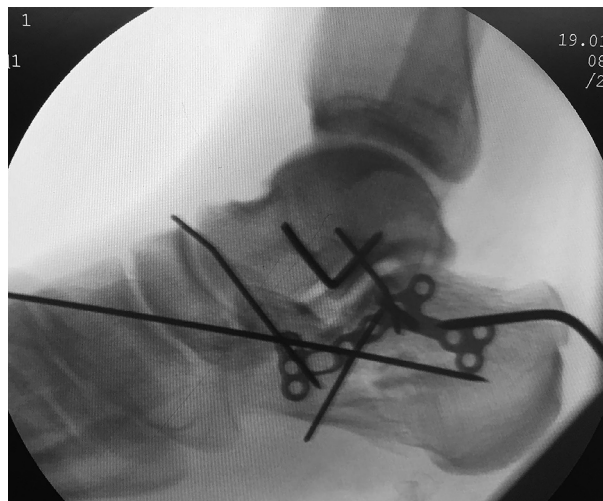

Figure 3. Intra-operative view of Bijan calcaneal plate in sanders III that helped with the fixation of the three main fragments with the minimally invasive approach

### References

1. Epstein N, Chandran S, Chou L. Current concepts review: Intra-articular fractures of the calcaneus. *Foot Ankle Int.* 2012;**33**(1):79-86. doi:10.3113/FAL.2012.0079. [PubMed: 22381241].
2. Kline AJ, Anderson RB, Davis WH, Jones CP, Cohen BE. Minimally invasive technique versus an extensile lateral approach for intra-articular calcaneal fractures. *Foot Ankle Int.* 2013;**34**(6):773-80. doi:10.1177/1071100713477607. [PubMed: 23460669].
3. Kikuchi C, Charlton TP, Thordarson DB. Limited sinus tarsi approach for intra-articular calcaneus fractures. *Foot Ankle Int.* 2013;**34**(12):1689-94. doi:10.1177/1071100713510267. [PubMed: 24151194].