

Case Report: Elbow Region Ganglion Cyst: A Case Report and Brief Review of Literature



Hamidreza Dehghani¹ , Mehryar Khadem^{1*} , Milad Bahari¹

1. Bone and Joint Reconstruction Research Center, Shafa Orthopedic Hospital, Iran University of Medical Science, Tehran, Iran.



Citation Dehghani H, Khadem M, Bahari M. Elbow Region Ganglion Cyst: A Case Report and Brief Review of Literature. Journal of Research in Orthopedic Science. 2020; 7(2):87-92. <http://dx.doi.org/10.32598/JROS.7.2.619.1>

doi <http://dx.doi.org/10.32598/JROS.7.2.619.1>



Article info:

Received: 17 Sep 2019

Revised: 09 Feb 2020

Accepted: 13 Mar 2020

Available Online: 01 May 2020

Keywords:

Elbow, Ganglion cyst,
Case report

ABSTRACT

A ganglion cyst is a small sac of fluid that forms over a joint or tendon (tissue that connects muscle to bone). A 23-year-old woman, right hand dominant, and Laboratory expert, was referred with a 1-year history of a lump in the anterior aspect of her elbow associated with altered sensation in the anterolateral aspect of her left hand. Her elbow was painful and the mass progressive increased in size during the last 1.5 months. There was no history of trauma, injections or manipulation. The patient had no symptoms of fever, ulcers, or numbness. On physical examination, there was a tendered mass about 4 cm in diameter in the anterior aspect of the elbow. X-ray was normal and MRI confirmed a mass along with a radiocapitellar capsule. The cyst and radial nerve were explored through an anterolateral curved incision, with ligation of the radial recurrent vessels. The cyst was on the capsule of the radiocapitellar joint and posterior to the interosseous nerve at the proximal fibers on the edge of the supinator muscle. The cyst was identified as a ganglion clinically, and excised completely. Pathology finding confirmed it. The lateral elbow pain disappeared immediately after surgery, with no neurological deficit. The patient returned to work after 1 month.

1. Introduction

A Ganglion cyst is a small sac of fluid that forms over a joint or tendon (tissue that connects muscle to bone). The cyst contains a thick, sticky, clear, colorless, jellylike material. Depending on the size, cysts may be firm or spongy [1].

One large cyst or many smaller ones may develop. Multiple small cysts can give the appearance of more than one cyst, but a common stalk usually connects them

within the deeper tissue. This type of cyst is not harmful and accounts for about half of all soft tissue tumors of the hand [2]. Ganglion cysts, also known as Bible cysts, are more common in women, and 70% occur in people aged 20-40 years. Rarely, ganglion cysts can occur in children younger than 10 years [3].

Ganglion cysts most commonly occur on the back of the hand at the wrist joint but they can also develop on the palm side of the wrist. When found on the back of the wrist, they become more prominent when the wrist is flexed forward. Other sites, although less common,

* Corresponding Author:

Mehryar Khadem, MD.

Address: Bone and Joint Reconstruction Research Center, Shafa Orthopedic Hospital, Iran University of Medical Science, Tehran, Iran.

Phone: +98 (912) 4251487

E-mail: mehryarkhadem90@gmail.com

include the base of the fingers on the palm, where they appear as small pea-sized bumps, the fingertip, just below the cuticle, where they are called mucous cysts, the outside of the knee and ankle, and the top of the foot [4].

The cause of ganglion cysts is unknown. One theory suggests that trauma causes the tissue of the joint to break down, forming small cysts that join into a larger, more obvious mass. The most likely theory involves a flaw in the joint capsule or tendon sheath that allows the joint tissue to bulge out [5].

The ganglion cyst usually appears as a mass that progressively enlarges. It is usually soft, anywhere from 1-3 cm in diameter, and does not move. The swelling may appear over time or appear suddenly, may get smaller in size, and may even go away, only to come back at another time. Most ganglion cysts cause some degree of pain, usually following acute or repetitive trauma, but up to 35% are without symptoms except for appearance. If pain is present, it is usually chronic and made worse by joint motion. In hand, when the cyst is connected to a tendon, it may cause a sense of weakness in the affected finger [6].

In this article we report the case of a radiocapitellar joint ganglion cyst without any neurological involve-

ment in the elbow, in a middle-aged female where the diagnosis could not be made for more than a year.

2. Case Presentation

A 23-year-old woman, right hand dominant, and Laboratory expert, was referred with a 1-year history of a lump in the anterior aspect of her elbow associated with altered sensation in the anterolateral aspect of her left hand. Her elbow was painful and the mass progressively increased in size during the last 1.5 months. She had no history of trauma or any exacerbating factor. The patient had no symptoms of fever, ulcers, or numbness. On physical examination, there was a tender mass about 4 cm in diameter in the anterior aspect of the elbow.

X-ray images had no finding and MRI confirmed a mass along with the radiocapitellar capsule (Figure 1). The mass had no motion, with neither firm nor soft stiffness. The skin over the mass was normal (Figure 2). The cyst and radial nerve were explored through an anterolateral curved incision, with ligation of the radial recurrent vessels.

The cyst was on the capsule of the radiocapitellar joint and posterior to the interosseous nerve at the proximal fibers edge of the supinator muscle. The nerve was intact

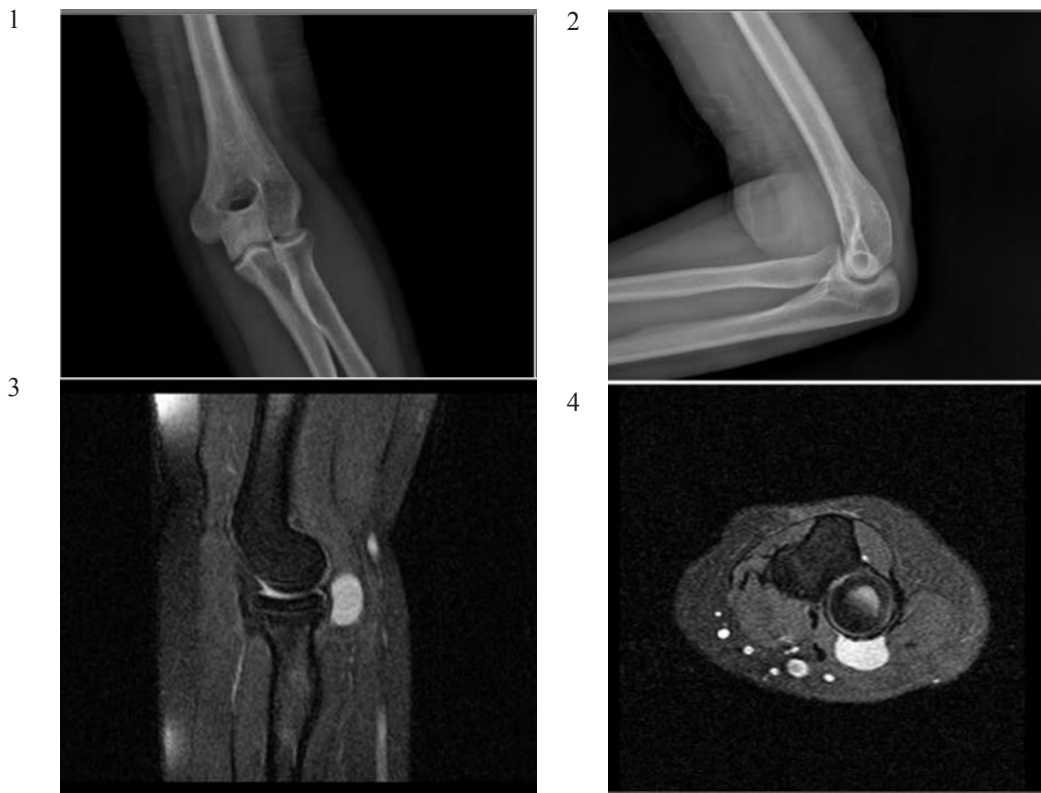

Figure 1. x-ray 1. AP; 2. Lateral; and MRI 3. Sagittal T2 weighted; 4. Axial T2 weighted of elbow

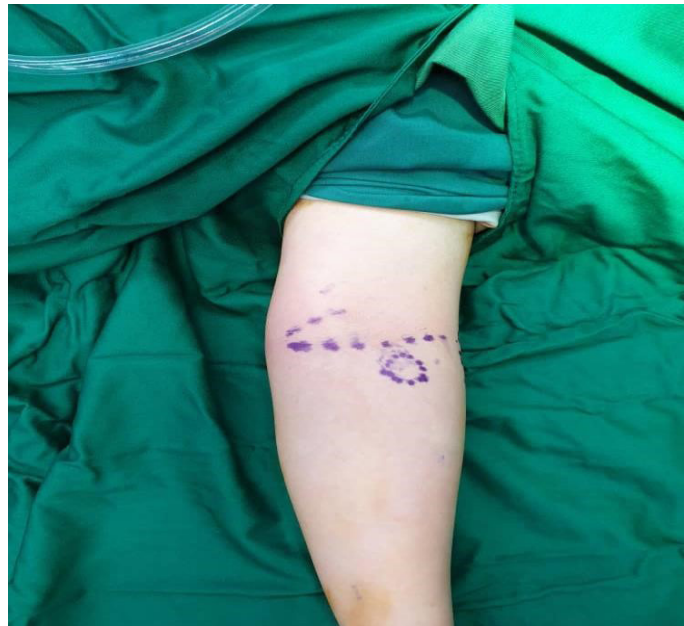

Figure 2. Appearance of the patient's left hand before the operation

Journal of Research in
Orthopedic Science

(Figure 3A and 3B). The cyst was identified as a ganglion clinically and excised completely (Figure 4). It contained pale yellow jelly-like material. The diagnosis of ganglion was confirmed histologically (Figure 5). The lateral elbow pain disappeared immediately after surgery, with no neurological deficit. There were no pain and no complications and the patient returned to work after 1 month.

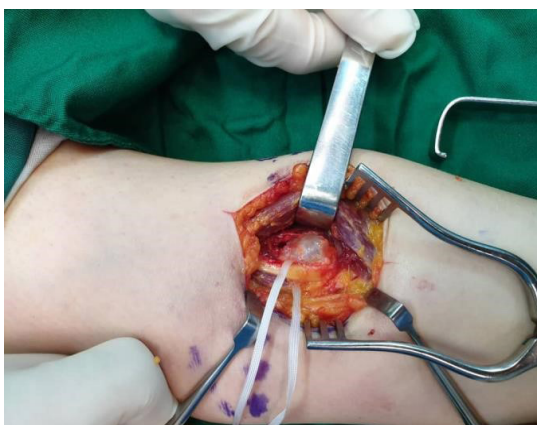3. Discussion

A ganglion is a cyst filled with colloid material developed within the vicinity of a joint or tendon sheath. The origin of ganglions has been debated for many years. The current hypotheses include: 1. retention cysts; 2. herniation of joint capsule; 3. degenerative cysts; and 4.

ligament strain with an impaired repair process leading to a mucinous degeneration. The commonest variety, i.e., the carpal ganglion, presents with a smooth, rounded, or oval swelling on the dorsal aspect of the carpus, usually towards its radial side. Ganglia are thought to arise from cystic degeneration in a tendon sheath or joint capsule usually in middle-aged males [1].

In literature, there are many case reports of the elbow ganglion cyst. Most of them had neurologic involvement. Hartwell et al. were among the first who reported intraneural ganglion of the median nerve [7]. Over 80 cases of intraneural ganglion have been reported in English articles so far [8]. Ours is the first case report of the

A



B

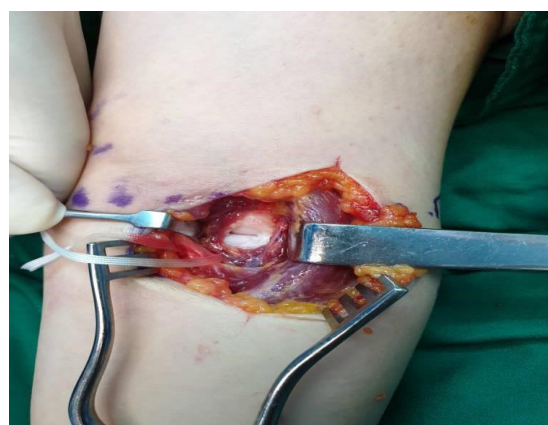

Figure 3. A. Intraoperative picture showing the cyst and B. Rent in the capsule of radiocapitellar joint

Journal of Research in
Orthopedic Science

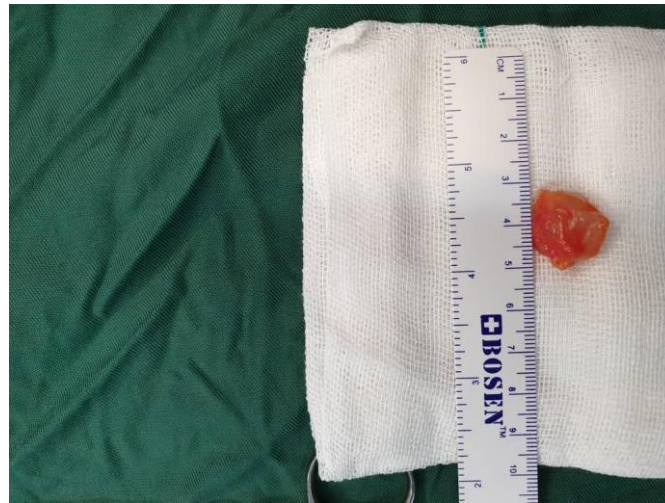

Figure 4. Dissection and resection of the ganglion

Journal of Research in
Orthopedic Science

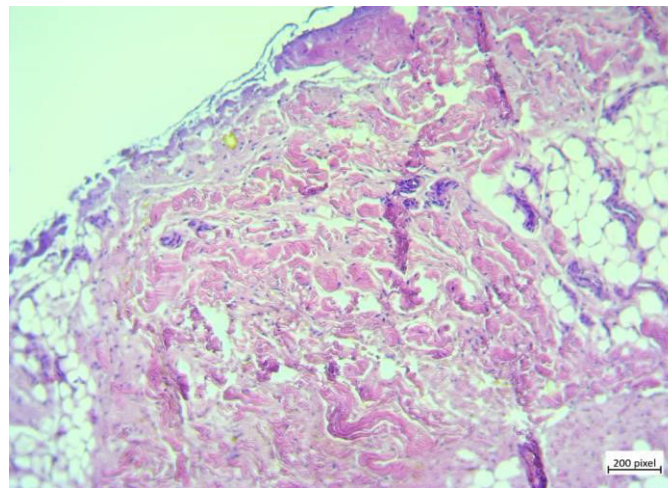


Figure 5. Histology of ganglion showing meshwork of fibrous tissue

Journal of Research in
Orthopedic Science

radiocapitellar joint ganglion cyst without any neurological involvement.

These cysts may result from a lack of support from surrounding structures in the elbow which leads to a gradual disturbance in the mechanics of movement and the production of excess fluid in a synovial membrane [1]. Other differential diagnoses in this site, like lipoma, should be considered. Safe excision without nerve damage requires wide exploration not only of the cyst but of the normal nerve trunk above and below, and beyond the attachment of the ganglion. Careful separation of the cyst from normal fasciculi is necessary, too.

Ethical Considerations

Compliance with ethical guidelines

All ethical principles were considered in this article.

Funding

This research did not receive any specific grant from funding agencies in the public, commercial, or not-for-profit sectors.

Authors' contributions

All authors contributed in preparing this article.

Conflict of interest

The authors declared no conflict of interest.

References

- [1] Nelson CL, Sawmiller S, Phalen GS. Ganglions of the wrist and hand. *J Bone Joint Surg.* 1972; 54A:1459-64. [DOI:10.2106/00004623-197254070-00009]

- [2] Barnes WE, Larsen RD, Posch JL. Review of ganglia of the hand and wrist with analysis of surgical treatment. *Plast Reconstr Surg*. 1964; 34:570-8. [DOI:10.1097/00006534-196412000-00004] [PMID]
- [3] Zachariae L, Vibe-Hansen H. Ganglia: Recurrence rate elucidated by a follow-up of 347 operated cases. *Acta Chir Scand*. 1973; 139:625-8.
- [4] Green DP, O'Brien ET. Open reduction of carpal dislocations: Indications and operative techniques. *J Hand Surg*. 1978; 3:250-65. [DOI:10.1016/S0363-5023(78)80089-6]
- [5] Cooney WP, Bussey R, Dobyns JH, Linscheid RL. Difficult wrist fractures: Perilunate fracture-dislocations of the wrist. *Clin Orthop*. 1987; 214:136-47.
- [6] Carp L, Stout AP. A study of ganglion: With especial reference to treatment. *Surg Gynecol Obstet*. 1928; 47:460-5.
- [7] Hartwell AS. Cystic tumor of median nerve: Operation: Restoration of function. *Boston Med Surg J*. 1901; 144:582-3.
- [8] Stack RE, Bianco AJ, Maccarty CS. Compression of the common peroneal nerve by ganglion cysts: Report of nine cases. *J Bone Joint Surg*. 1965; 47A:773-8. [DOI:10.2106/00004623-196547040-00012]

This Page Intentionally Left Blank