



Clinical Image
<http://crp.tums.ac.ir>

Too Many Calcifications

Morteza Daraei

Department of Internal Medicine, Imam Khomeini Hospital, University of Medical Sciences, Tehran, Iran

Received: 3 May 2018

Revised: 21 May 2018

Accepted: 17 June 2018

ARTICLE INFO

Corresponding author:
Morteza Daraei
Email:
mortezadaraie@gmail.com

Keywords

Mammography;
Calciphylaxis;
End-Stage Renal Disease

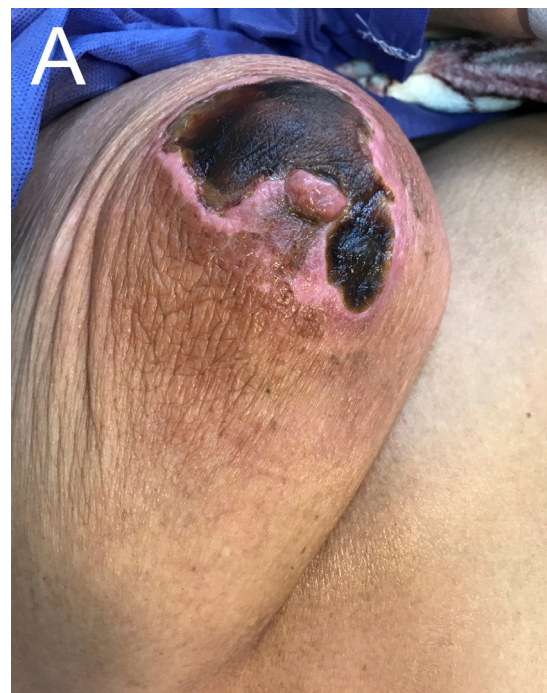Citation: Daraei M. **Too Many Calcifications.** Case Rep Clin Pract 2018; 3(2): 58-59.

Introduction

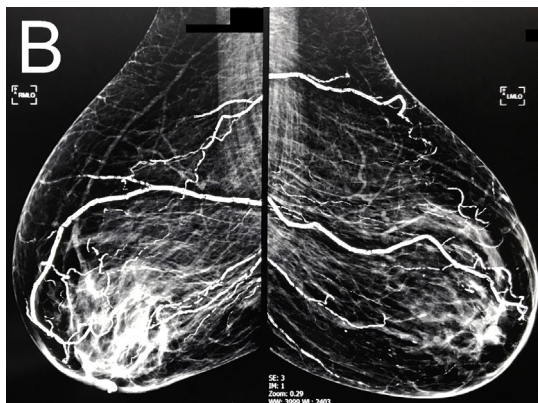
A 65-year-old woman with history of diabetes mellitus induced end-stage renal disease (ESRD) presented with several weeks of bilateral breast pain and ulcers that did not respond to empirical antibiotics. On examination there were bilateral necrotic ulcers, surrounded by erythema which were tender on palpation (Panel A).

Her medications were calcitriol and calcium supplement. Laboratory data revealed serum calcium level of 7.9 mg/dl, phosphorus 4 mg/dl, 25(OH) vitamin D 16.9 ng/ml and iPTH was 32 pg/ml. Mammography showed bilateral retro-areolar densities with widespread arterial calcifications (Panel B). She refused debridement and tissue biopsy.

Although we could not confirm the diagnosis by pathologic exam but this mammogram with



Panel A. Areolar necrotic ulcer with erythematous border



Panel B. Evidence of retro-areolar densities with widespread arterial calcifications in mammography

compatible clinical setting was highly suggestive of calciphylaxis.

Calciphylaxis is a well-recognized rare condition in which arteriolar calcification and occlusion induce painful ischemic ulcers usually in adipose-laden tissues. It is more often occur in

women with ESRD and its occurrence is associated with high morbidity and mortality. Treatment option is limited and include conservative management such as necrotic tissue debridement, prevention of secondary infection and correction of calcium and phosphorus abnormalities.

References

1. Mazhar AR, Johnson RJ, Gillen D, Stivelman JC, Ryan MJ, Davis CL, et al. Risk factors and mortality associated with calciphylaxis in end-stage renal disease. *Kidney Int.* 2001 Jul 1;60(1):324-32.
2. Wilmer WA, Magro CM. Calciphylaxis: emerging concepts in prevention, diagnosis, and treatment. In *Seminars in dialysis*. Malden, US: Blackwell Science Inc. 2002 Jun;15(3):172-186.